

ORIGINAL ARTICLE

TANDEM URETEROCYSTOPLASTY

SAEED AHMED, KHALID FOUDA NEEL AND SUDIPTA SEN

Department of Surgery, King Faisal Specialist Hospital and Research Centre, Riyadh, Saudi Arabia

Background: Bladder augmentation may be undertaken by using various gastrointestinal segments but their use is associated with a multitude of well-recognized complications. The mega-ureter has proven to be a satisfactory alternative; in patients with bilateral mega-ureters, both ureters may be used for this purpose.

Methods: Seventeen patients had augmentation ureterocystoplasty, including three in whom both distal ureters were used in tandem. The latter included two patients with neurogenic bladder and one with bladder exstrophy.

Results: Satisfactory augmentation was achieved in all patients undergoing tandem ureterocystoplasty. The neurogenic bladder patients are managed by urethral clean intermittent catheterization (CIC) and the exstrophy patient is managed by CIC of an appendicovesicostomy (Mitrofanoff). All are continent.

Conclusions: The mega-ureter provides an excellent source of augmentation material in patients with small non-compliant bladders. In those with bilateral mega-ureters, consideration should be given to using both ureters in tandem to achieve the maximum possible bladder capacity.

Key words: bladder augmentation, non-compliant bladder, mega-ureters, tandem ureterocystoplasty.

INTRODUCTION

The low-capacity, high-pressure, heavily trabeculated bladder with refluxing or obstructed mega-ureters is common in patients with neurogenic bladder, urethral valves and various other urological abnormalities. Pharmacological manipulation and clean intermittent catheterization (CIC) are major advances in management but bladder augmentation is often necessary.¹ Various gastrointestinal segments may be used for this purpose but the mega-ureter provides an ideal alternative. The aim is to achieve a low-pressure, large-capacity bladder, for which purpose we undertook tandem ureterocystoplasty using both mega-ureters in three patients.

METHODS

Seventeen children, aged 1–9 years, underwent ureterocystoplasty in the period 1993–96. Included were six female and three male patients with neurogenic bladder, five males with congenital bladder outflow obstruction (posterior urethral valves 4, urethral diverticulum 1), two males with bladder exstrophy and one male with severe bladder damage after multiple failed attempts to correct vesico-ureteric reflux (VUR). The reconstruction procedure included 9 ureteric reimplantations (1 bilateral), 9 transuretero-ureterostomies (TUU), 4 appendicovesicotomies, 2 bladder neck reconstructions and 2 unilateral nephrectomies. The left ureter was used in eight patients, the right was used in six patients and both distal ureters were used in tandem in two patients with neurogenic bladder and one with bladder exstrophy.

Technique of tandem ureterocystoplasty

A liberal laparotomy incision is necessary for the multiple steps required to reconstruct the urinary tract. Both the ureters are

carefully inspected with respect to their width and also tortuosity/redundancy to determine the feasibility of the procedure. The ureters are then mobilized, carefully preserving the adventitial blood supply. The dissection is taken to within 1–2 cm of the ureteric hiatus and the ureters are divided at an appropriate level depending upon availability and the type of upper urinary tract reconstruction planned (Fig. 1). This may be by bilateral reimplantation of the proximal ureter or by unilateral reimplantation and TUU (Fig. 2). The bladder is usually opened in the transverse plane. The two ureters are detubularized and reconfigured, although this may be more conveniently achieved during anastomosis to the bladder. One ureter is sutured to the posterior flap of the bladder, the other to the anterior flap with the cystoplasty being completed by anastomosing ureter to ureter (Fig. 3). Continuous sutures of 5–0 Maxon (Davis and Geek, Baulkham Hills, NSW, Australia) are usually used for the cystoplasty. Various catheters are left *in situ* for postoperative drainage, these being removed as appropriate in about 2 weeks, following which CIC is commenced.

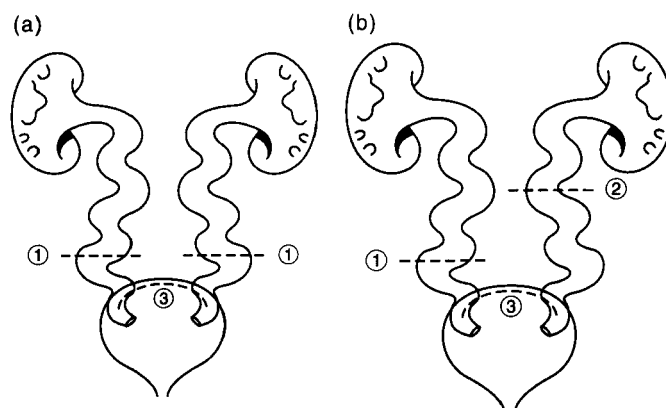


Fig. 1. Both lower ureters are divided at (a) level 1 and (b) levels 1 and 2, which will determine type of upper tract reconstruction and length of ureter available for cystoplasty.

Correspondence: Saeed Ahmed, Department of Paediatric Surgery, Women's and Children's Hospital, 72 King William Road, North Adelaide, SA 5006, Australia.

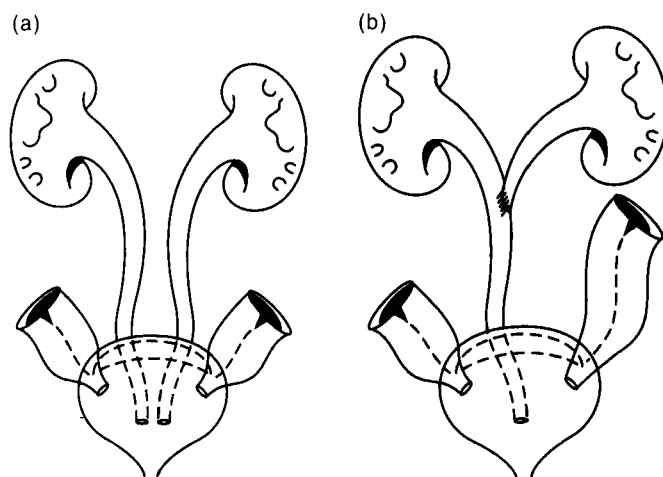


Fig. 2. Ureteric drainage re-established either by (a) bilateral ureteric reimplantation or by (b) unilateral reimplantation and TUU.

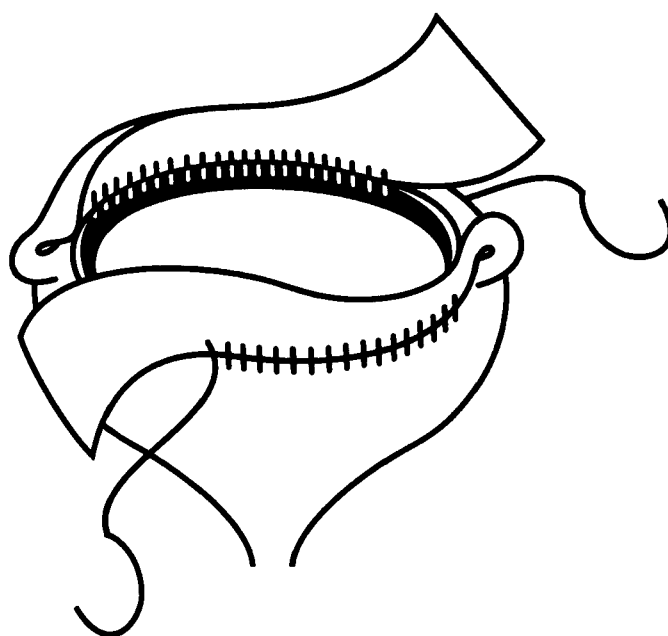


Fig. 3. The bladder is usually opened in the transverse plane (③ in Fig. 1). One opened ureter is anastomosed to the posterior flap of the opened bladder and the other to the anterior flap, the procedure being completed by anastomosing ureter to ureter.

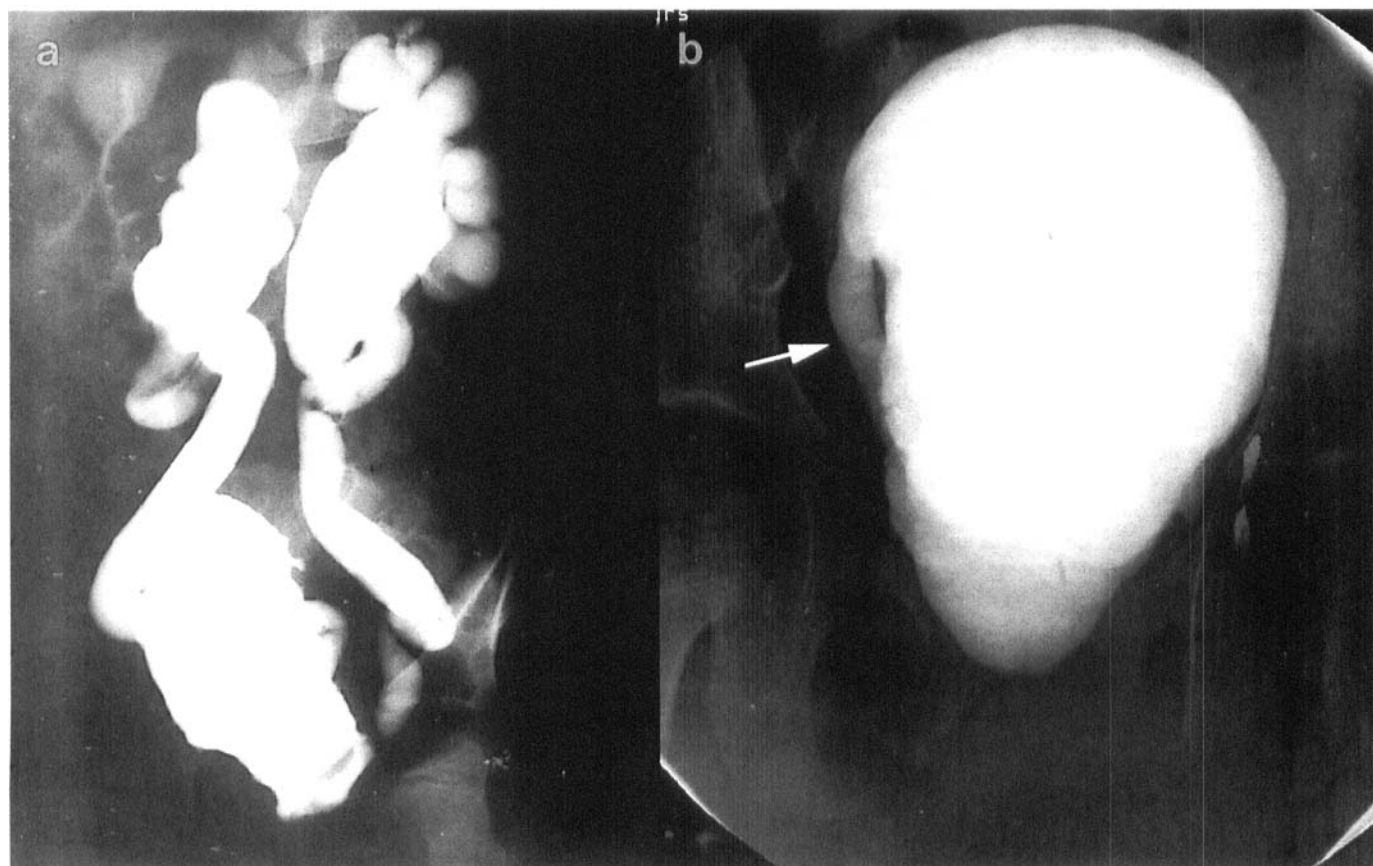


Fig. 4. (a) Pre-operative and (b) postoperative cysto-urethrograms after tandem ureterocystoplasty showing satisfactory augmentation and no VUR. Arrow shows stump of right ureter.

RESULTS

Case 1

A female child aged 4 years with myelodysplasia neurogenic bladder and gross VUR had tandem ureterocystoplasty and bilateral ureteric reimplantation. On follow-up for 16 months her renal function was normal but with significant residual hydronephrosis. She is continent on urethral CIC, the bladder capacity having increased from 120 to 300 mL (Fig. 4).

Case 2

A female child aged 5 years with myelodysplasia neurogenic bladder and gross VUR had tandem ureterocystoplasty, right ureteric reimplantation and right-to-left TUU. On follow-up for 1 year her renal function has remained normal with complete resolution of hydronephrosis. She is continent on urethral CIC, bladder capacity having increased from 80 to 200 mL.

Case 3

A male child aged 1 year with bladder exstrophy had severe bilateral ureterohydronephrosis secondary to ureterovesical obstruction and urethral stricture. Surgical reconstruction included tandem ureterocystoplasty, left ureteric reimplantation and right-to-left TUU together with bladder neck division and appendicovesicostomy. On follow-up at 6 months his upper tracts have improved, renal function is normal and he is continent on CIC with a bladder capacity over 100 mL.

DISCUSSION

The clinical features of non-compliant bladders in association with neurogenic disease, urethral valves and other bladder abnormalities are well recognized.^{2,3} Radiologically, such children usually have small-capacity, heavily trabeculated bladders and progressive upper tract dilatation and compromise of renal function. Vesico-ureteric reflux is considered to be the key factor in the pathogenesis of nephropathy in such patients, although 'obstructive nephropathy' may also be encountered.^{2,3} A unilateral refluxing mega-ureter may take up part of the storage function of the bladder, provide a pop-off mechanism and effectively protect the contralateral kidney.⁴ Ureteric reimplantation is technically difficult in such cases and has a high failure rate.⁵ Complete urinary tract reconstruction is therefore advisable, the aim being to provide a good-capacity compliant bladder with no VUR and to ensure adequate bladder-emptying. For the latter result an appendicovesicostomy was performed in case 3 and in three other patients.

The classical management of small trabeculated non-compliant bladders is by augmentation cystoplasty, for which purpose various detubularized intestinal segments or stomach may be used.^{6,7} However, there are well-recognized long-term complications associated with the use of gastrointestinal segments.⁸⁻¹⁰ Hence the need for a suitable alternative, the logical one being the refluxing mega-ureter, although we have also used obstructed ureters.¹¹⁻¹⁷

Whereas extraperitoneal ureterocystoplasty may be possible in selected cases, the majority, including those having the 'tandem' procedure, require a transperitoneal exposure. During ureteric mobilization and detubularization, we deliberately leave the distal 1-2 cm of ureter undisturbed, so lessening the risk of damage to the ureteric blood supply and to the vas deferens in males. The incision in the bladder should also stop short of the

ureteric orifice, particularly when tandem ureterocystoplasty is planned, because an incision extending into both ureteric orifices may render the posterior bladder flap ischaemic.¹⁸

In conclusion, ureterocystoplasty is an ideal alternative for bladder augmentation in patients with mega-ureter. Although the refluxing ureter is generally considered more suitable, the obstructed mega-ureter may also be used successfully. The procedure avoids the known risks of gastrointestinal segments, and eliminates the tubular ureter as a source of infection. Tandem ureterocystoplasty should be considered in patients with bilateral mega-ureters in order to achieve the objective of a good-capacity compliant bladder.¹⁹

REFERENCES

1. Synder HM. Principles of pediatric urinary reconstruction: A synthesis. In: Gillenwater JY, Grayhack JJ, Howards JJ *et al.* (eds). *Adult and Pediatric Urology*. Chicago: Year Book Medical Publishers, 1987; 1726-81.
2. Rink RC, Mitchell ME. Physiology of lower urinary obstruction. *Urol. Clin. North Am.* 1990; **17**: 329-34.
3. Khoury JM, Webster GD. Evaluation of augmentation cystoplasty for severe neuropathic bladder using the hostility score. *Dev. Med. Child Neurol.* 1992; **34**: 441-7.
4. Rittenberg MH, Hulbert WC, Snyder HM III, Duckett JW. Protective factors in posterior urethral valves. *J. Urol.* 1988; **140**: 993-6.
5. Jeffs RD, Jonas P, Schillinger JF. Surgical correction of vesico-ureteral reflux in children with neurogenic bladder. *J. Urol.* 1976; **115**: 449-51.
6. Goldwasser B, Webster GD. Augmentation and substitution enterocystoplasty. *J. Urol.* 1986; **135**: 215-24.
7. Adams MC, Mitchell ME, Rink RC. Gastrocystoplasty: An alternative solution to the problem of urological reconstruction in the severely compromised patient. *J. Urol.* 1988; **140**: 1152-6.
8. McDougal WS. Metabolic complications of urinary intestinal diversion. *J. Urol.* 1992; **147**: 1199-208.
9. Hensle TW, Dean GE. Complications of urinary tract reconstruction. *Urol. Clin. North Am.* 1991; **18**: 755-64.
10. Mahan JD, Mentser MI, Koff SA. Complications of intestinal augmentation and substitution cystoplasty. *Pediatr. Nephrol.* 1994; **8**: 505-7.
11. Churchill BM, Aliabadi H, Landau EH *et al.* Ureteral bladder augmentation. *J. Urol.* 1993; **150**: 716-20.
12. Wolf JS Jr, Turzan CW. Augmentation ureterocystoplasty. *J. Urol.* 1993; **149**: 1095-.
13. Bellinger MF. Ureterocystoplasty: A unique method for vesical augmentation in children. *J. Urol.* 1993; **149**: 811-13.
14. Hitchcock RJI, Duffy PG, Malone PS. Ureterocystoplasty: The bladder augmentation of choice. *Br. J. Urol.* 1994; **73**: 575-9.
15. Landau EH, Jayanthi VR, Khoury AE *et al.* Bladder augmentation: Ureterocystoplasty versus ileocystoplasty. *J. Urol.* 1994; **152**: 716-9.
16. Dewan PA, Nicholls EA, Goh DW. Ureterocystoplasty: An extraperitoneal urethelial bladder augmentation technique. *Eur. Urol.* 1994; **26**: 85-9.
17. Reinberg Y, Allen RC Jr, Vaughn M, McKenna PH. Nephrectomy combined with lower abdominal extraperitoneal ureteral bladder augmentation in the treatment of children with the vesico-ureteral reflux dysplasia syndrome. *J. Urol.* 1995; **153**: 177-9.
18. Gosalbez R Jr, Kim CO Jr. Ureterocystoplasty with preservation of ipsilateral renal function. *J. Pediatr. Surg.* 1996; **31**: 970-5.
19. Churchill BM, Jayanthi VR, Landau EH, McLorie GA, Khoury AE. Ureterocystoplasty: Importance of the proximal blood supply. *J. Urol.* 1995; **154**: 197-8.