

Subcutaneous mycoses

Fungal infections

1. Superficial mycosis.
2. Coetaneous mycosis: **Dermatophytoses.**
3. Subcutaneous mycosis.
4. Systemic mycosis.
5. Opportunistic mycosis.

Subcutanuse mycoses

- Fungal Infections that penetrate the dermis and subcautanuse tissues.

Subcutanuse mycosis include:

1. Chromomycosis
2. Mycetoma (Madura foot)
3. Phaeohyphomycosis

1- Chromomycosis

- it is a subcutaneous fungal infection caused by number of dematiaceous fungi.
- **Etiological agent:**
 - Phialophora verrucosa*
 - Fonsecaea pedrosoi*

1- Chromomycosis

Phialophora verrucosa

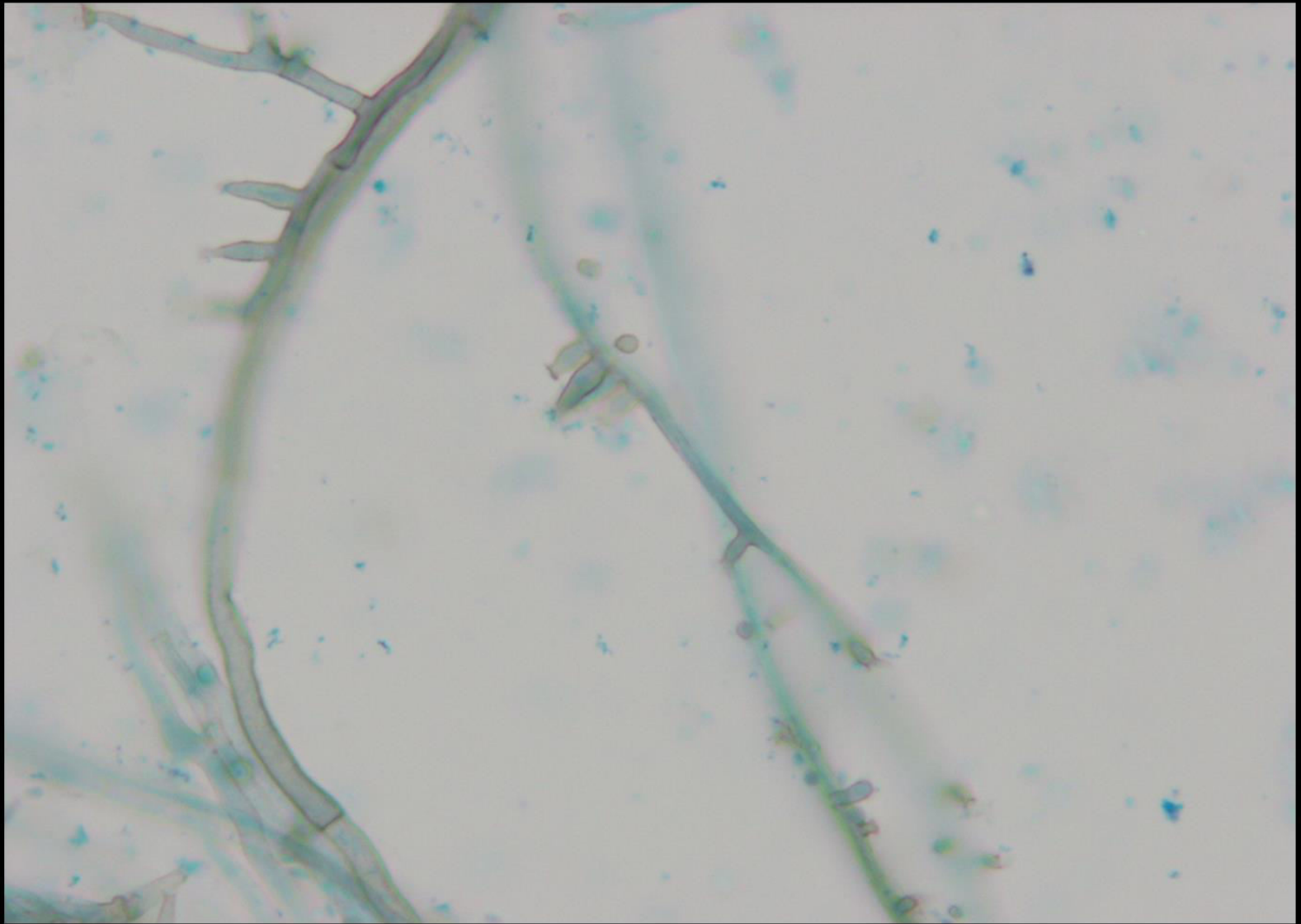
➤ colony morphology:

Dark gray or black

➤ microscopic morphology:

- Brown, branching Septate hyphae.
- Phialides are flask or vase shaped and they are formed laterally or at the tip
- Oval conidia at tip of phialides





1- Chromomycosis

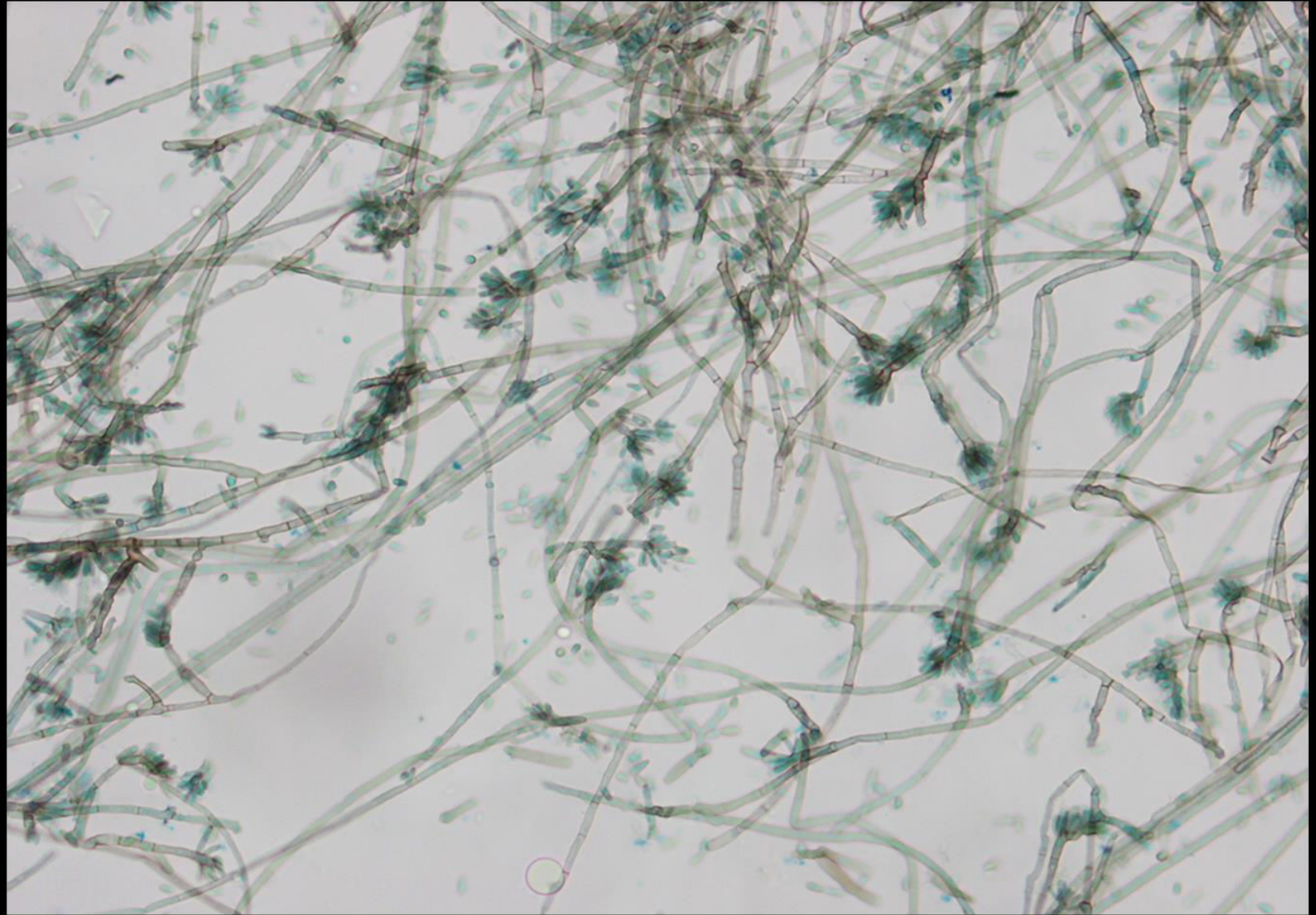
Fonsecaea pedrosoi

➤ Colony morphology:

Dark gray or black.

➤ Microscopic morphology:

- Branch ,brown Septate hyphae.
- Conidiophor vary in length .
- Elongated conidia giving flower like or finger like appearance



Laboratory Diagnosis

- **Specimen:** Biopsy tissue.
- **Direct microscopic examination:** stain with 10% KOH will show brown cells with septa.
- **Culture:** on SDA (very slow growing, black colonies).
- **Microscopic examination:** stain with LPCB.

2- Mycetoma

- It is a subcutaneous fungal infection which will cause grain in the infected site.
- **Etiological agent:**
 - i. *Madurella mycetomatis*
 - ii. *Monosporium apiospermum*

2- Mycetoma

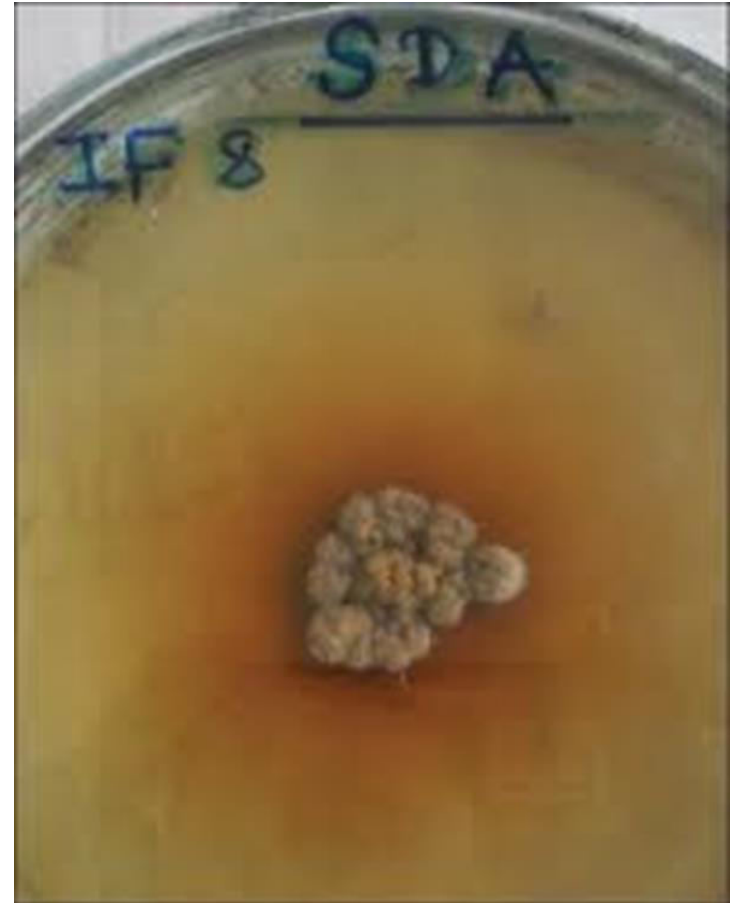Madurella mycetomatis

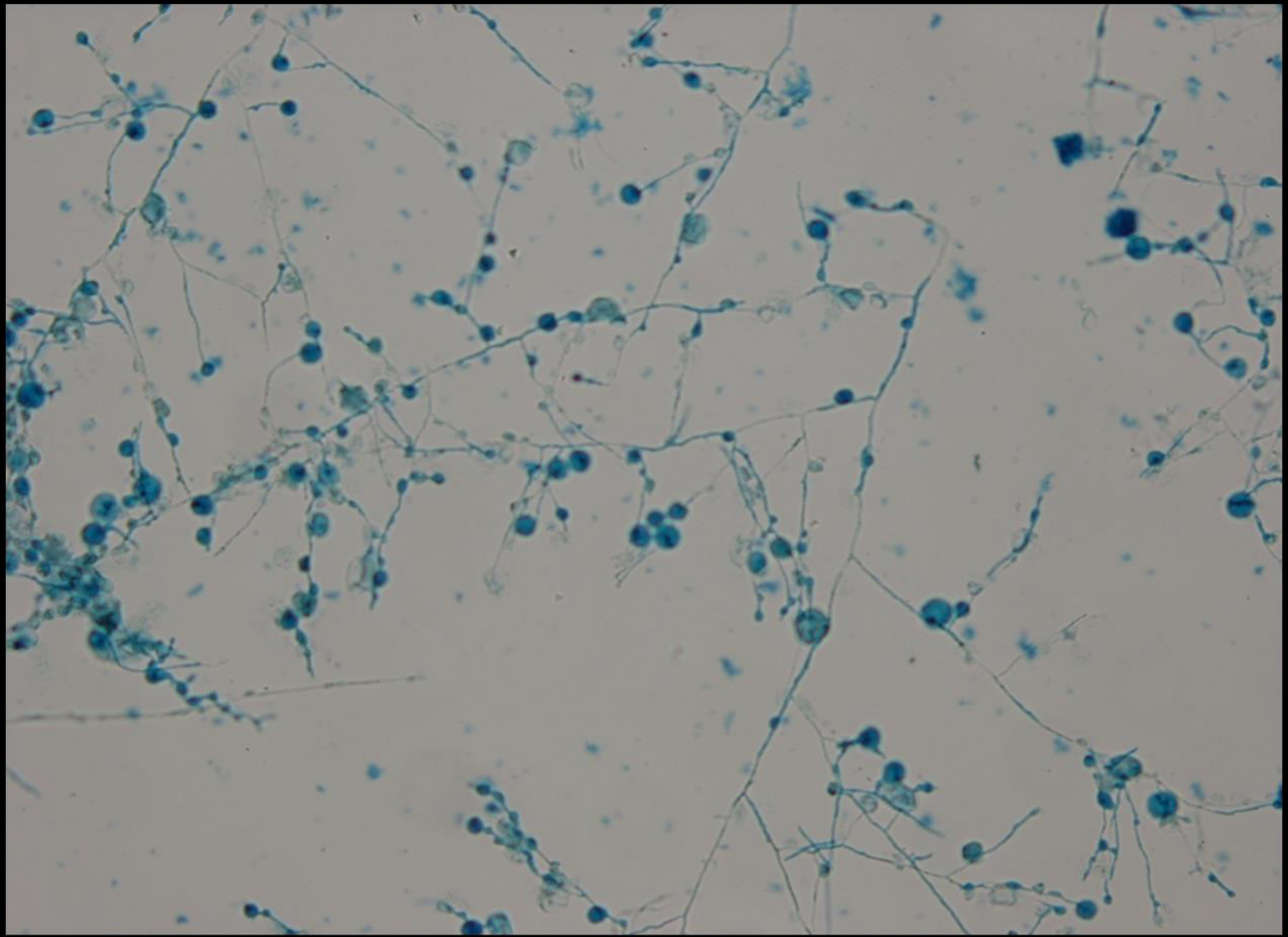
➤ **Colony morphology:**

- Flat, velvety brownish color
- Brown pigment diffuses in the agar

➤ **Microscopic morphology:**

- Septate hyphae with chlamydospore



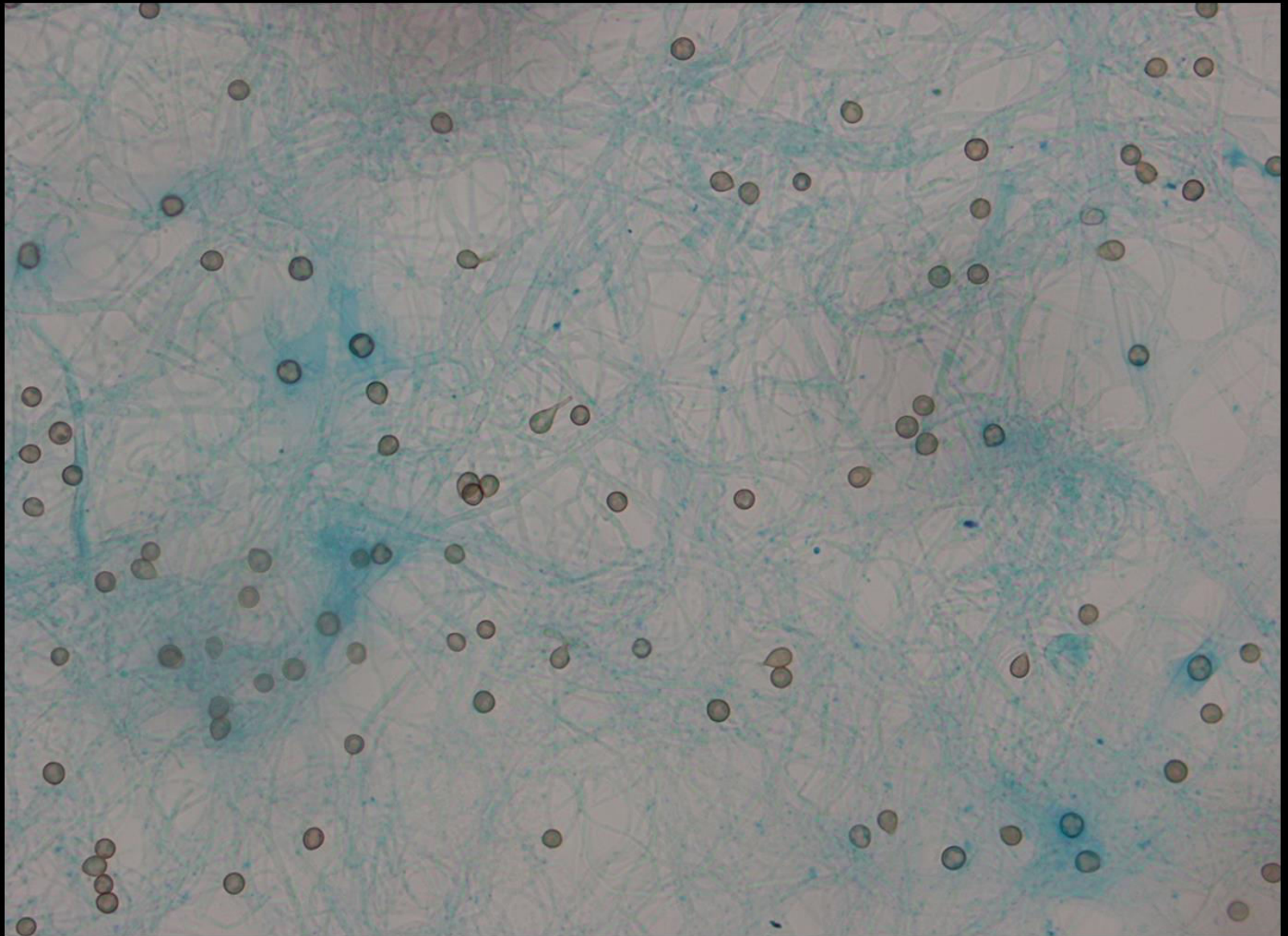


2- Mycetoma

Monosporium apiospermum

➤ **Microscopic morphology:**

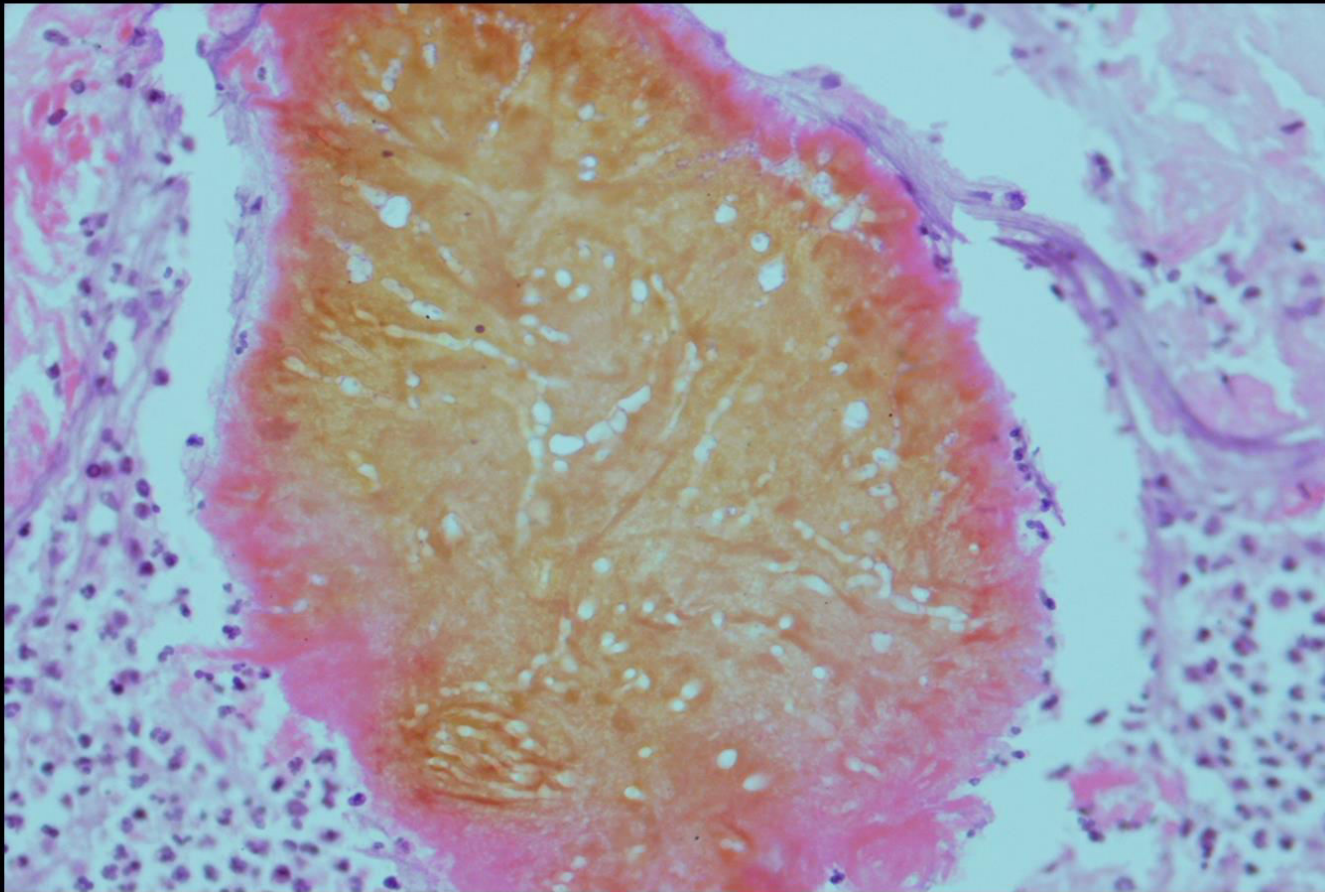
- Hyaline thin Septate hyphae
- Conidiophore short and thin (hardly to appear)
- Conidia is oval or rounded, singly on top of conidiophore but it look like as sitting on top of the hyphae



Laboratory Diagnosis

- **Specimen:** grains, biopsy tissue
- **Direct microscopic examination:** stain with HE stain (histology)
- **Culture:** on SDA.
- **Microscopic examination:** stain with LPCB will
- **Serology:** ID, CIE

Eumycotic grain



3- Phaeohyphomycosis

- it is a subcutaneous fungal infection caused by number of dematiaceous fungi.
- **Etiological agent:**
 - Cladosporium sp*
 - Ramichloridium mackenziei*

3- Phaeohyphomycosis

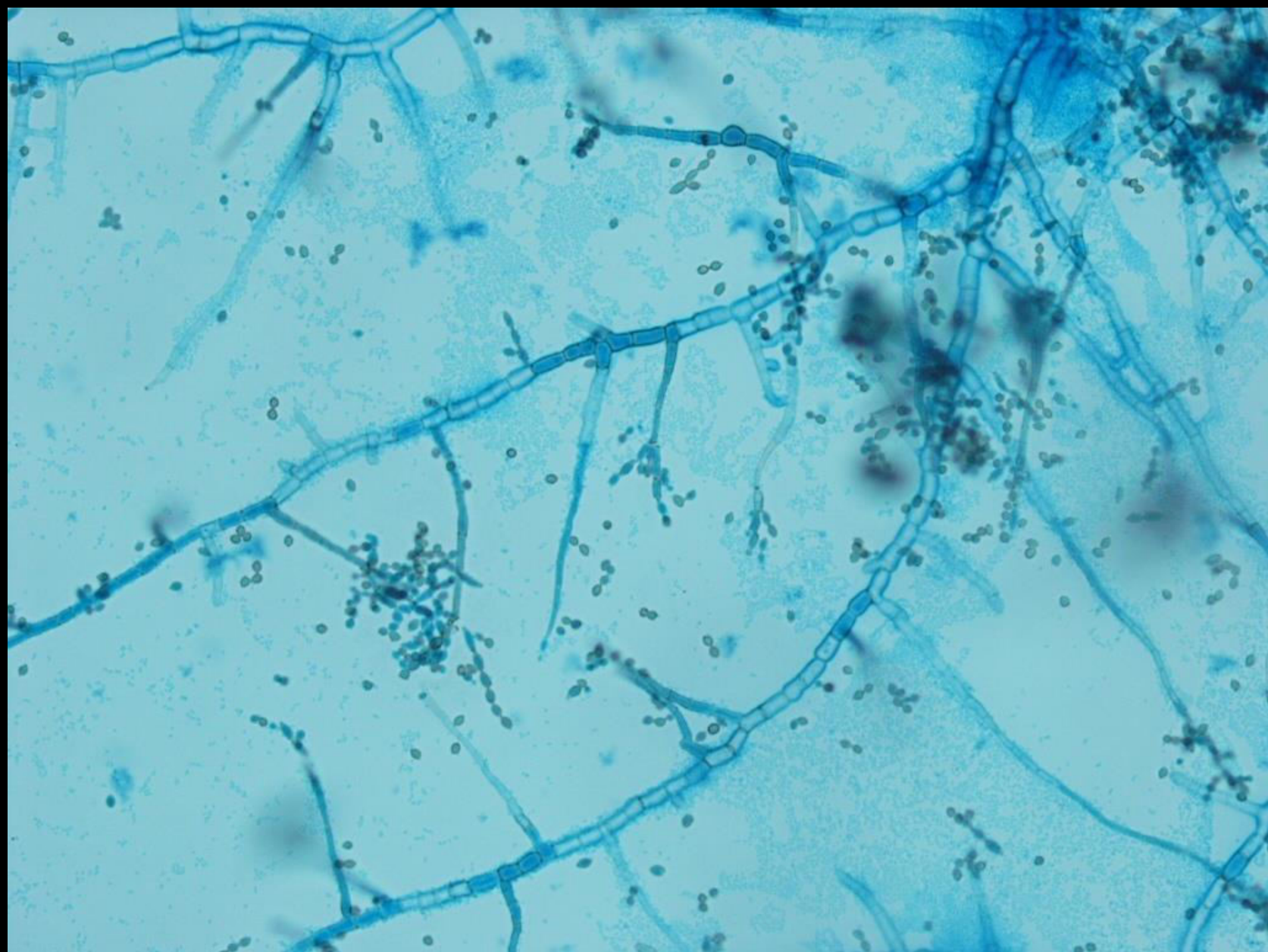
Cladosporium sp

➤ Colony morphology:

Velvety and darkly pigmented

➤ Microscopic morphology:

- Septate hyphae, thick wall and brown in color
- Conidiophor produce long, branching chains of elliptical conidia

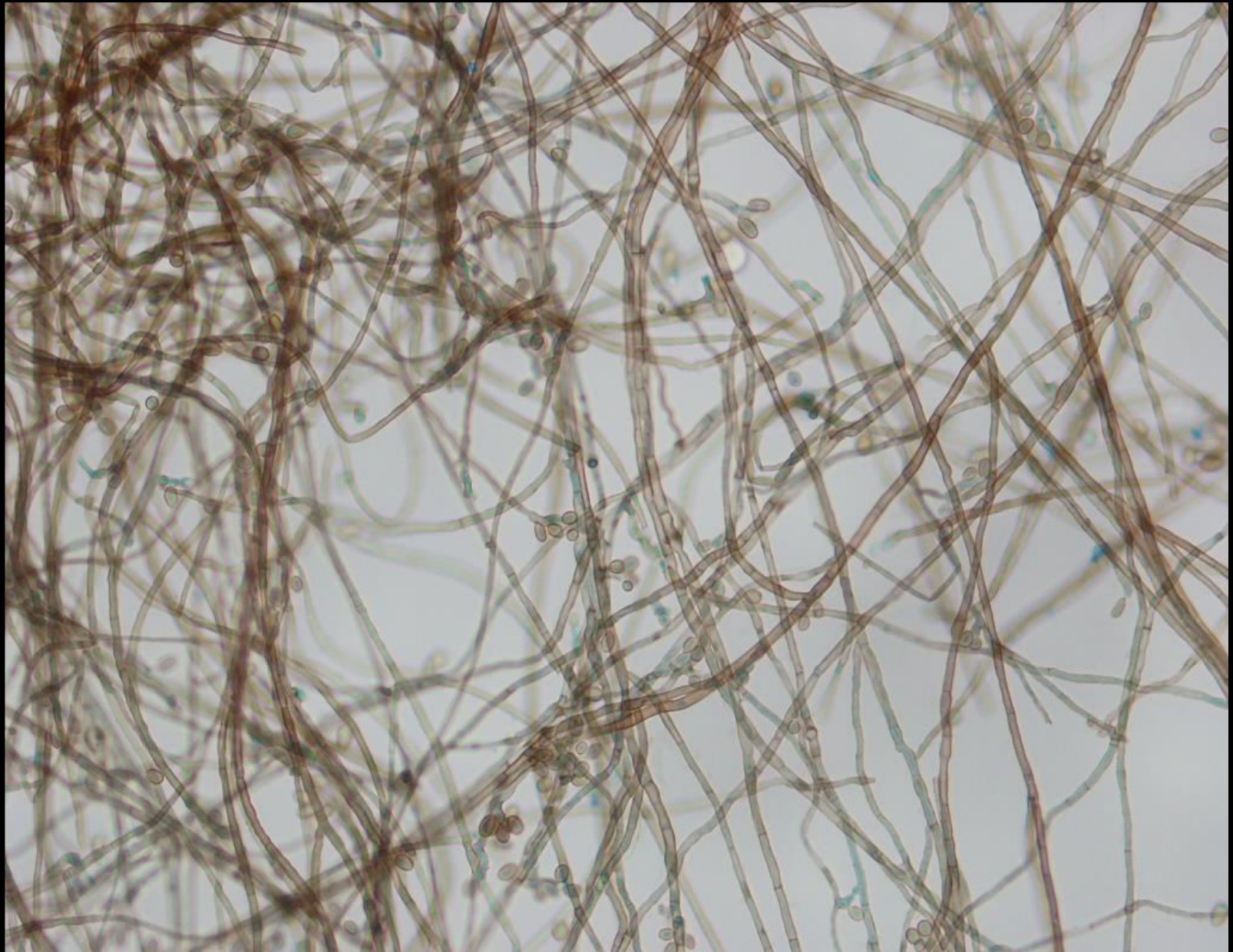


3- Phaeohyphomycosis

Ramichloridium mackenziei

➤ Microscopic morphology:

- Septate hyphae and brown in color
- Short or long conidiophore
- Conidia 4-6 at the tip of the conidiophore and it is brownish in color.



Laboratory Diagnosis

- **Specimen:** Biopsy tissue, pus
- **Direct microscopic examination:** stain with 10% KOH will show brown, septate hyphae
- Culture:** on SDA (very slow growing, black colonies).
- **Microscopic examination:** stain with LPCB.