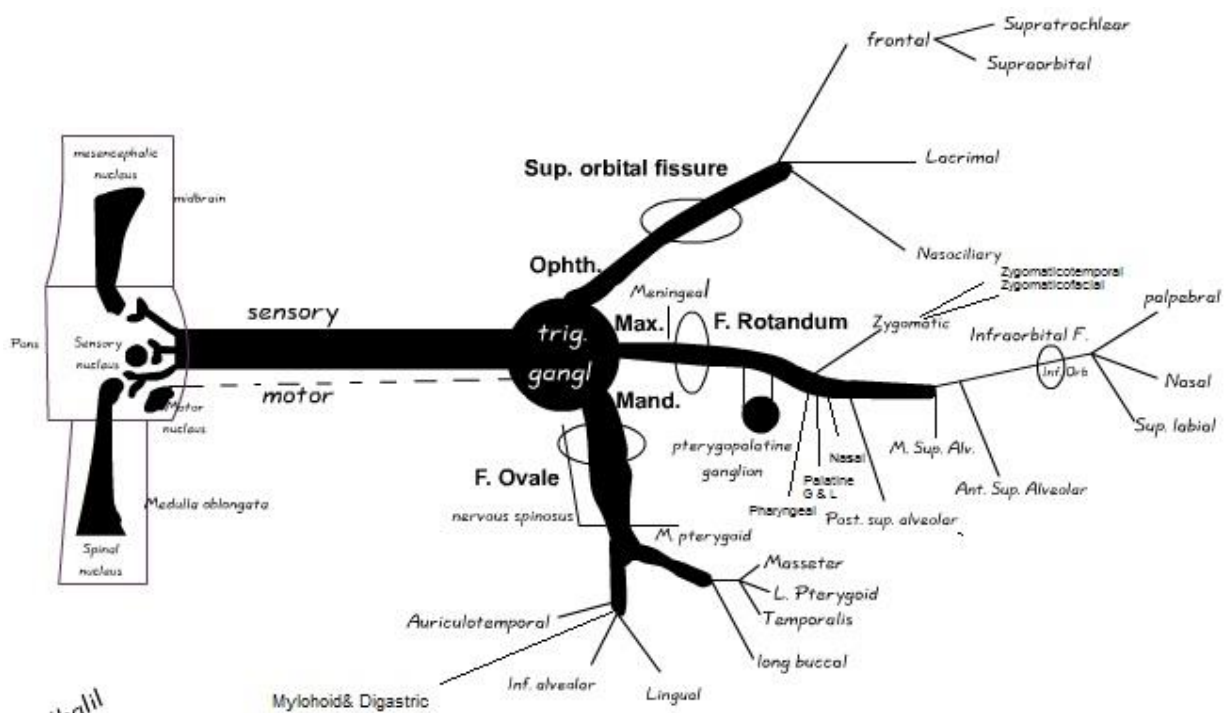


Clinic

Local Anesthesia (Anatomical Considerations)

- The **trigeminal** nerve: the largest cranial nerve
 - 1- Small motor root
 - 2- Large sensory root
- Branches
 - 1- Ophthalmic
 - 2- Maxillary
 - 3- Mandibular



H Khalil