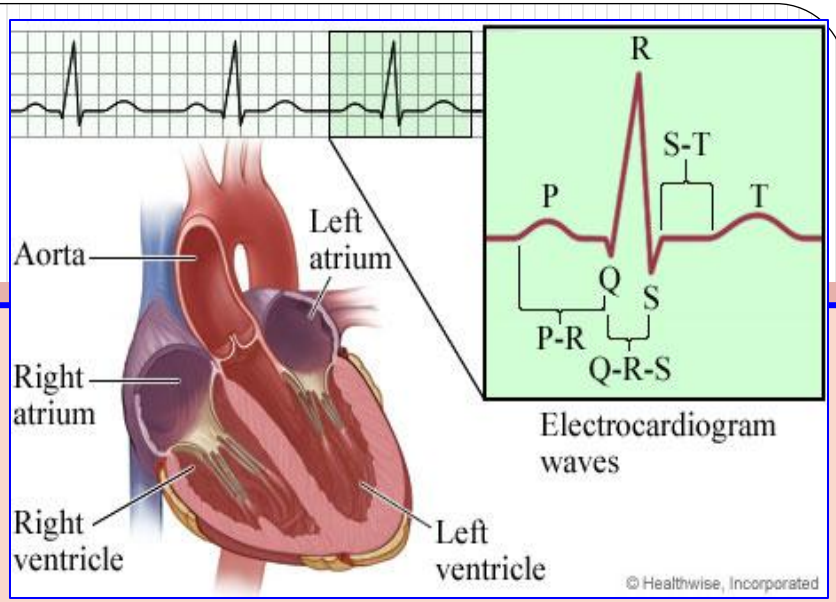

An Electrocardiogram (EKG/ECG)

Dr. Salwa El-Sayed

Assistant Prof. Medical Surgical Nursing

Objectives: by the end of this interactive lecture, the student will be able to

- Define An Electrocardiogram (EKG/ECG)
- Describe the indications and contraindications of performing ECG
- Describe the conductive system of the heart
- Describe normal ECG
- Describe pre, during, and post procedure care
- Identify the risk factors and factorss that interfere with ECG reading
- Describe the method of count heart rate
- Define Exercise Electrocardiography

Outlines:

- Definition of an Electrocardiogram (EKG/ECG)
- The indications and contraindications of performing ECG
- The conductive system of the heart
- Normal ECG
- Pre, during, and post procedure care
- The risk factors and factors that interfere with ECG reading
- The method of count heart rate
- Exercise Electrocardiography

An Electrocardiogram (EKG/ECG)

- An ECG is a quick, noninvasive method of assessing the heart's function.
- To measures the *electrical activity of the heart.*
- It is one of the simplest and fastest procedures used to evaluate the heart.
- It is a diagnostic tool that is routinely used to assess the electrical and muscular functions of the heart.
- The electrocardiogram can measure the rate and rhythm of the heartbeat, as well as provide indirect evidence of blood flow to the heart muscle.
- The electrocardiogram translates the heart's electrical activity into line tracings on paper.

Indications &

Contraindications

ECG

Indications for Performing ECG:

Some reasons for your doctor to request an ECG include, but are not limited to, the following:

- **To determine the cause of chest pain**
- **To evaluate other signs and symptoms which may be heart-related, such as fatigue, shortness of breath, dizziness, or fainting**
- **To identify irregular heartbeats (Cardiac arrhythmias)**

- **To determine the status of the heart prior to procedures such as surgery and/or after treatment for conditions such as a heart attack (myocardial infarction, MI), endocarditis (inflammation or infection of one or more of the heart valves), or after procedures such as heart surgery or cardiac catheterization.**
- To assess the function of an **implanted pacemaker**
- To determine the effectiveness of **certain heart medications**

Contraindications

- **No absolute contraindications** to performing an electrocardiogram,
- Patient refusal, exist.
- Some patients may have allergies, or more commonly, sensitivities to the adhesive used to affix the leads; ---in these cases, **hypoallergenic alternatives are available from various manufacturers.**

Conductive System

of the heart

Cardiac conduction system:

is the rate at which the heart conducts electrical impulses.

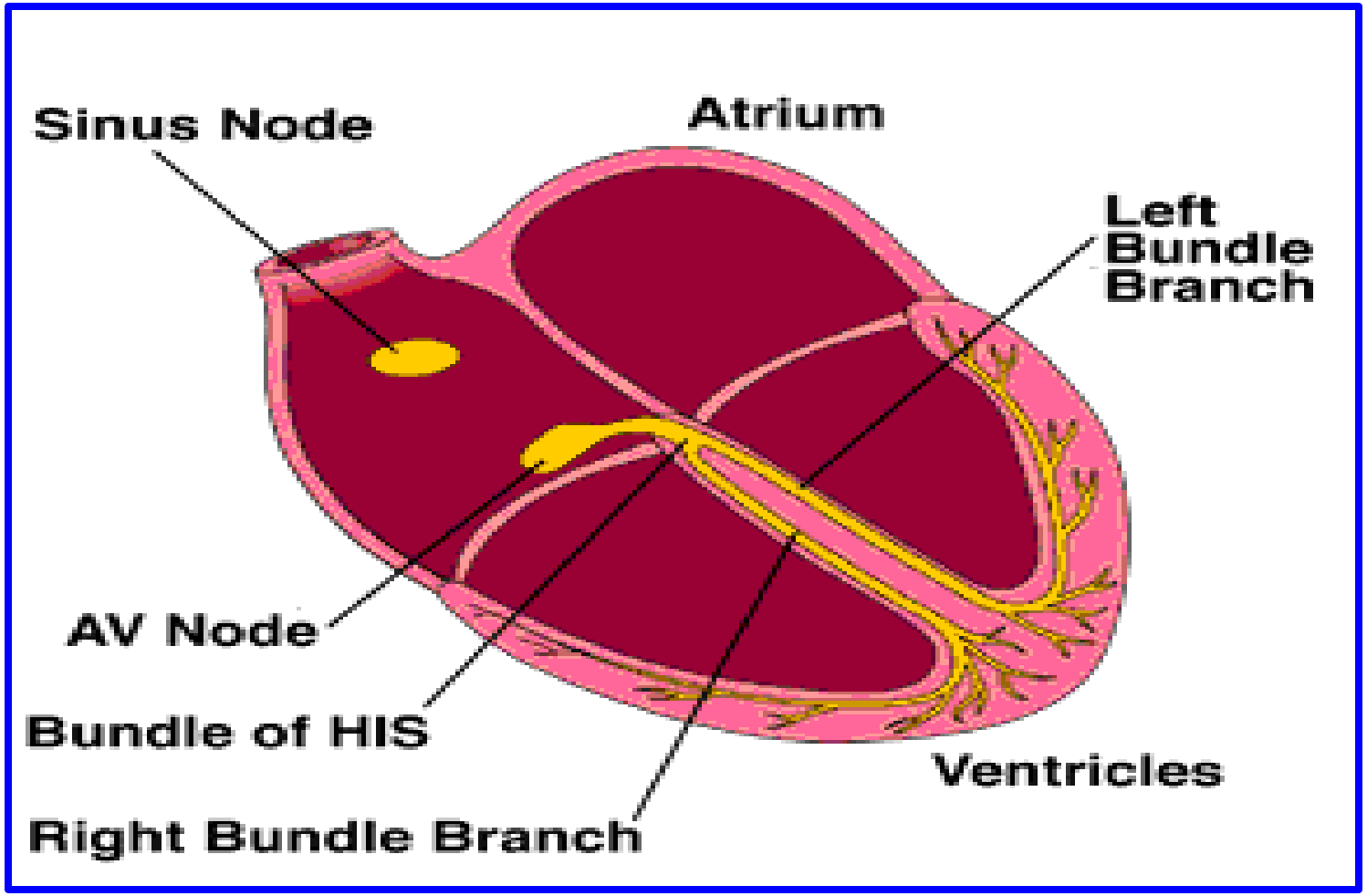

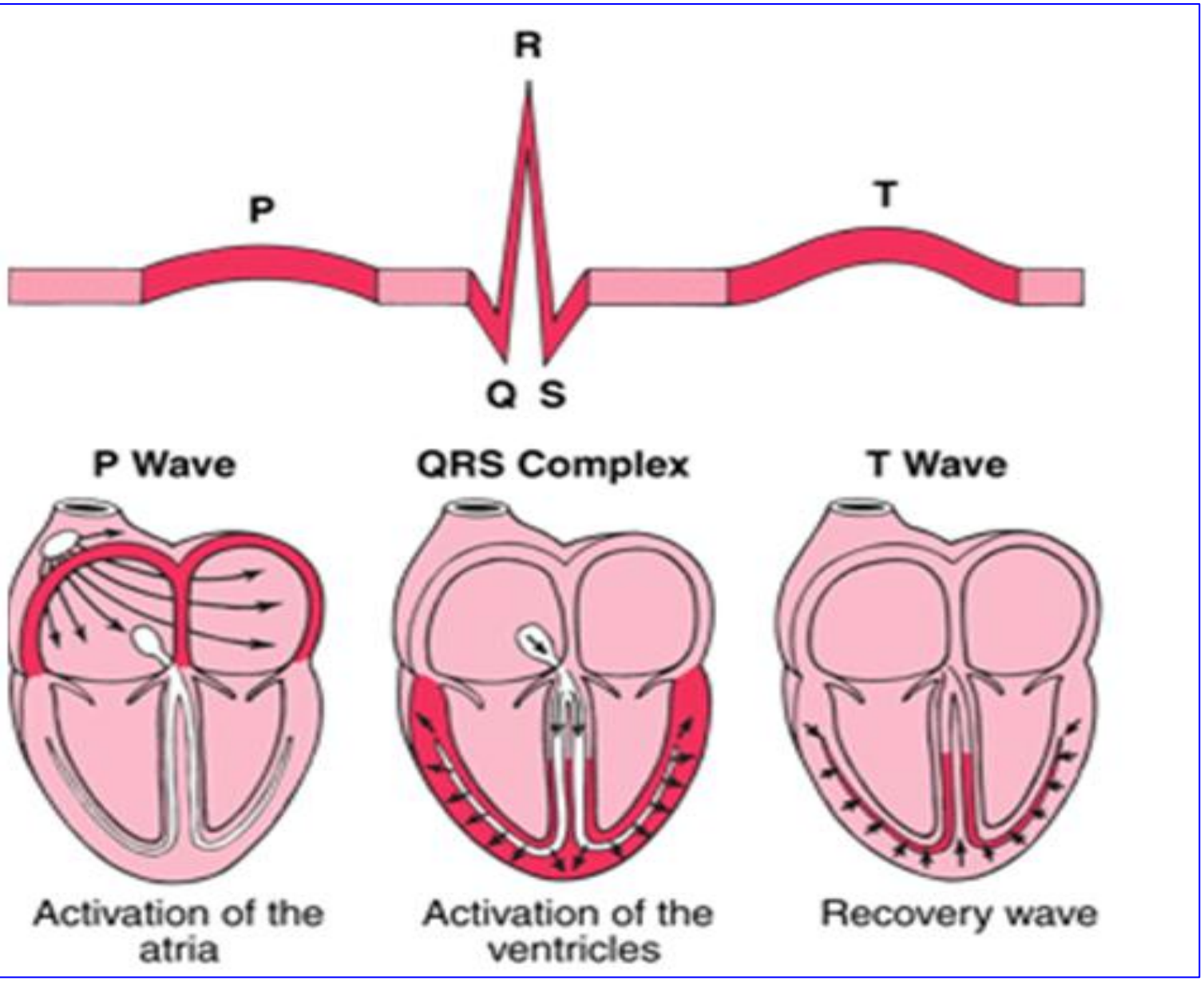
R
P
T
Q S
P Wave
QRS Complex
T Wave
Activation of the atria
Activation of the ventricles
Recovery wave

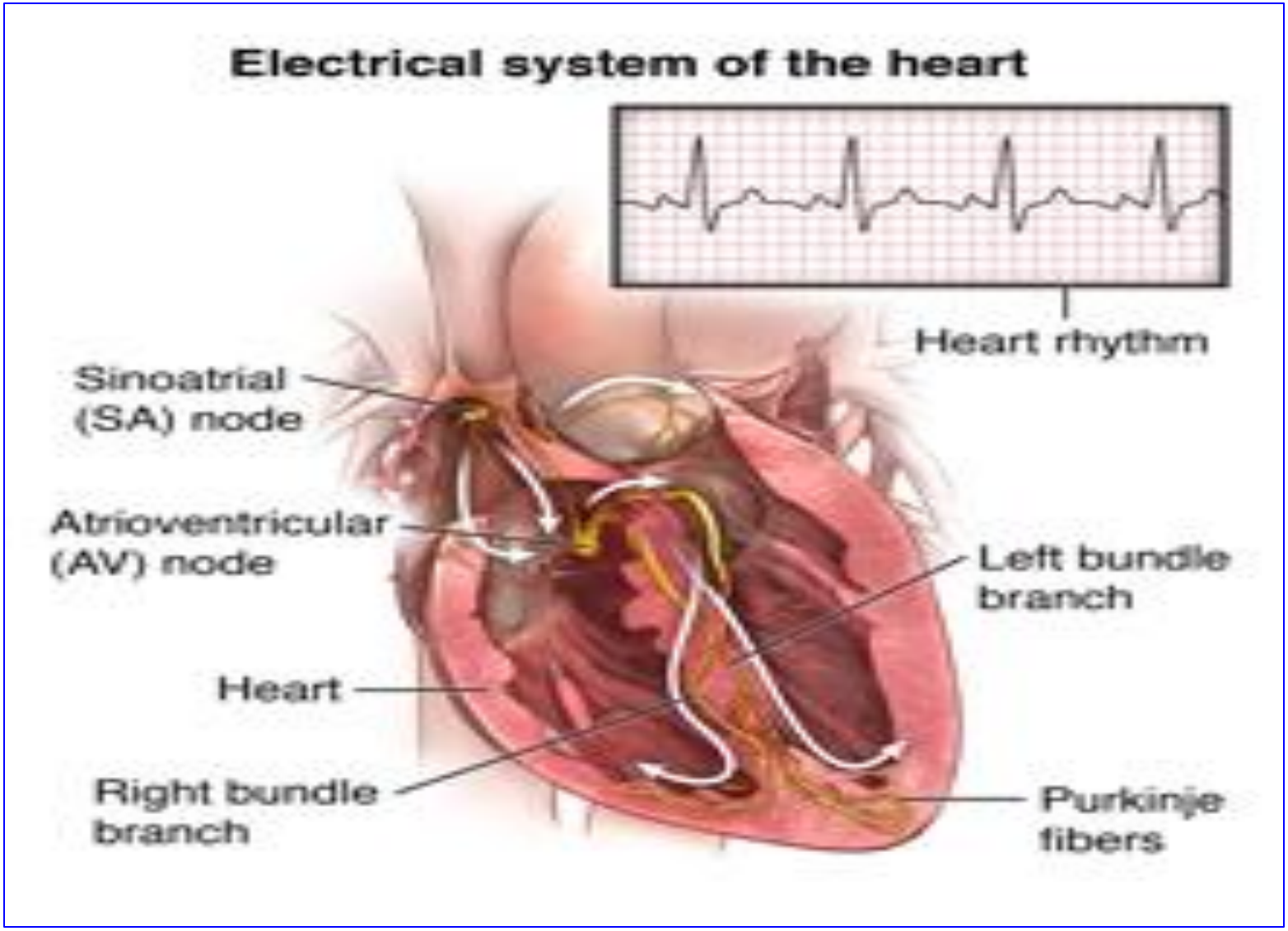
Electrical system of the heart
Heart rhythm
Sinoatrial (SA) node
Atrioventricular (AV) node
Left bundle branch
Heart
Right bundle branch
Purkinje fibers

Conduction System Structures and Functions

Structures	Functions & location
Sinoatrial (SA) node	Dominant pacemaker of the heart, located in upper portion of right atrium. **Intrinsic rate 60–100 b/m**
Internodal pathways	Direct electrical impulses between SA and AV nodes
Atrioventricular (AV) node	Part of AV junctional tissue. Slows conduction, creating a slight delay before impulses reach ventricles. **Intrinsic rate 40–60 b/m.**
Bundle of His	Transmits impulses to bundle branches. Located below AV node

Structures	Functions & location
Left bundle branch	Conducts impulses that lead to left ventricle.
Right bundle branch	Conducts impulses that lead to right ventricle.
Purkinje system	Network of fibers that spreads impulses rapidly throughout ventricular walls Located at terminals of bundle branches. Intrinsic rate 20–40 b/m.

Normal

ECG

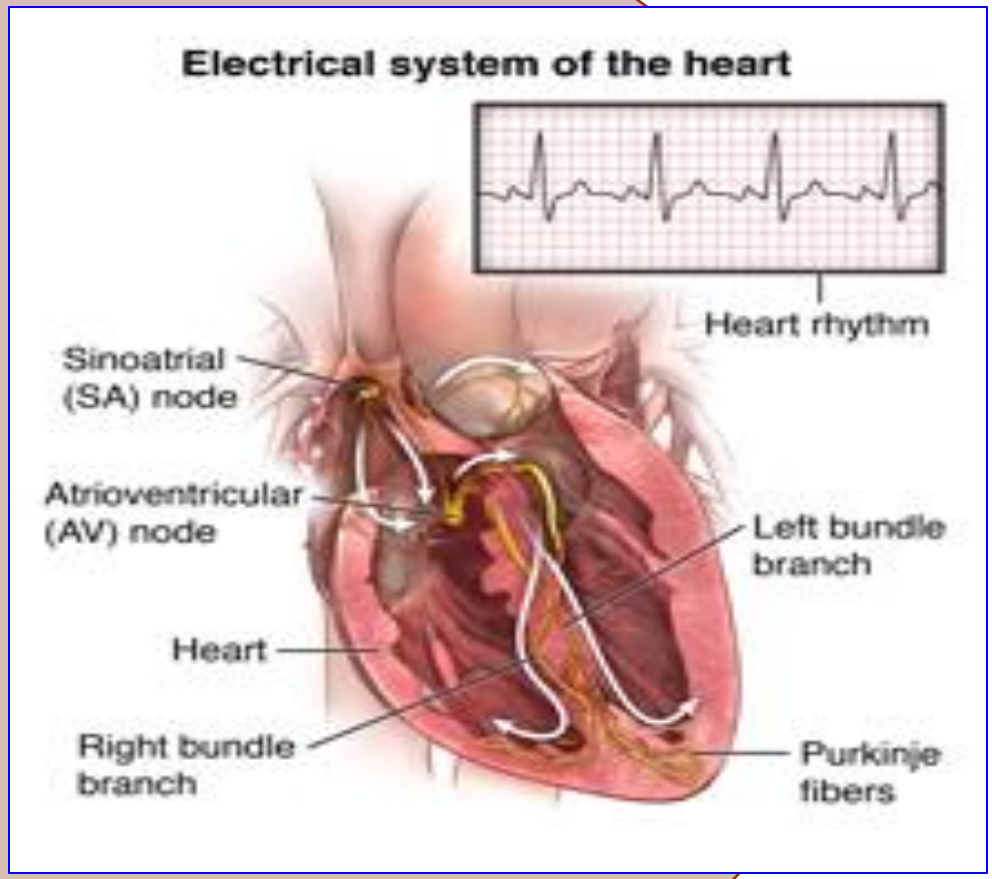
Electrical system of the heart
Heart rhythm
Sinoatrial (SA) node
Atrioventricular (AV) node
Left bundle branch
Heart
Right bundle branch
Purkinje fibers

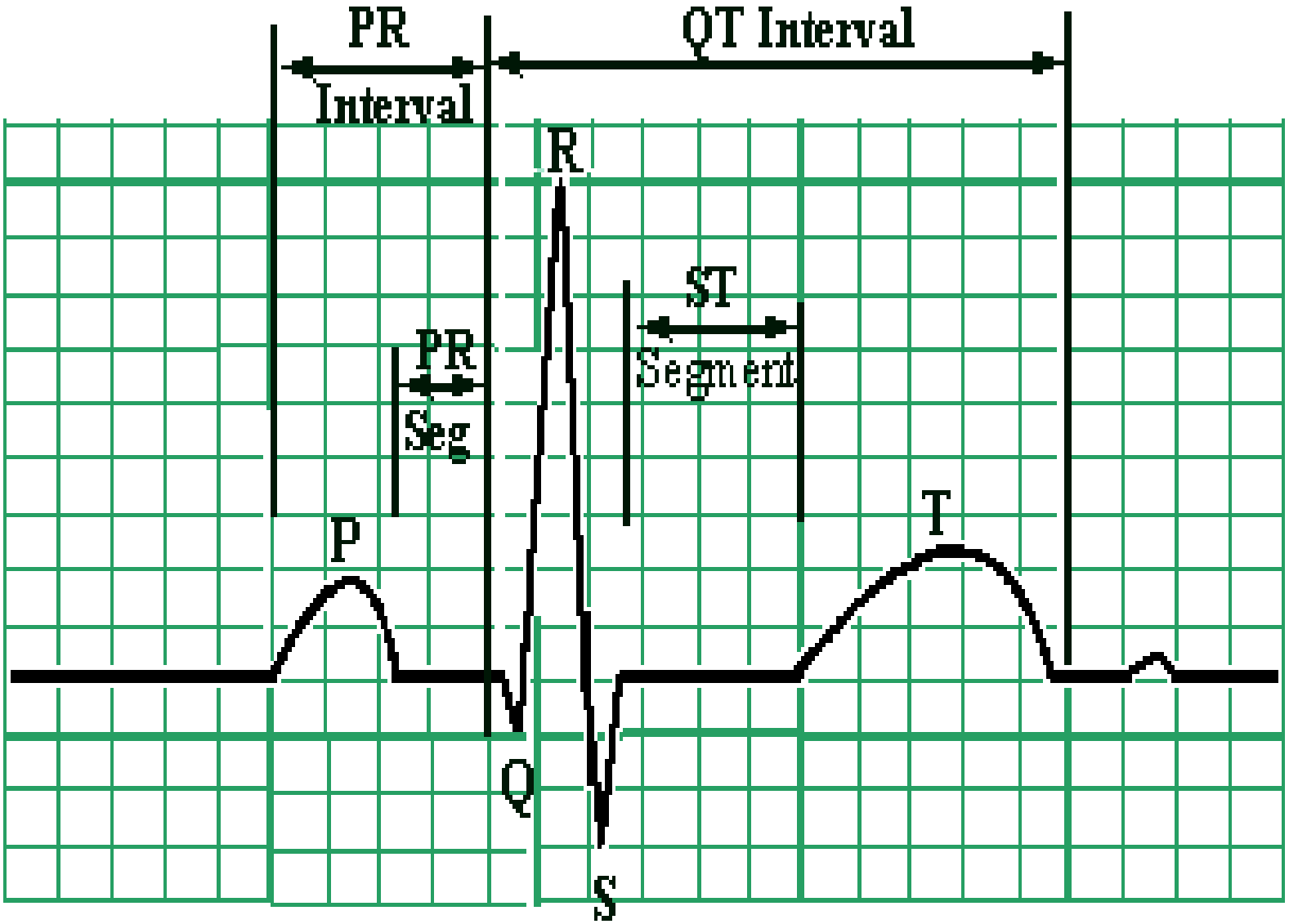
PR
Interval
QT Interval
R
ST
Segment
PR
Seg
P
T
Q
S

Normal Rhythm “ECG”

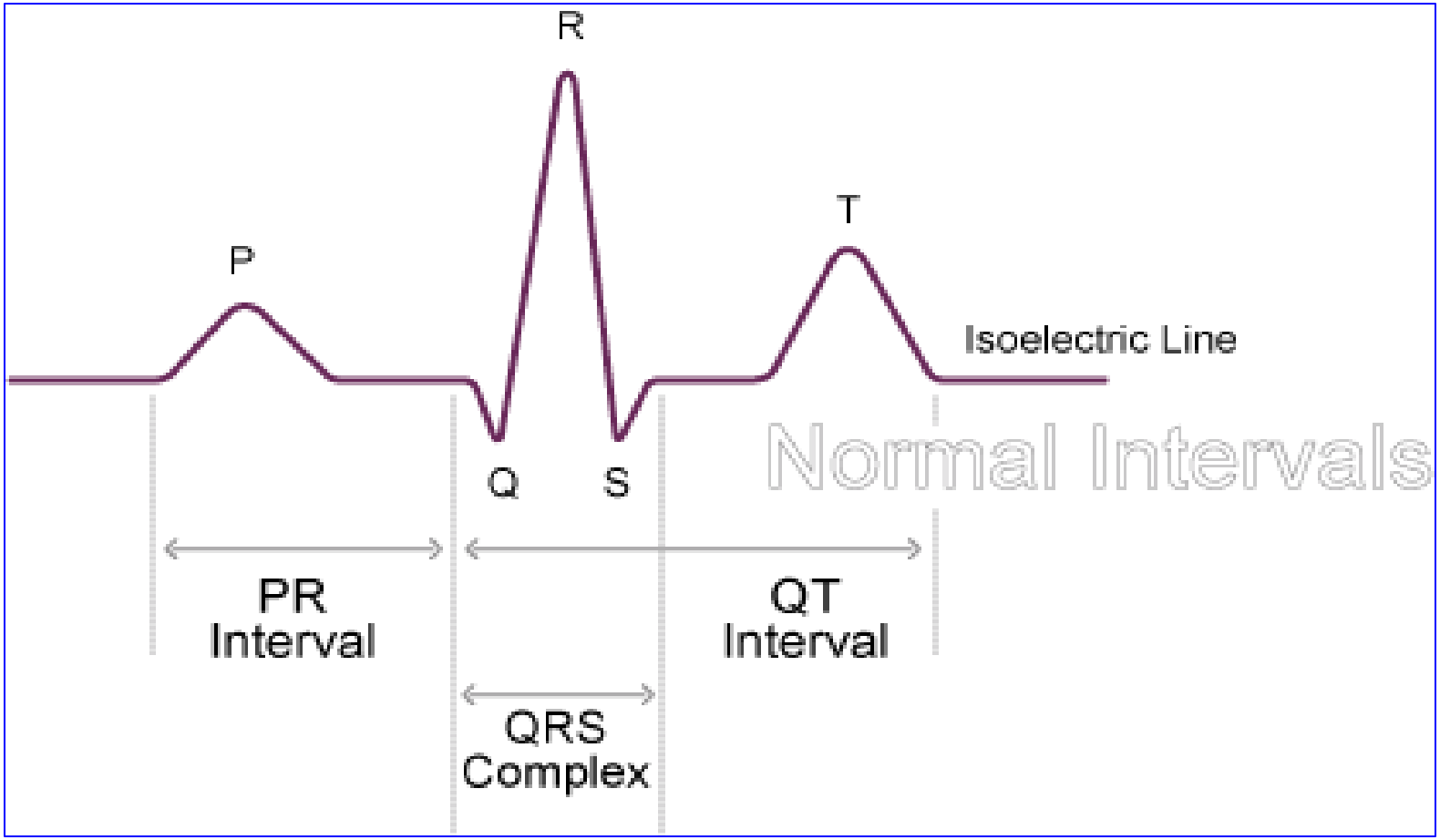

What is the isoelectric line?

Electrical Components

Deflection	Description
P Wave	Small rounded, **upright (positive)** wave indicating atrial depolarization (contraction)
QRS Interval	Distance between beginning of **P wave and beginning of QRS complex** Measures time during which a depolarization wave travels from the atria to the ventricles
ST Segment	Three deflections following P wave Indicates ventricular depolarization (contraction) - Q Wave: First negative deflection - R Wave: First positive deflection - S Wave: First negative deflection after R wave

Deflection	Description
T Wave	Rounded upright (positive) wave following QRS - Represents ventricular repolarization
QT Interval	- Measured from beginning of QRS to end of T wave. - Represents total ventricular activity.
U Wave	Small rounded, upright wave following T wave - Most easily seen with a slow HR. - Represents repolarization of Purkinje fibers.

ECG –Clinical Lead Groups

I Lateral	aVR Lateral	V1 Septal	V4 anterior
II Inferior	aVL Lateral	V2 Septal	V5 Lateral
III Inferior	aVF Inferior	V3 anterior	V6 Lateral

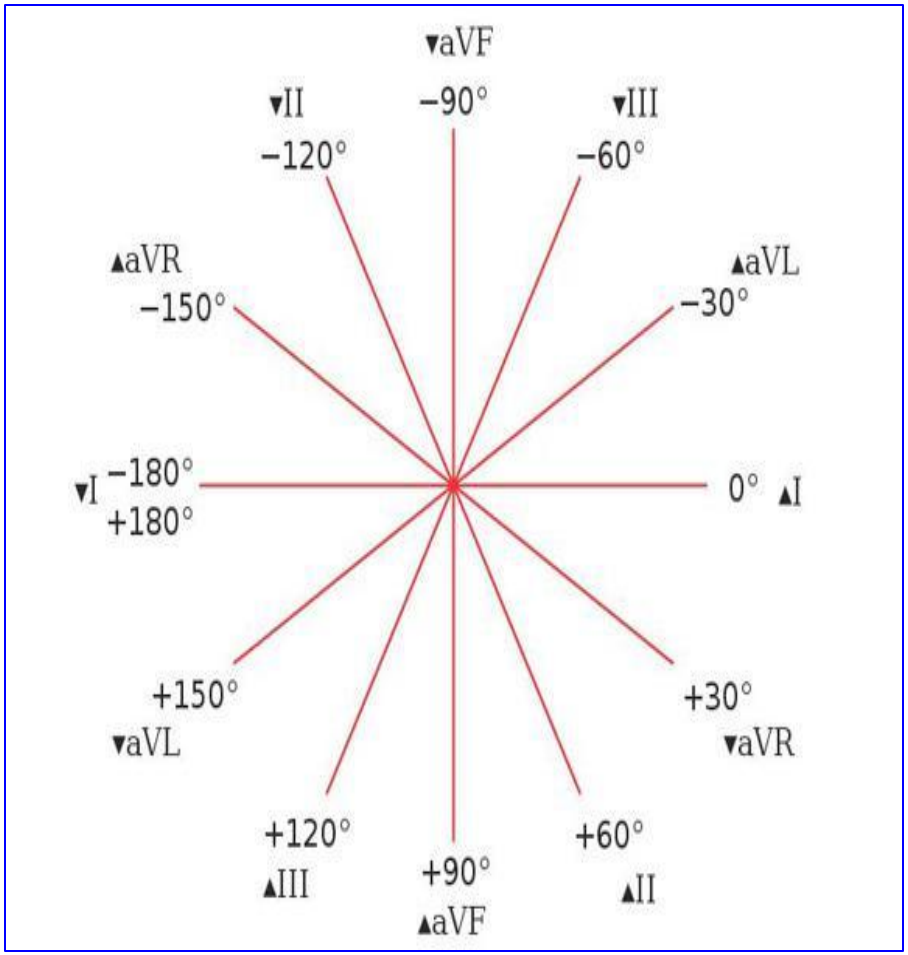
▼aVF
−90°
▼II
−120°
▼III
−60°
▲aVR
−150°
▲aVL
−30°
▼I
−180°
+180°
0°
▲I
+150°
▼aVL
+30°
▼aVR
+120°
▲III
+90°
▲aVF
+60°
▲II

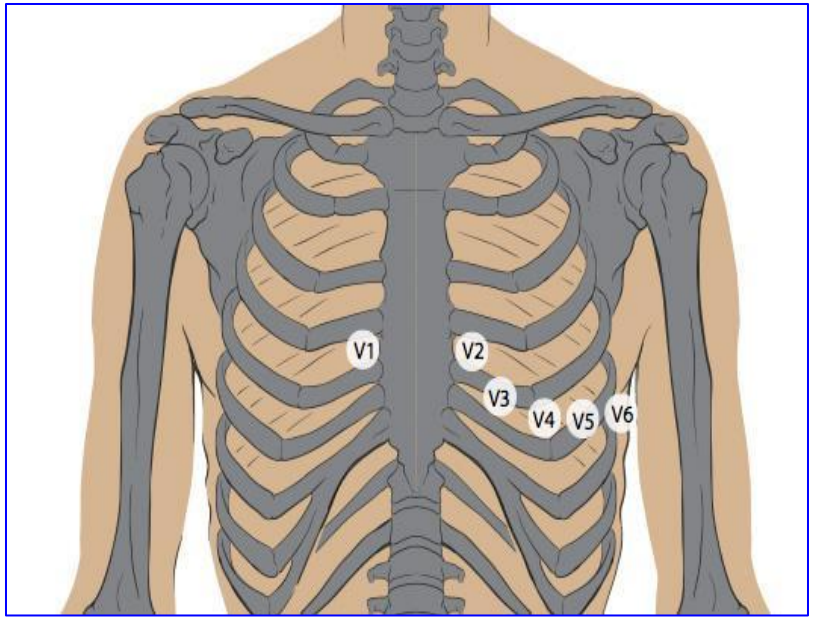
V1
V2
V3
V4
V5
V6

Method for determining heart rate

- Count the number of QRS complexes over a 6 second interval.
- Multiply by 10 to determine heart rate.
- This method works well for both regular and irregular rhythms.
- Count 6 QRS complexes, so the heart rate is 60.

Normal ---12 Leads ECG

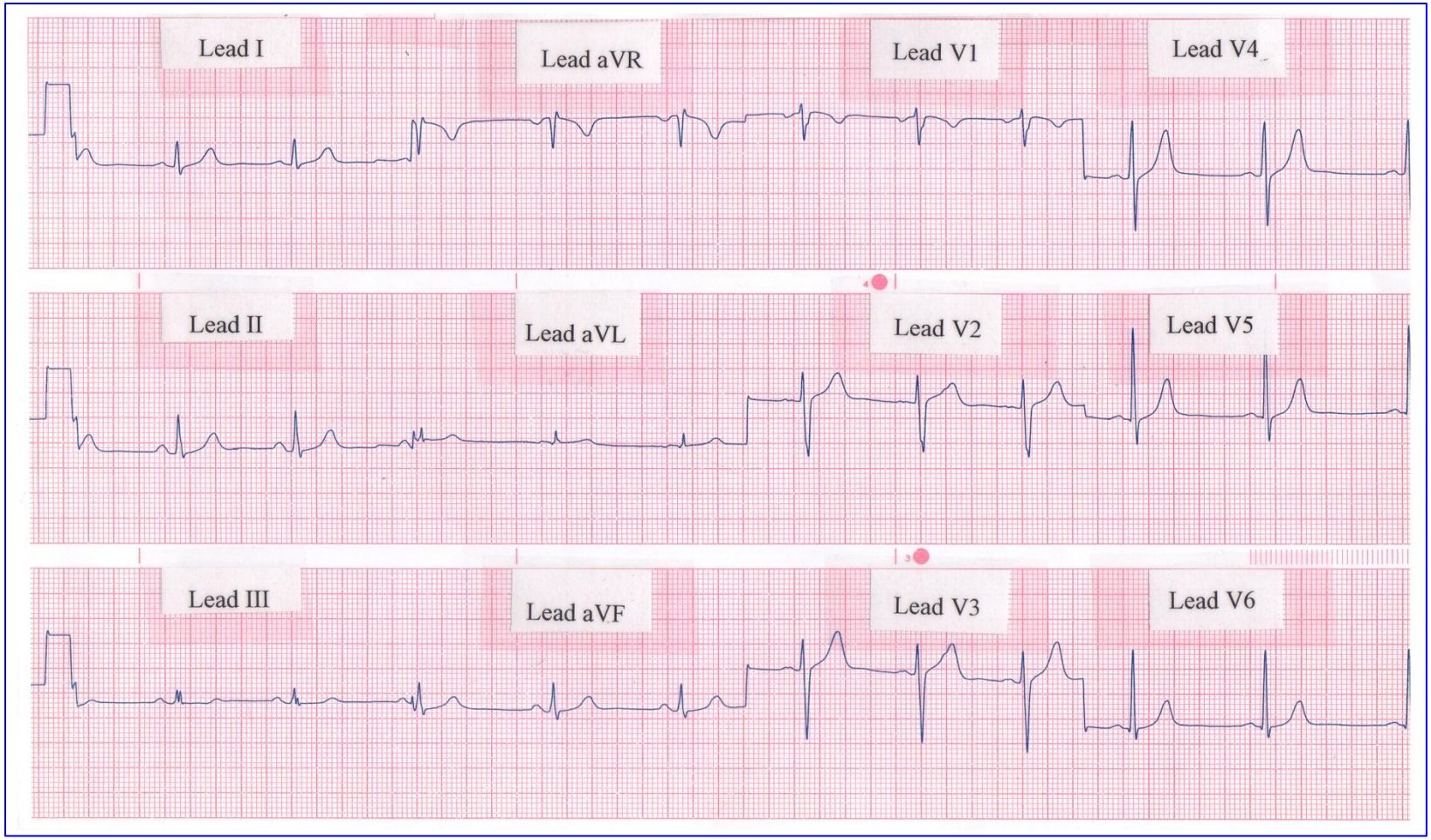

Pre-procedures

ECG

Risks of the Procedure

- Risks associated with ECG are minimal and rare.
- Prolonged application of the adhesive electrode patches may cause tissue breakdown or skin irritation at the application site.
- Be sure to discuss any concerns with your doctor prior to the procedure.

Pre the procedure:

- **Explain the procedure to you and offer you the opportunity to ask any questions that you might have about the procedure.** It will be important for you to lie still and not talk during the procedure, so as not to interfere with the tracing.

- **Notify doctor if you have a pacemaker, Over counter medications.**

- remove any jewelry or other objects that may interfere with the procedure.
- remove clothing from the waist up. The technician will ensure your privacy by covering you with a sheet or gown and exposing only the necessary skin.

During the procedure

- If your chest, arms, or legs are very hairy, the technician may shave or clip small patches of hair, as needed, so that the electrodes will stick closely to the skin.

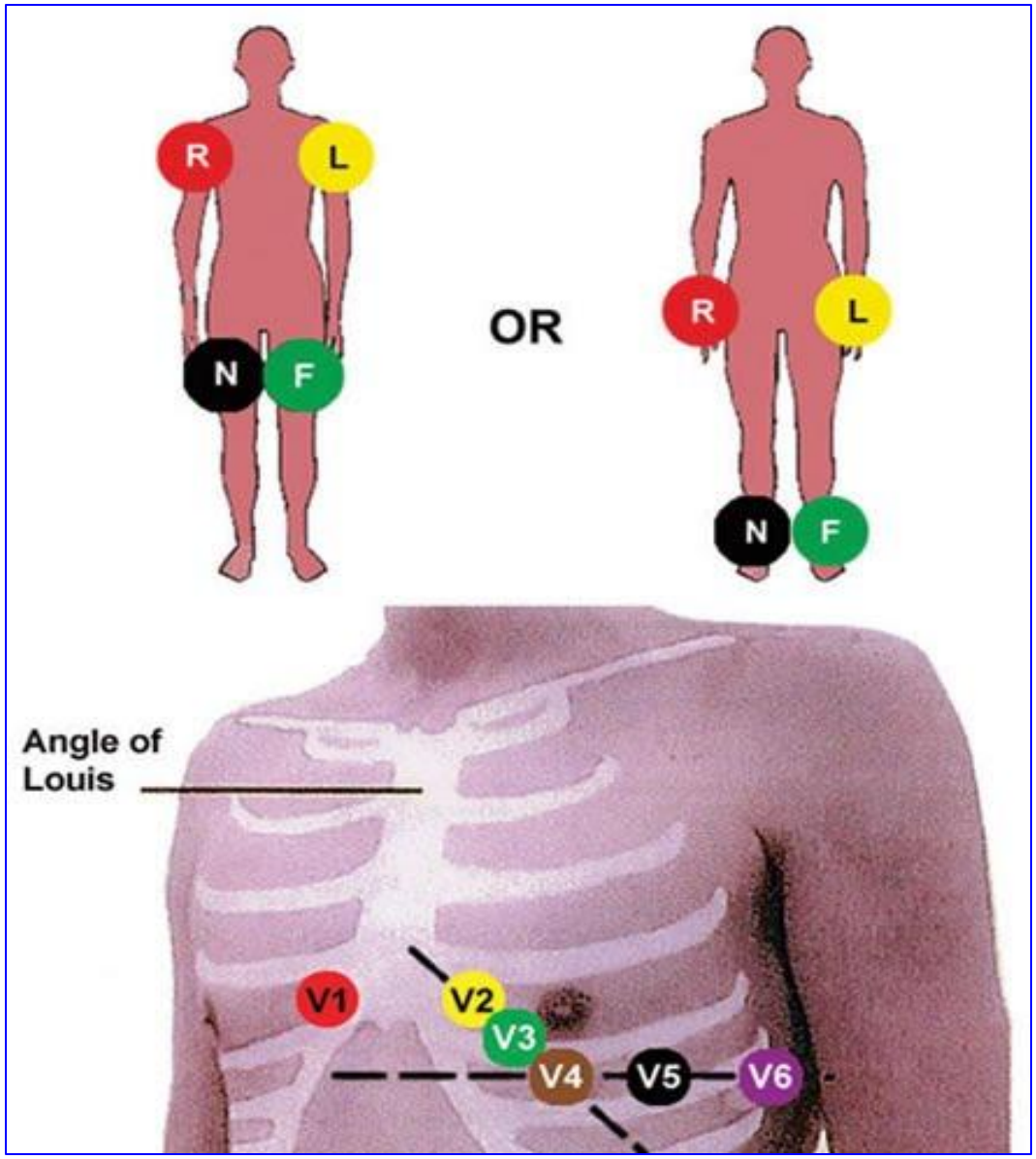
R
L
N
F
OR
R
L
N
F
Angle of Louis
V1
V2
V3
V4
V5
V6

CONTEC
ECG100G

UNICARE
CE ISO 13485

Post-procedures

ECG

Post the procedure

- The patient able to resume your normal diet and activities, unless your doctor instructs you differently.
- There is no special care following an ECG.
- The patient should notify the doctor if he develop any signs or symptoms you had prior to the test (for example, chest pain, shortness of breath, dizziness, or fainting).

Factors or conditions may interfere with or affect the results of the test

1. Obesity, pregnancy, or ascites (accumulation of fluid in the abdomen)
2. Anatomical considerations, such as the size of the chest and the location of the heart within the chest
3. Movement during the procedure
4. Exercise or smoking prior to the procedure
5. Certain medications
6. Electrolyte abnormalities, such as too much or too little potassium, magnesium, and/or calcium in the blood

Exercises

ECG

Exercise Electrocardiography

- An outpatient procedure to assess patients at risk for the presence of coronary artery disease.

- It is common practice to perform a low-level exercise test before hospital discharge after acute MI to identify patients at risk for ischemic events and to determine exercise prescription.

Good Luck with Best Wishes

Dr. Salwa El-Sayed