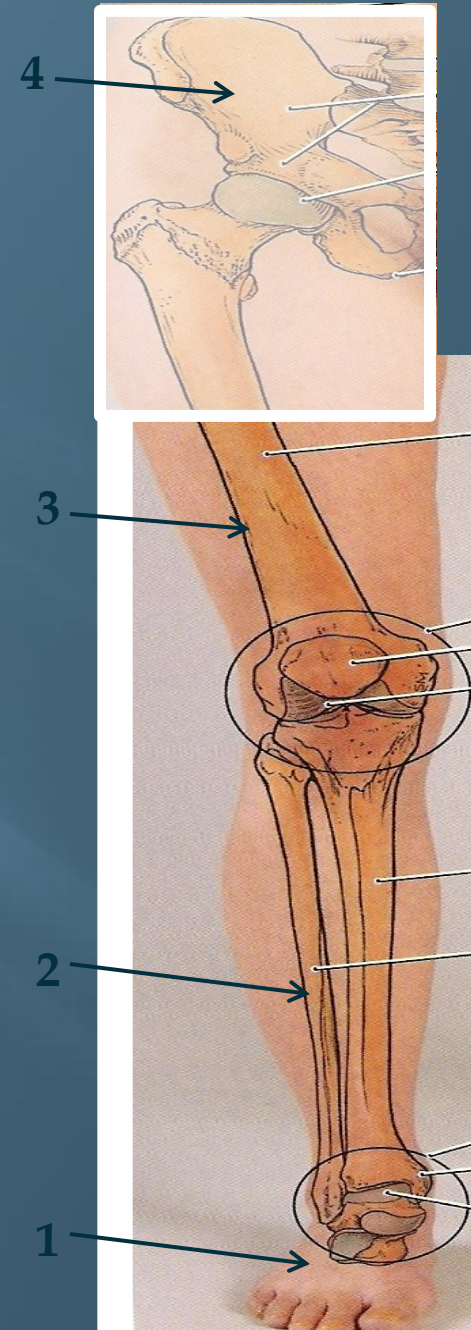


Lower Limb

Lower limb

The bones of the Lower limb are divided into 4 groups :

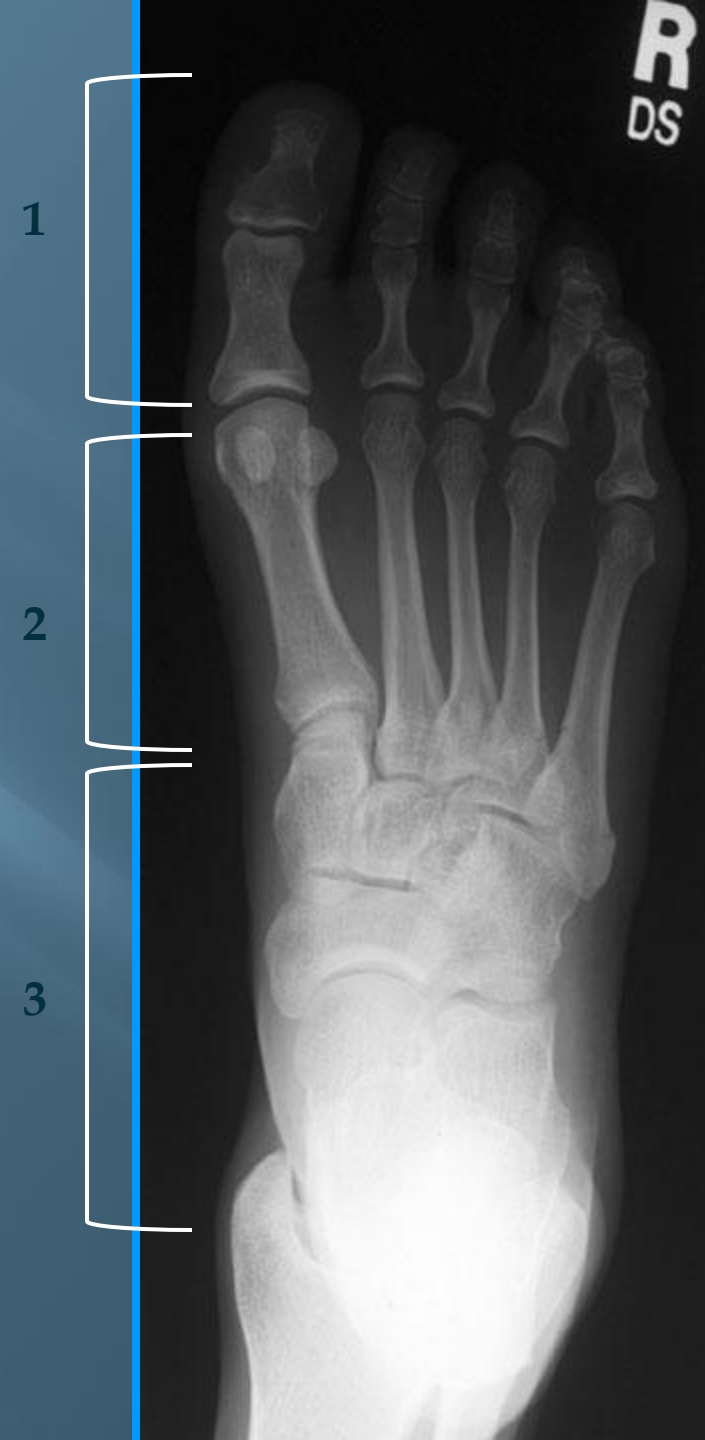1. The foot .
2. Leg .
3. Femur .
4. Hip .



1 – The Foot

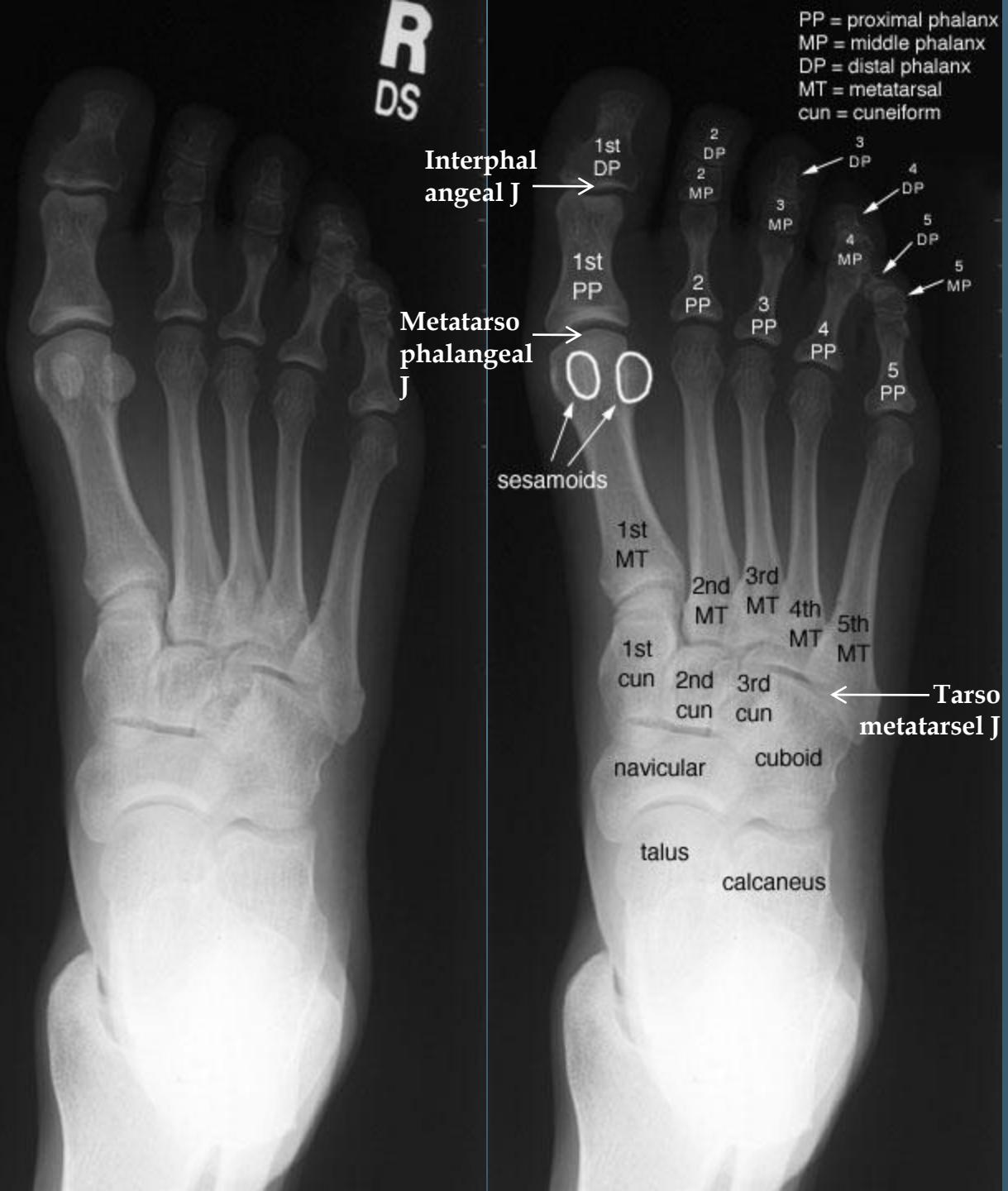
There are 26 bones of one Foot divided into 3 groups :

1. Phalanges (toes / digits)	14
2. Metatarsals	5
3. Tarsals	7
	<hr/>
Total	26



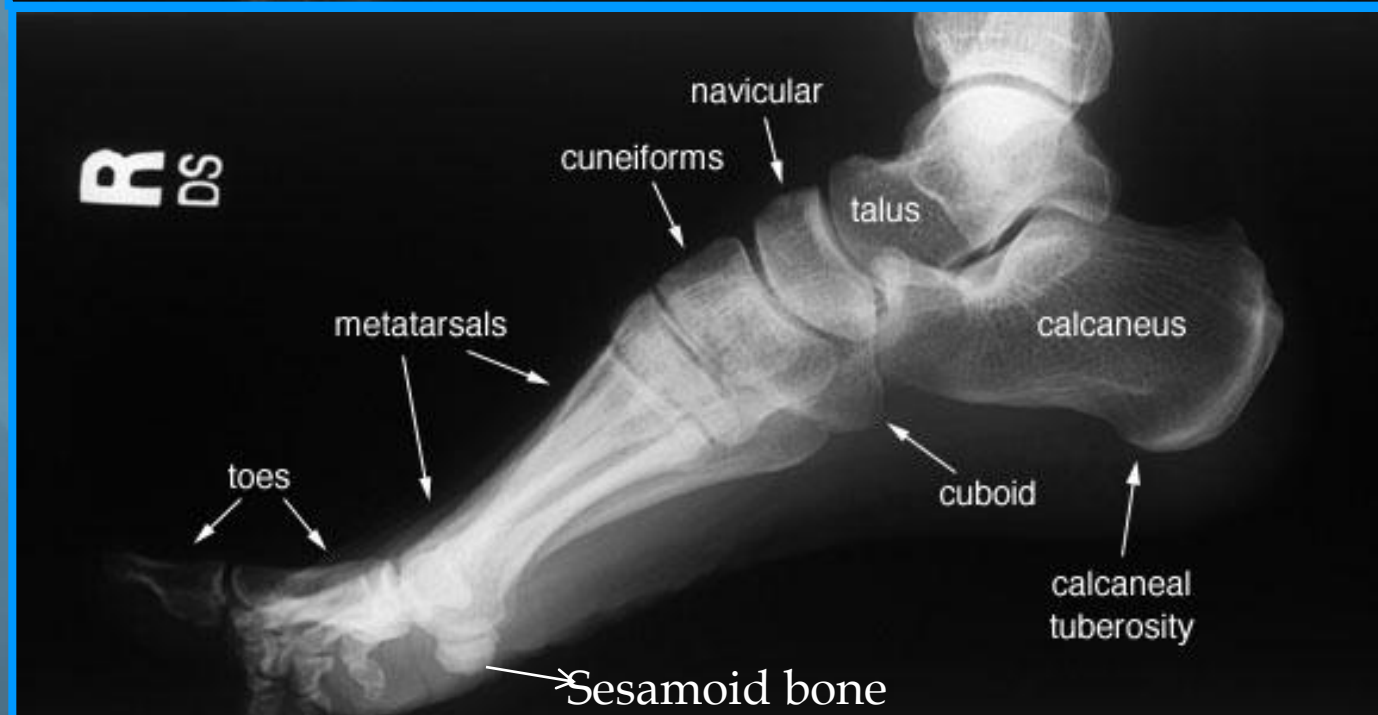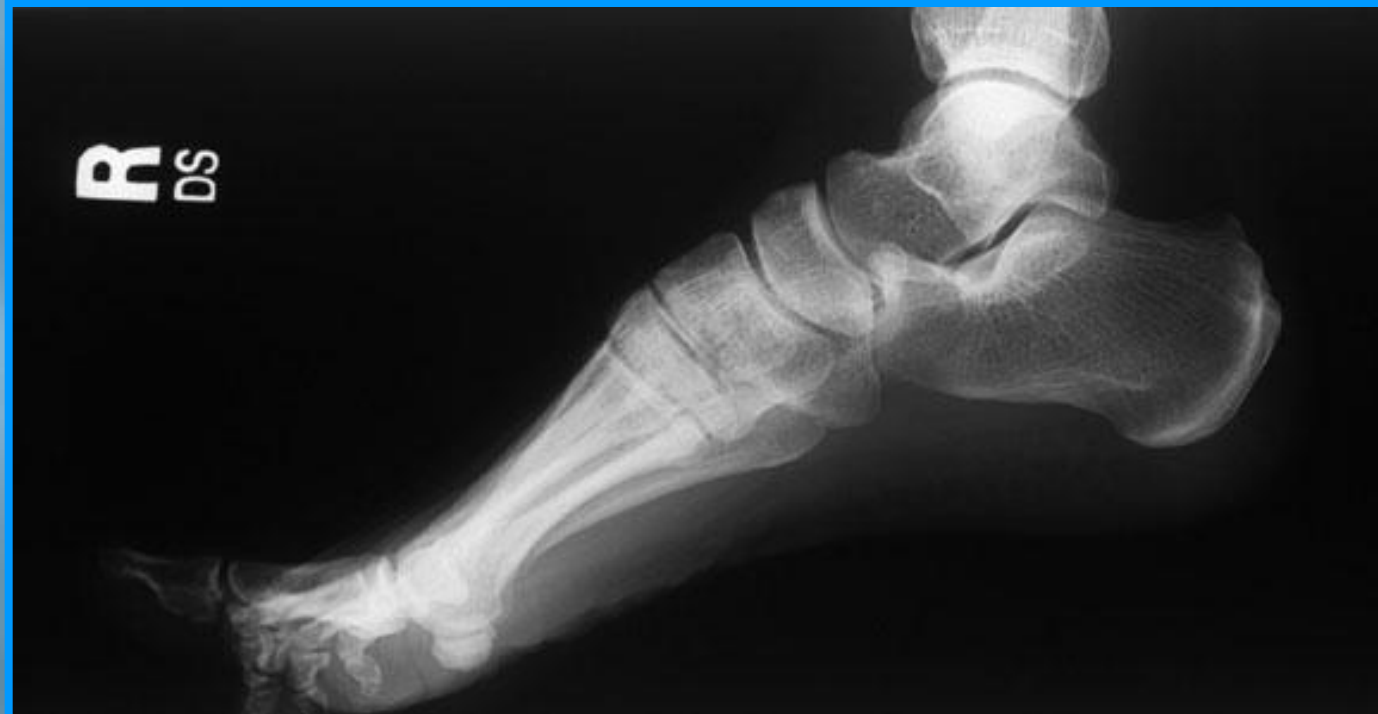Foot

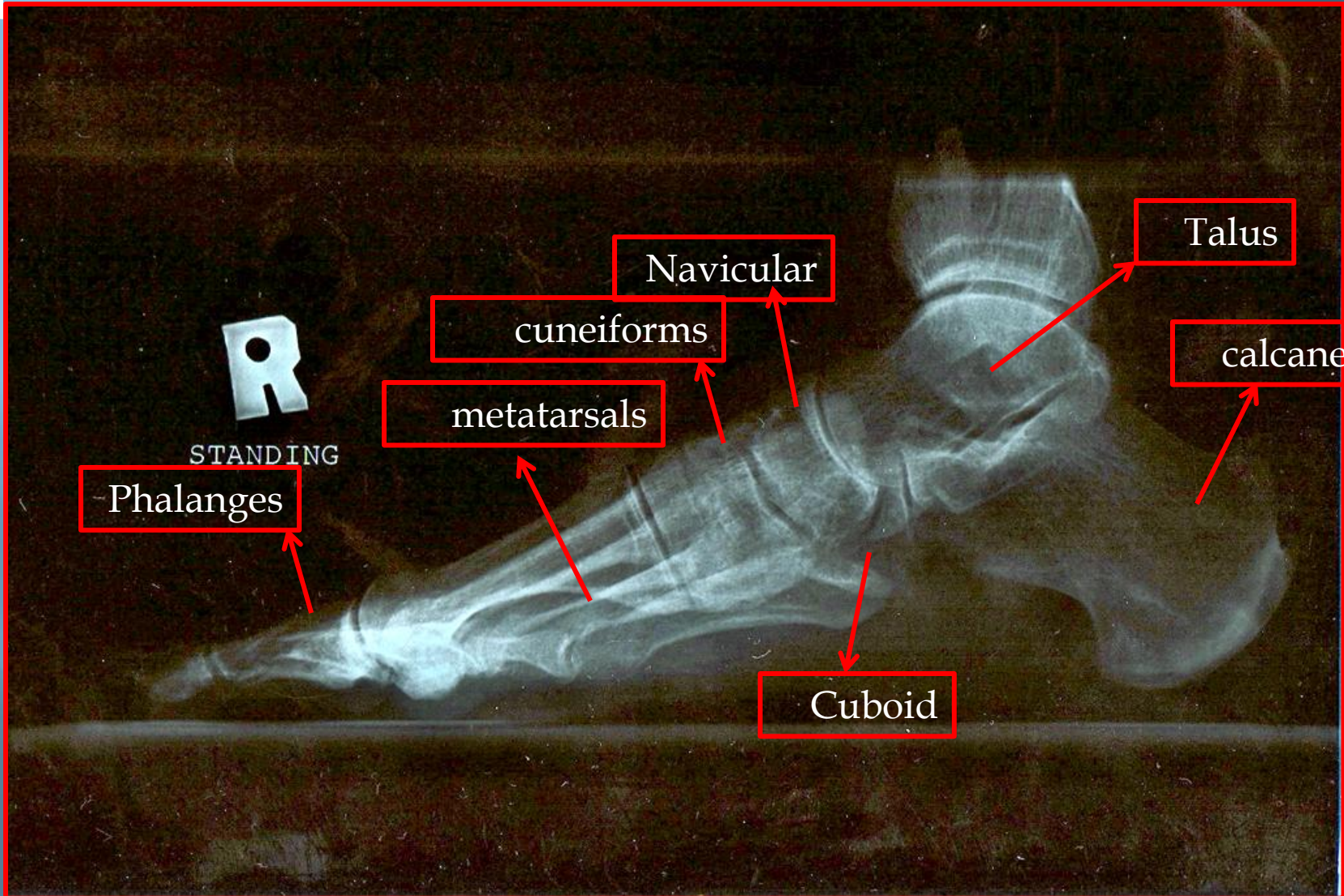
AP view



Foot

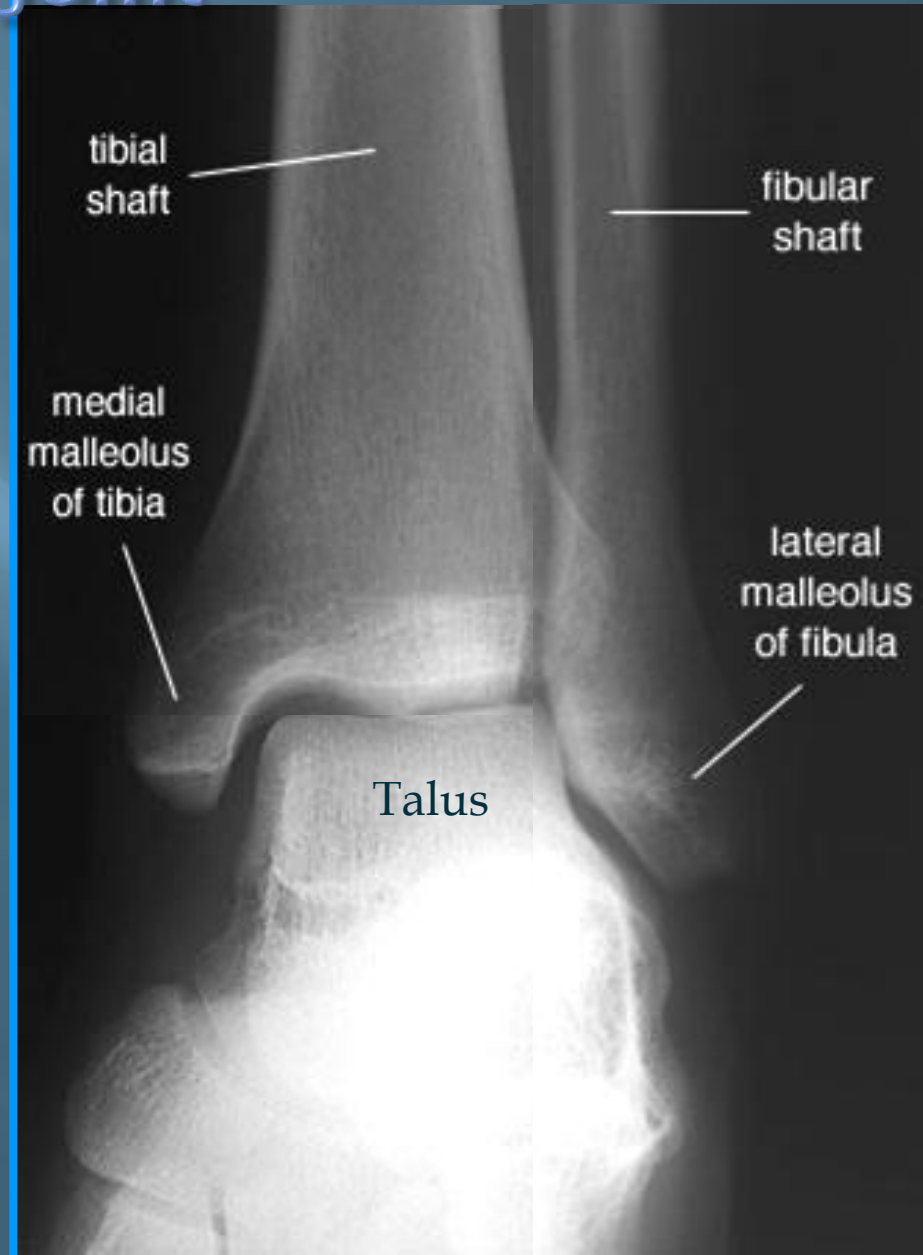
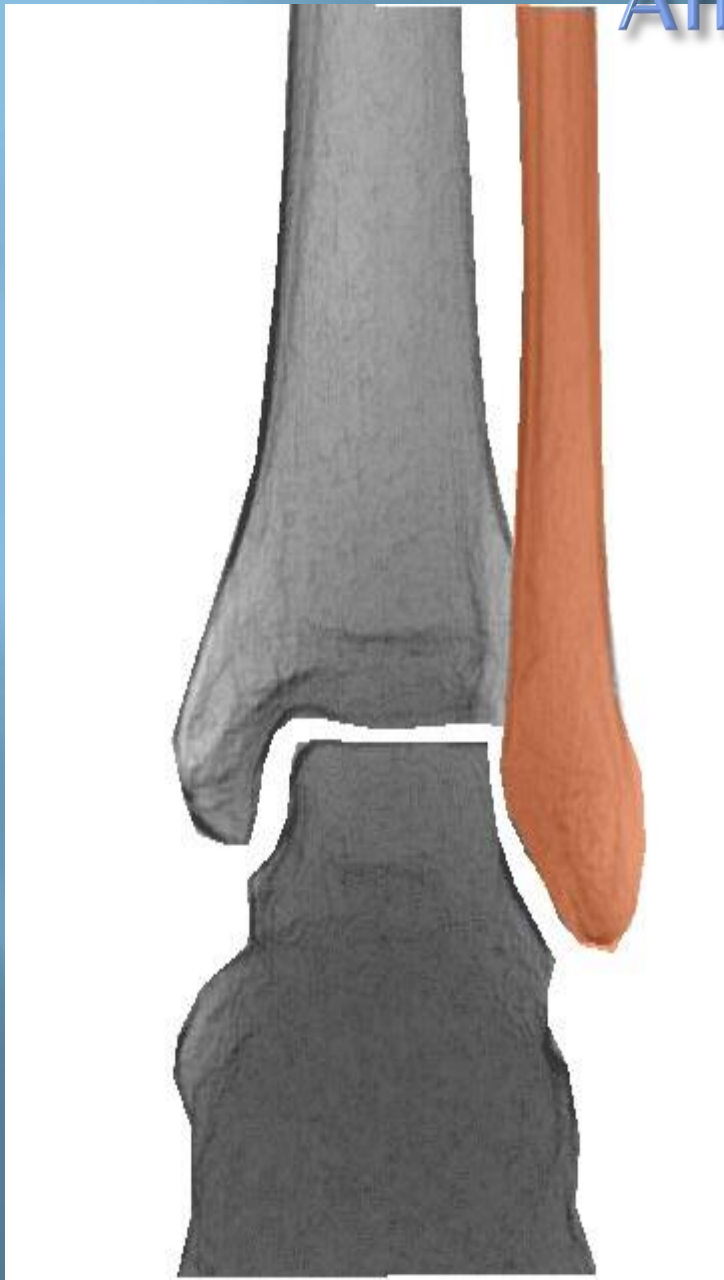
Lateral view





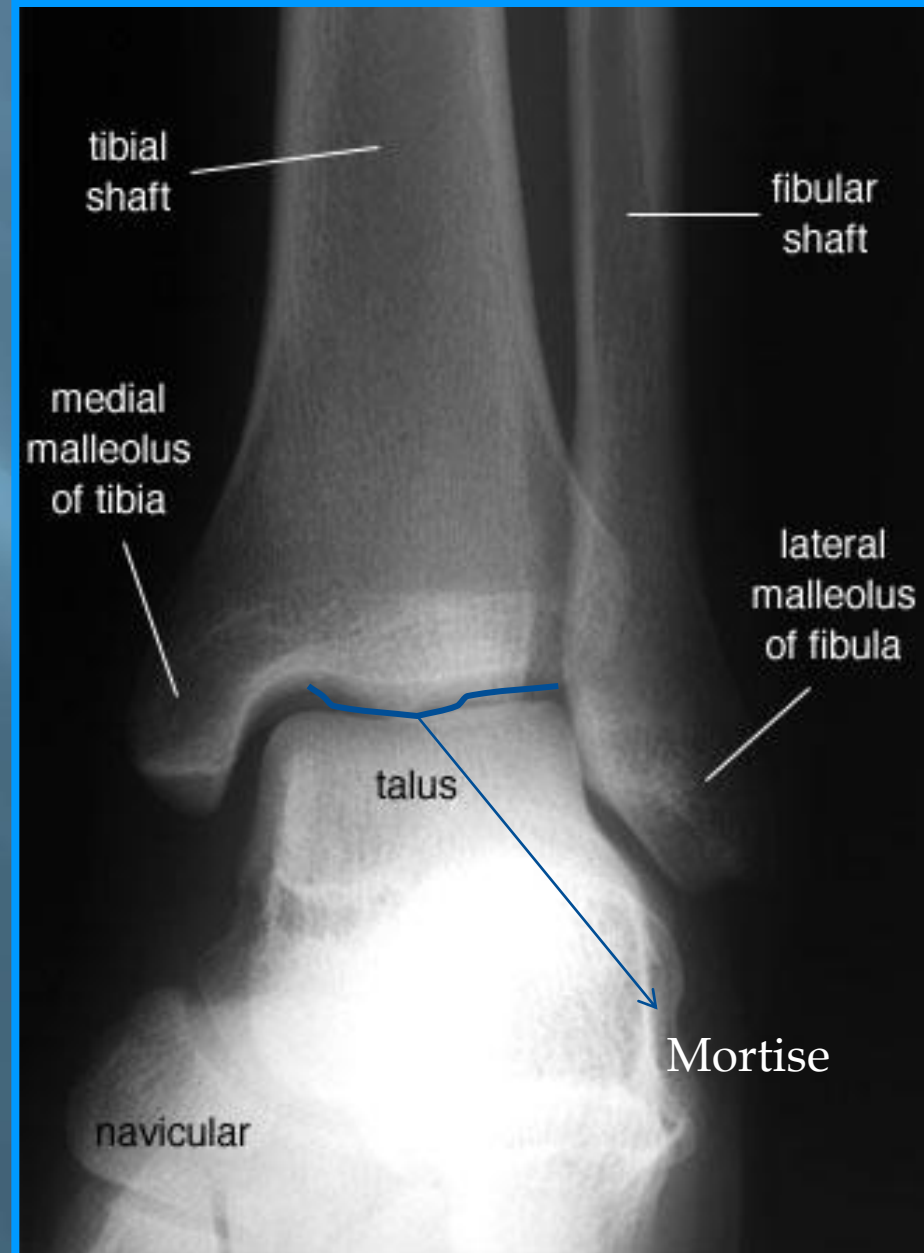
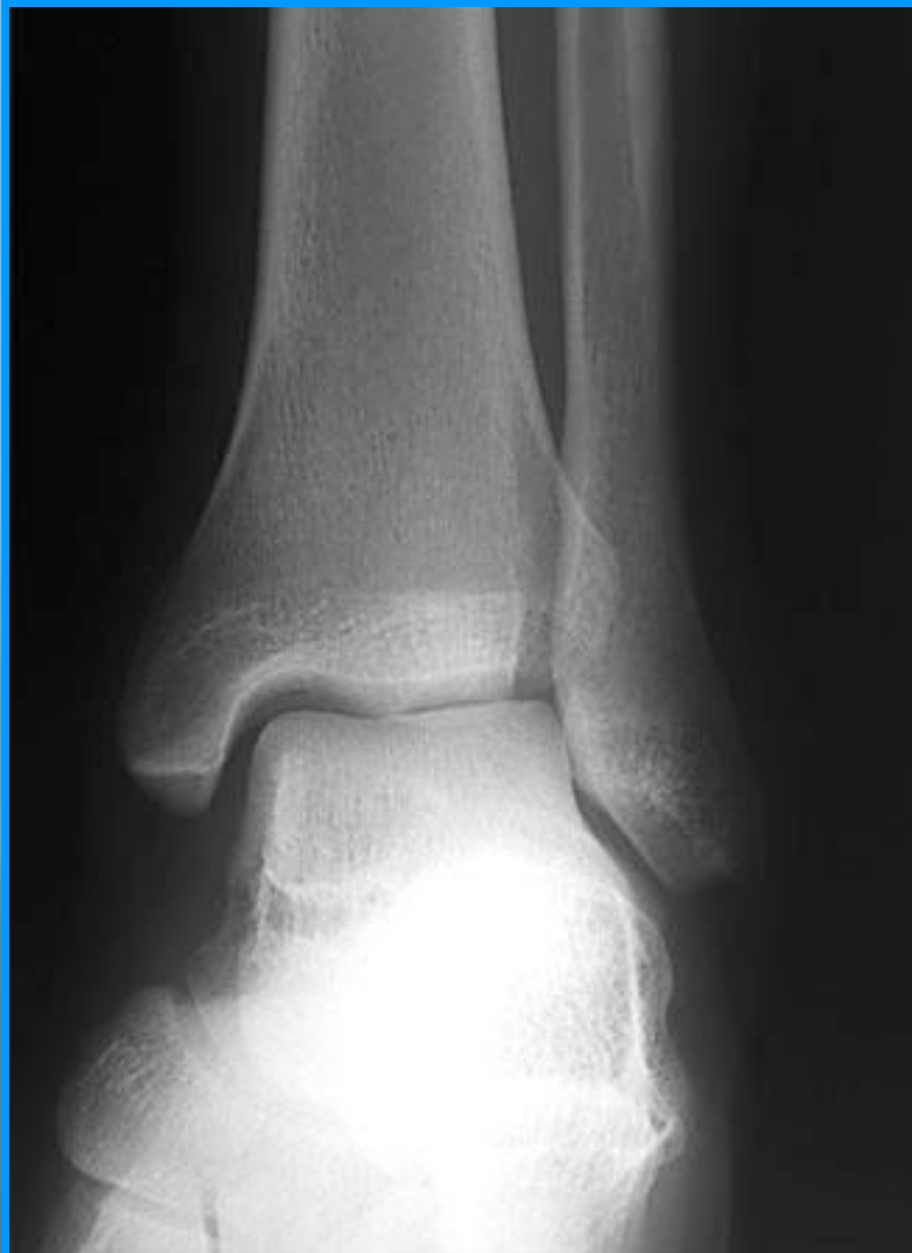LT Ankle, AP view

Ankle Joint

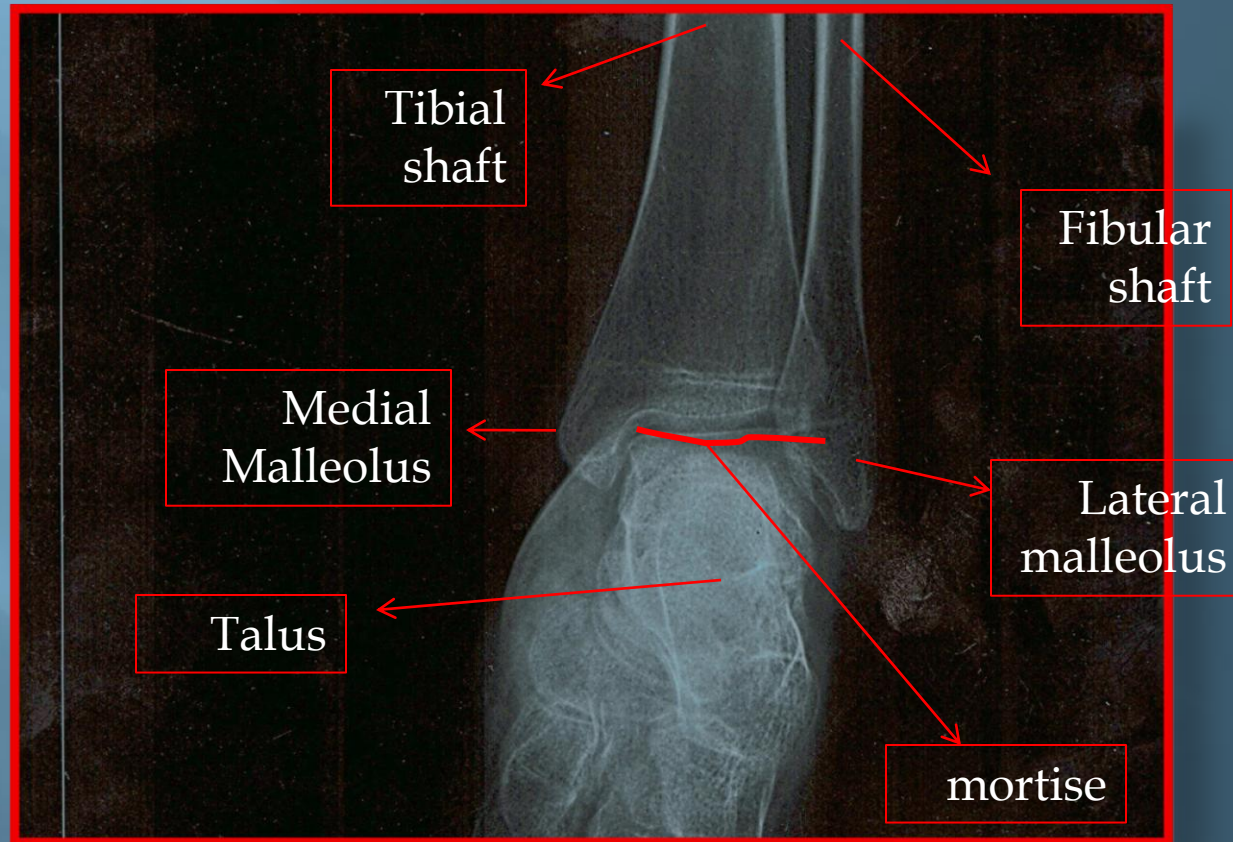


Ankle,

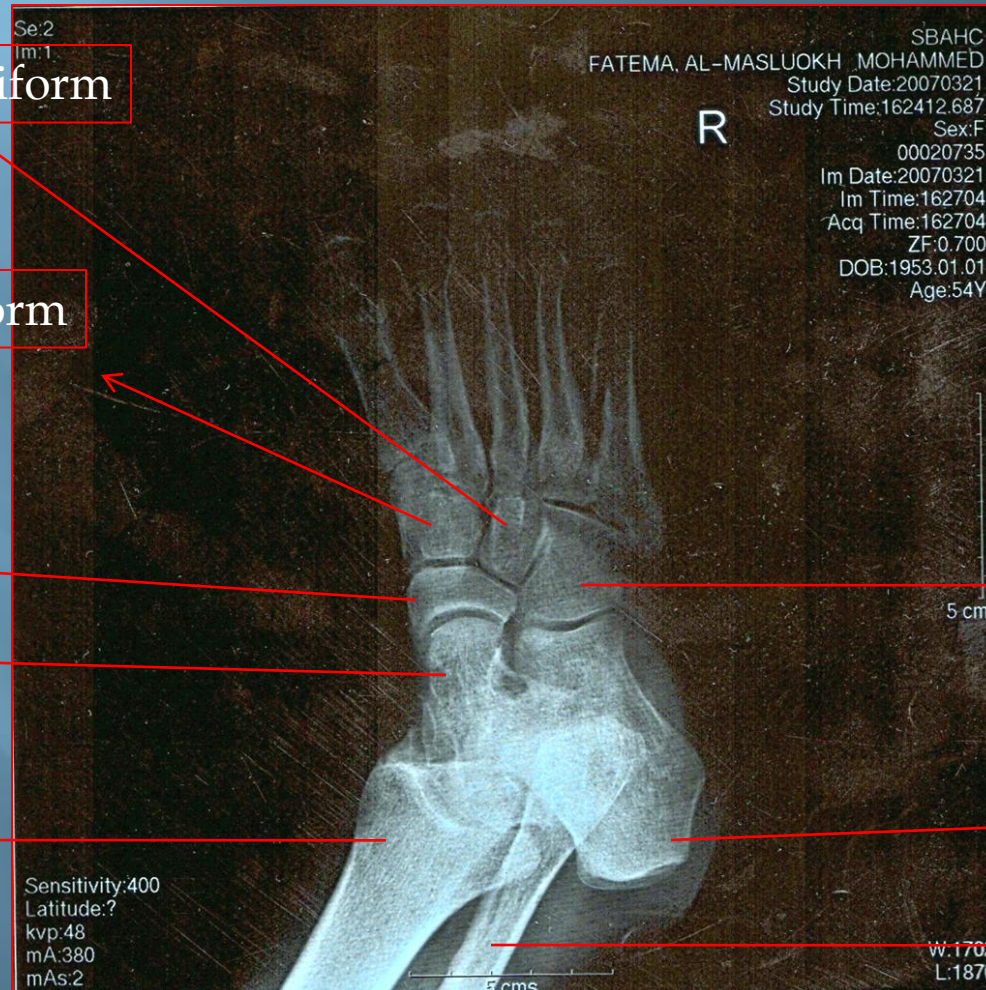
AP view



AP Ankle L



Rt Foot Oblique



3rd lateral Cuneiform

1st & 2nd cuneiform

Navicular

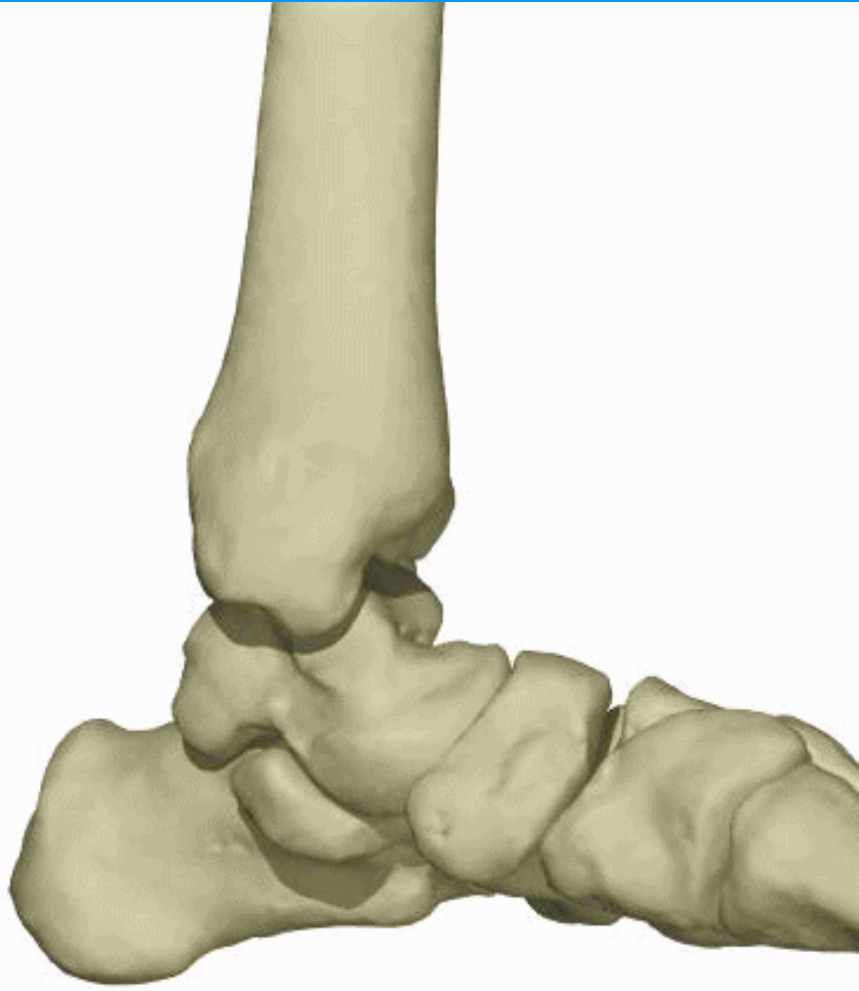
Talus

Tibia

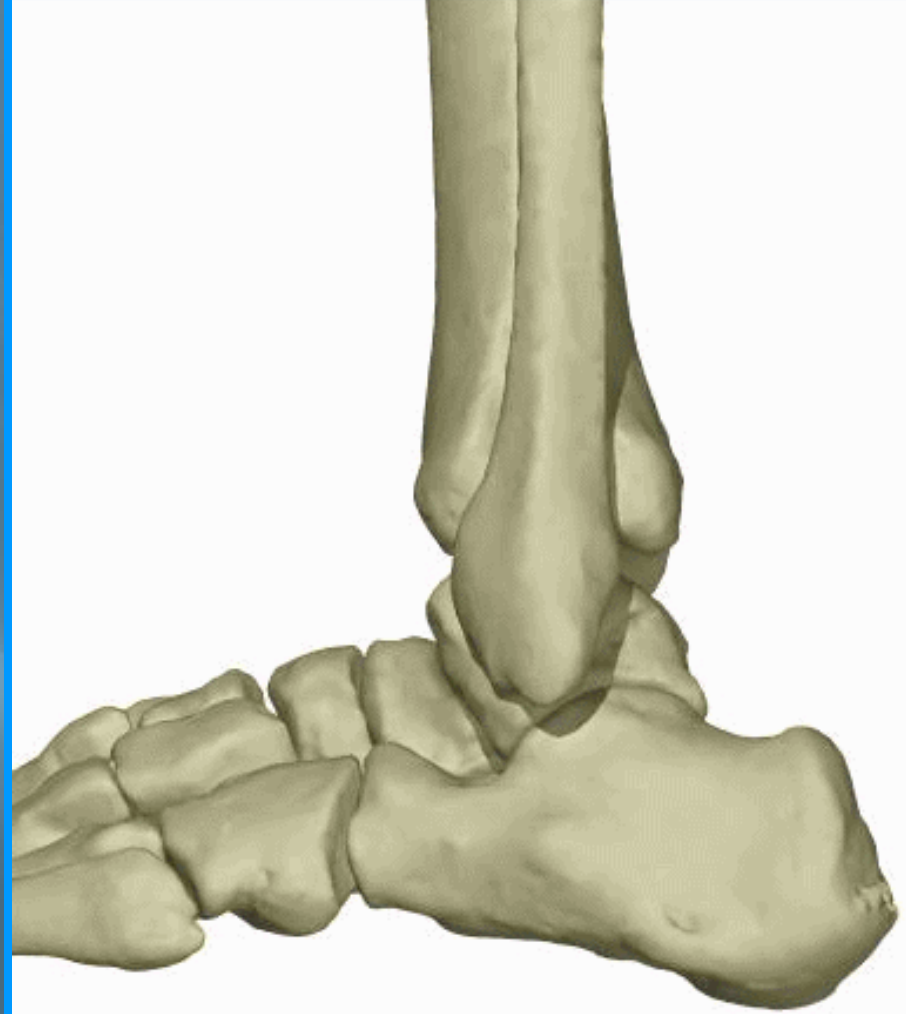
Cuboid

Calcaneus

Fibula



Medial Surface

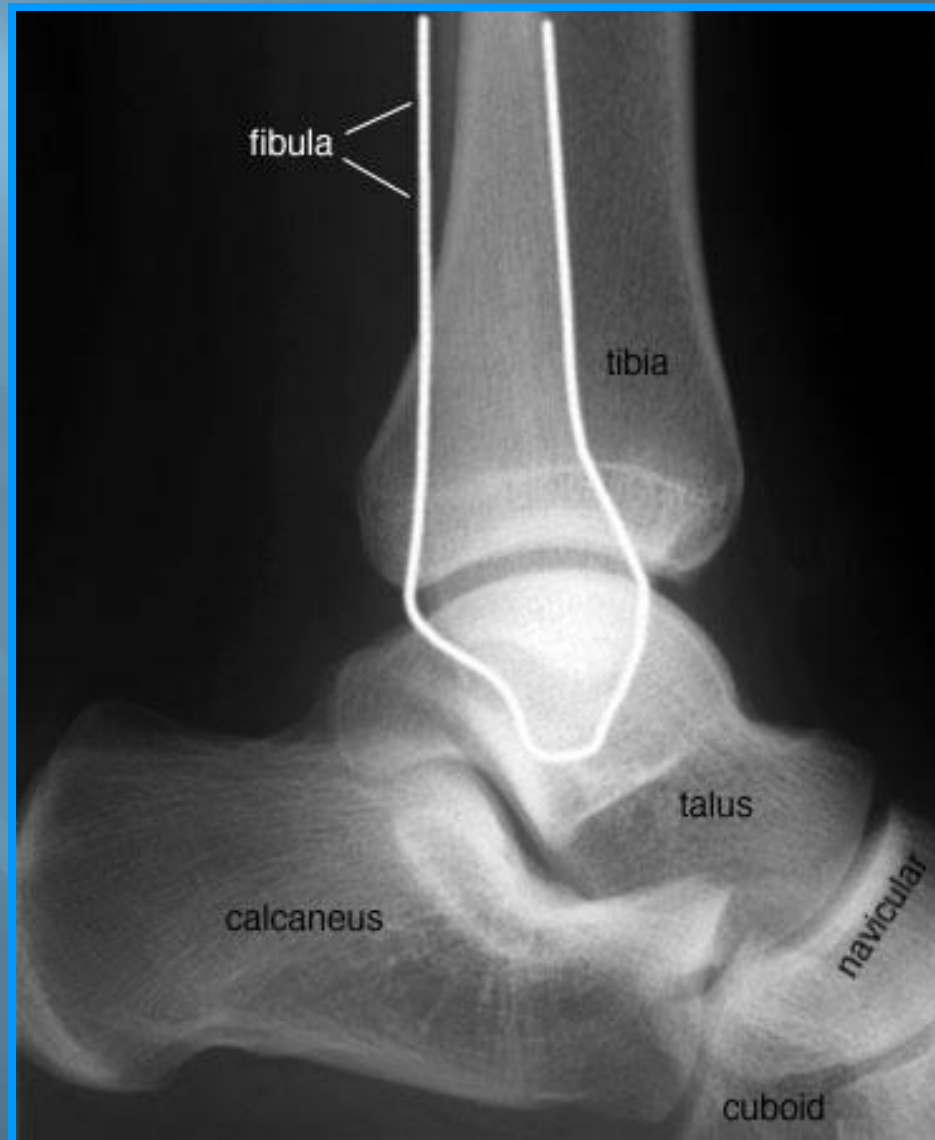

Lateral Surface

Ankle

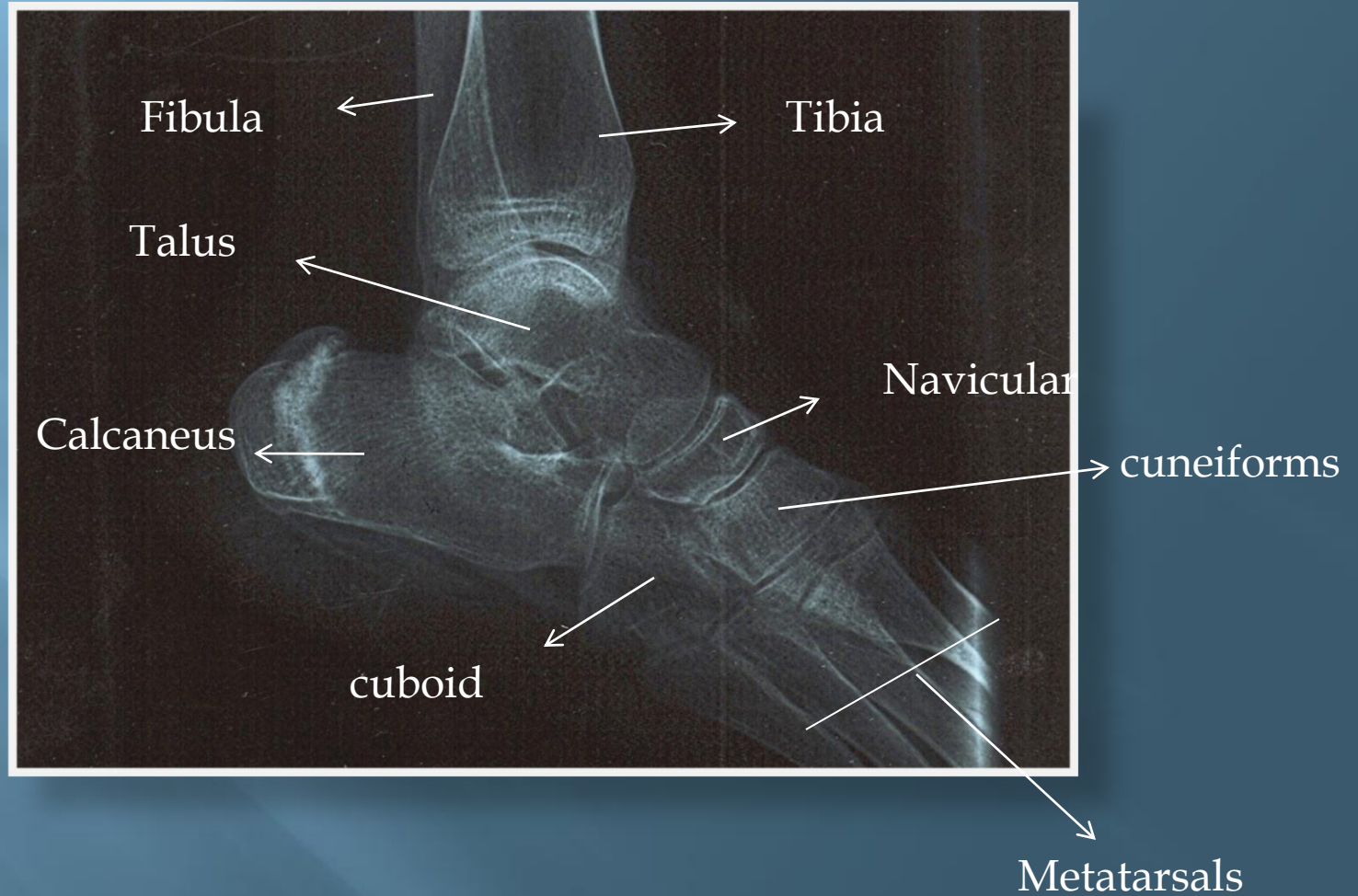
Ankle,

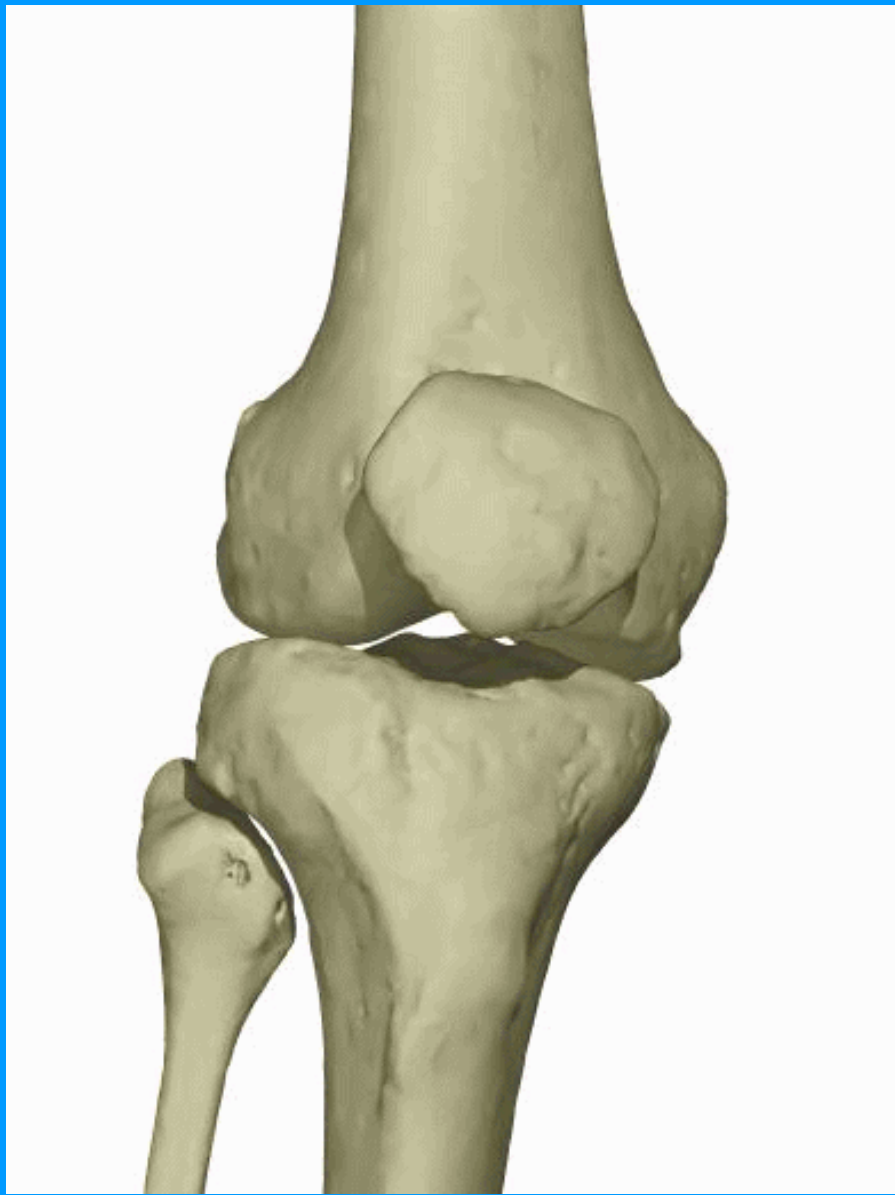
Lateral view



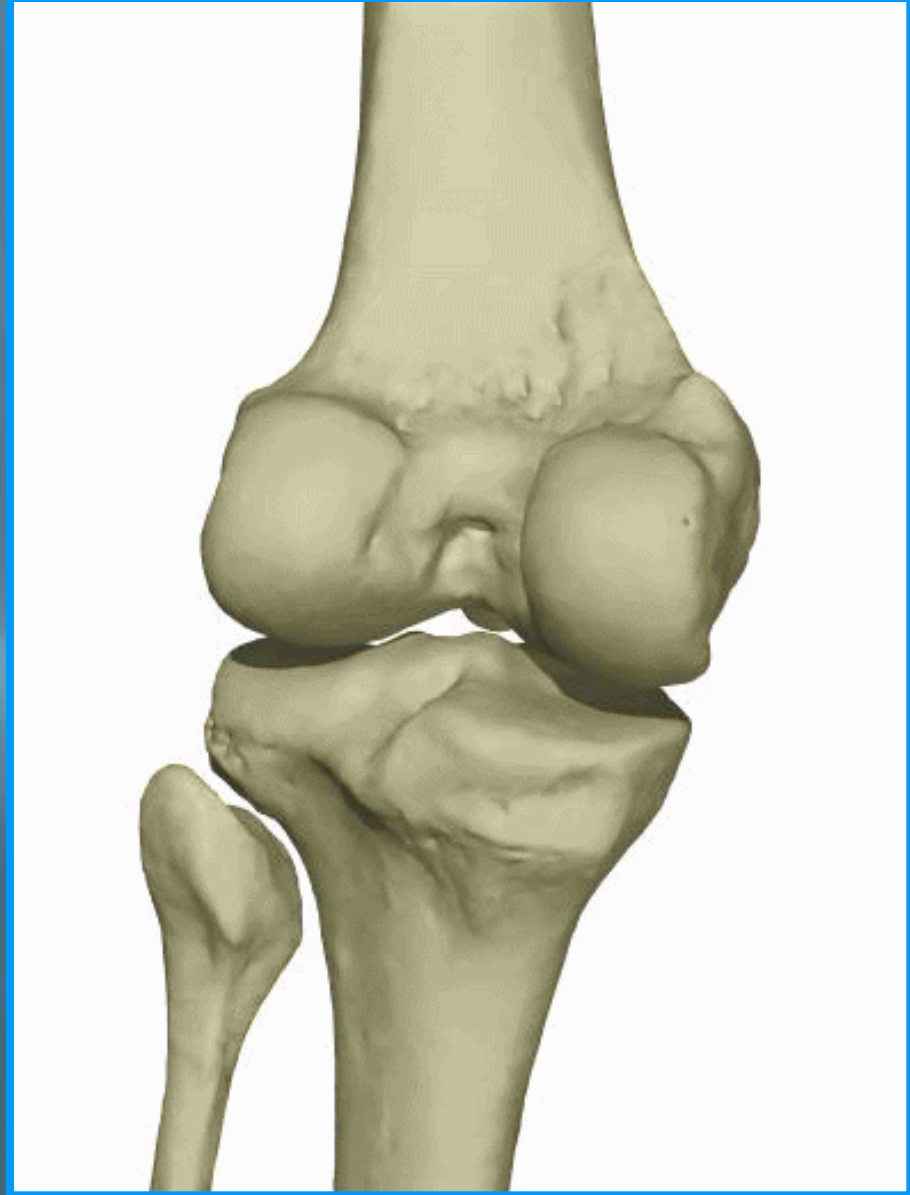
Ankle lateral

E





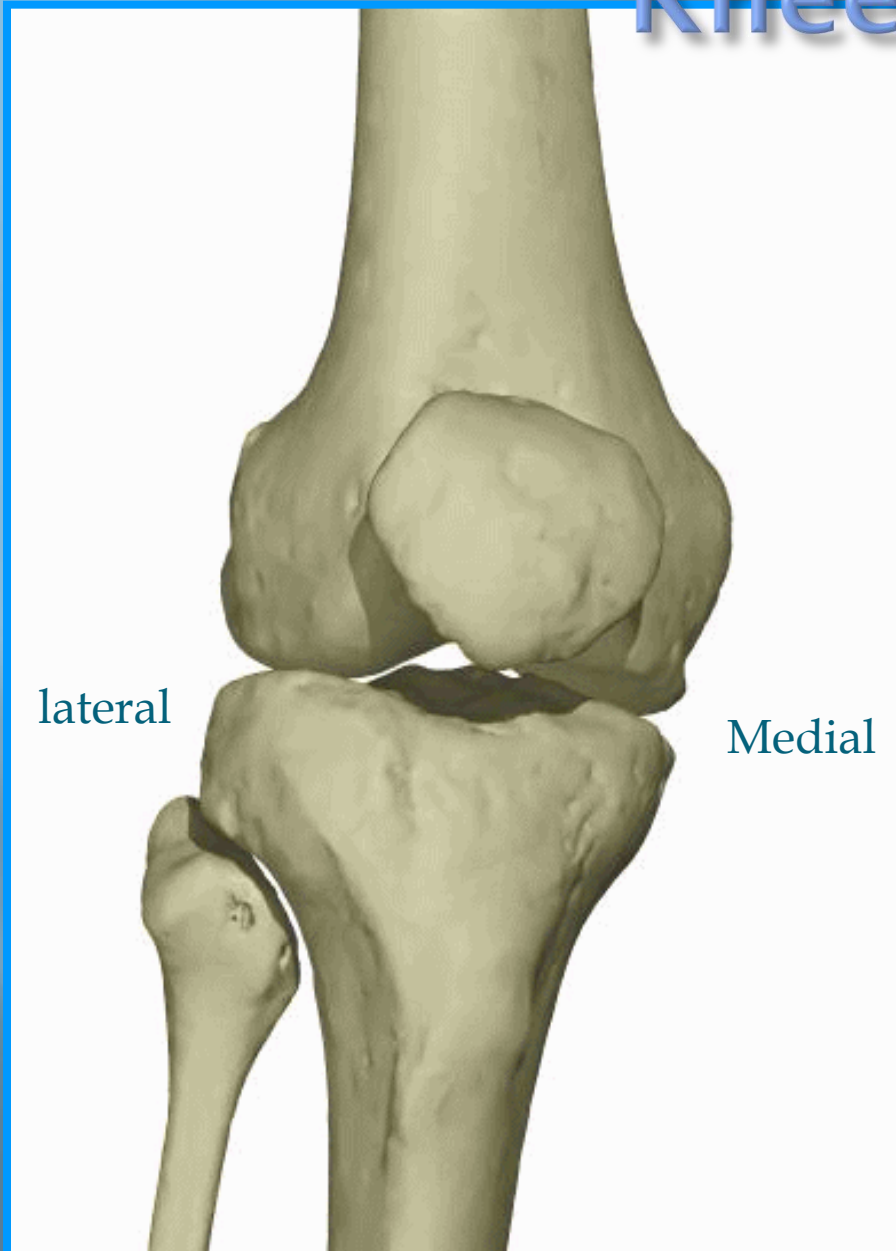
Anterior Surface



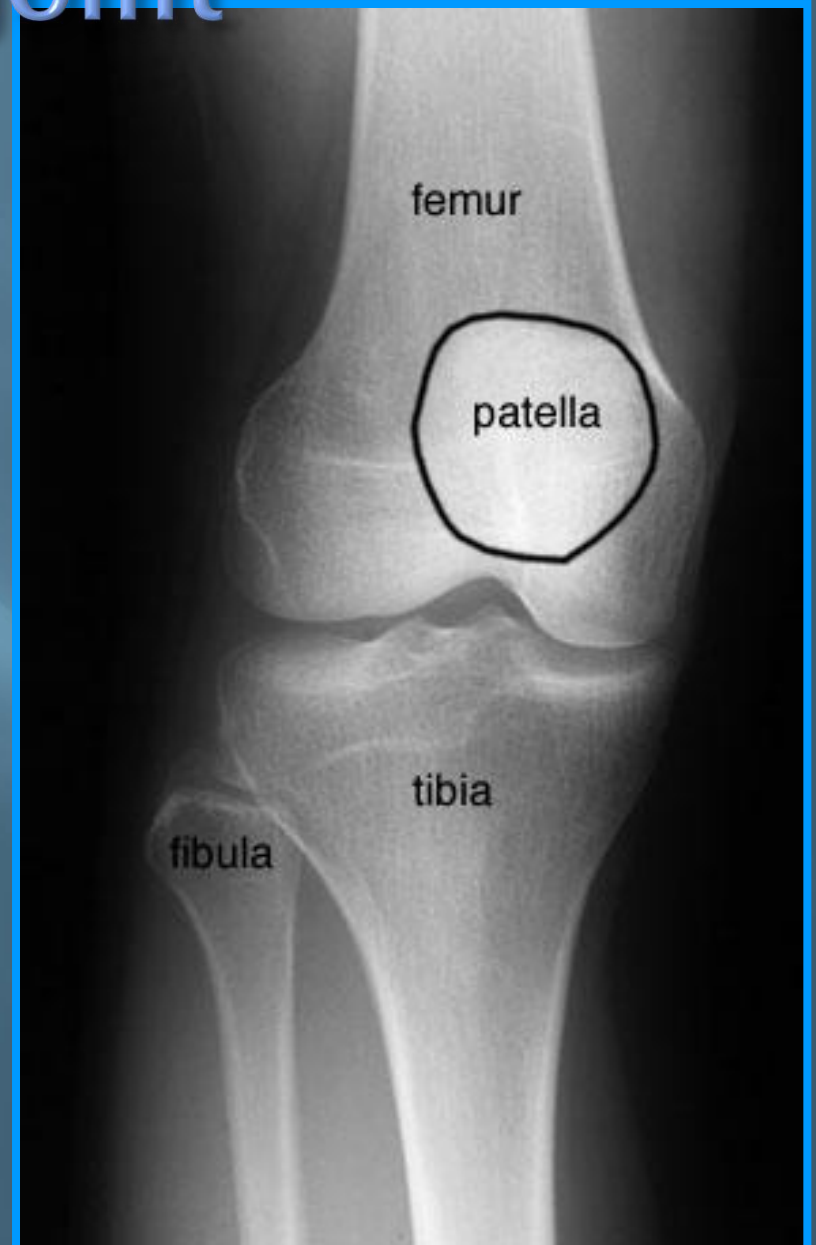Posterior Surface

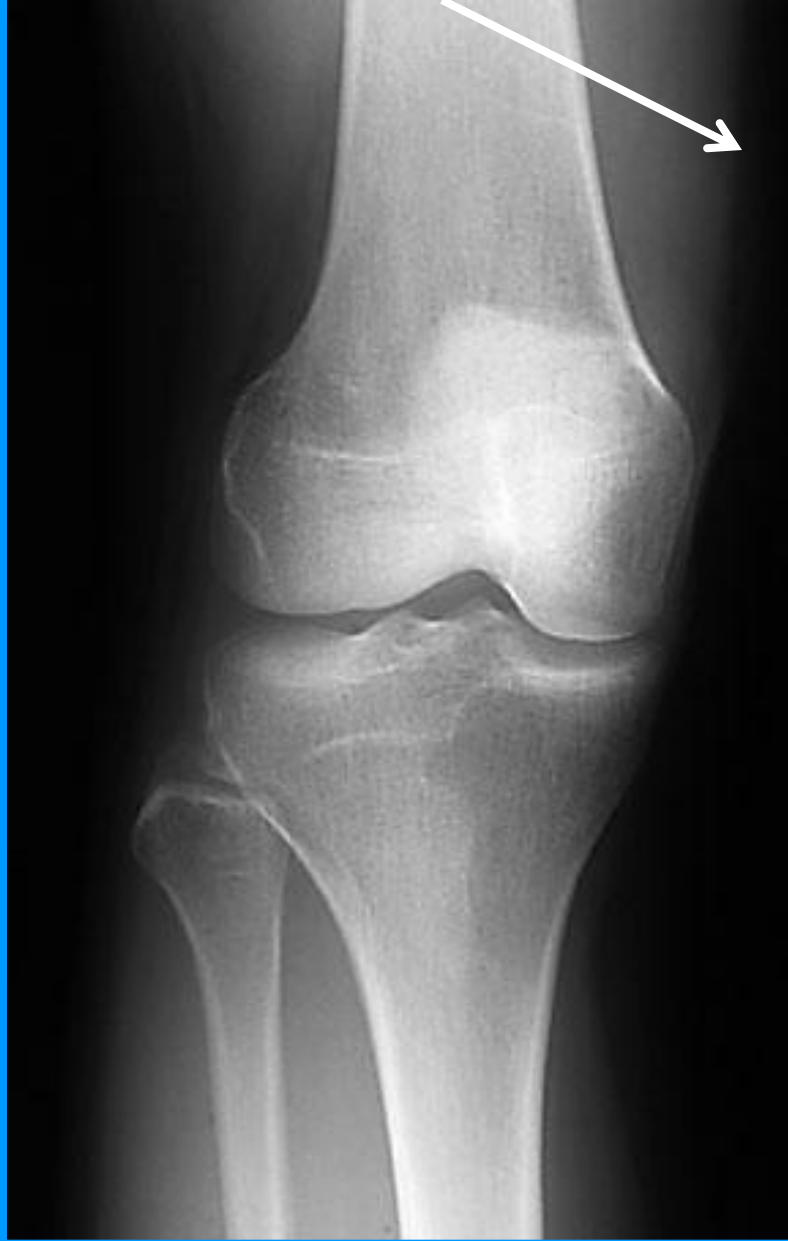Knee

Knee Joint

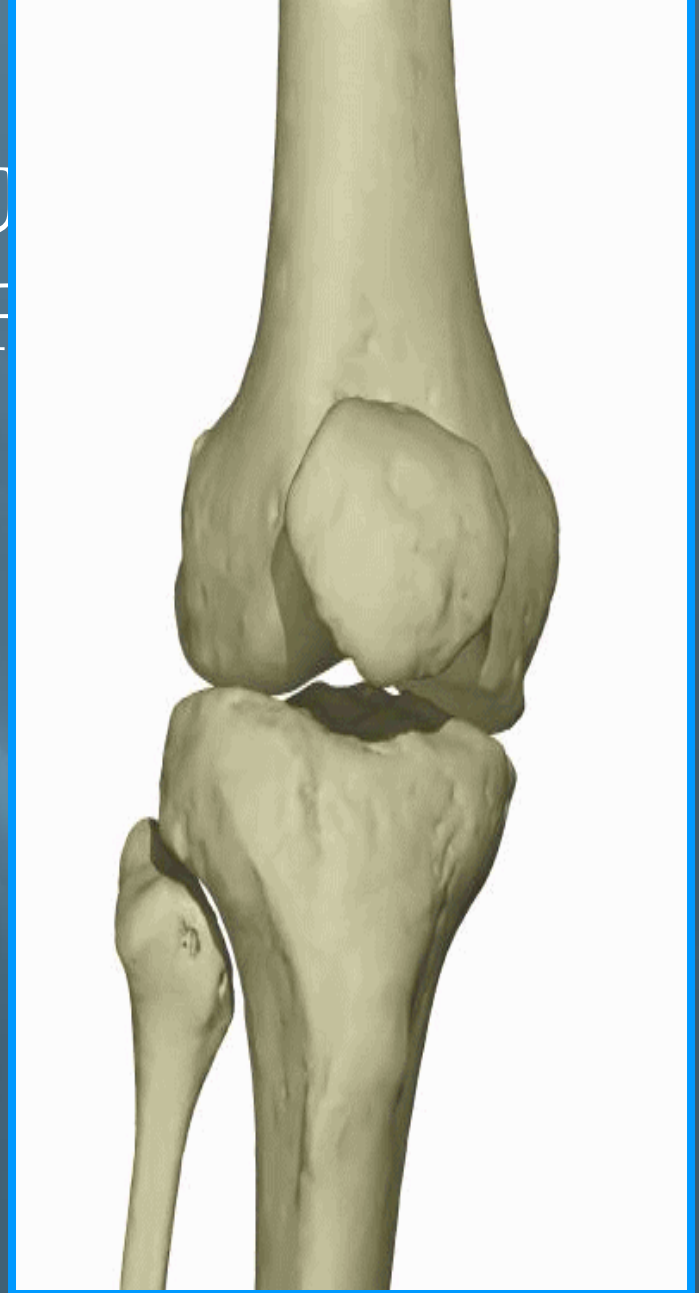


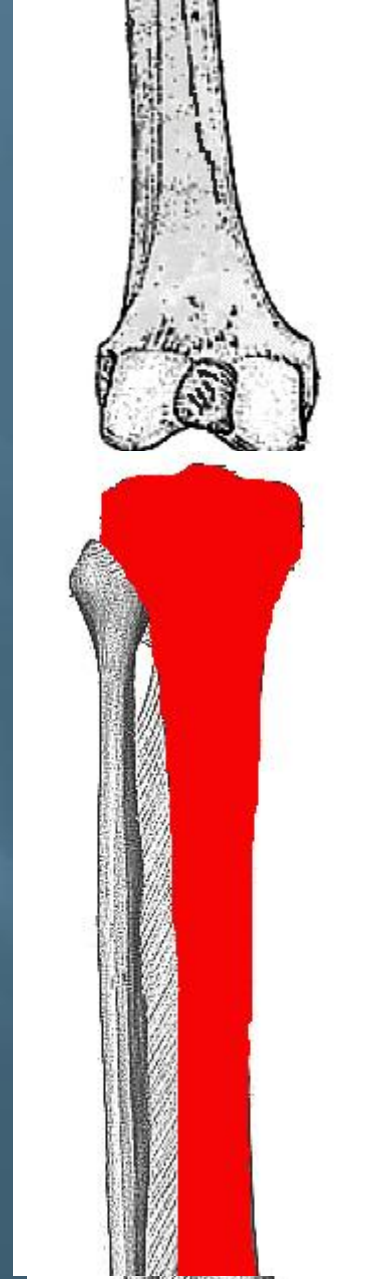
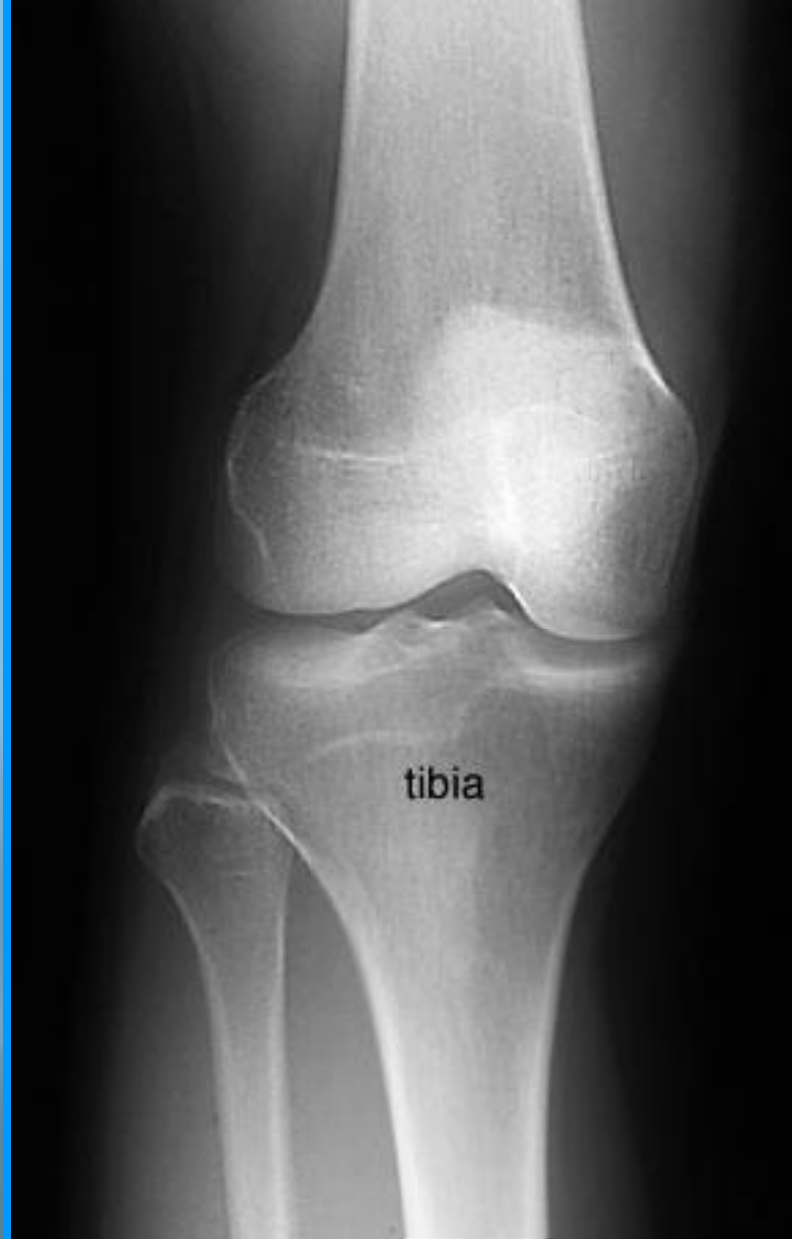Anterior Surface

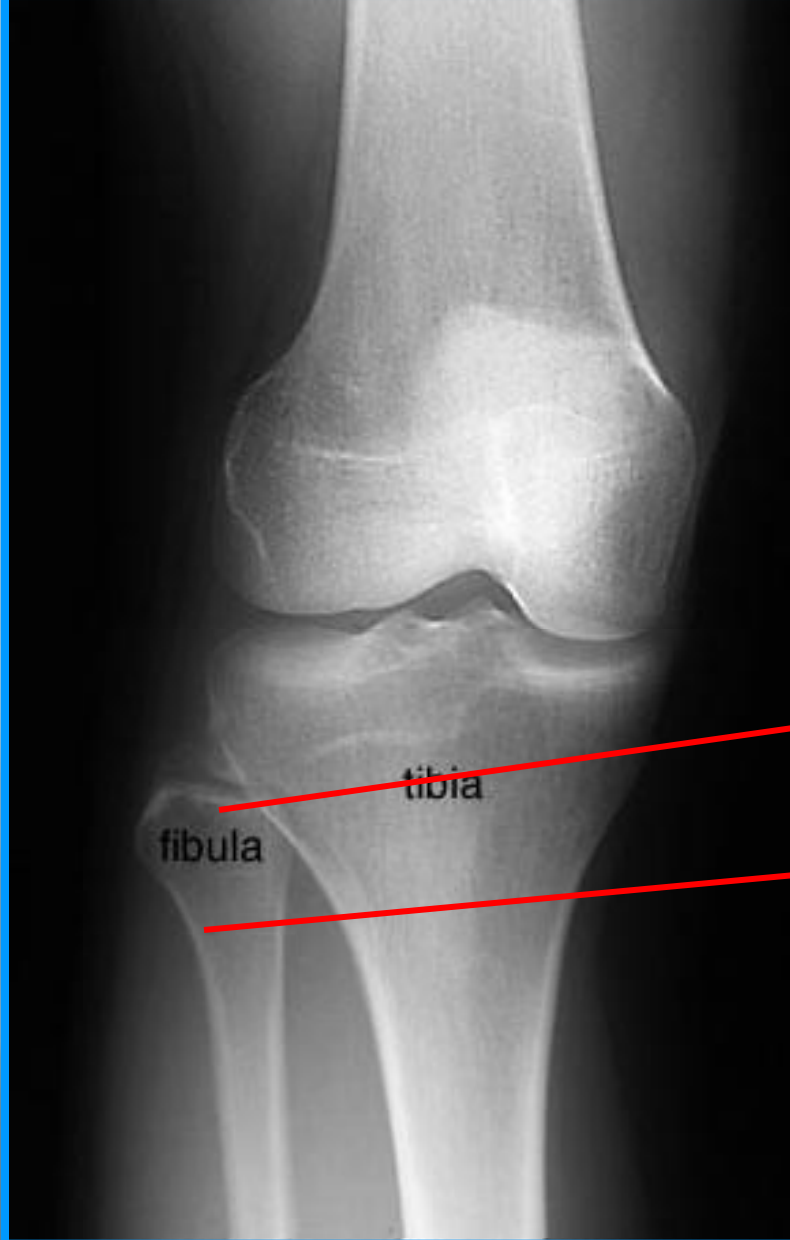




FEMUR
SHAPE



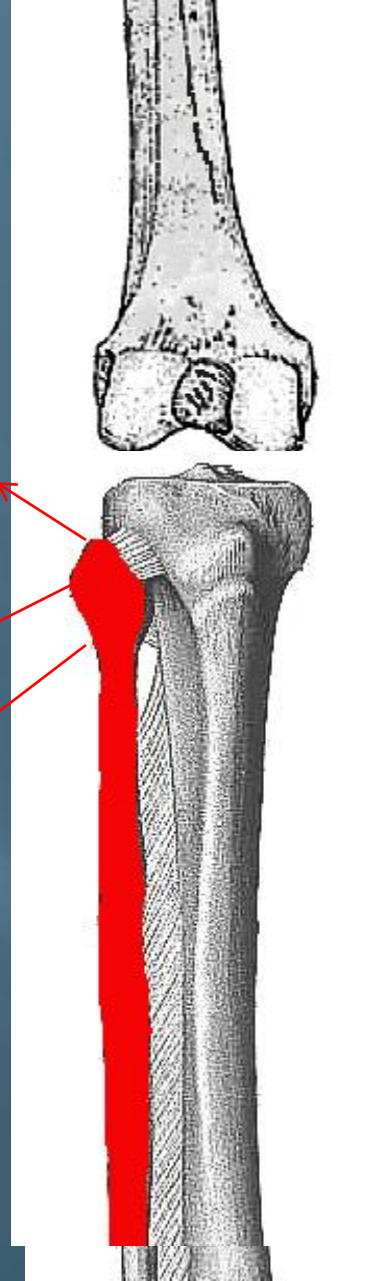


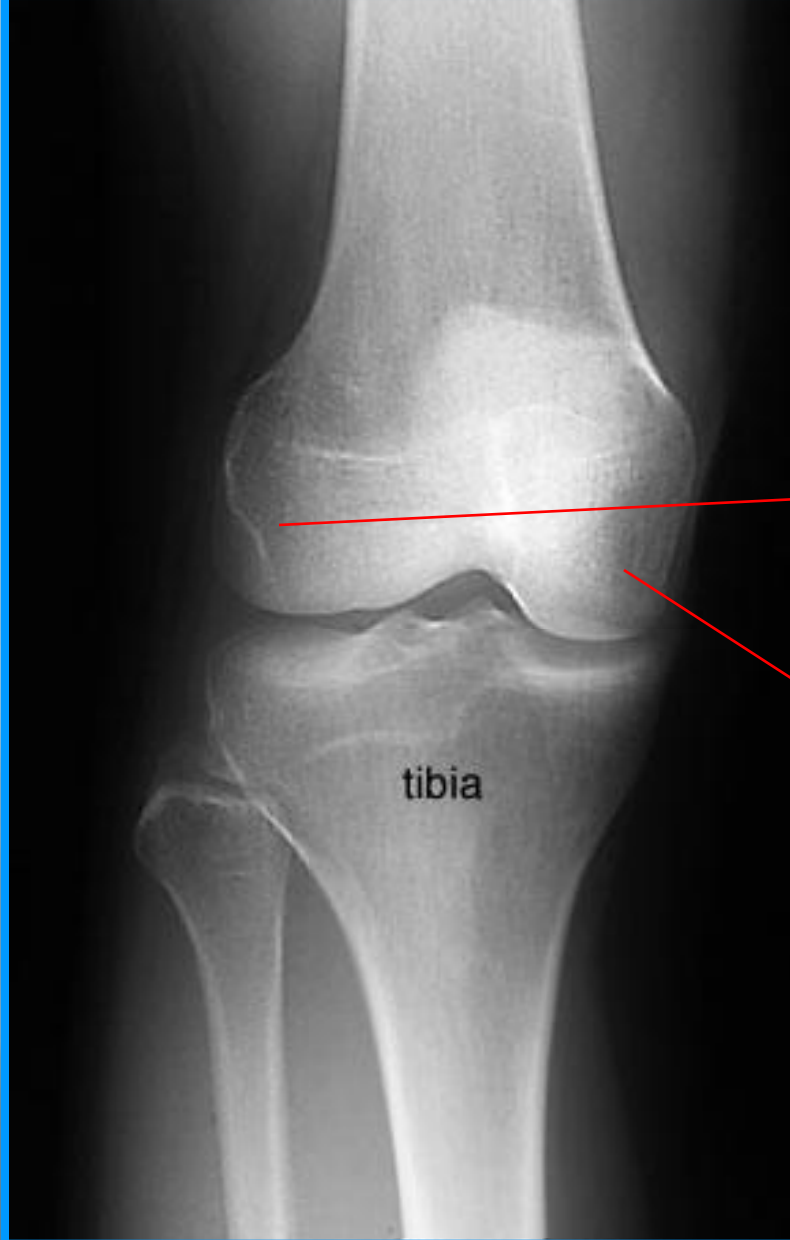


Apex styloid process

Head

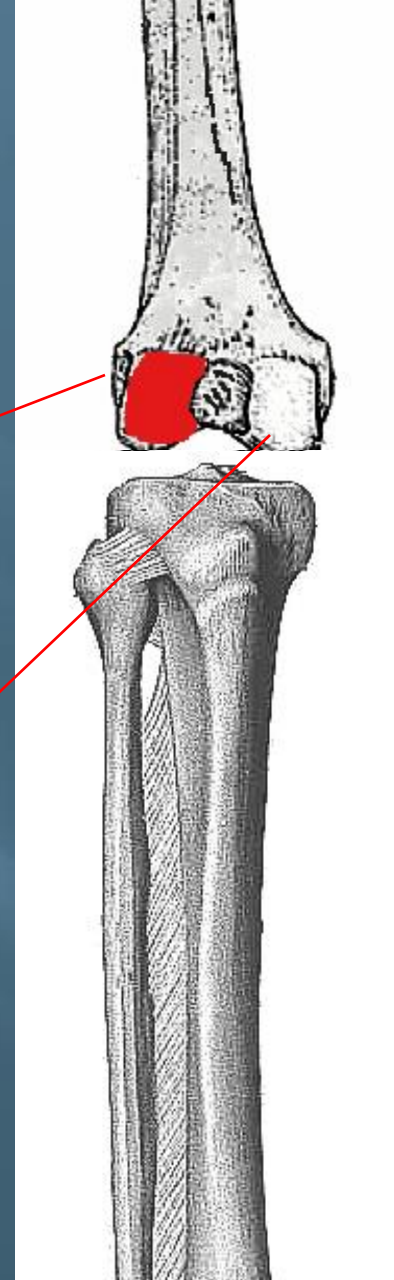
Neck

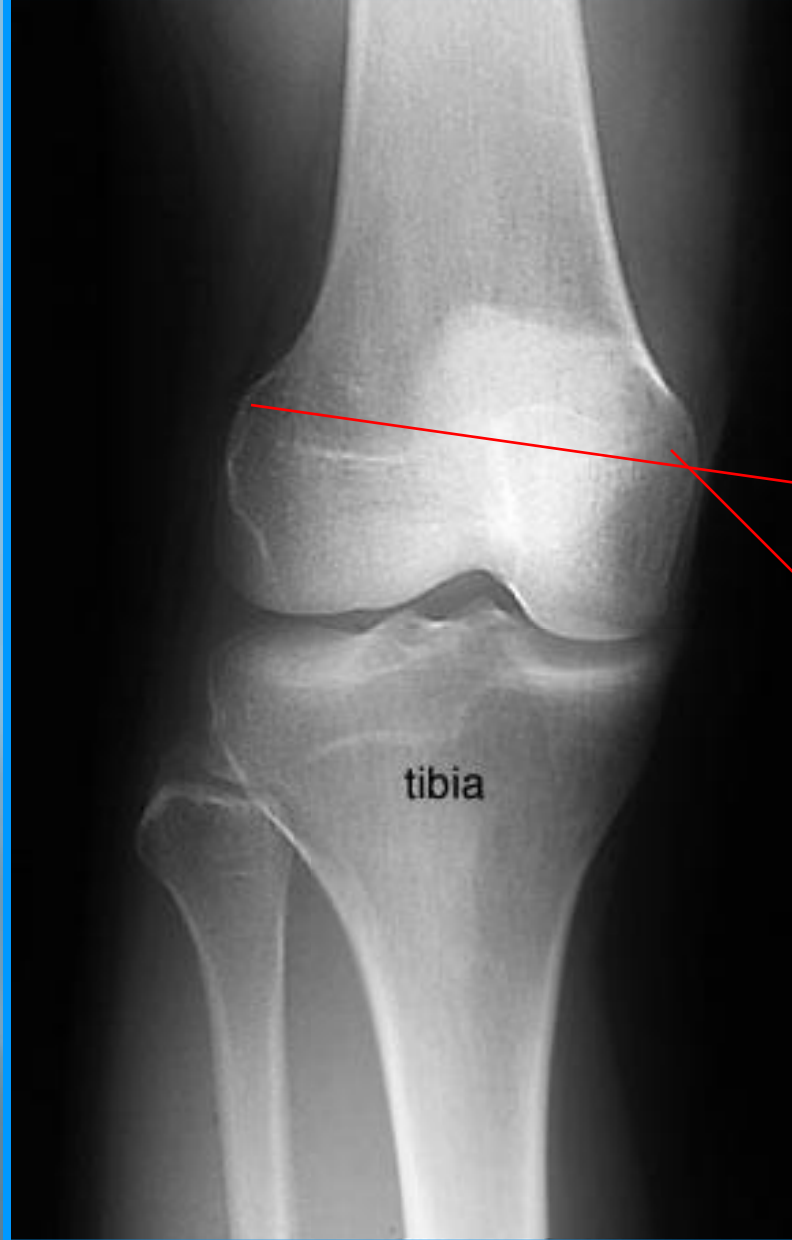



Lateral
condyle

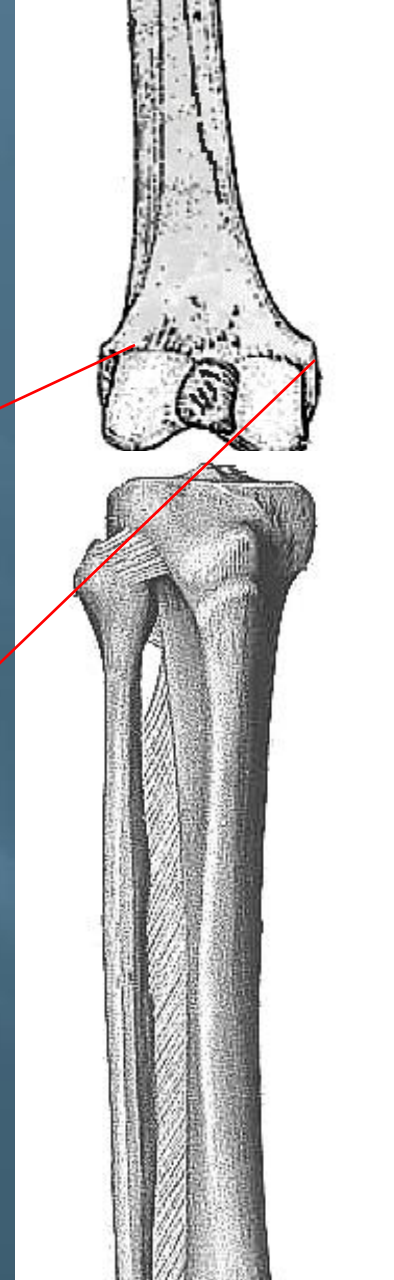
Medial
condyle

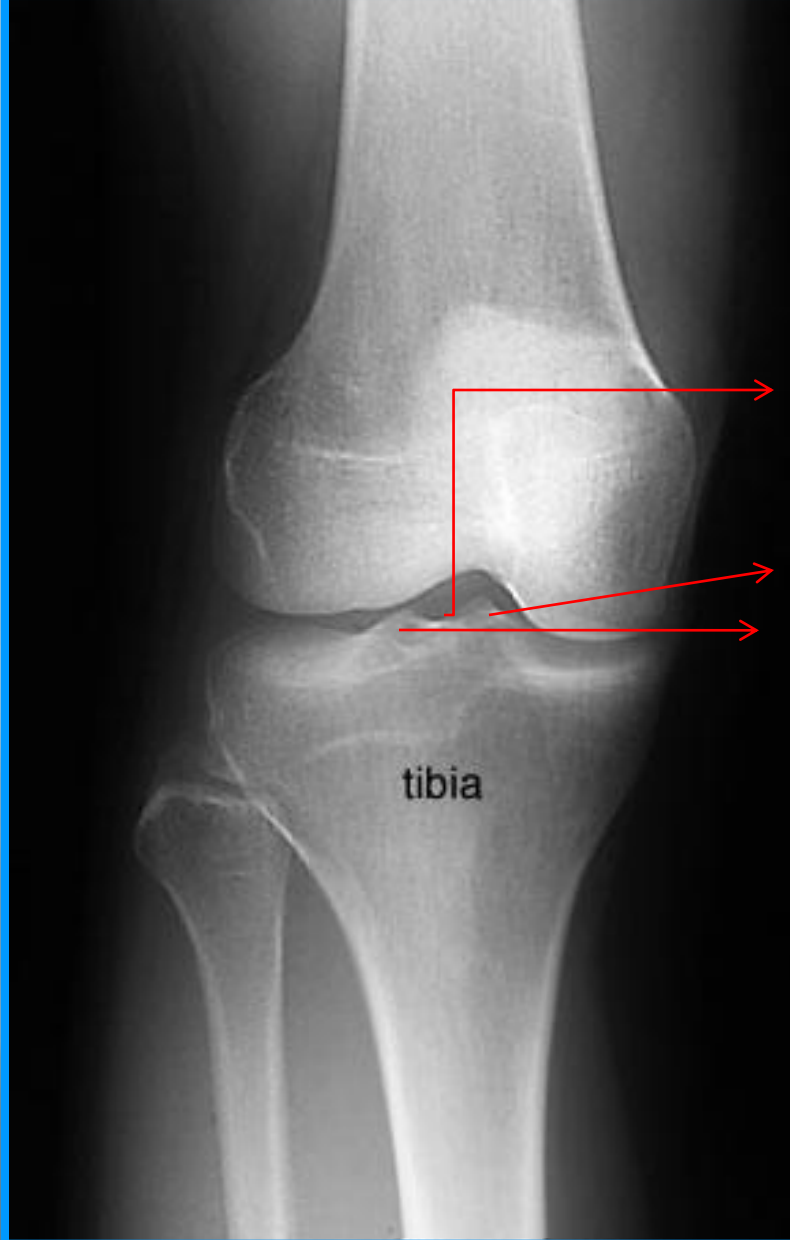




Lateral
epicondyle

Medial
epicondyle

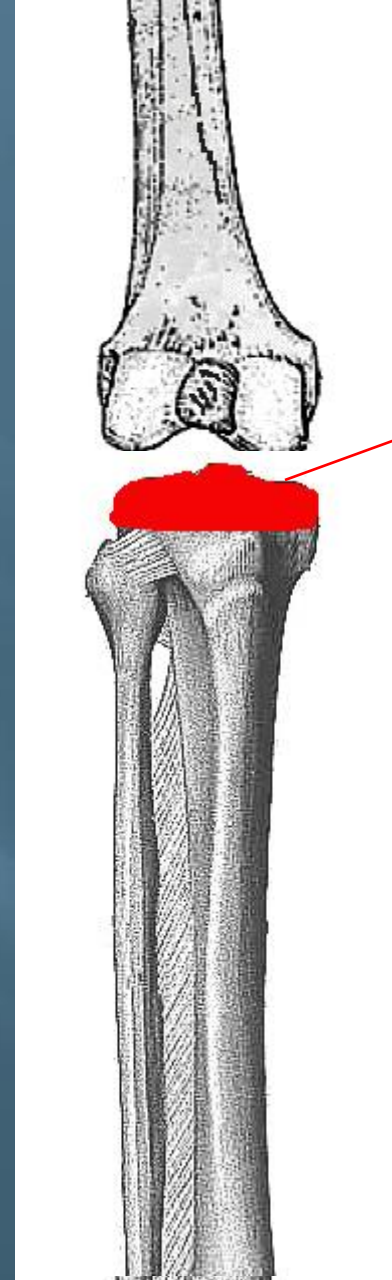




Intercondyloid
eminence

Medial & lateral
intercondylar
tubercles

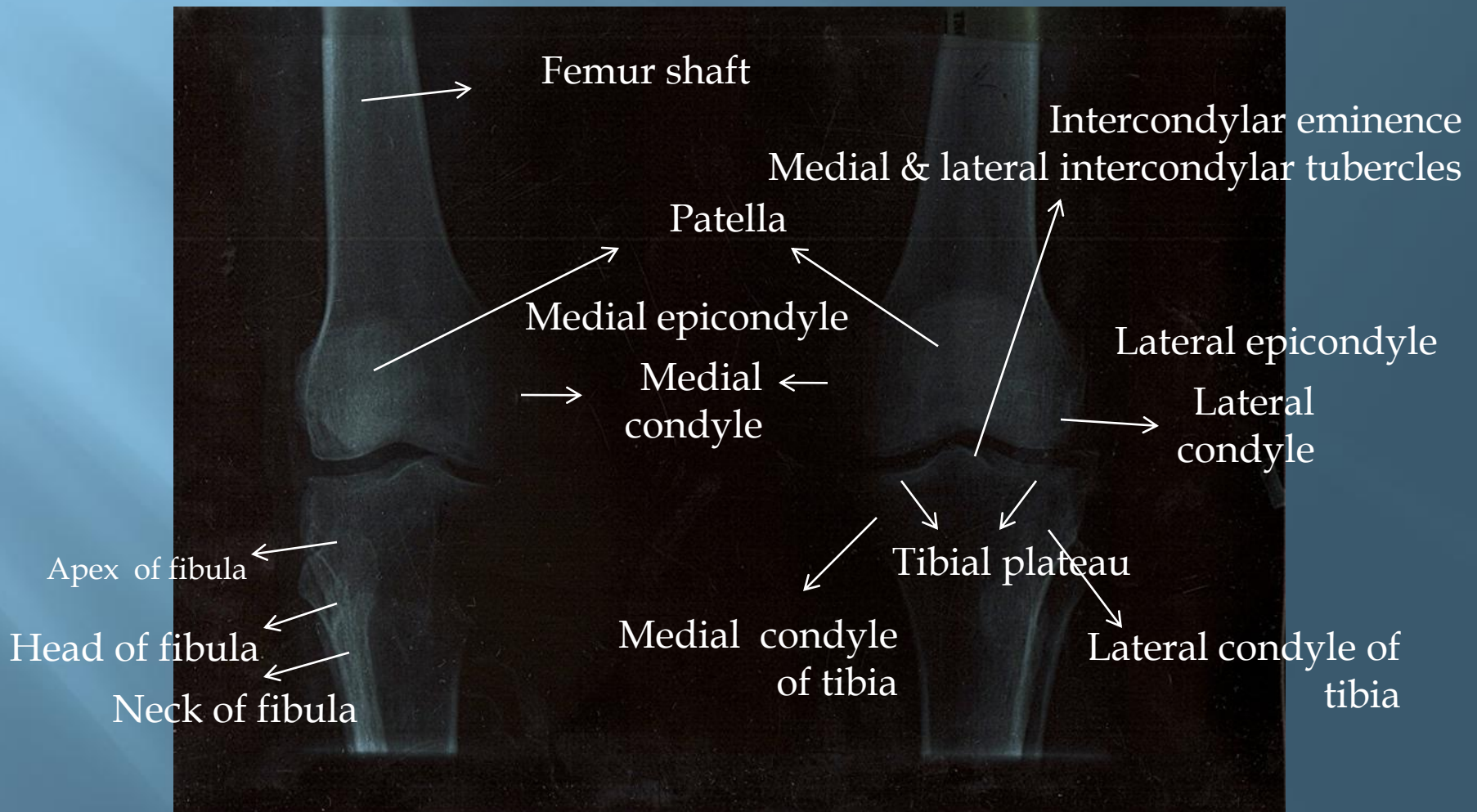
tibia



Tibial
plateau

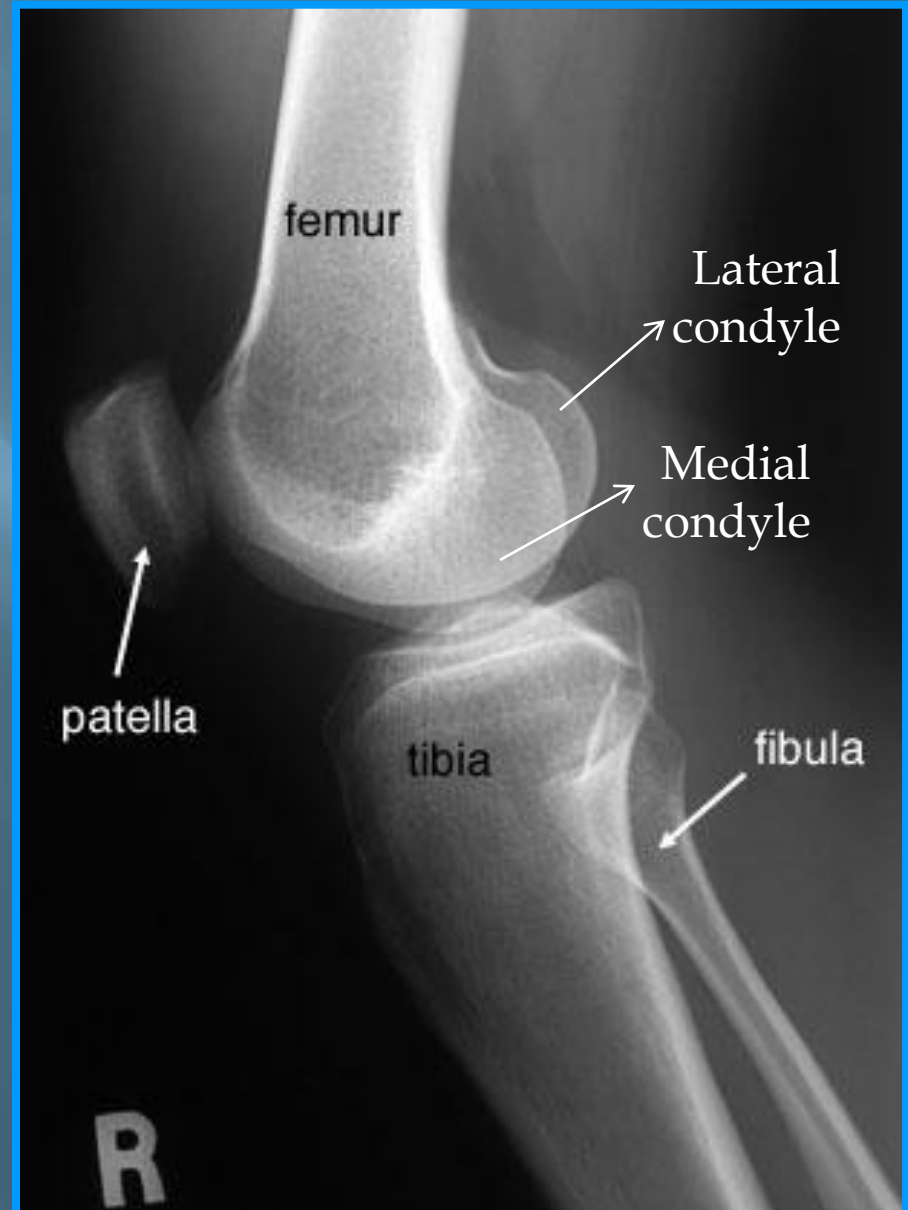
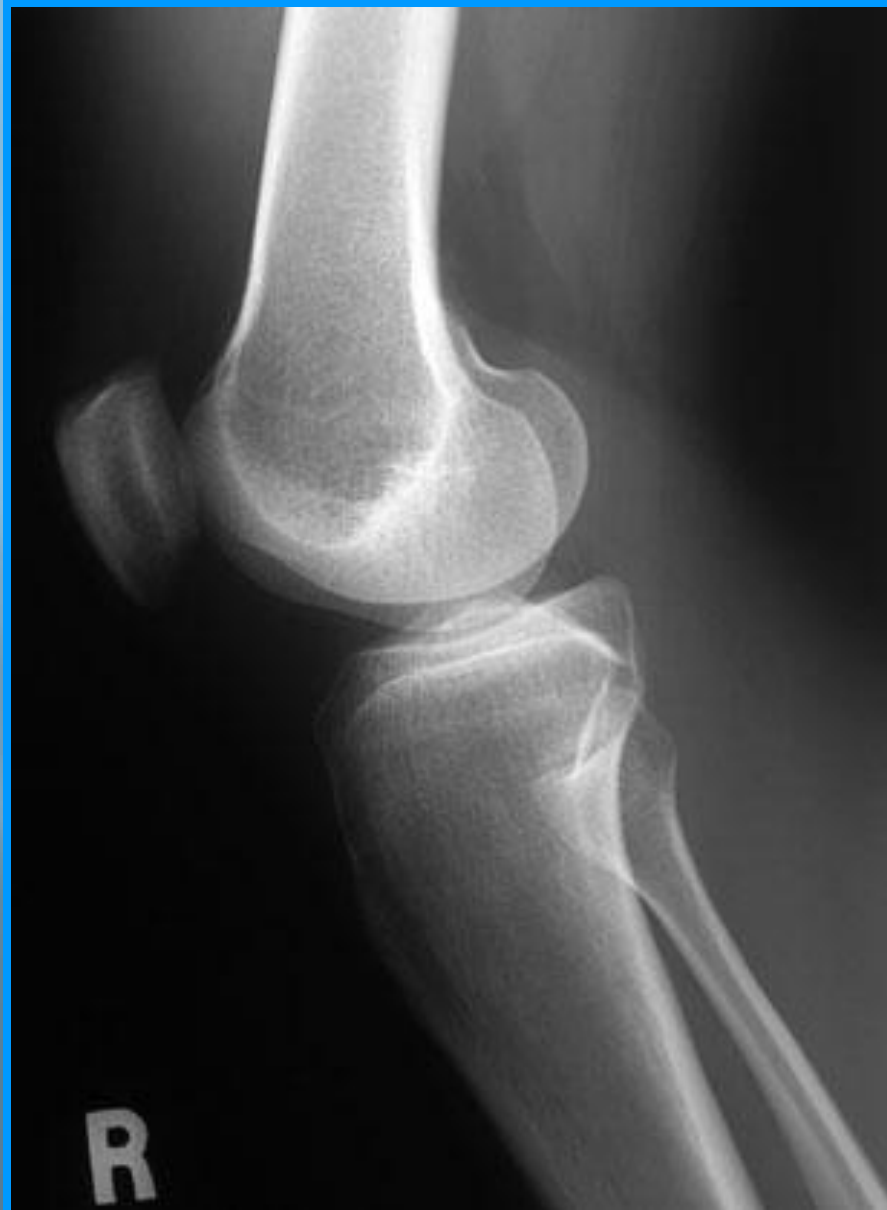Knee AP View

F



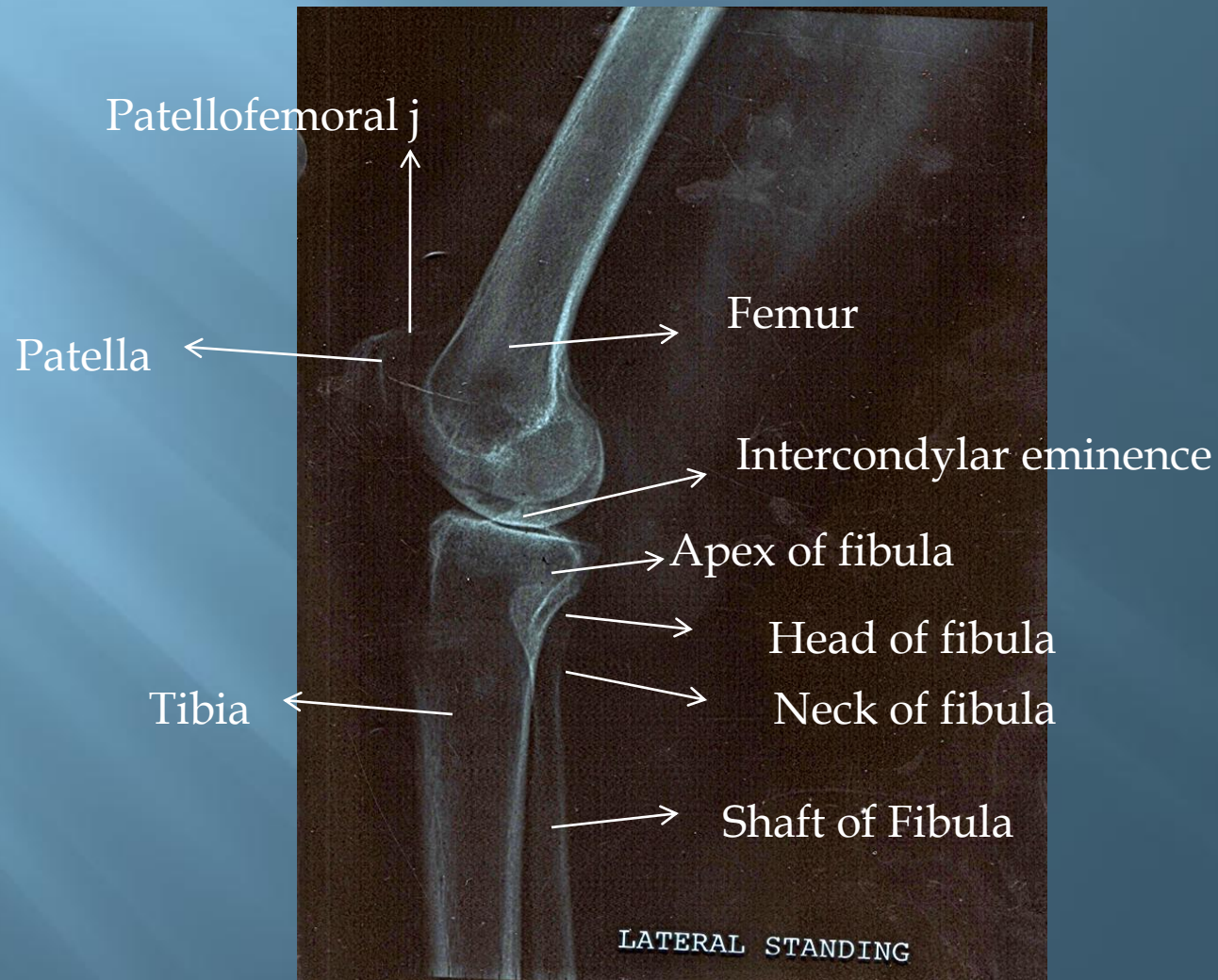
Knee,

Lateral view

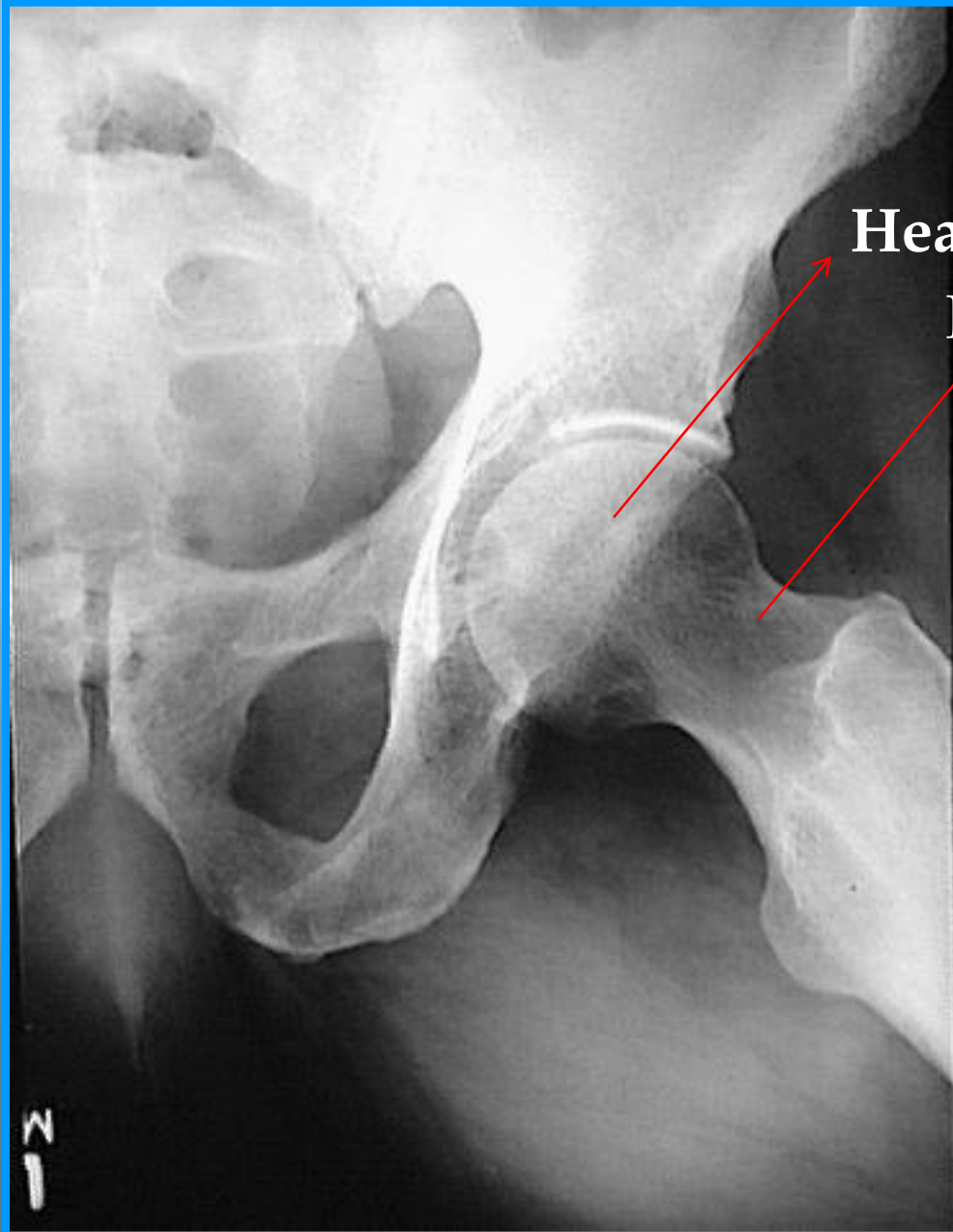


Rt Knee Lateral

G

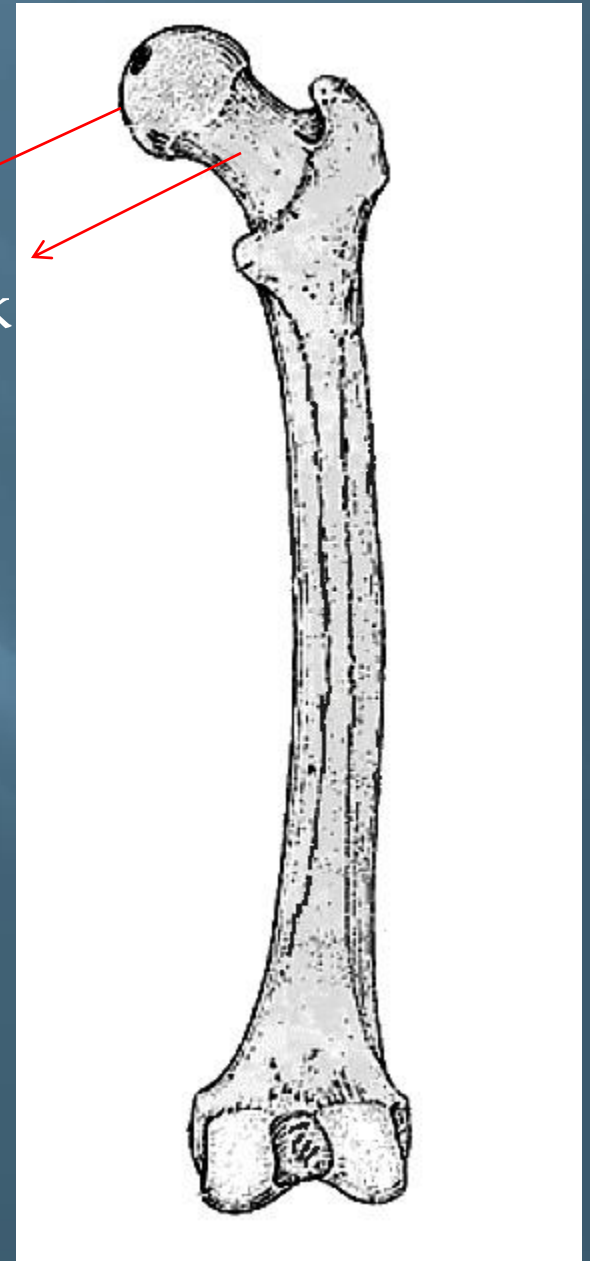


Femur

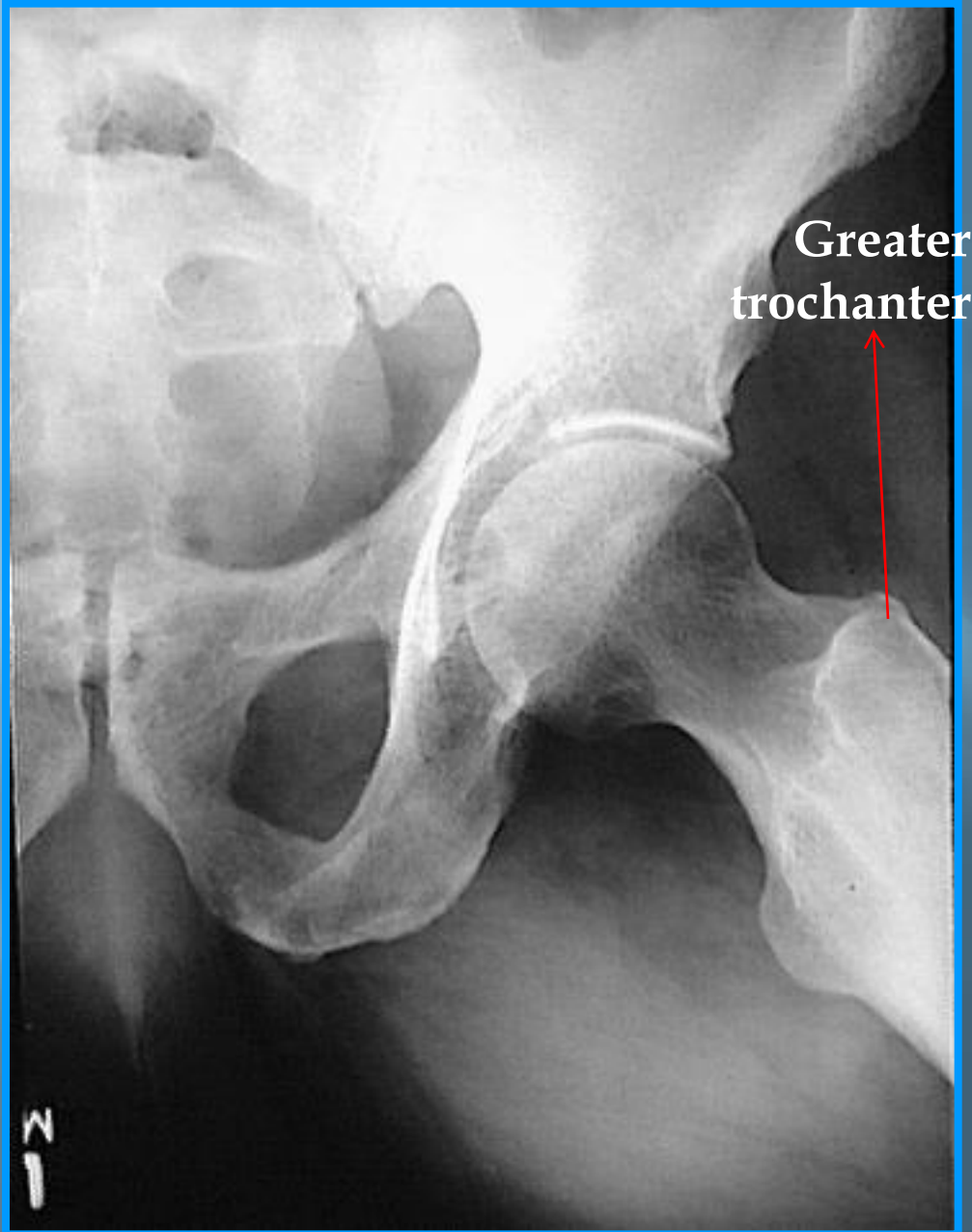


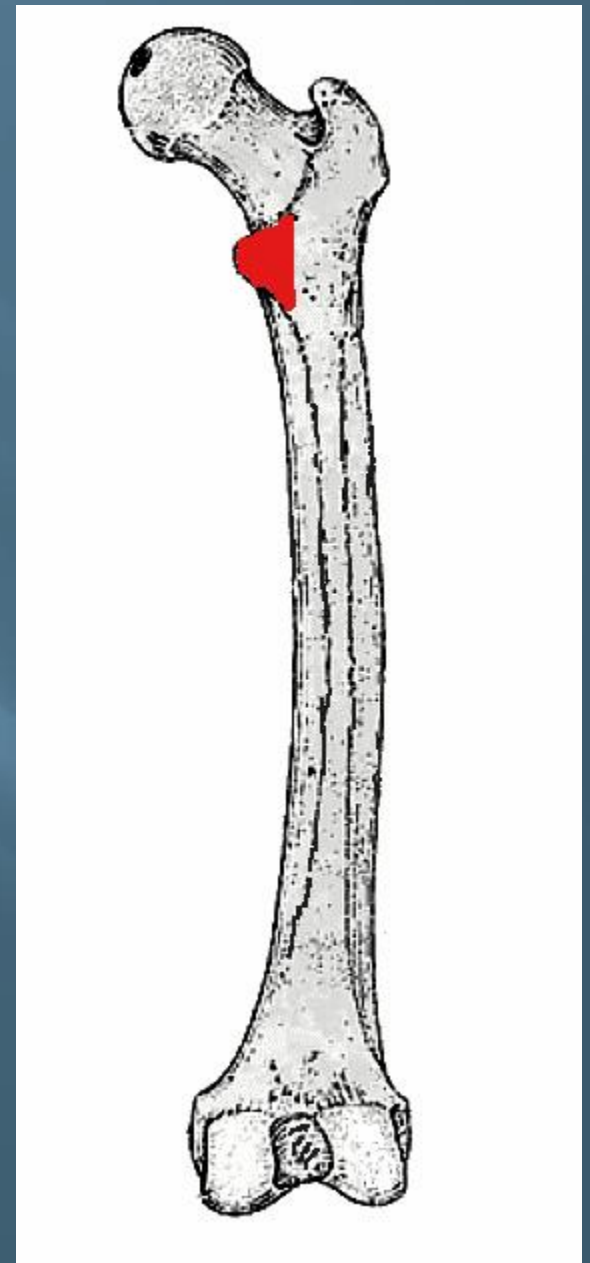
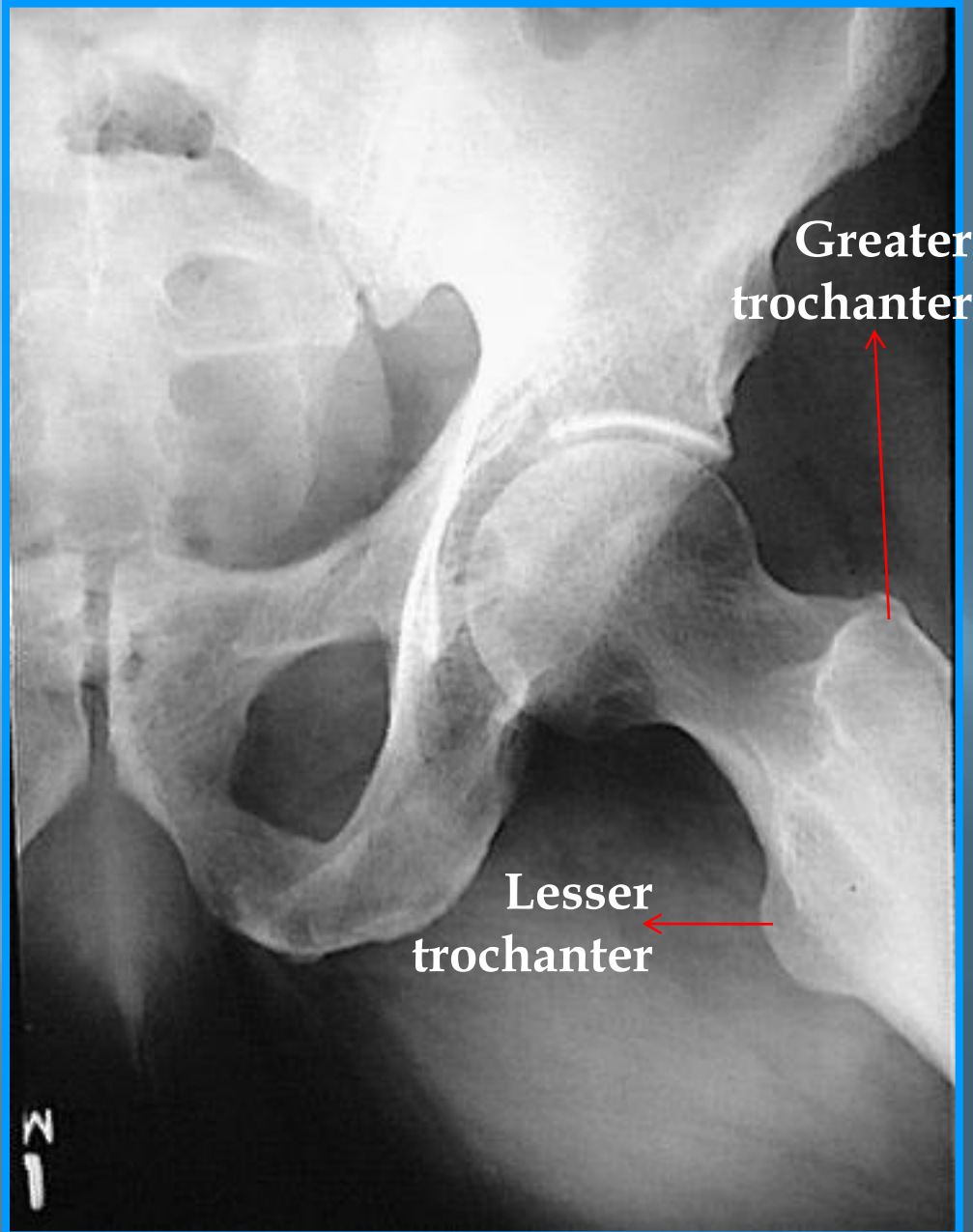
Head

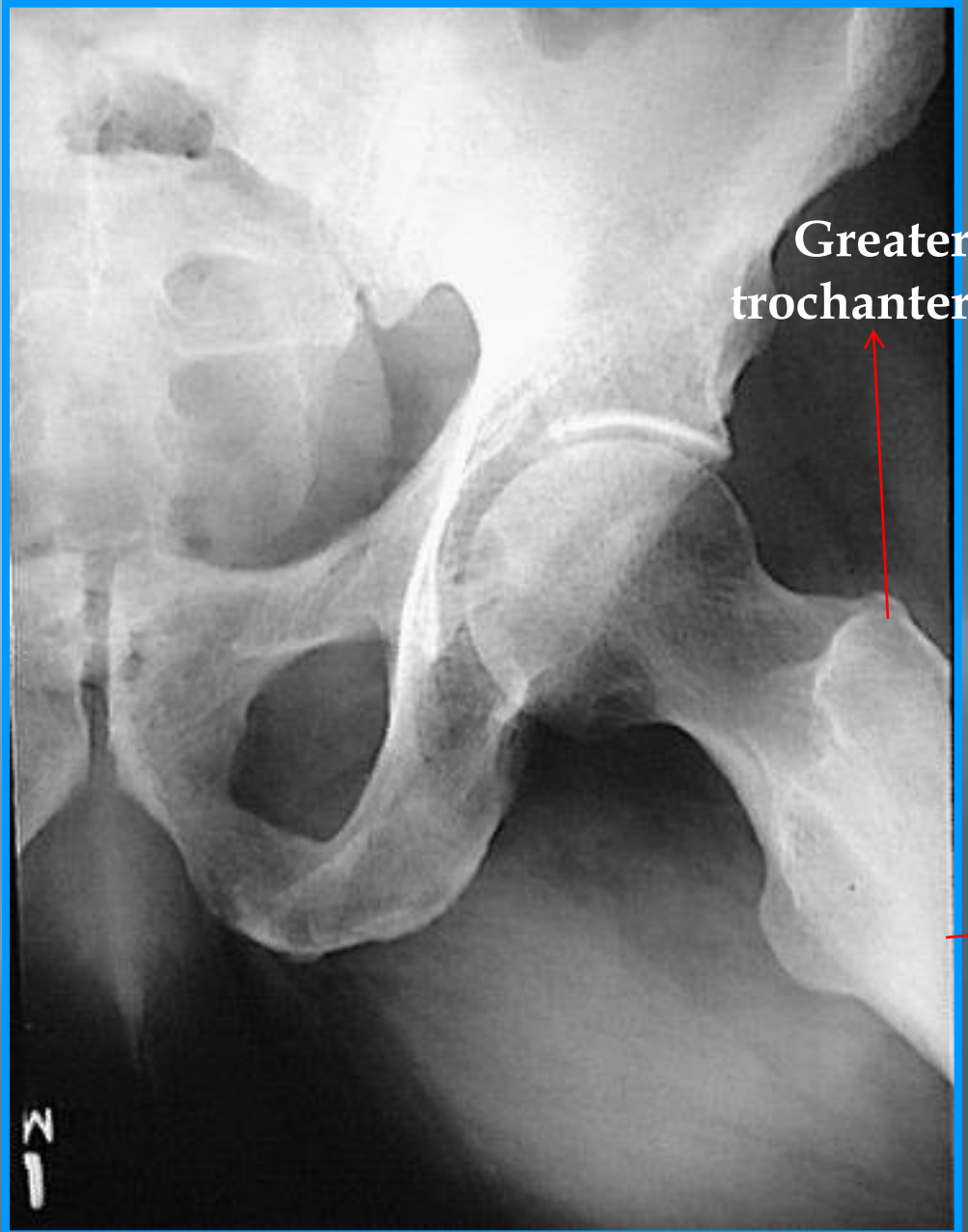Neck



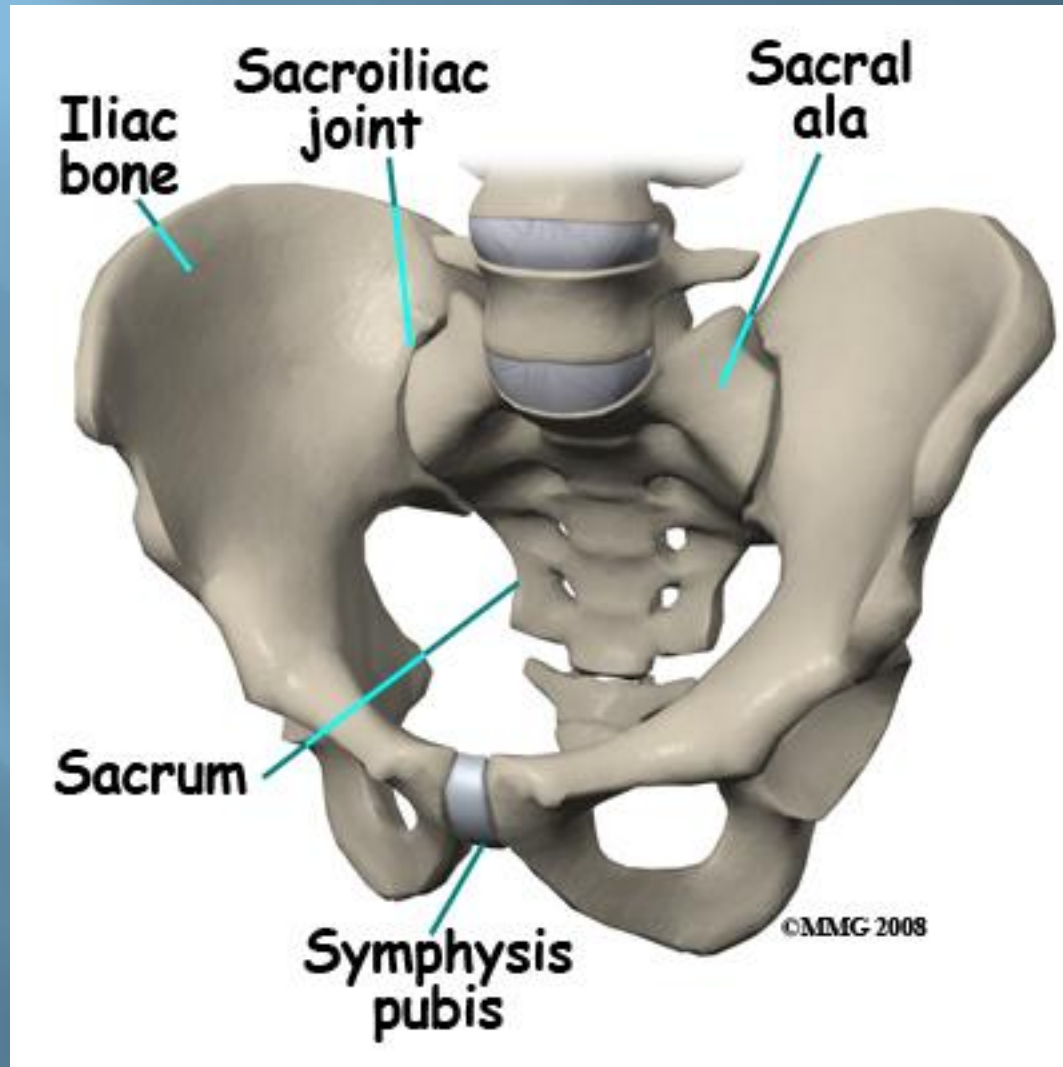
Femur





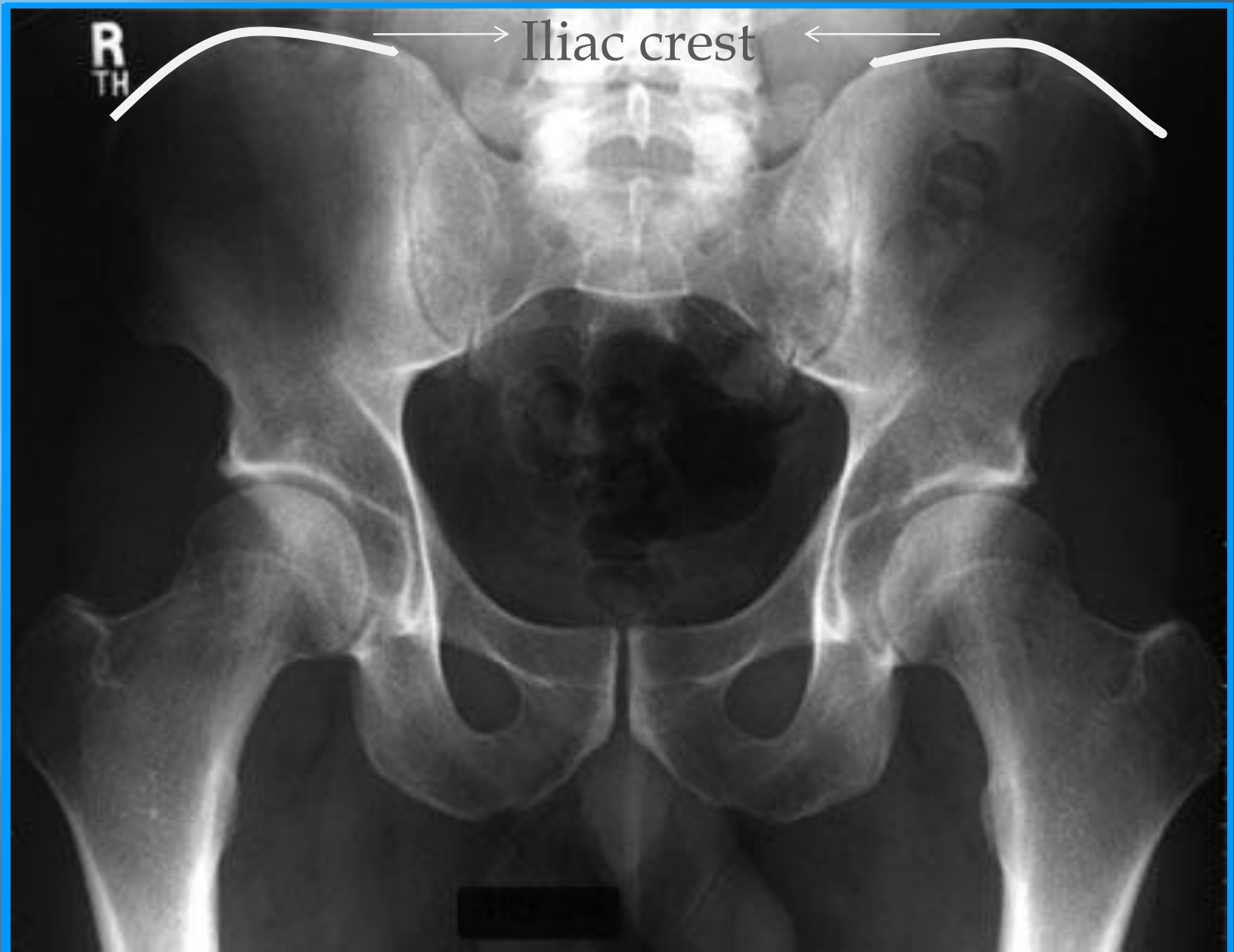

Pelvis

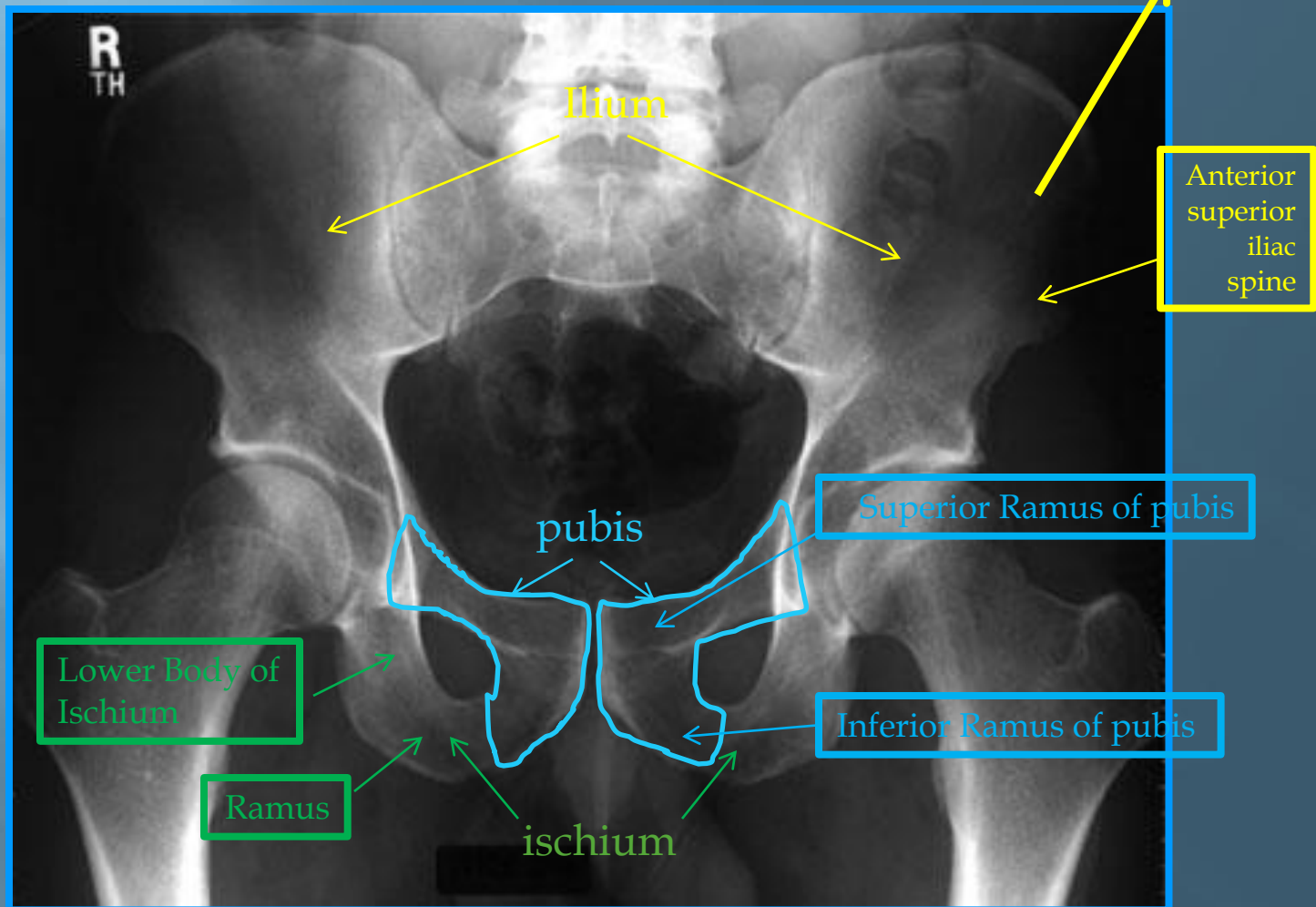


Pelvis,

AP view

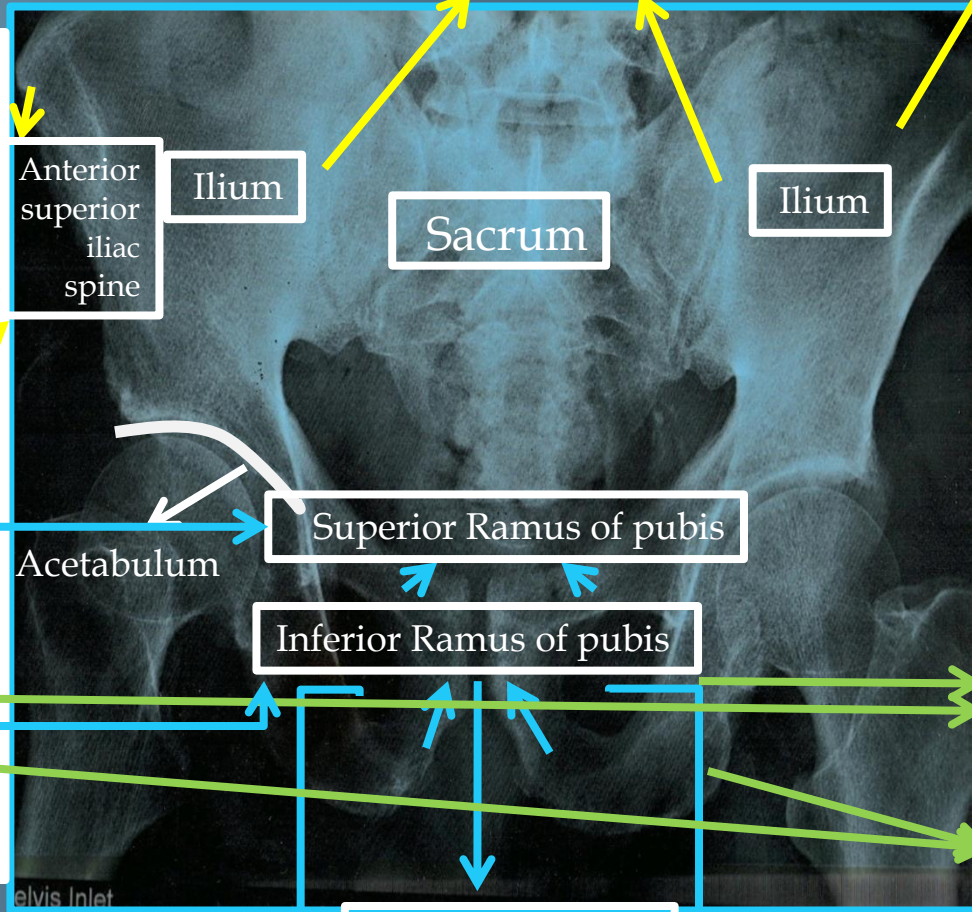
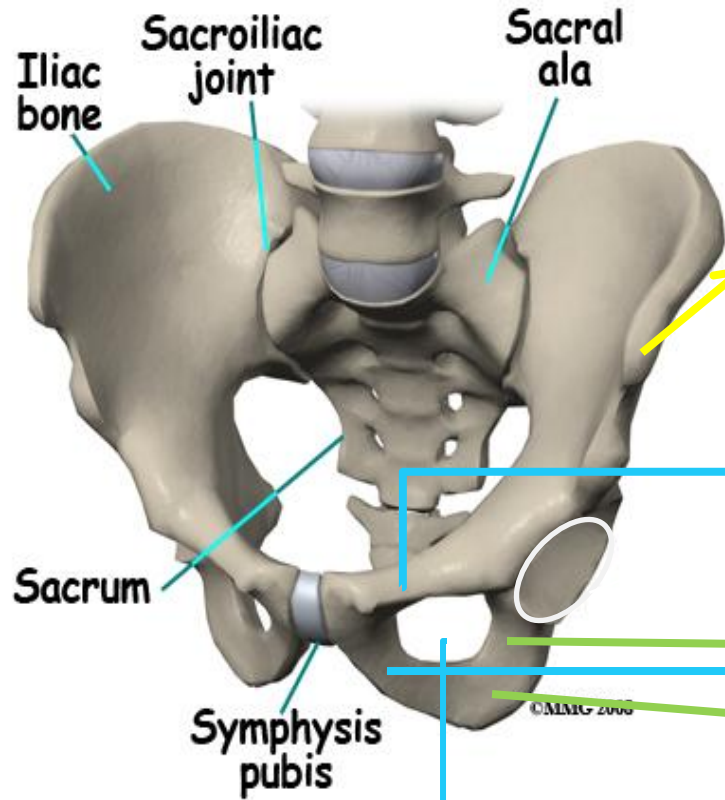


Hip Bone



Pelvis AP male m

- pubis
- ilium
- Ischeum



Ala ,wing of ilium

Sacroiliac joints

Anterior superior iliac spine

Ilium

Sacrum

Ilium

Superior Ramus of pubis

Inferior Ramus of pubis

Lower Body of Ischium

Ramus

Symphysis pubis

Obturator foramen

Pelvis AP

male

- pubis
- ilium
- Ischeum

Ala ,wing of ilium

Sacroiliac joints

Anterior superior
iliac spine

Ilium

Sacrum

Ilium

Acetabulum

Superior Ramus of pubis

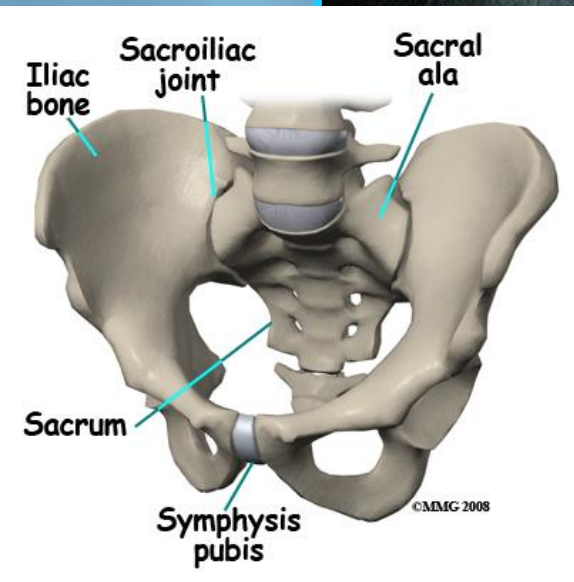
Inferior ramus of pubis

Symphysis pubis

Obturator foramen

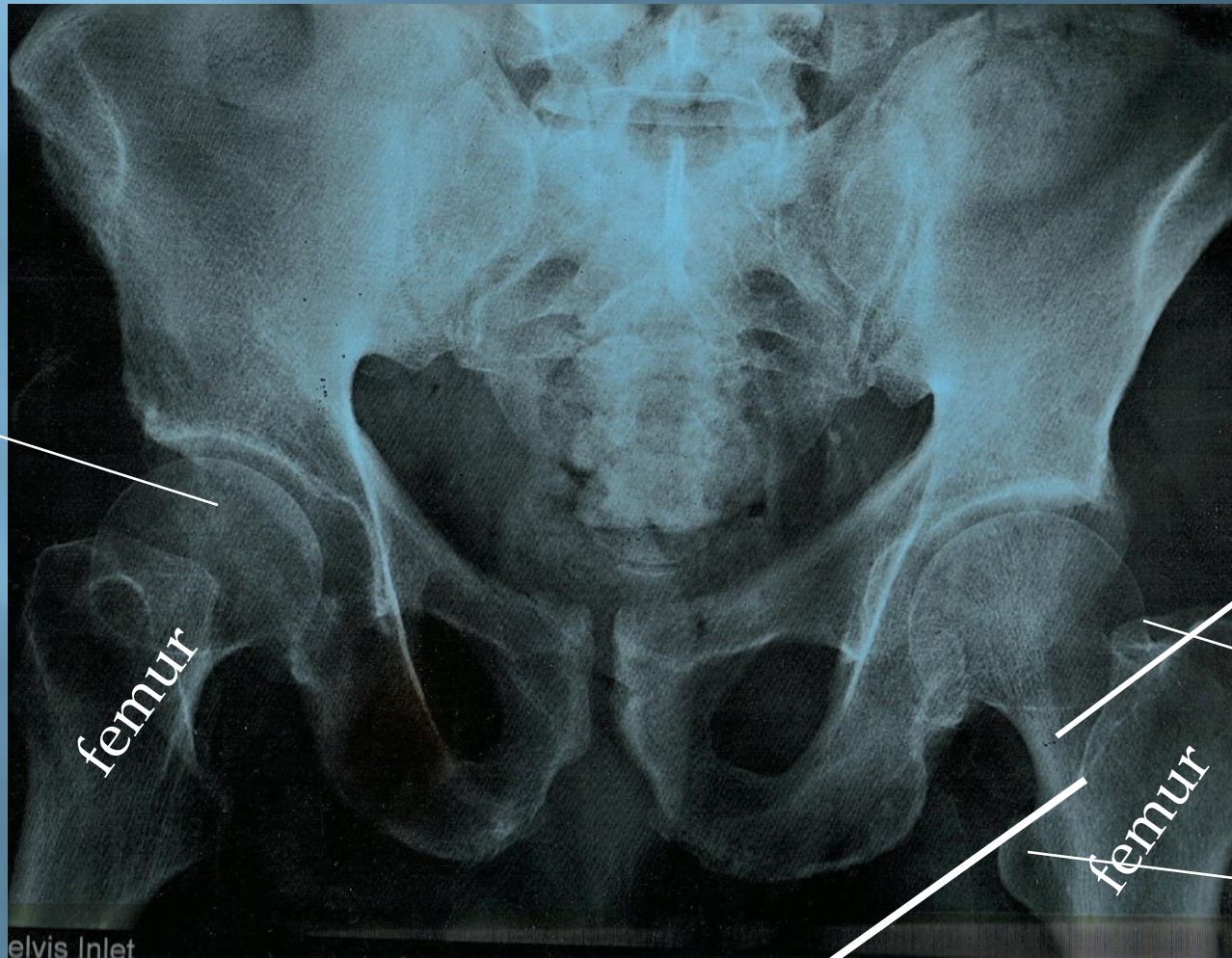
Lower
Body of
Ischium

Ramus



head

femur



neck

Greater
trochanter

Lesser
Trochanter

Intertrochanteric crest

elvis Inlet