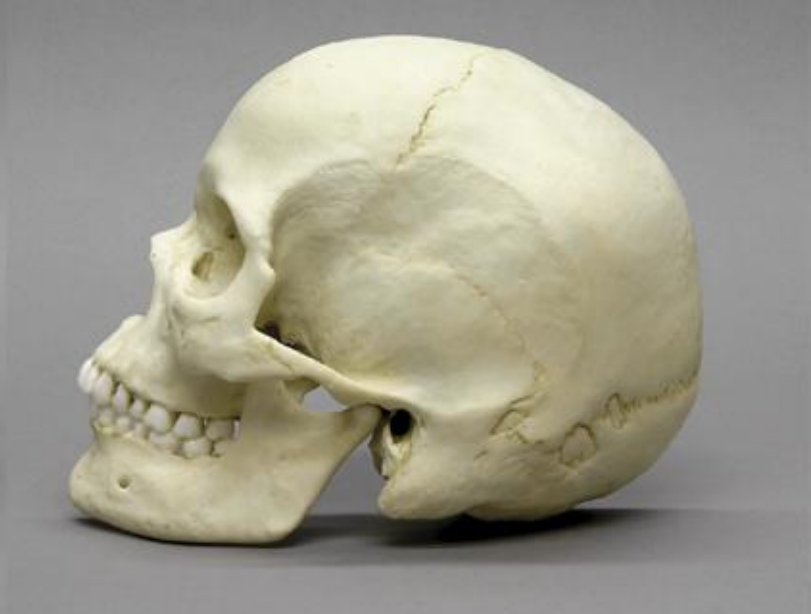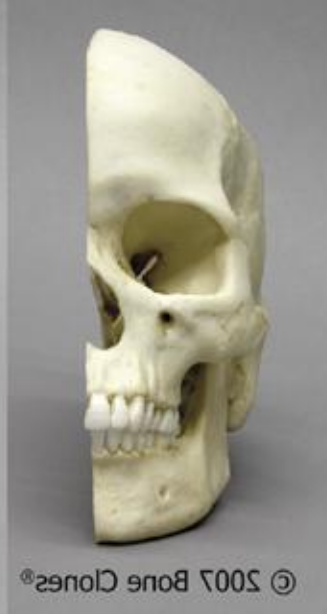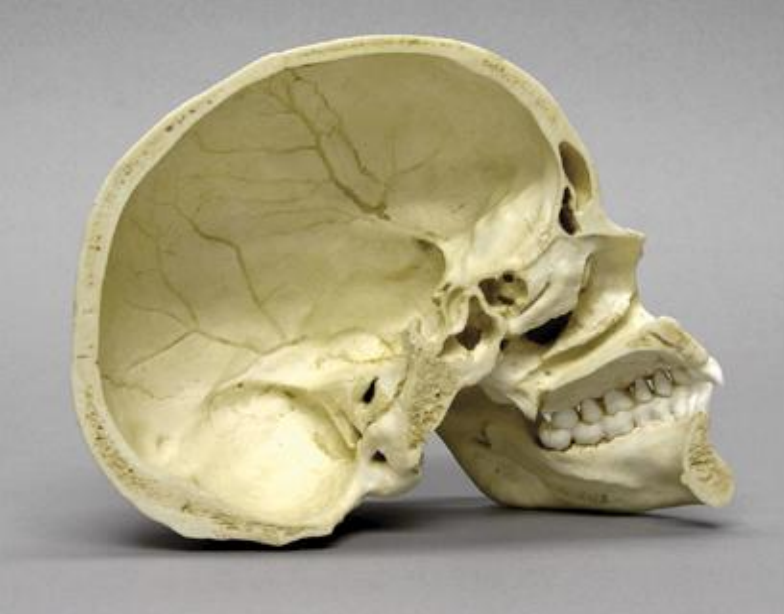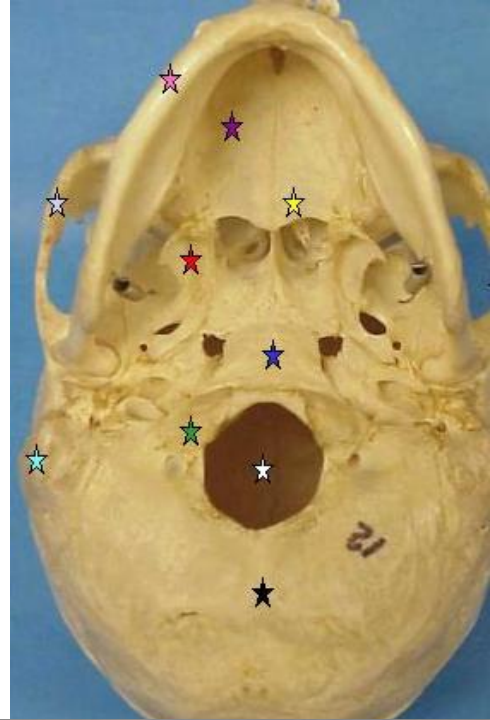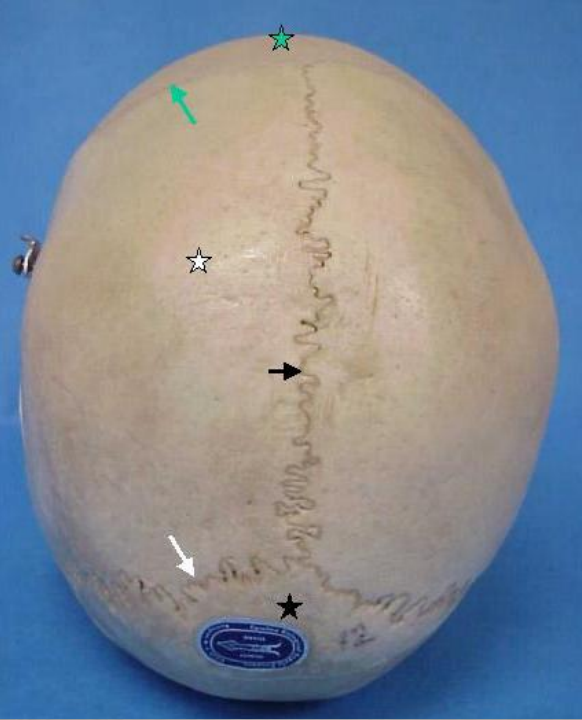


skull

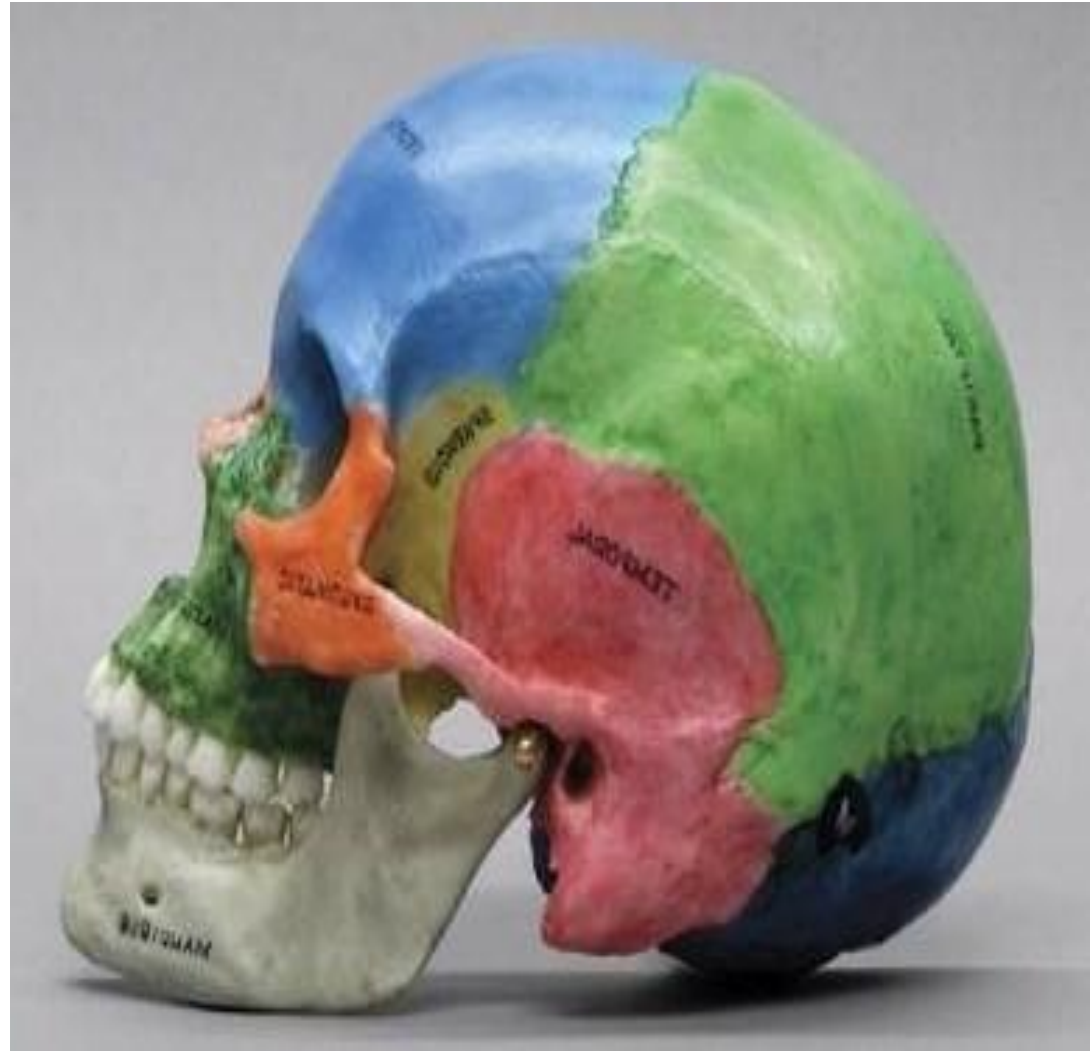

Facial bones

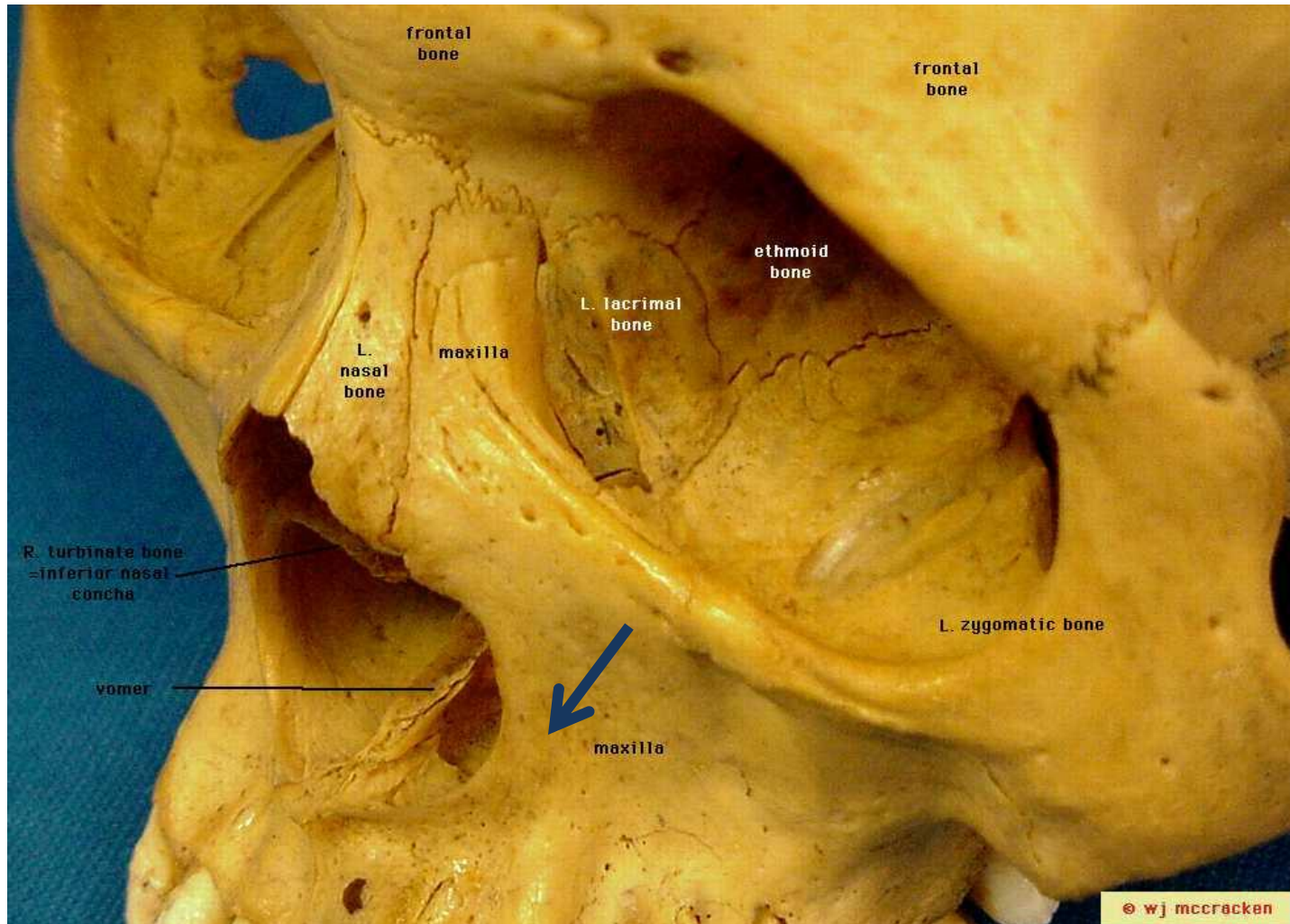
There are 14 Facial bones:

- 2 Maxillary bones
- 2 zygomatic Bone
- 2 Lacrimal bones
- 2 Nasal bones
- 2 Inferior nasal conchae
- 2 palatine bones
- 1 Vomer
- 1 Mandible (lower jaw)

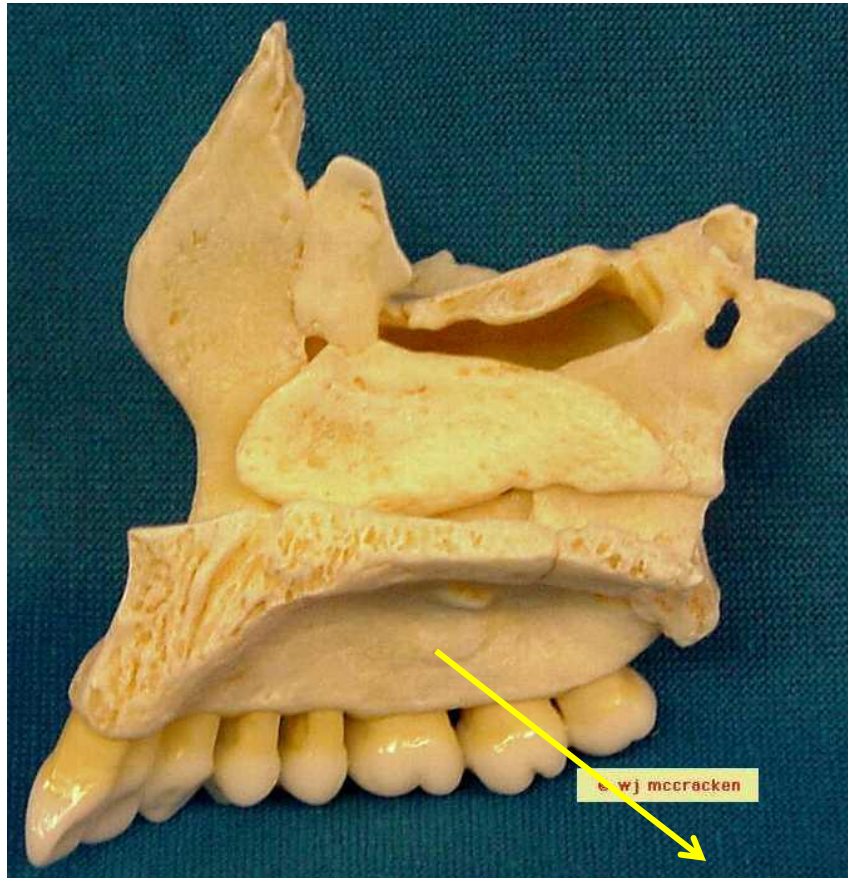
14 Total



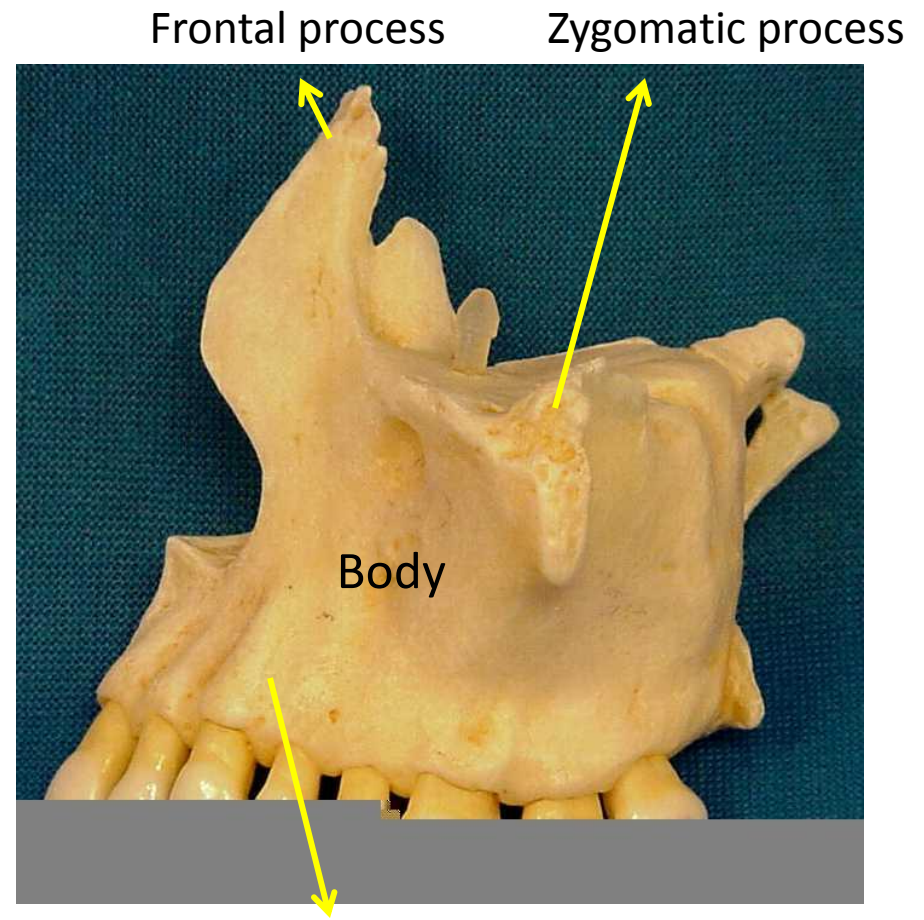
Maxillae



Maxillae

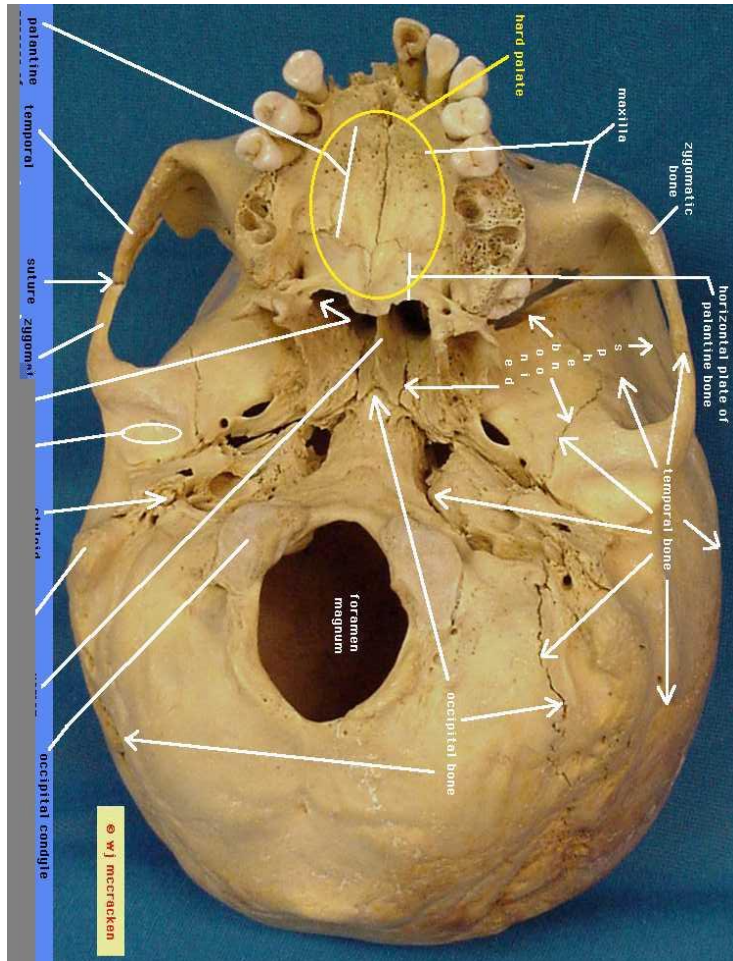


Palatine process

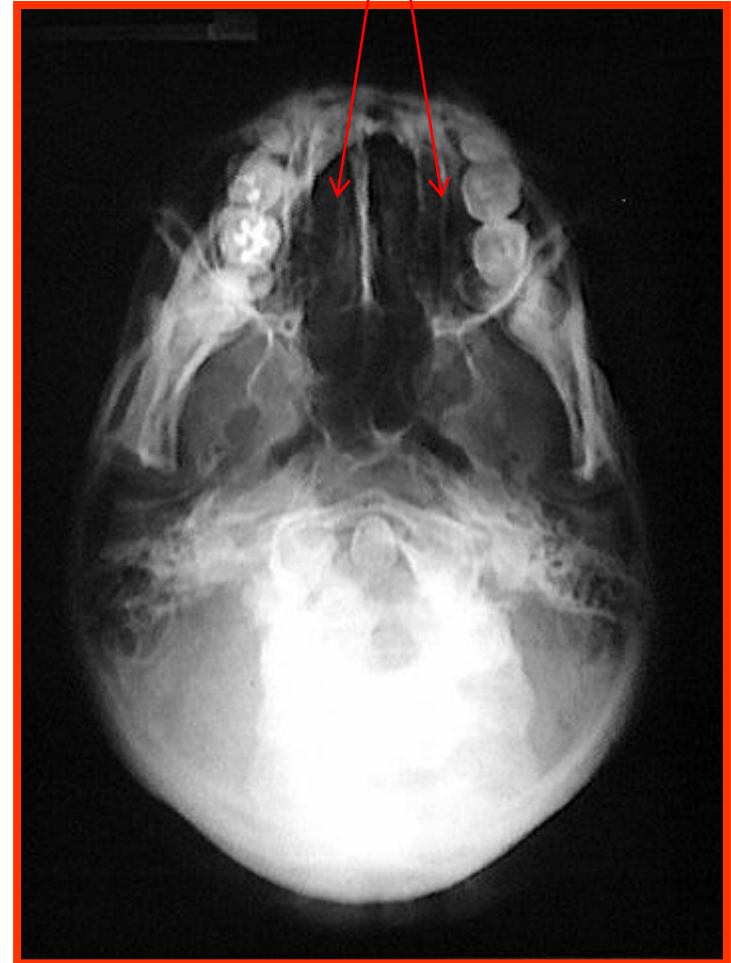

Alveolar process

Submentovertical view

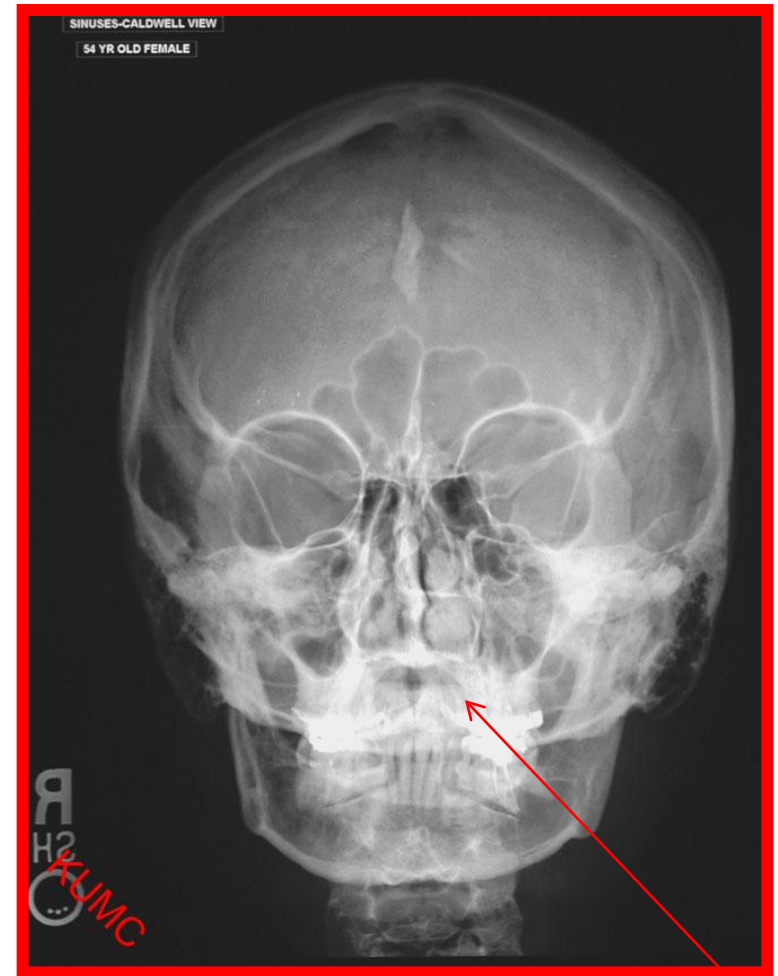
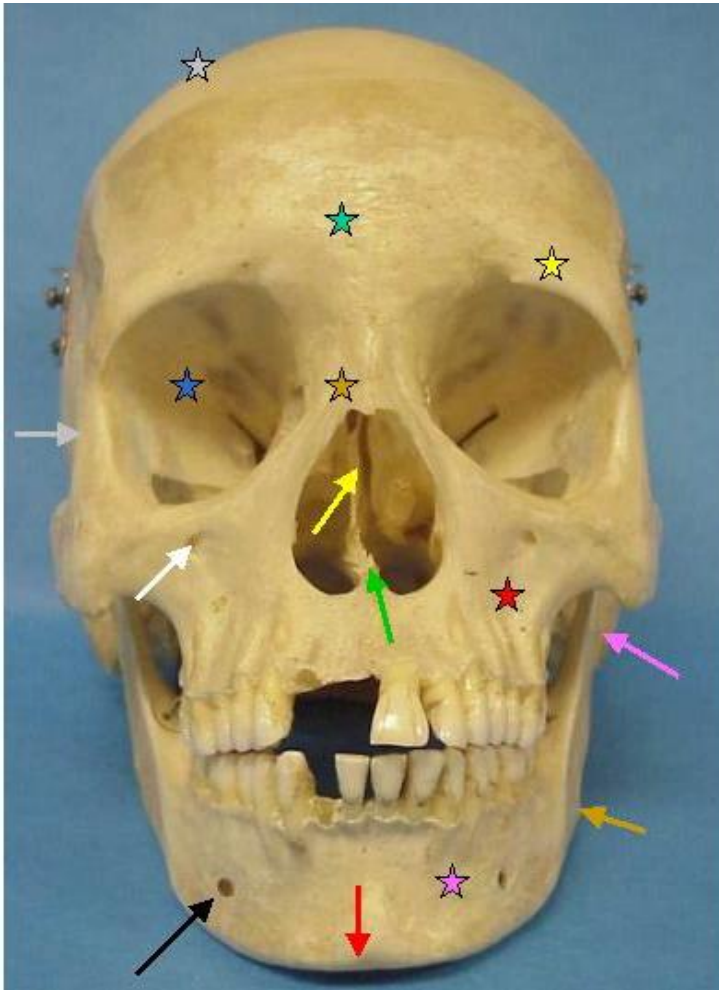


Palatine process of maxilla



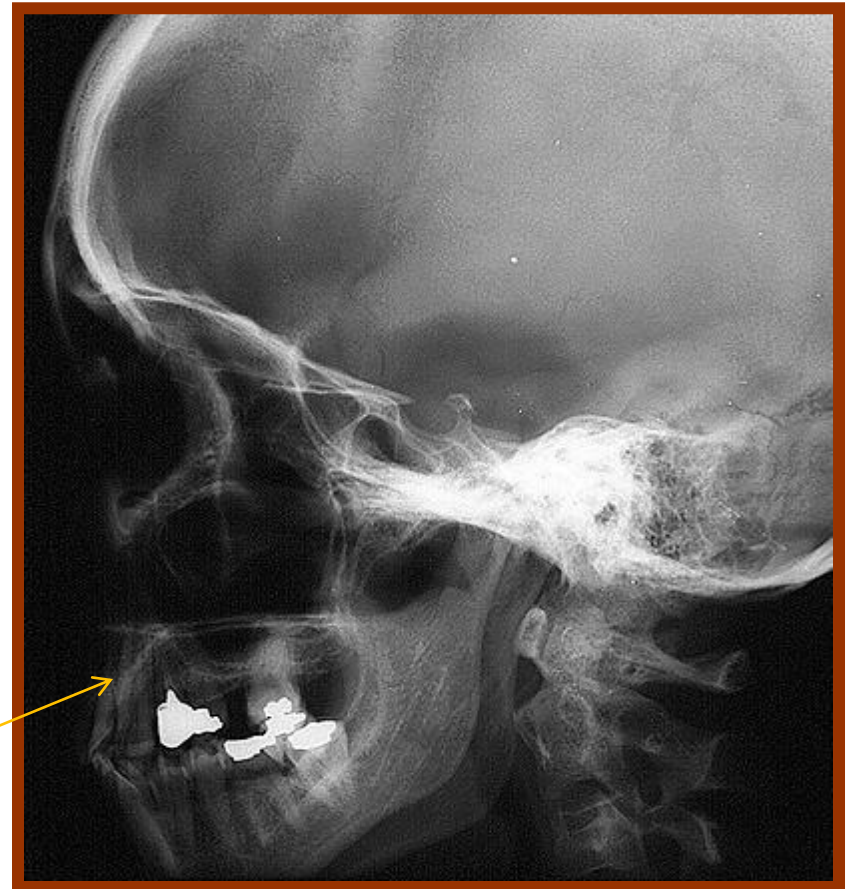
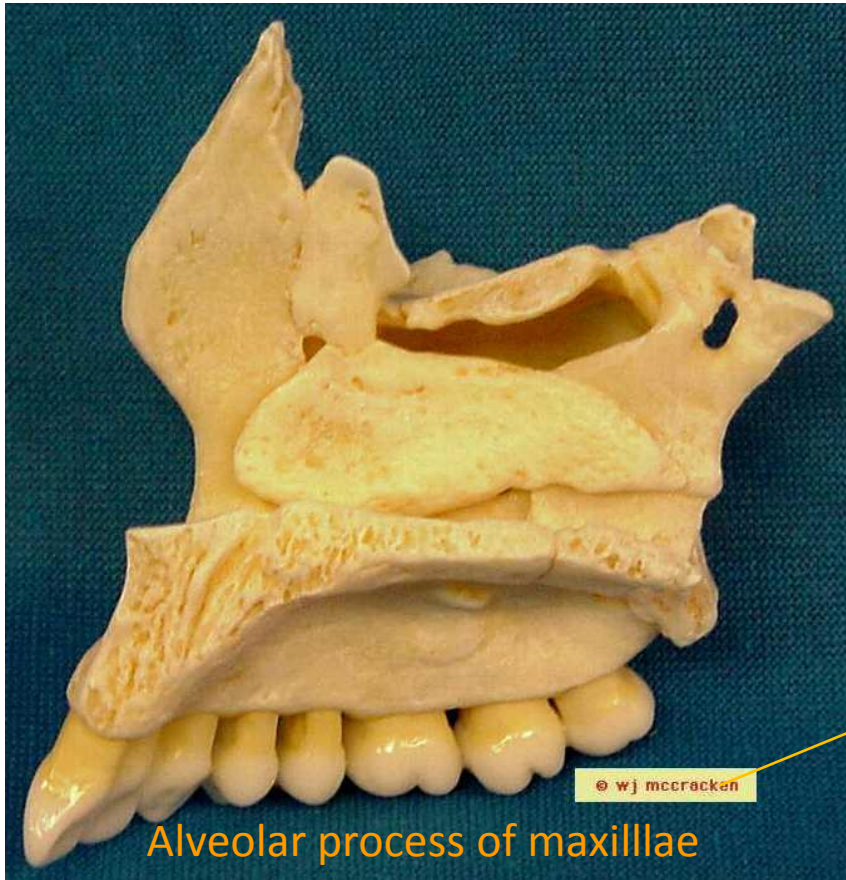
Caldwell view

PA with angle

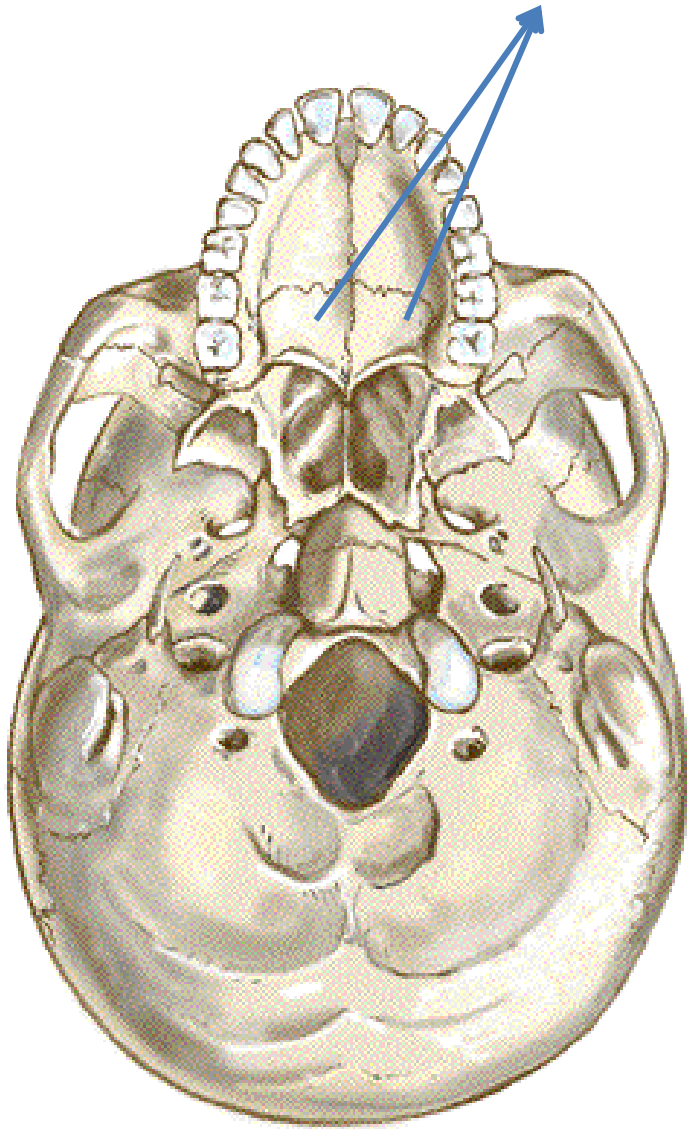


Alveolar process of maxilla

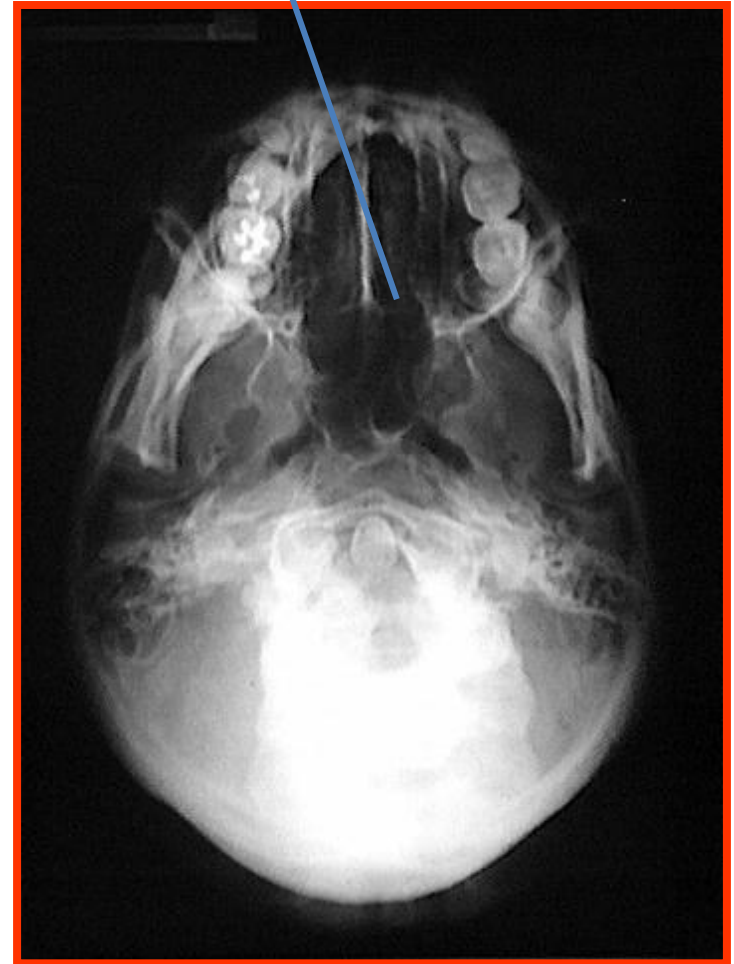
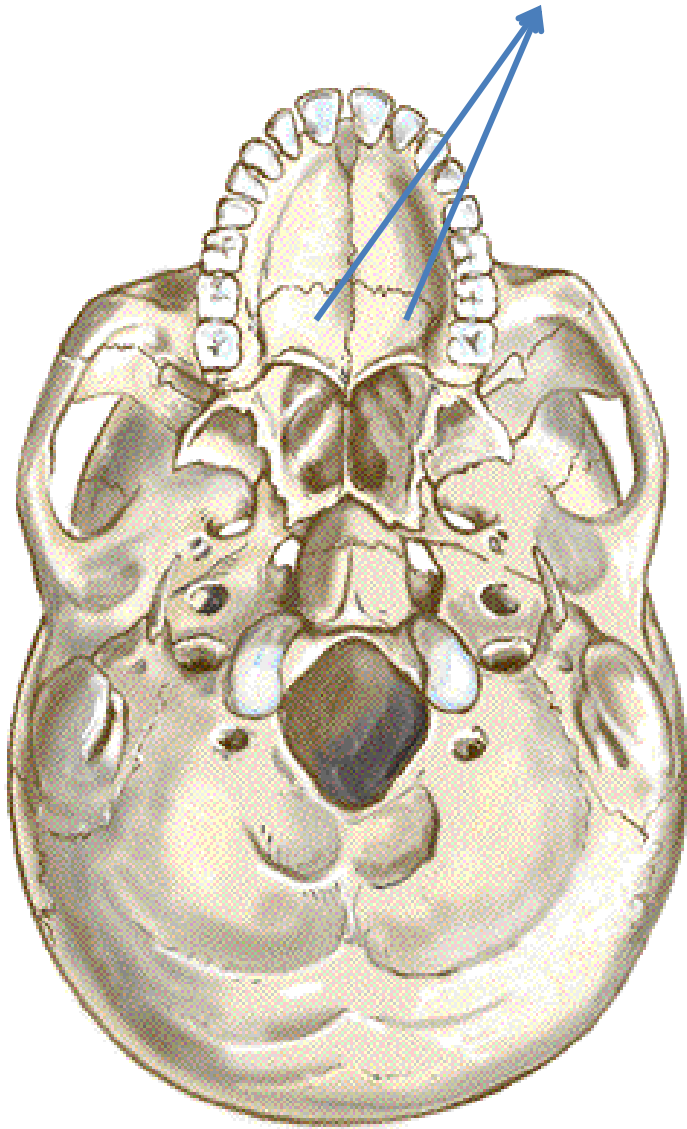
Lateral



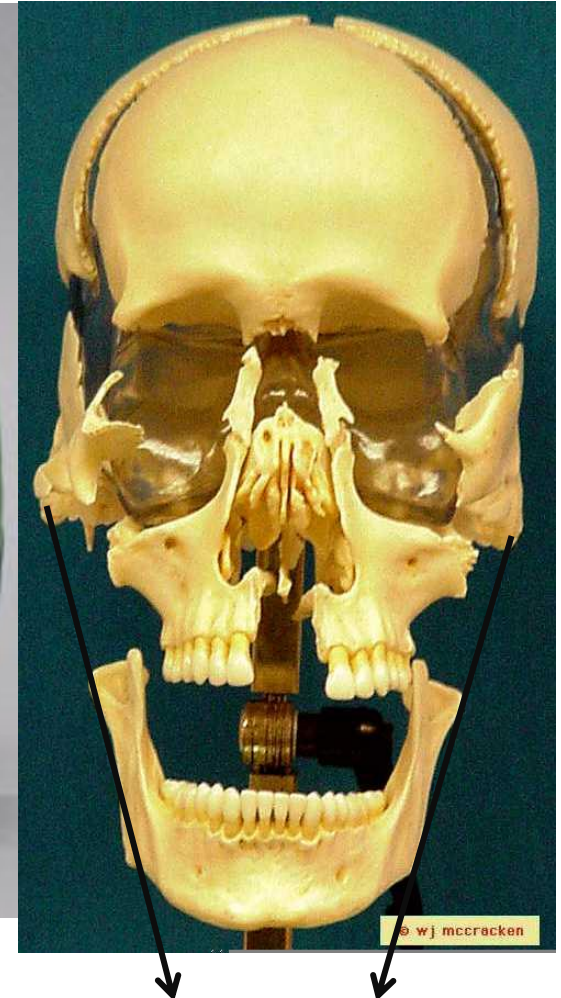
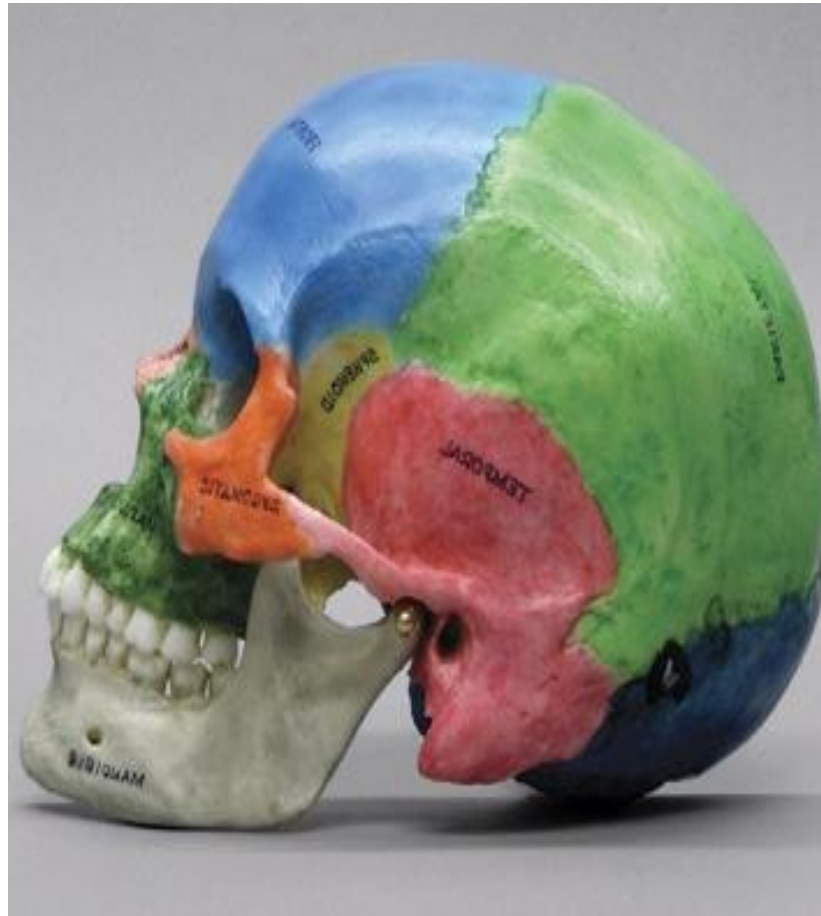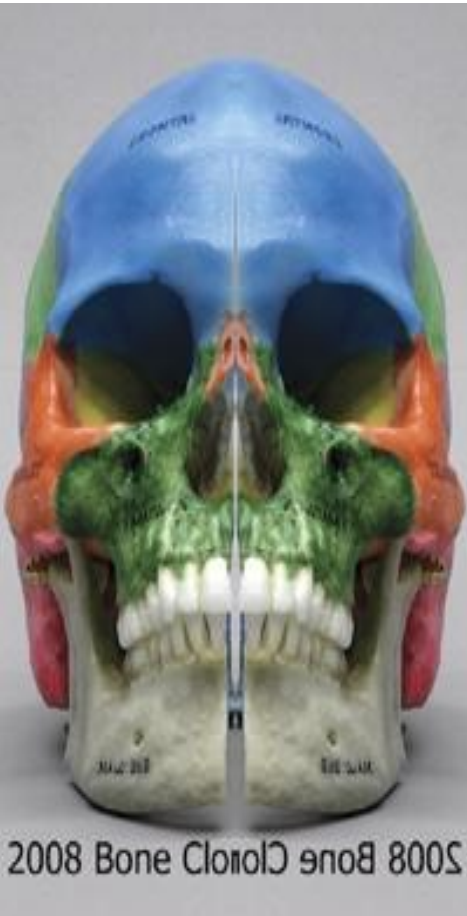Palatine Bones



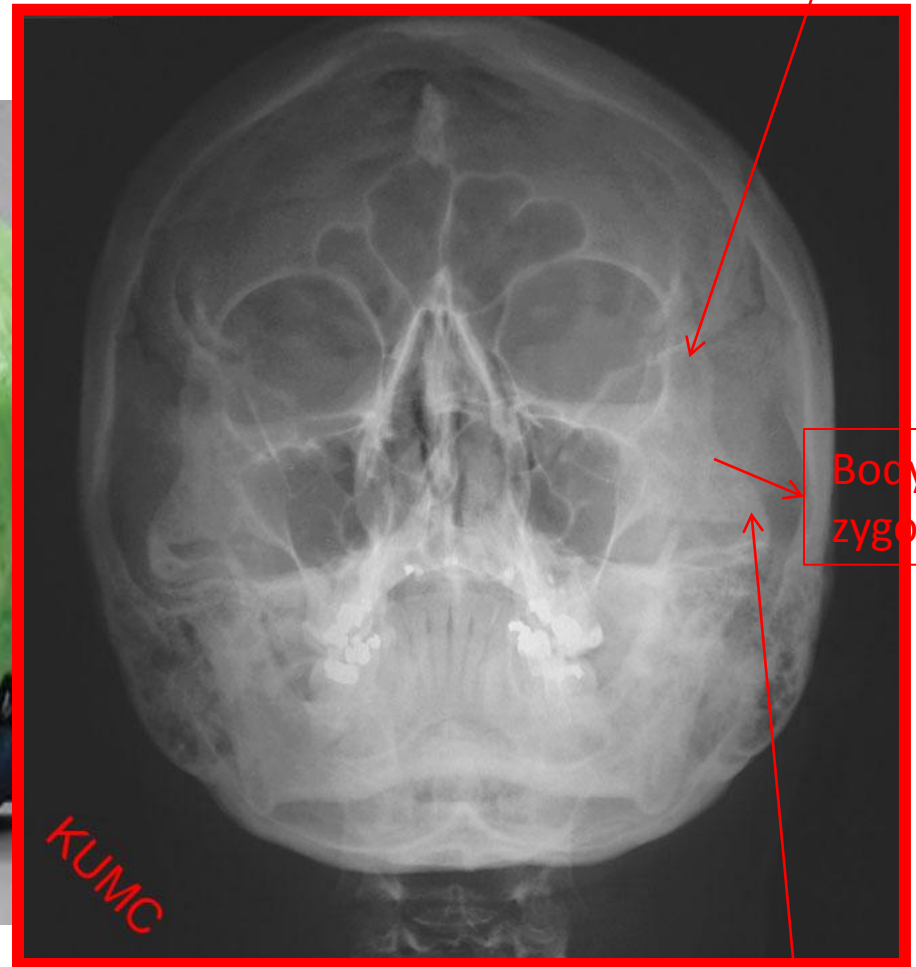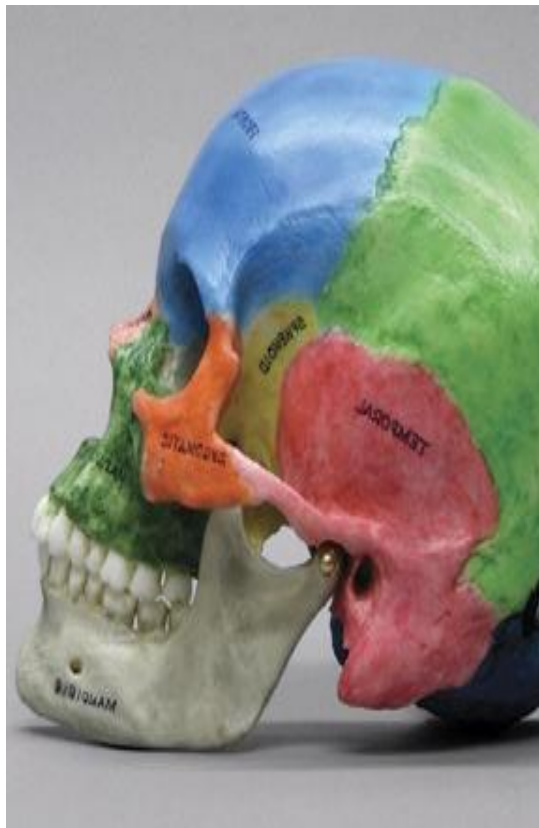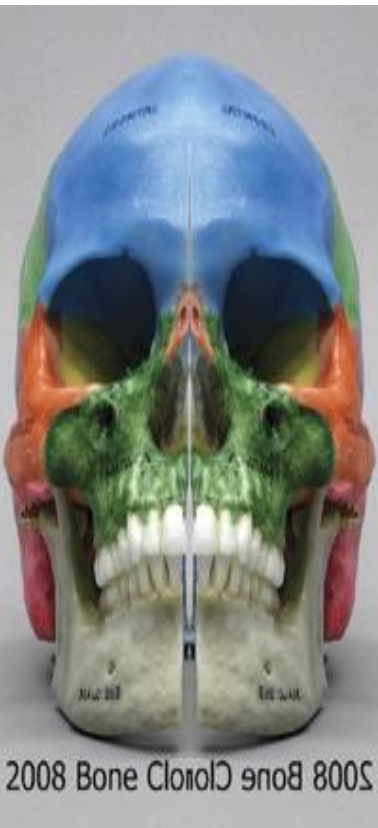Palatine Bones



Zygomatic bone



waters view

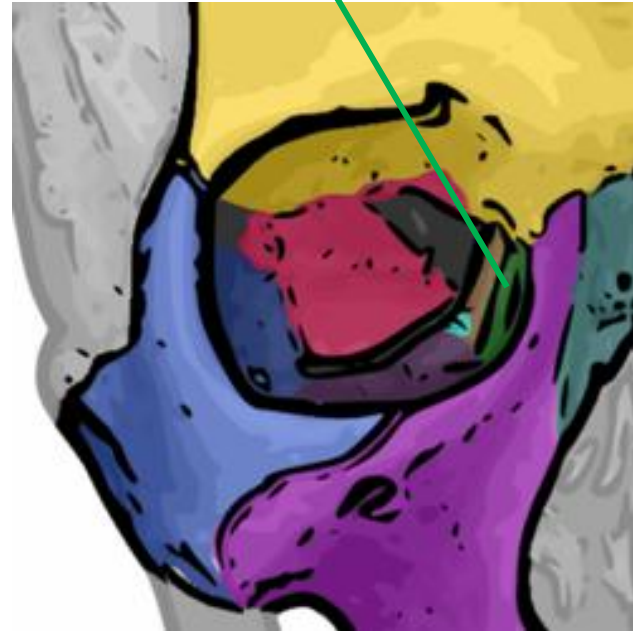
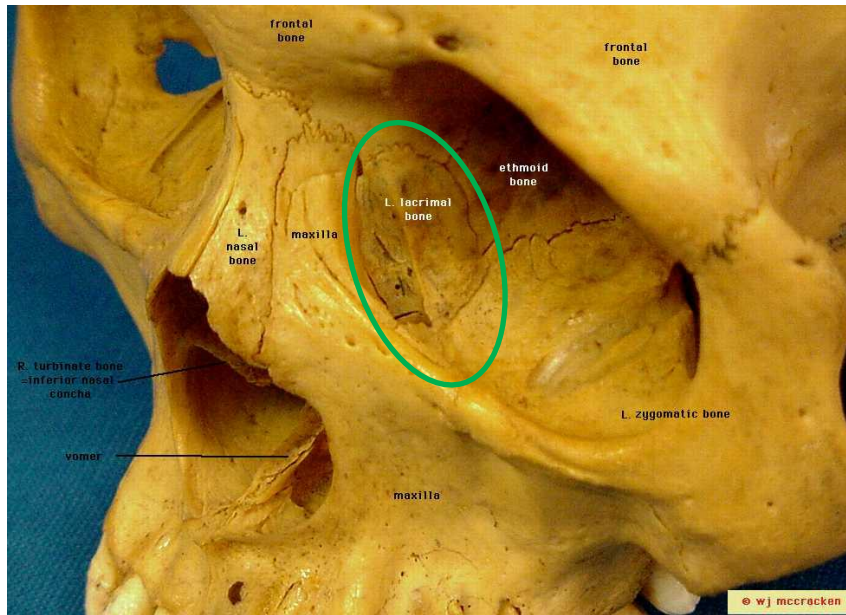


Frontal process of zygomatic

Body of zygoma

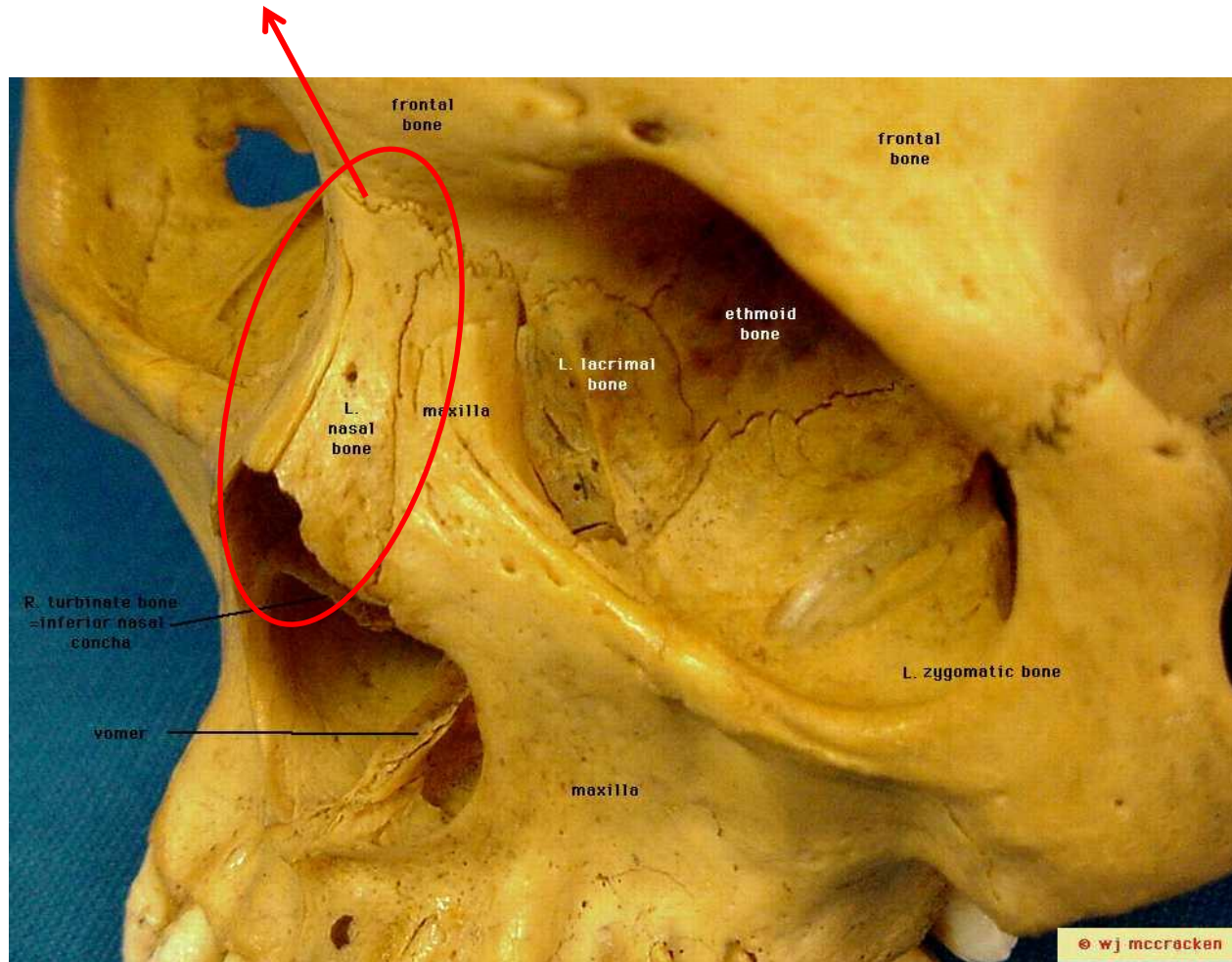
Temporal process of zygomatic bone

Lacrimal



Nasal bone

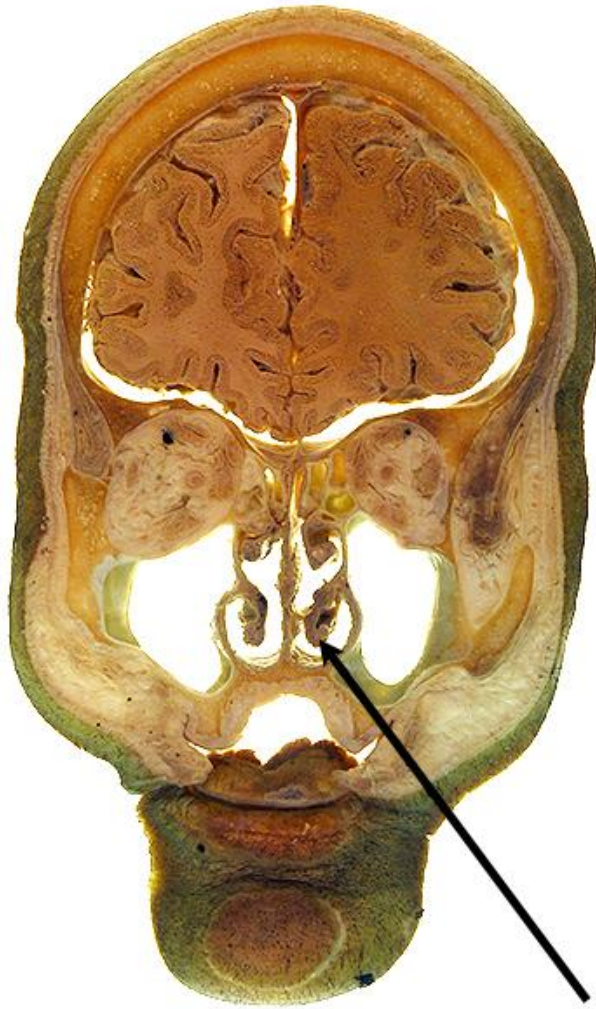
Nasion



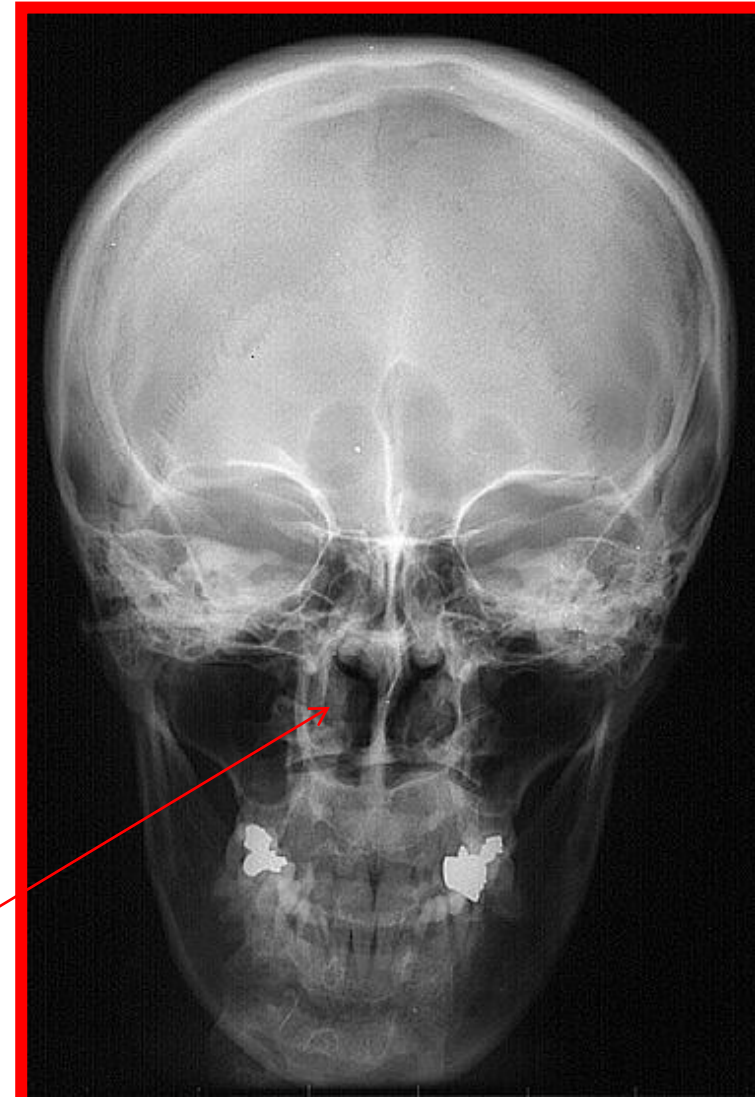
Inferior nasal conchae(turbinates)

Inferior nasal conchae

PA

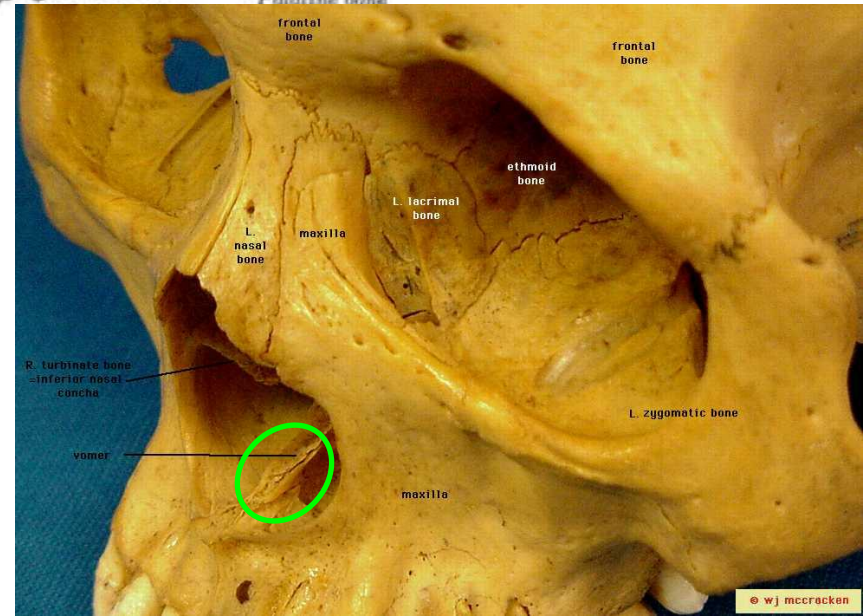
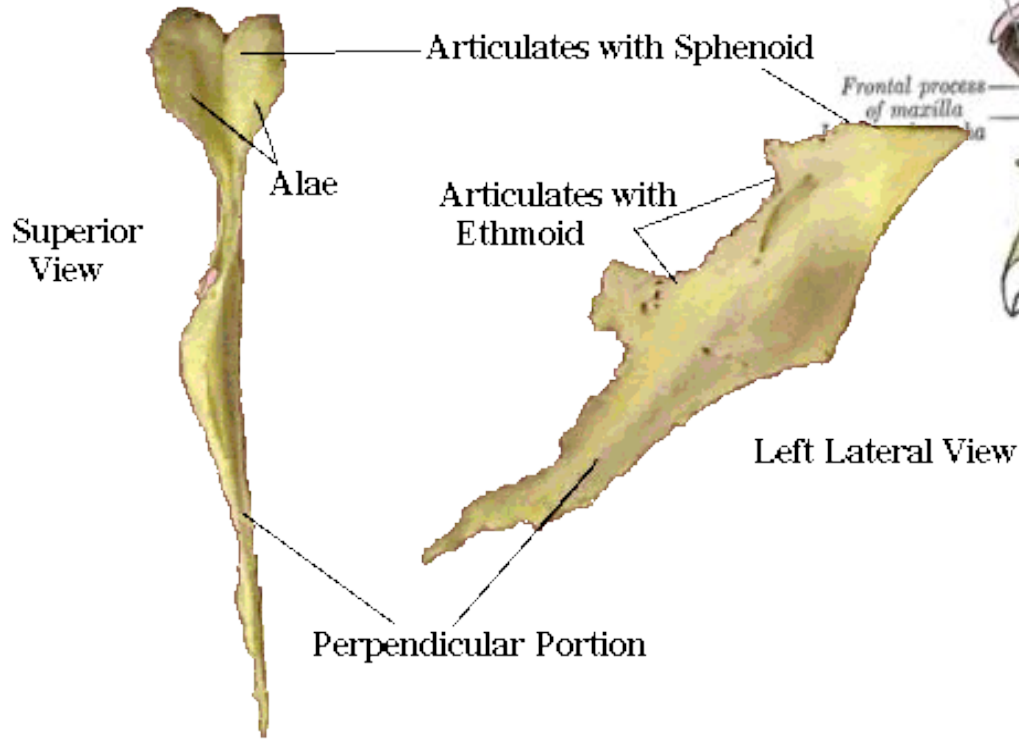
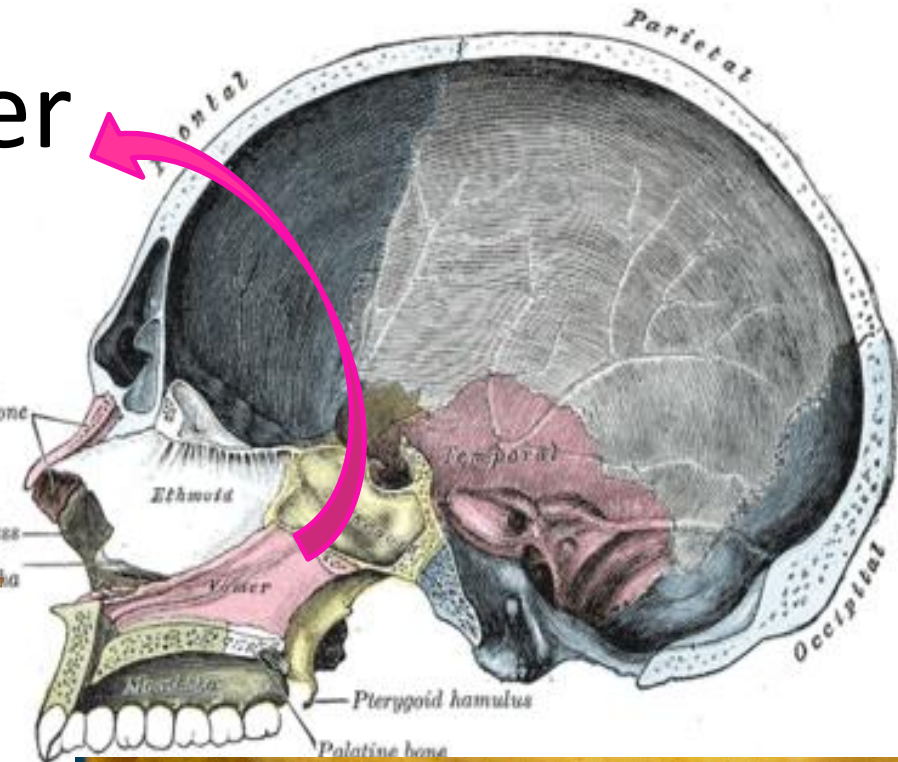


Inferior nasal conche

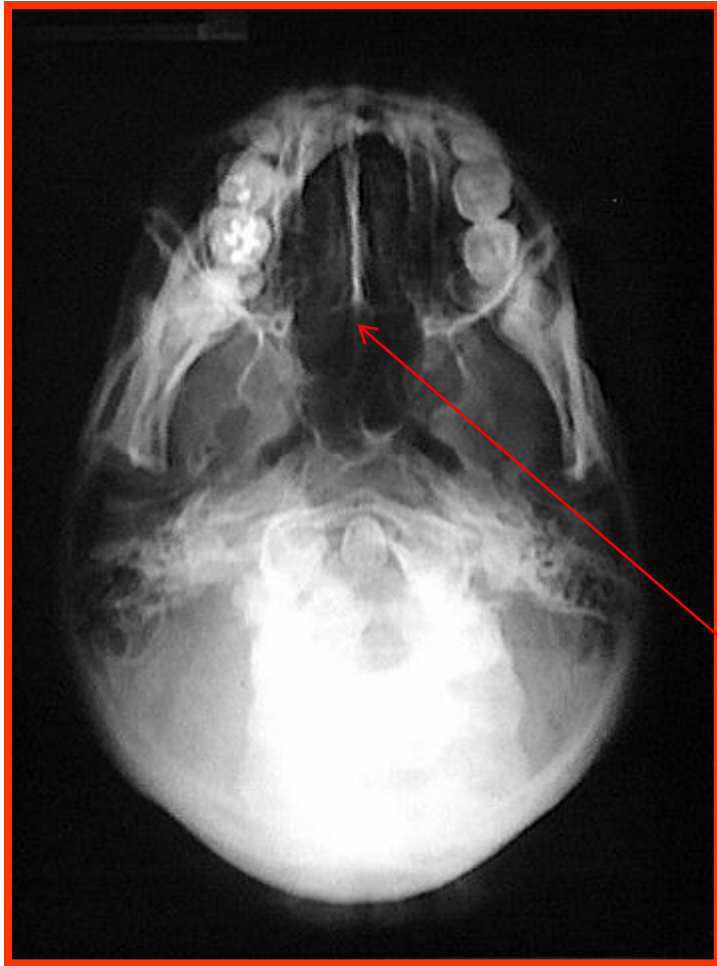

Vomer

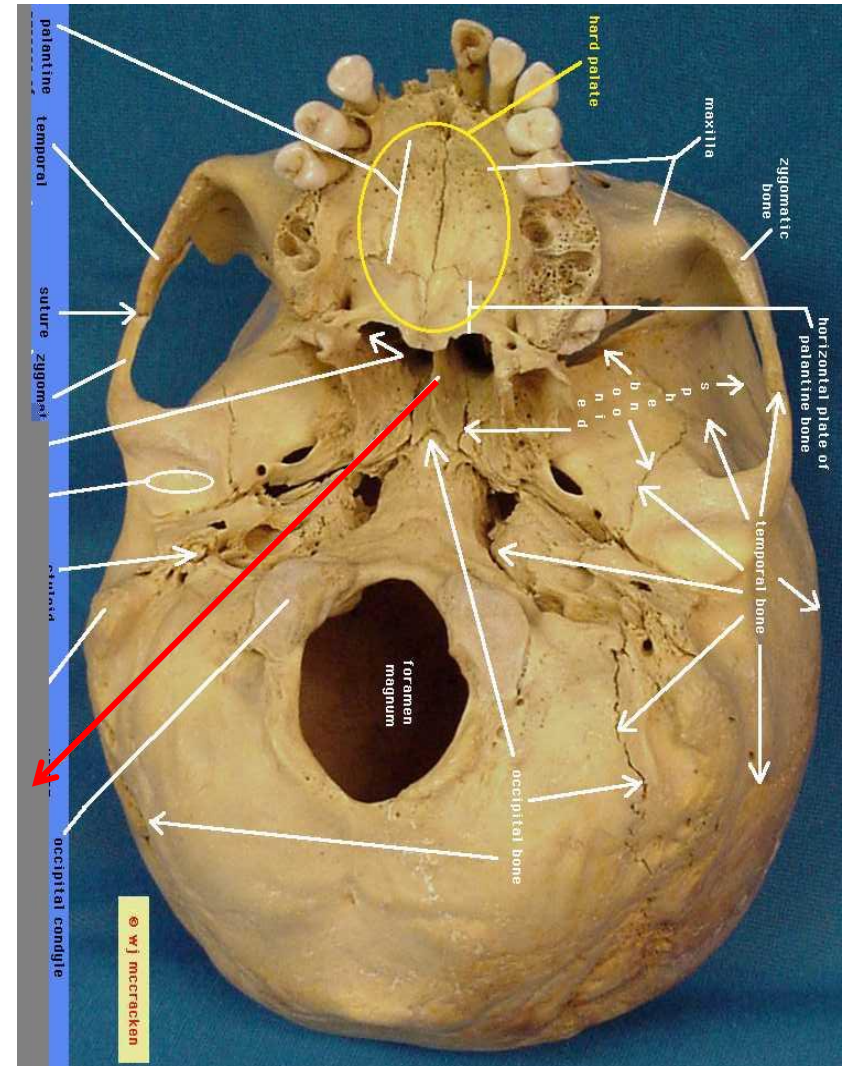
Vomer

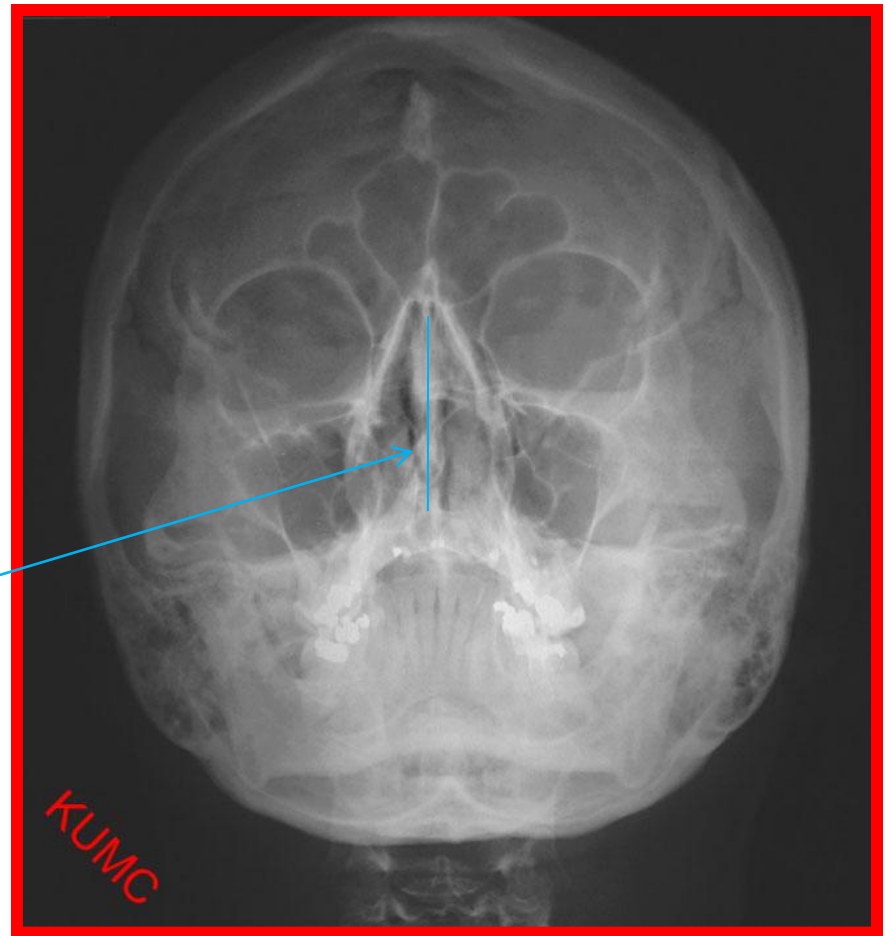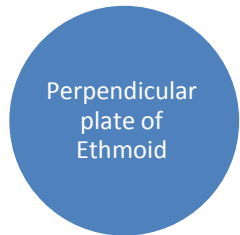


Submentovertical view



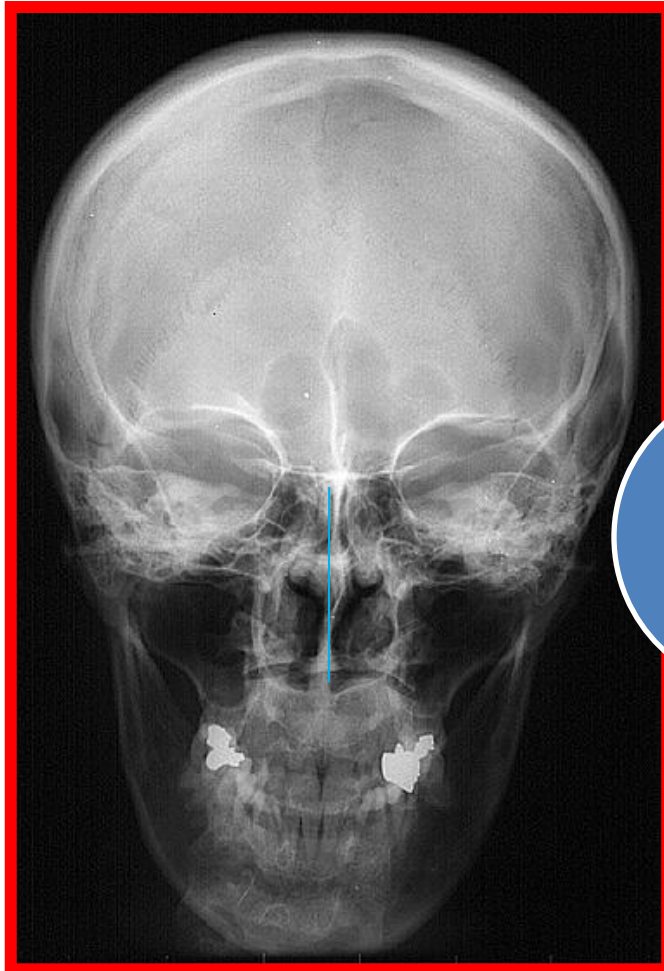
Vomer



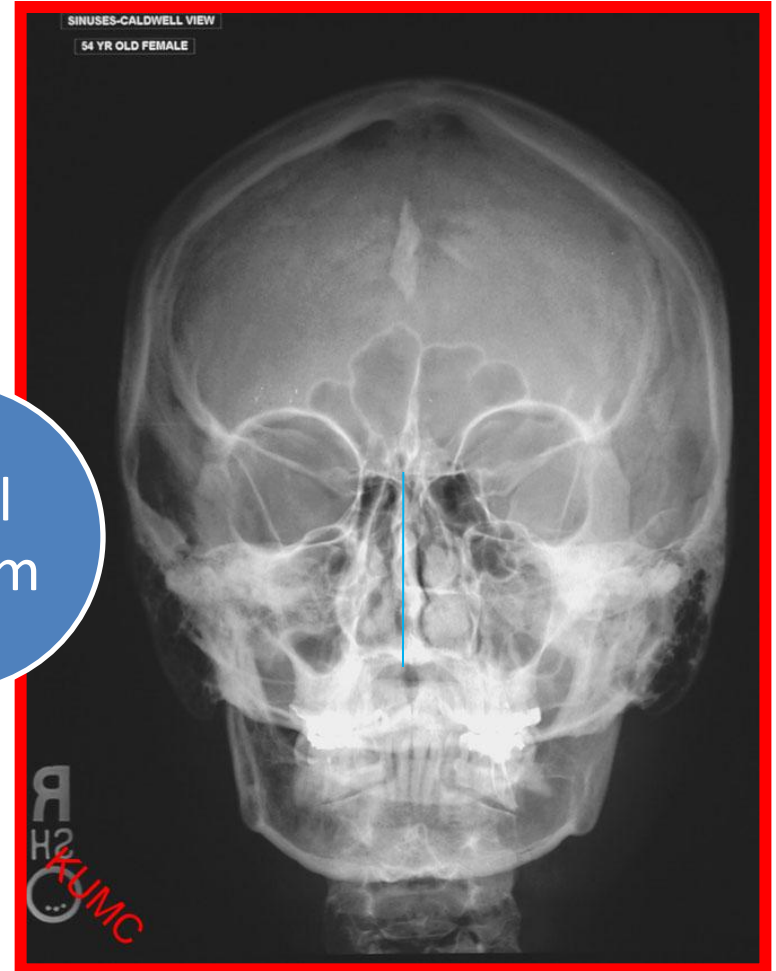


PA

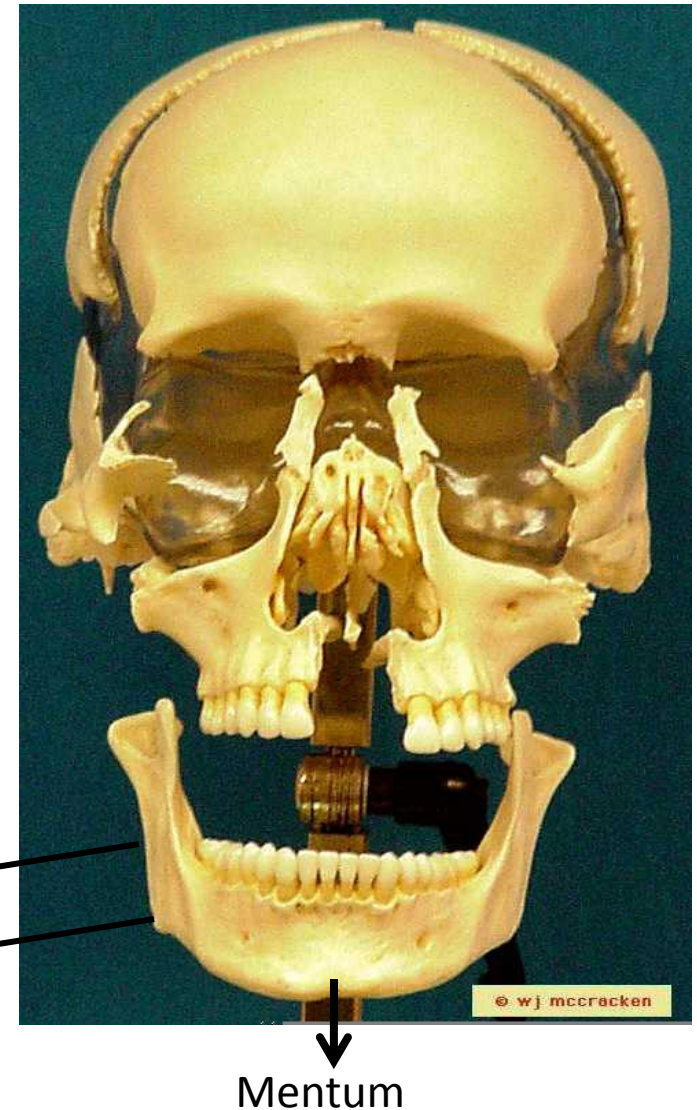
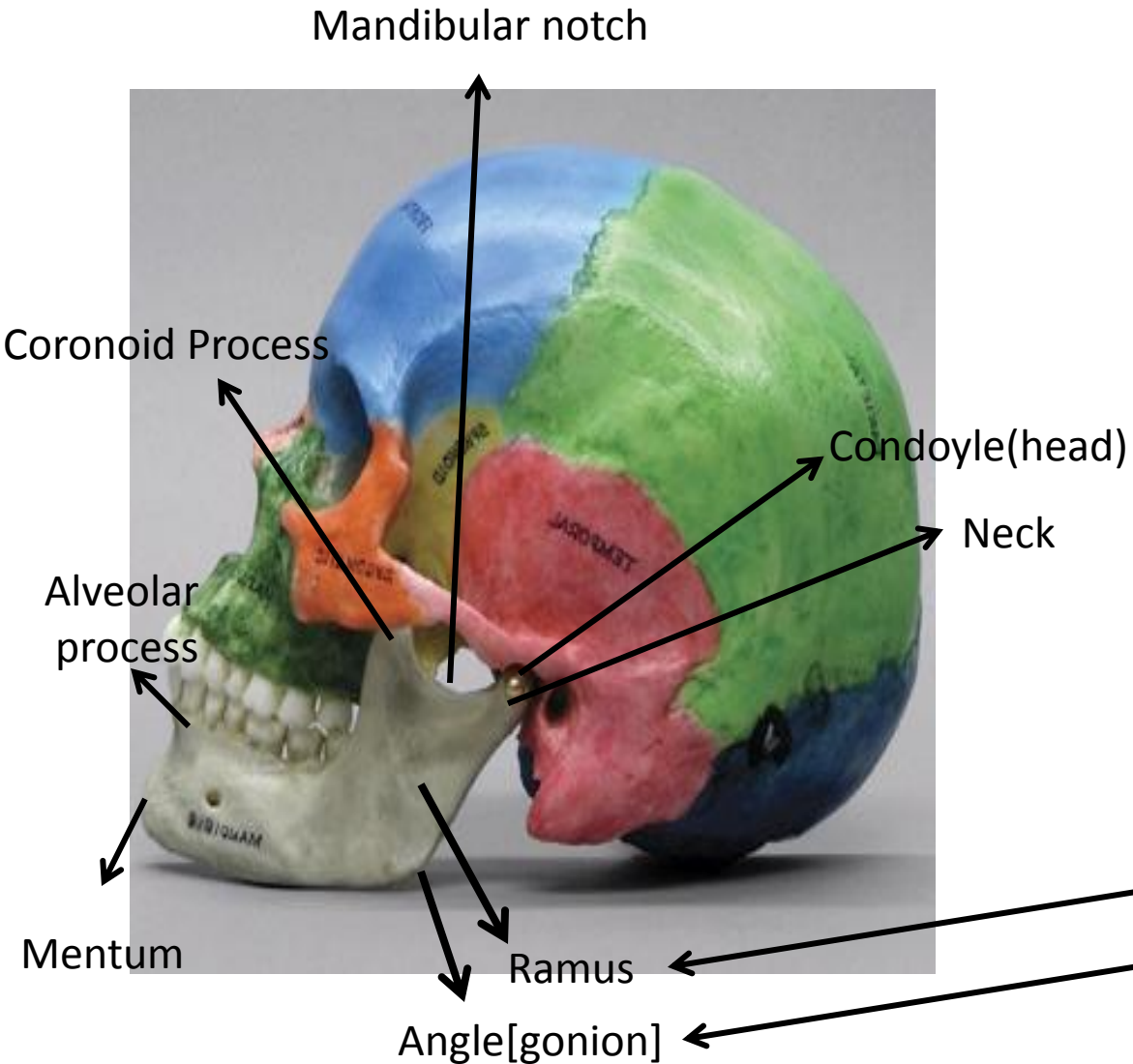
Caldwell view
PA with angle



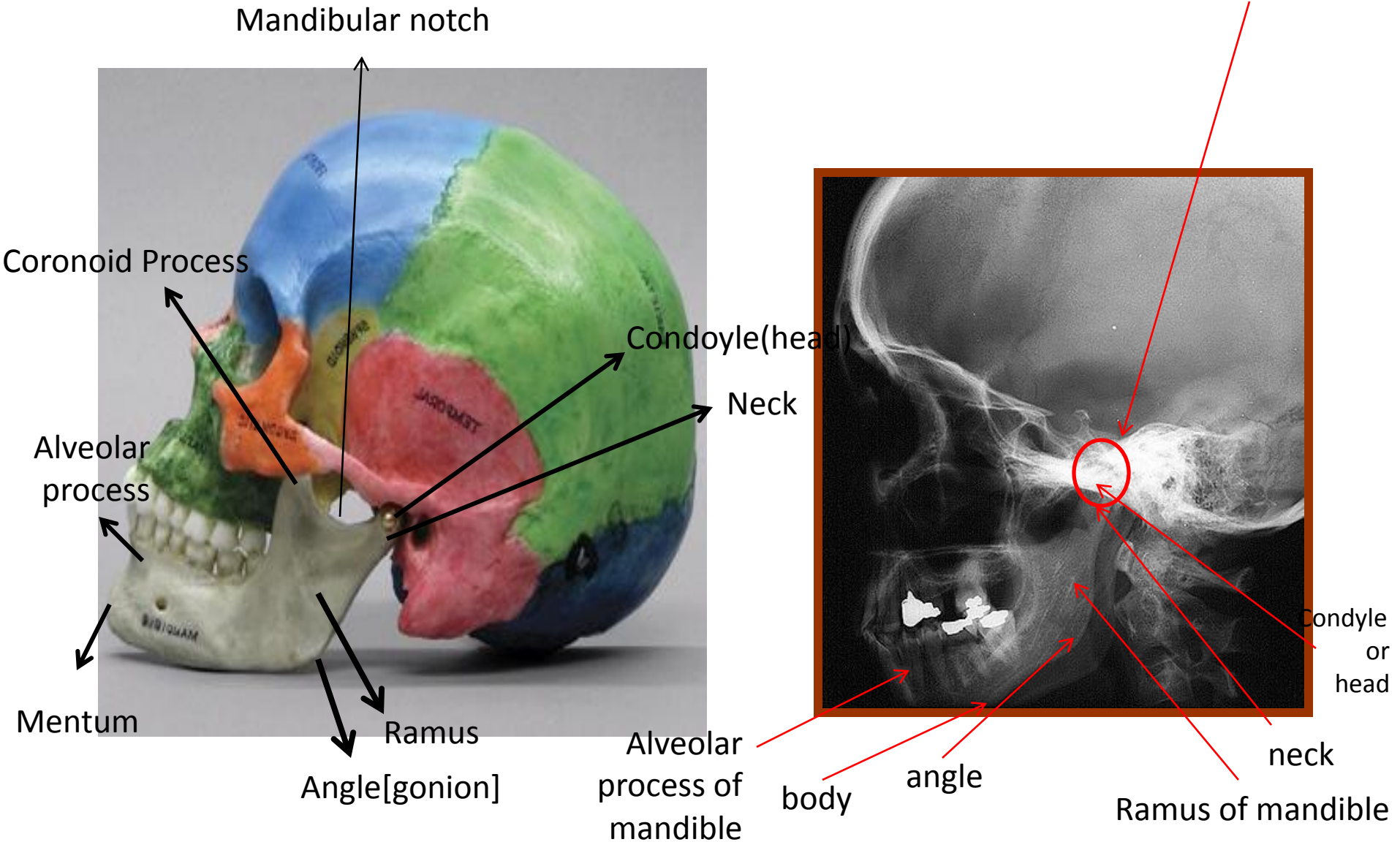
nasal
septum



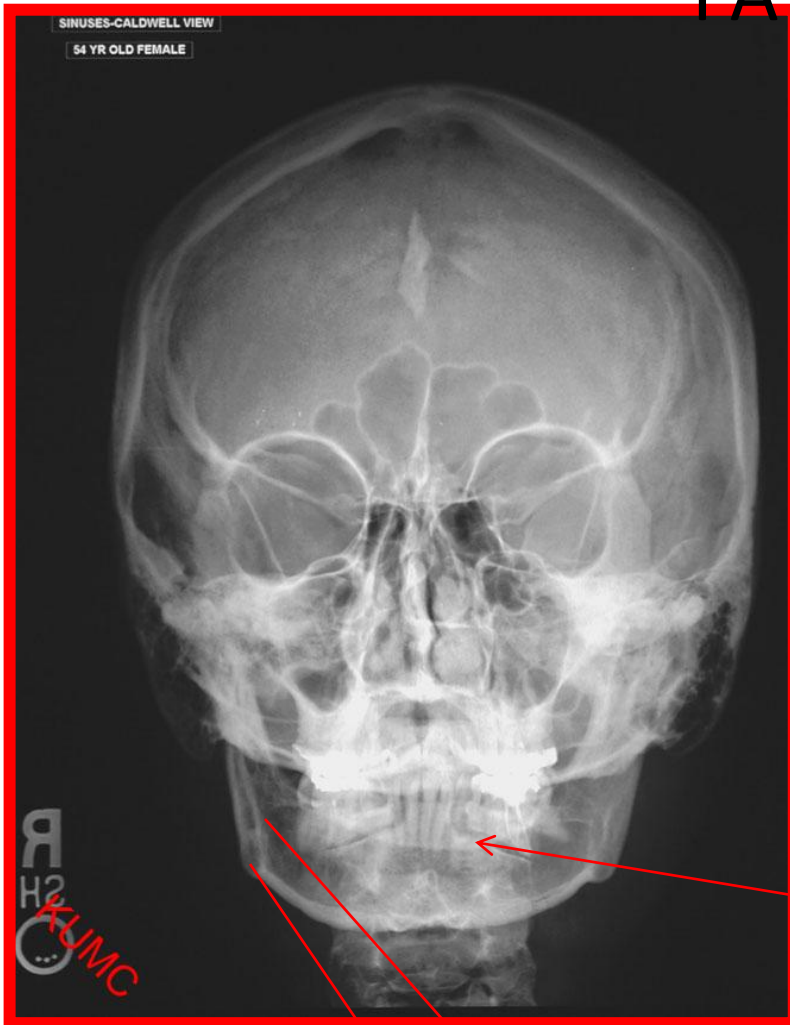
Mandible



Mandible



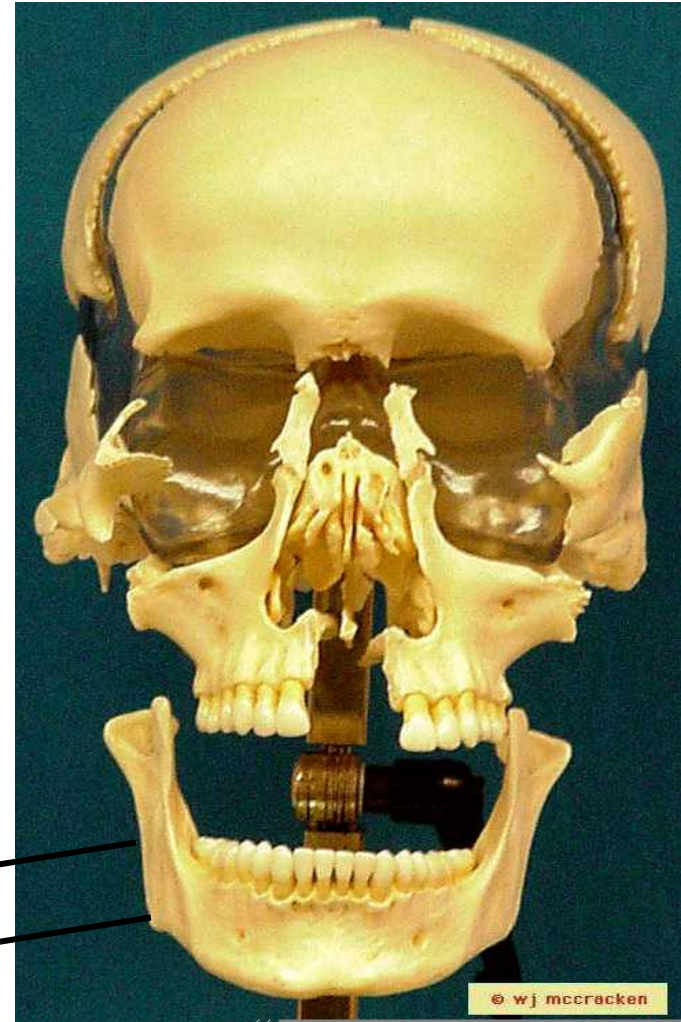
Caldwell view PA with angle



Alveolar
process of
mandible

Ramus

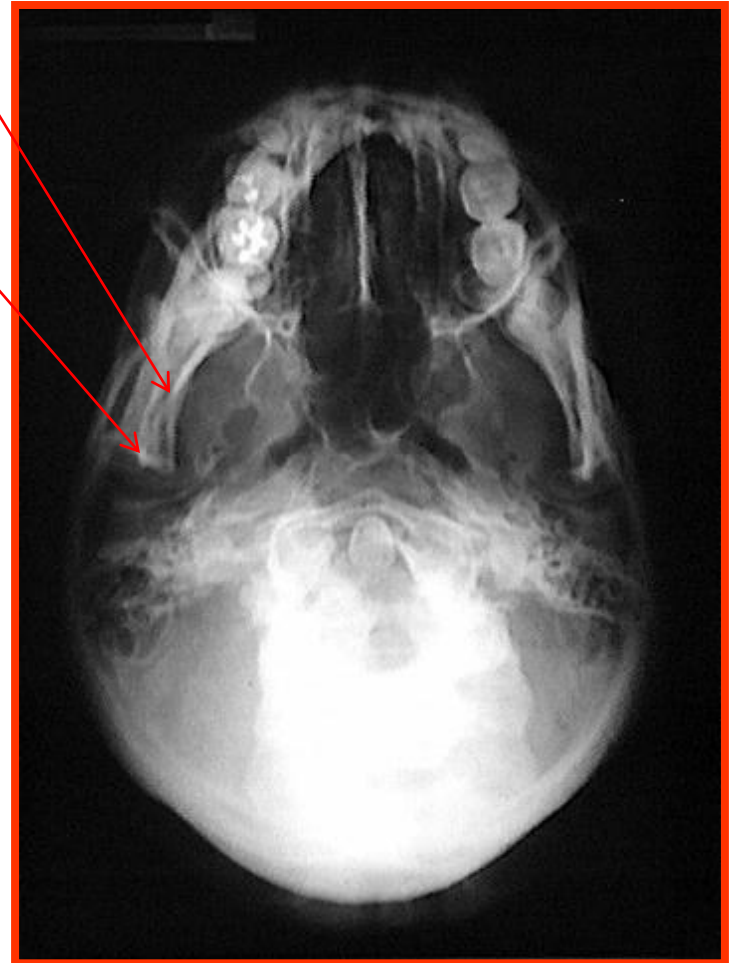Angle[gonion]



Submentovertical view

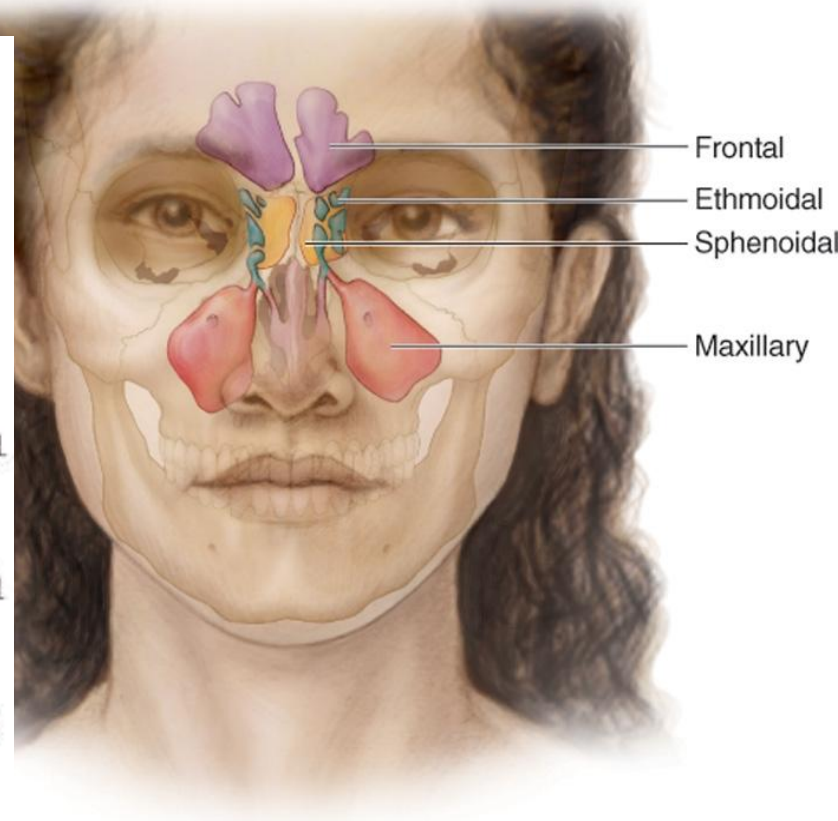
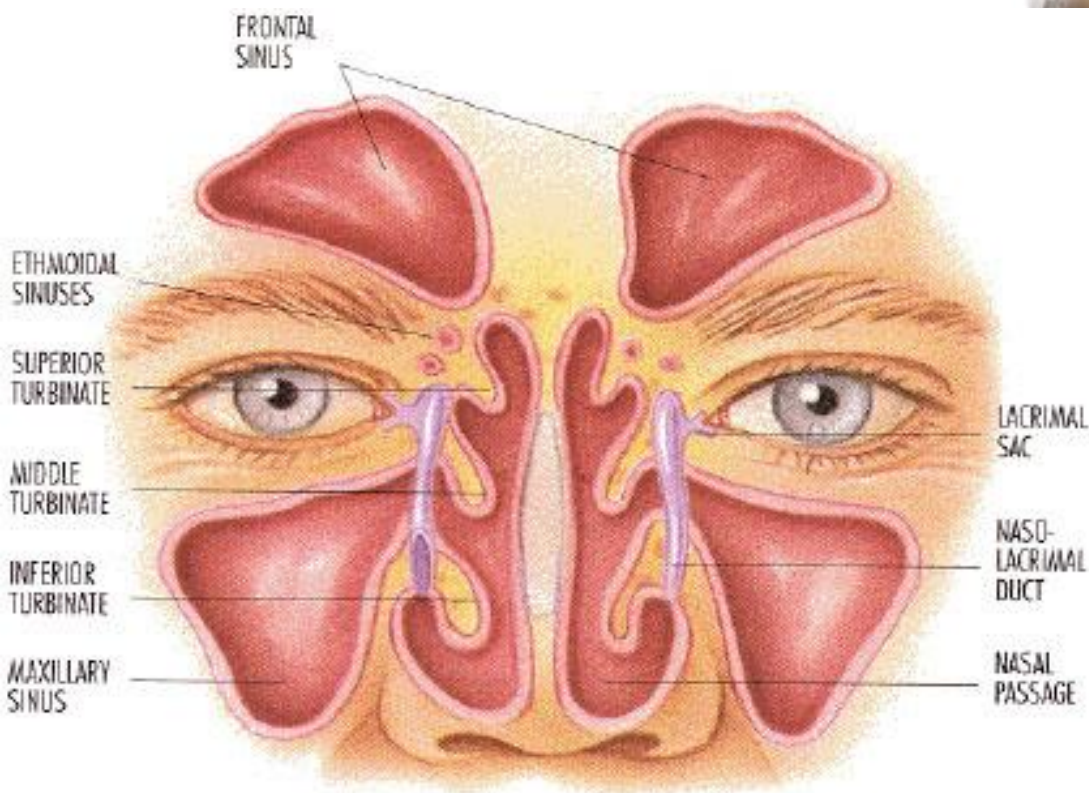
Ramus

Mandibular
condyle (head)

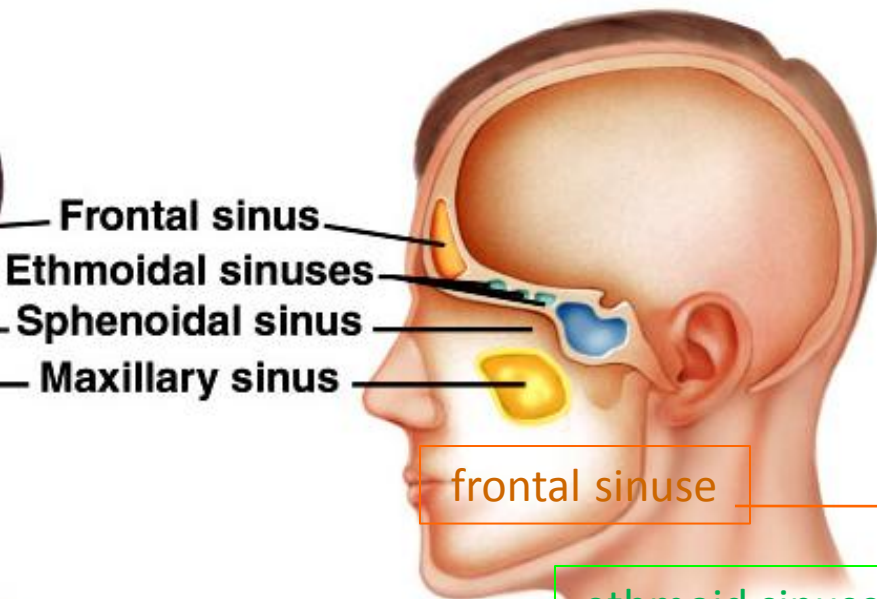


Sinuses

Copyright © The McGraw-Hill Companies, Inc. Permission required for reproduction or display.



Lateral

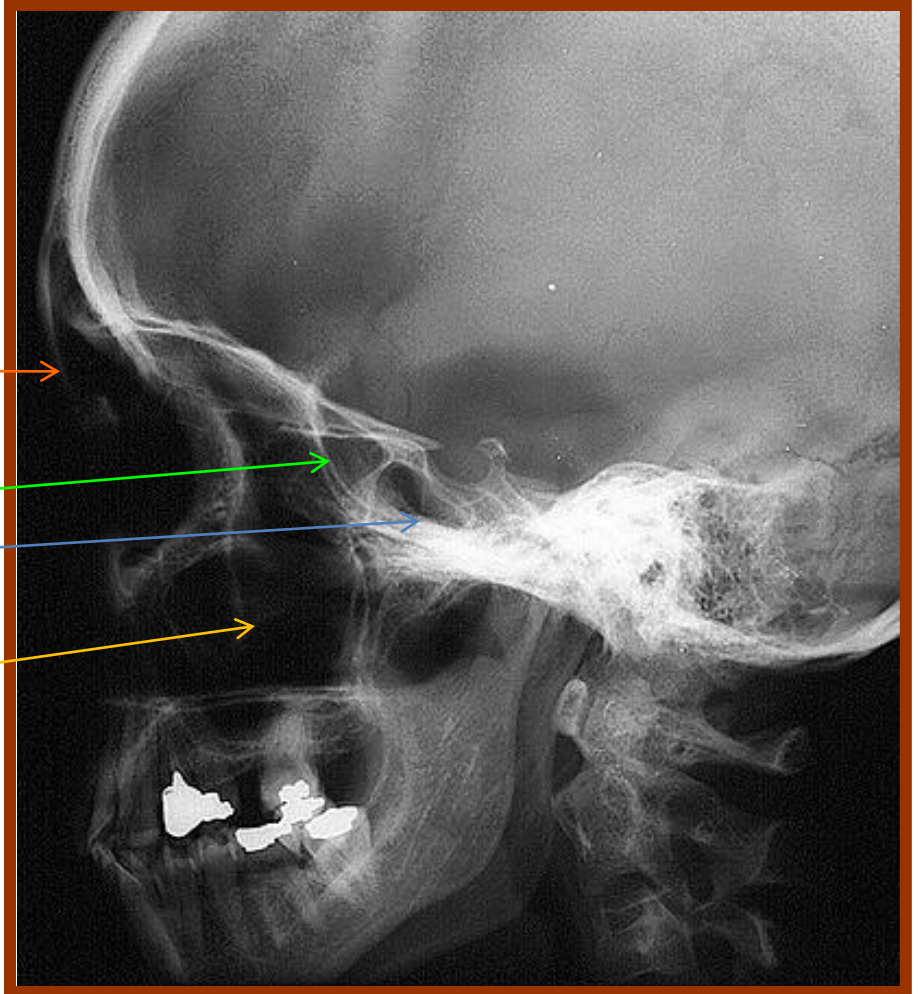


frontal sinuse

ethmoid sinuse

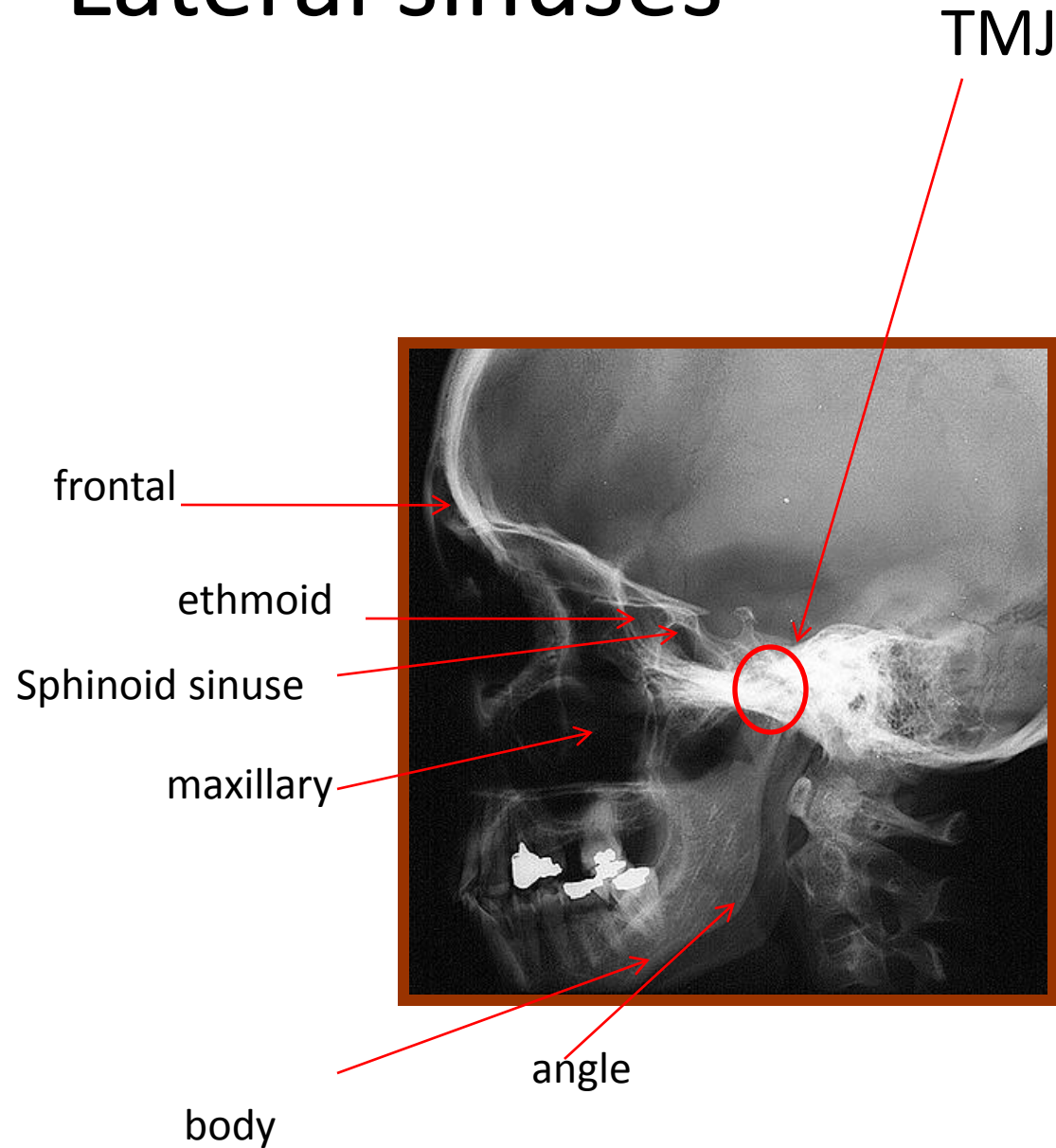
Sphenoid sinuse

Maxillary sinuse

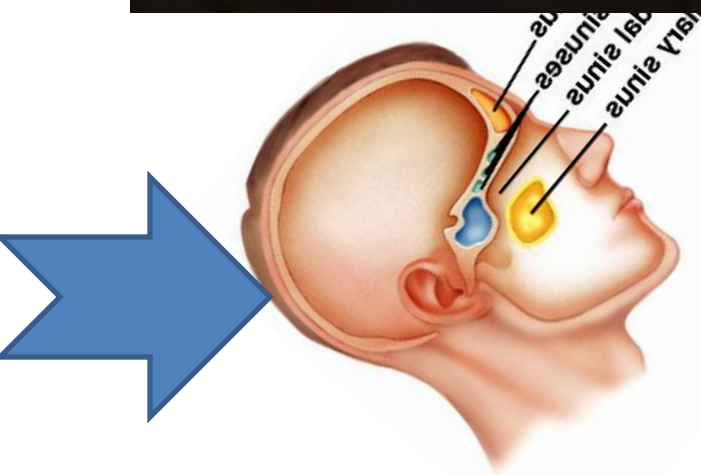
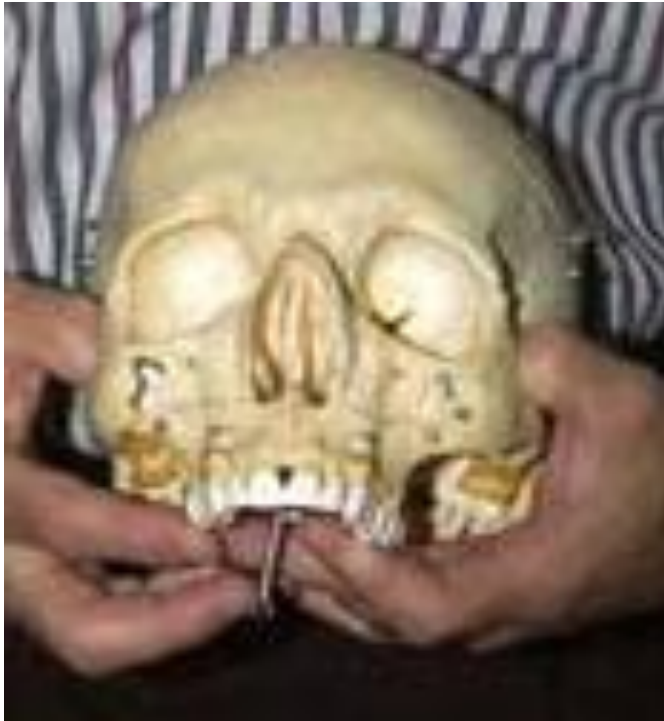

Review

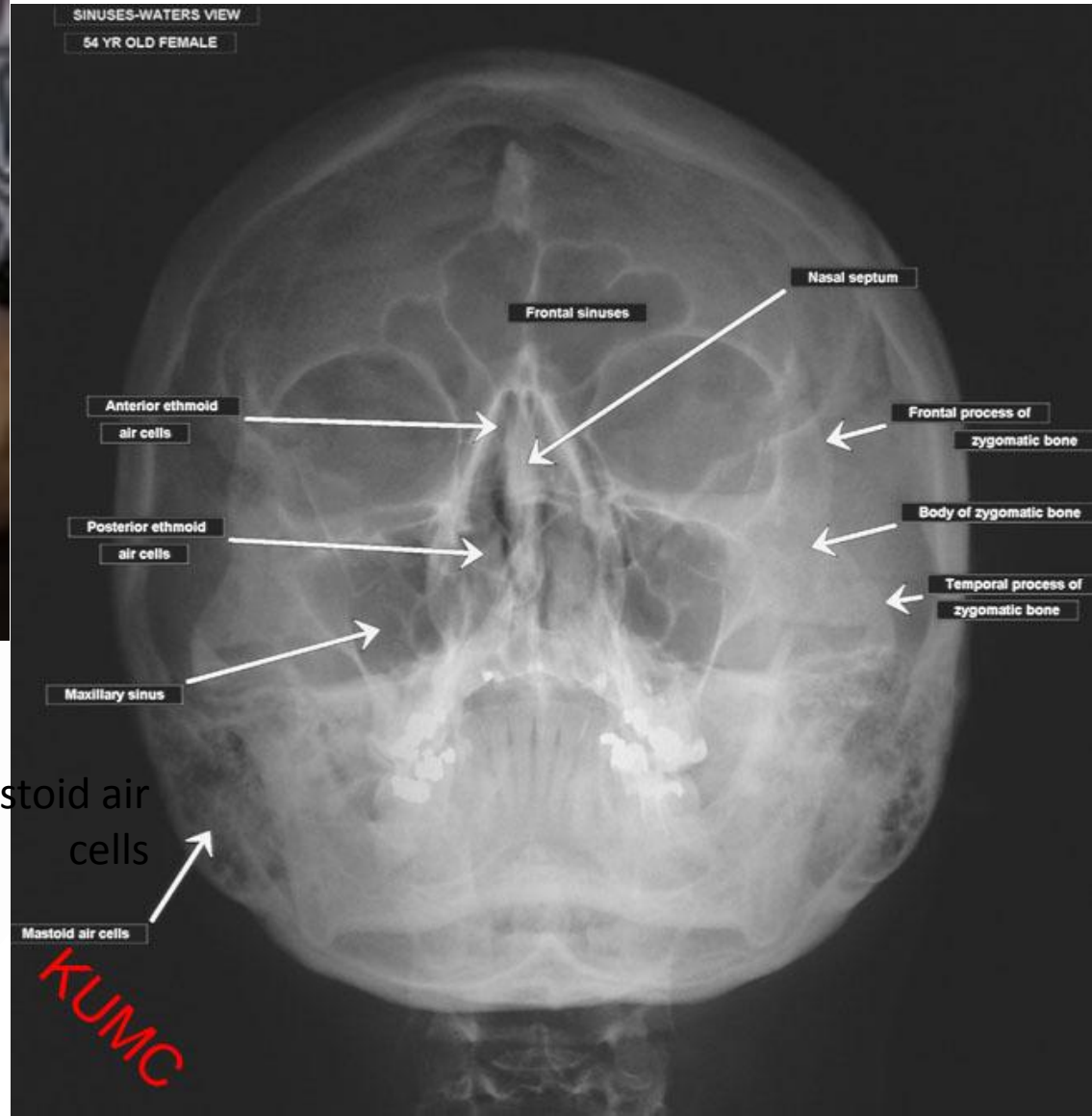
Lateral sinuses



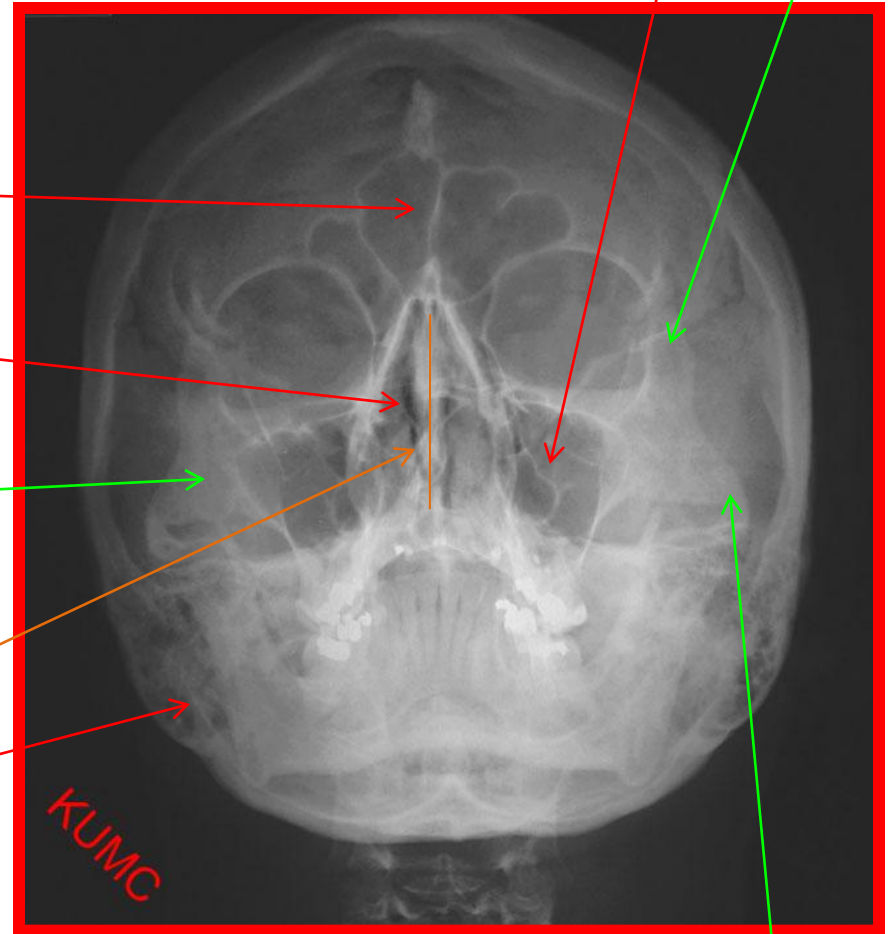
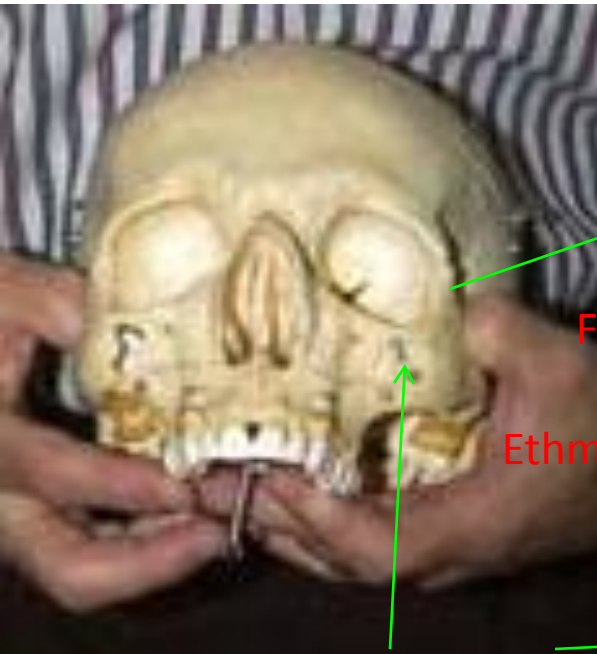
Sinuses waters view



Mastoid air cells



Waters view facial bones



Maxillary sinus

Frontal process of zygomatic

Frontal sinuses

Ethmoid sinus

Body of zygomatic bone

Prependicular plate

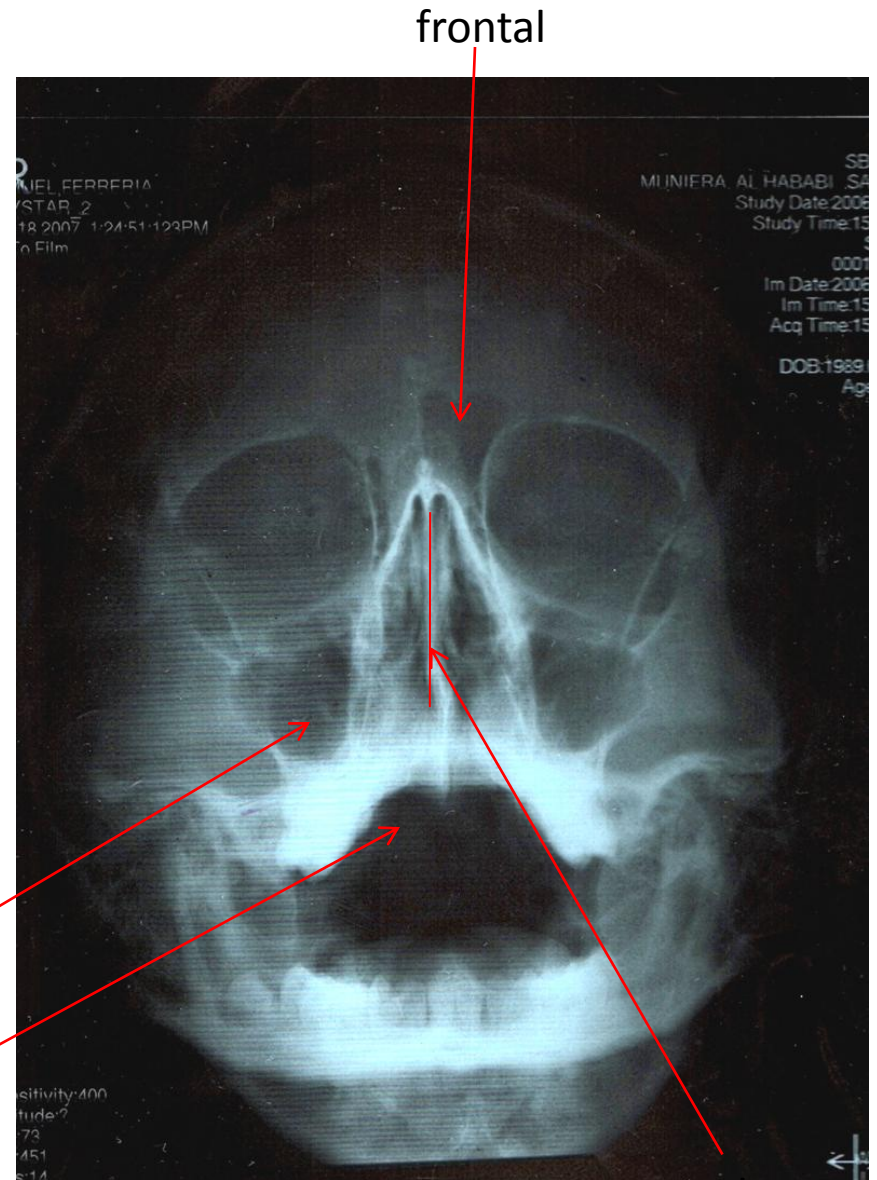
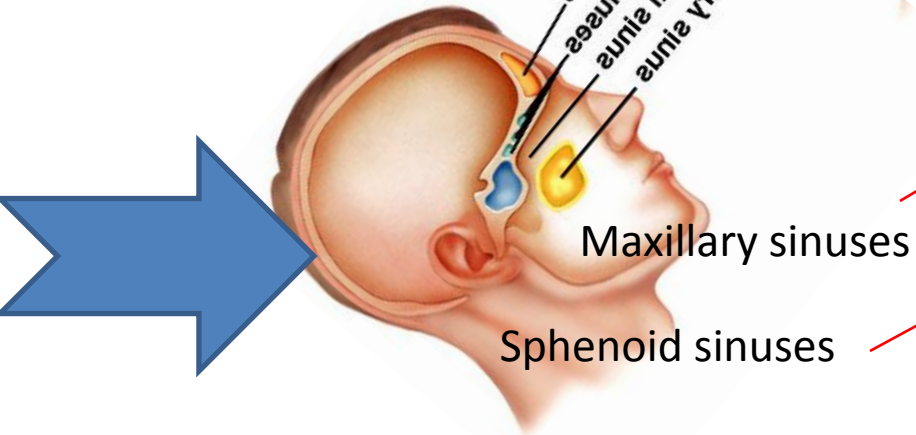
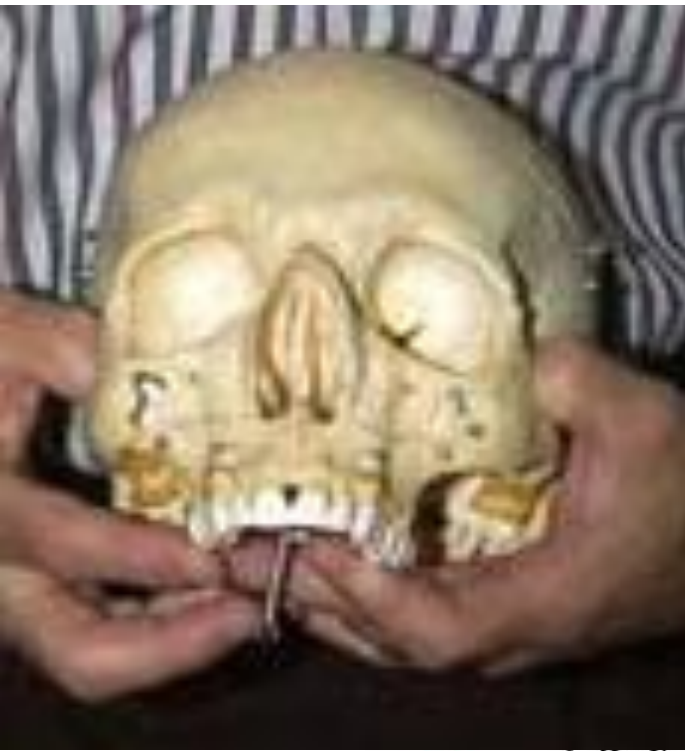vomer

Nasal septum

Mastoid air cells

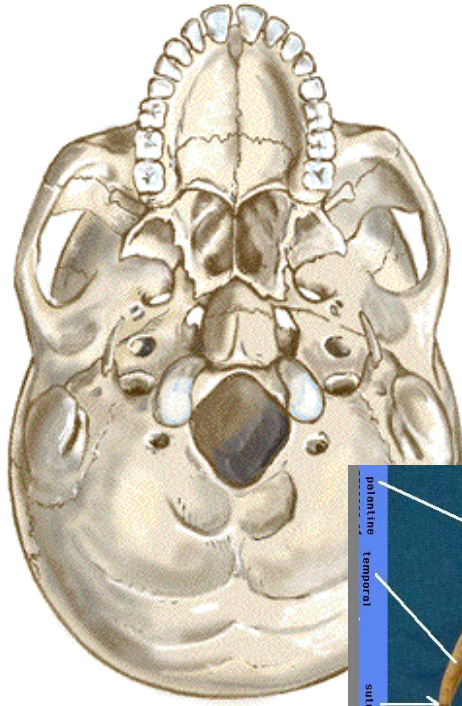
Temporal process of
zygomatic bone

Waters view OPEN MOUTH (SINUSES)



Nasal septum

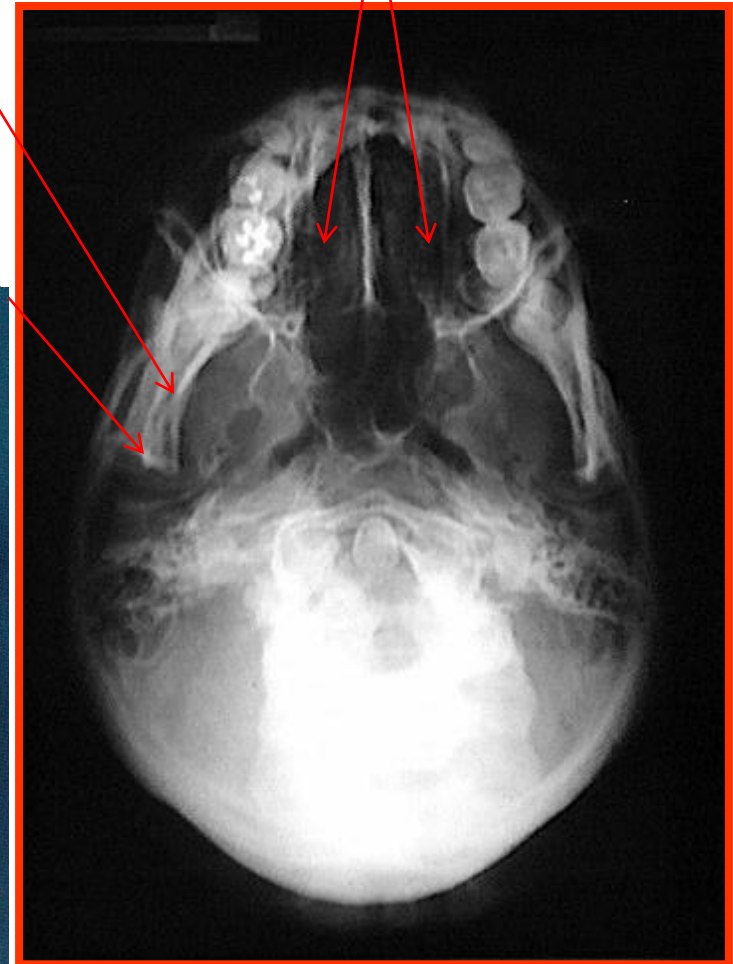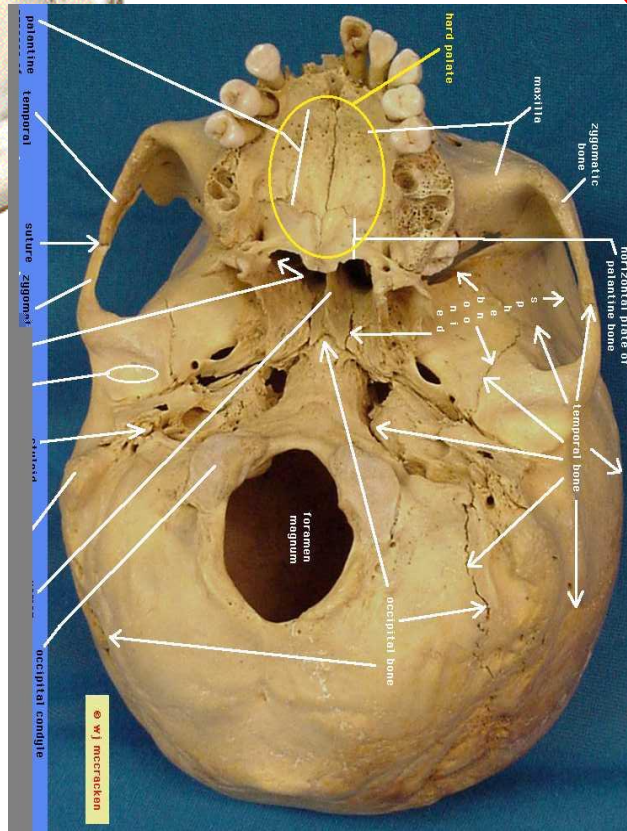
Submentovertical view



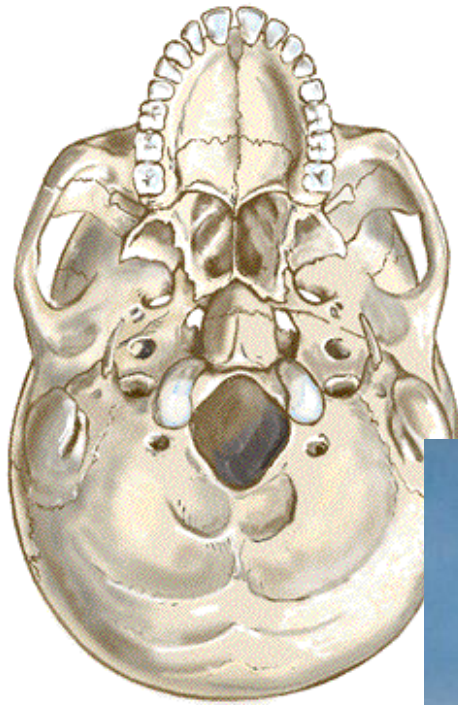
Ramus

Mandibular
condyle (head)

Hard palate

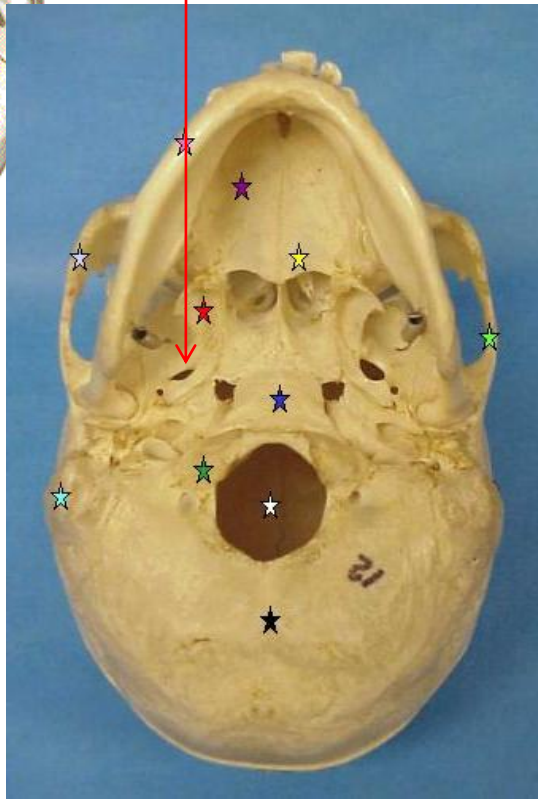


Submentovertical view



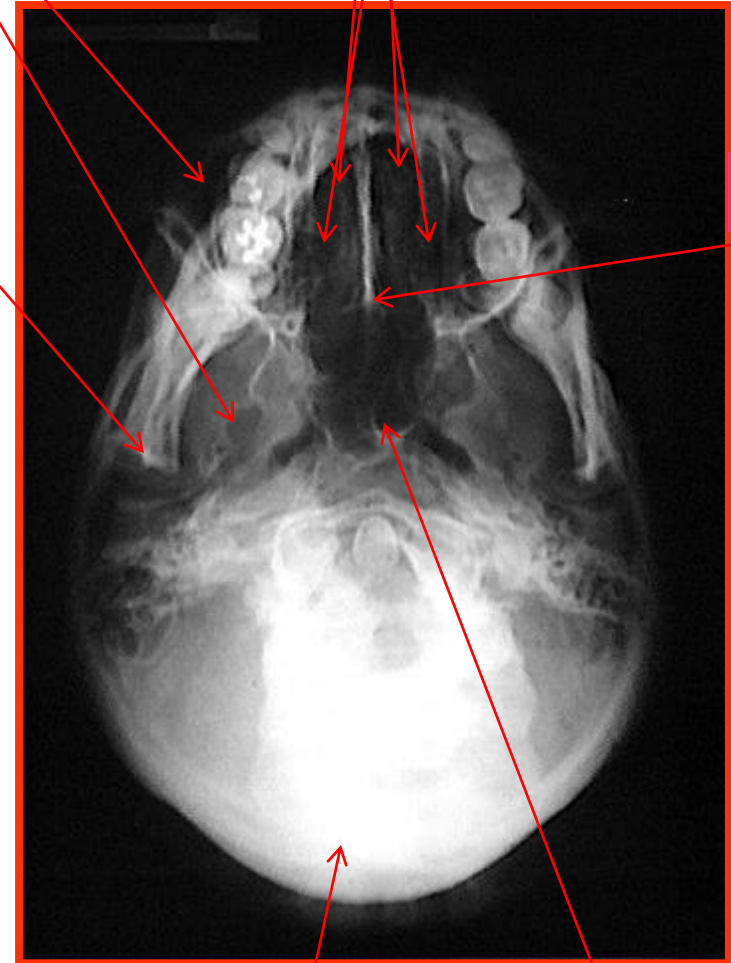Maxillary sinuse
Foramen ovale

Mandibular
condyle (head)



Ethmoid sinuse

Hard palate

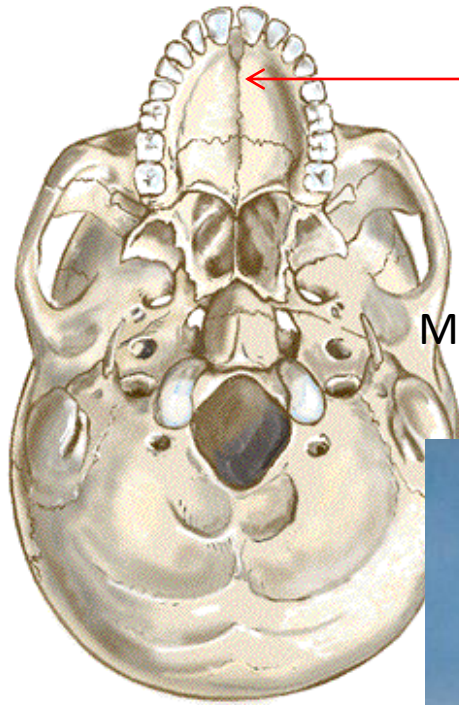


vomer

Occipital bone

Sphenoid sinus

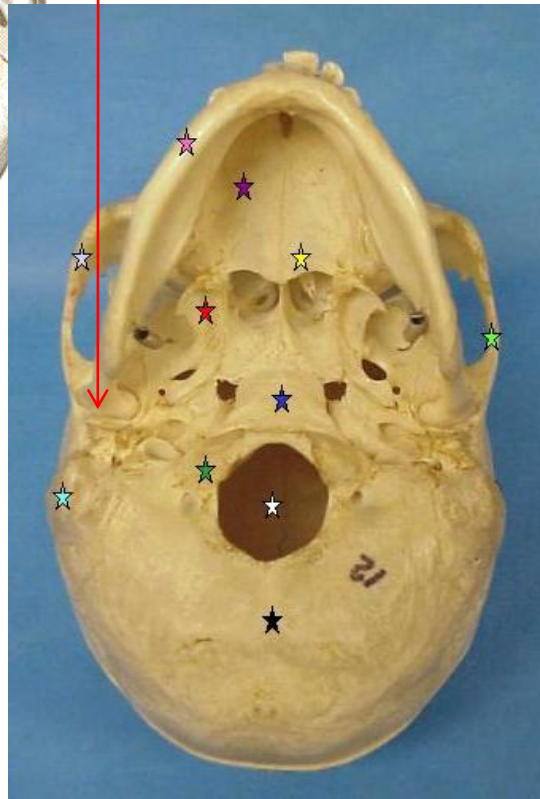
Submentovertical view



Maxillary sinus

Ramus

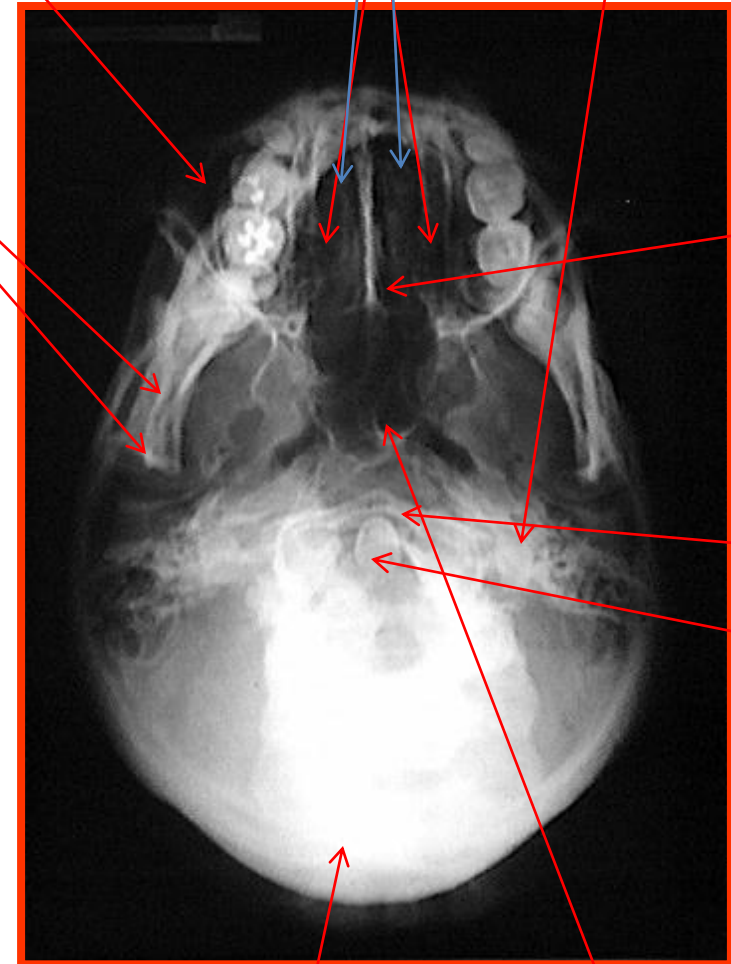
Mandibular condyle (head)



Petrous pyramids of temporal bone

Ethmoid sinus

Hard palate (palatin process of maxilla)



vomer

atlas

Dense

Occipital bone

Sphenoid sinus

THANK YOU