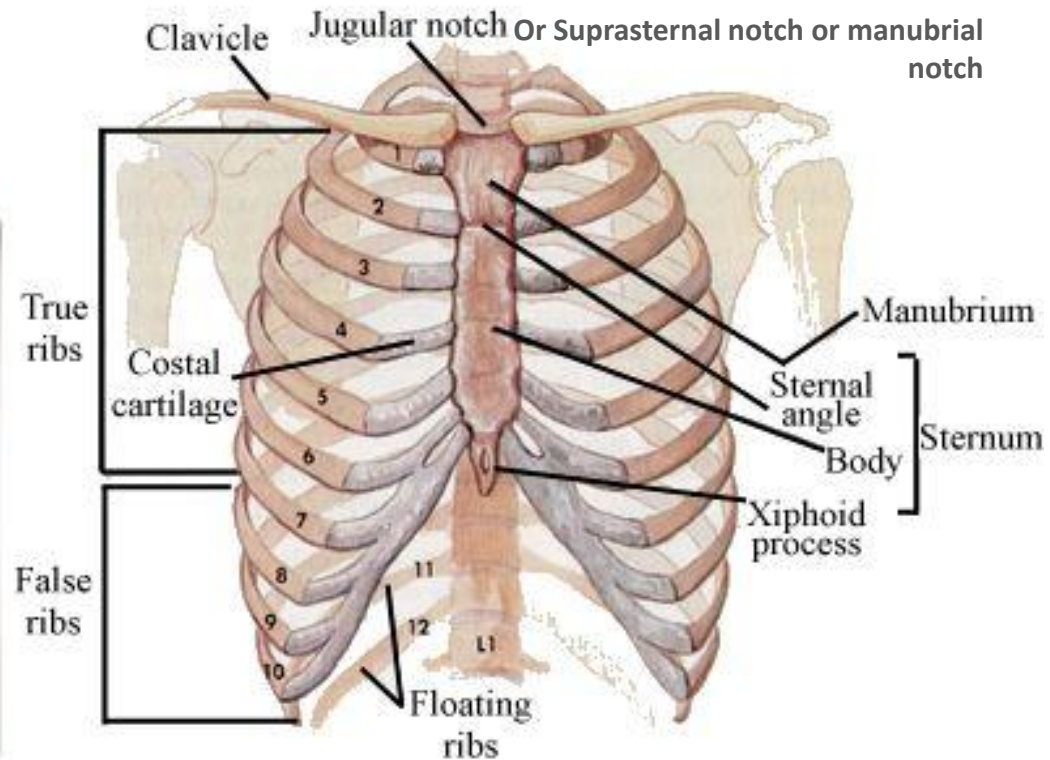
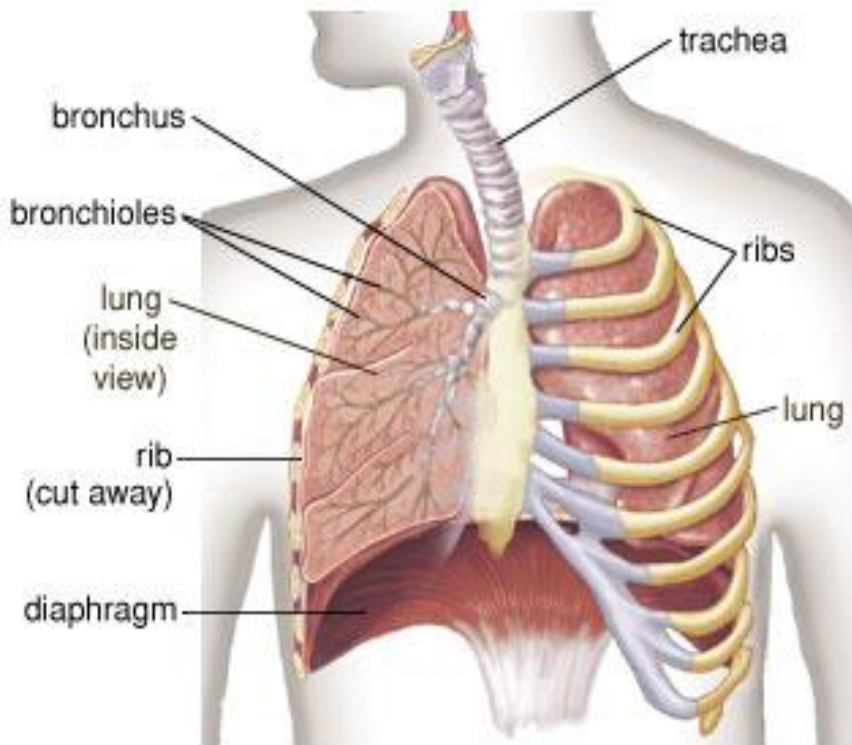


Chest or thorax

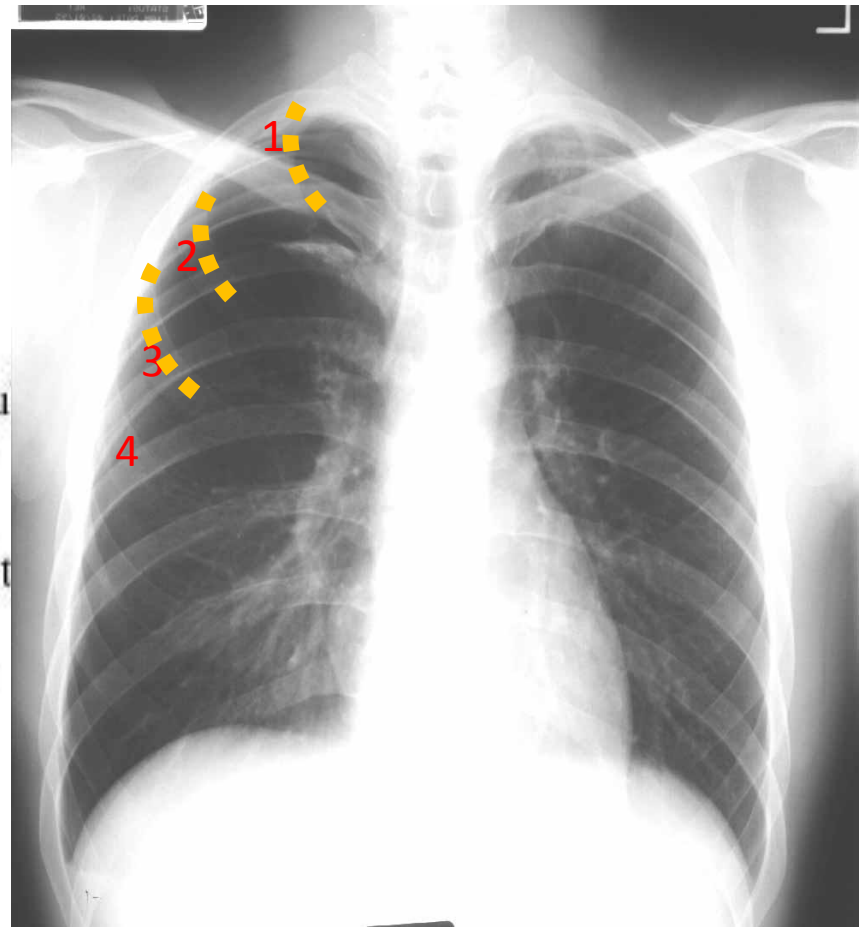
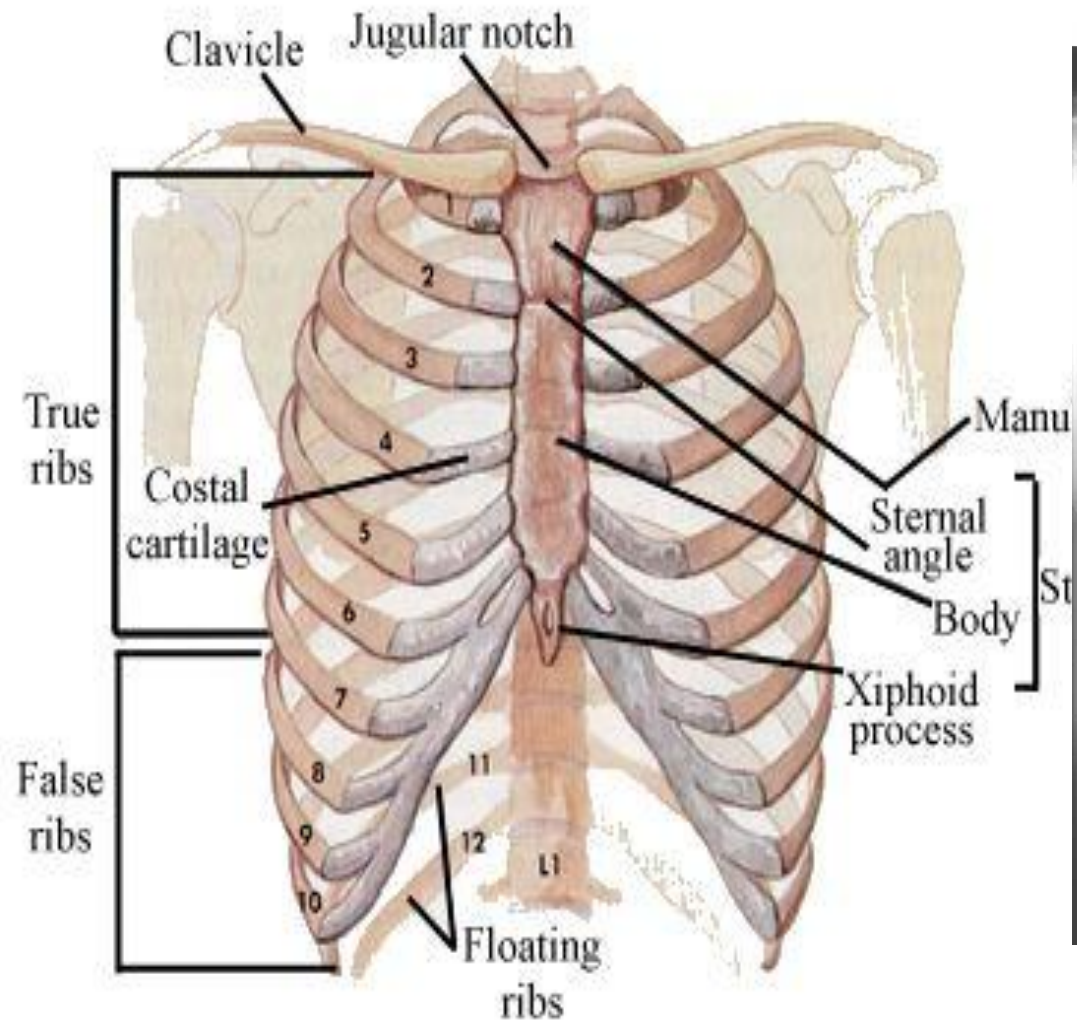
Radiographic anatomy of the chest is divided into 3 section :

1. Bony thorax
2. Respiratory system
3. mediastinum

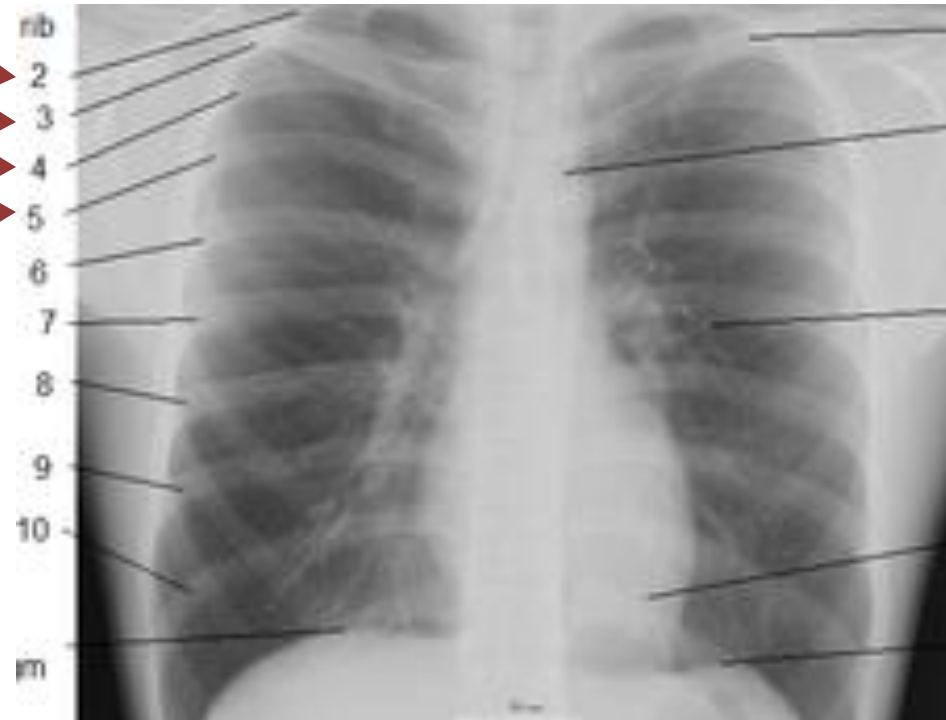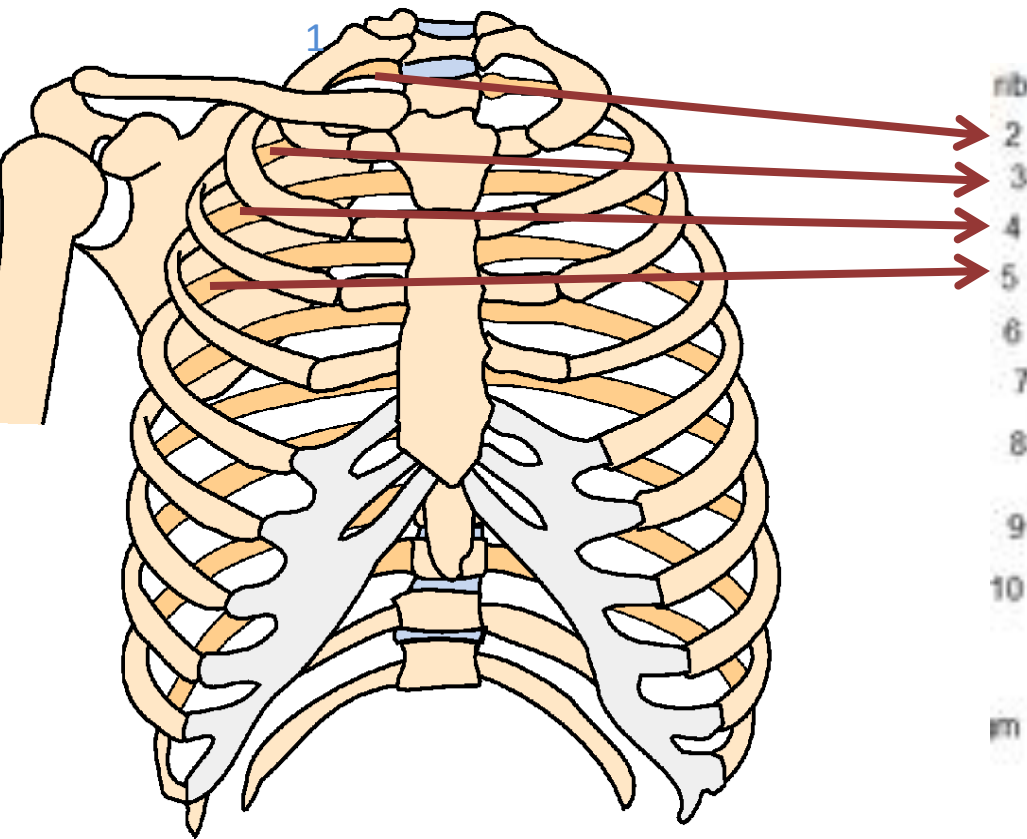
Bony thorax



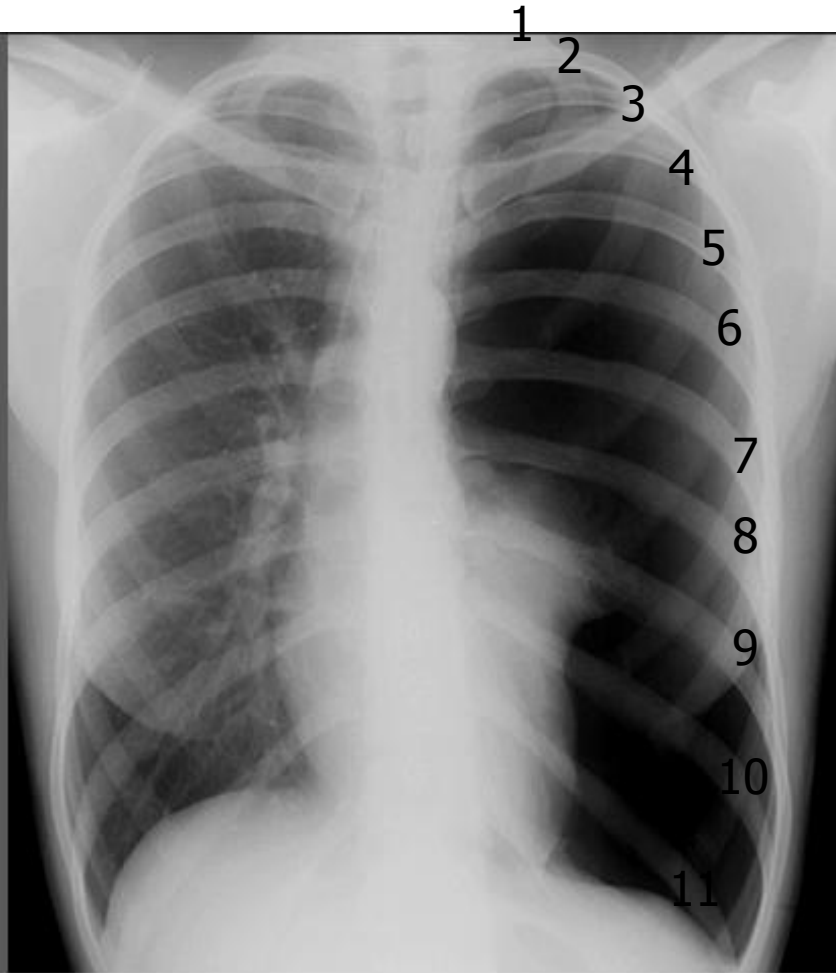
Anterior ribs



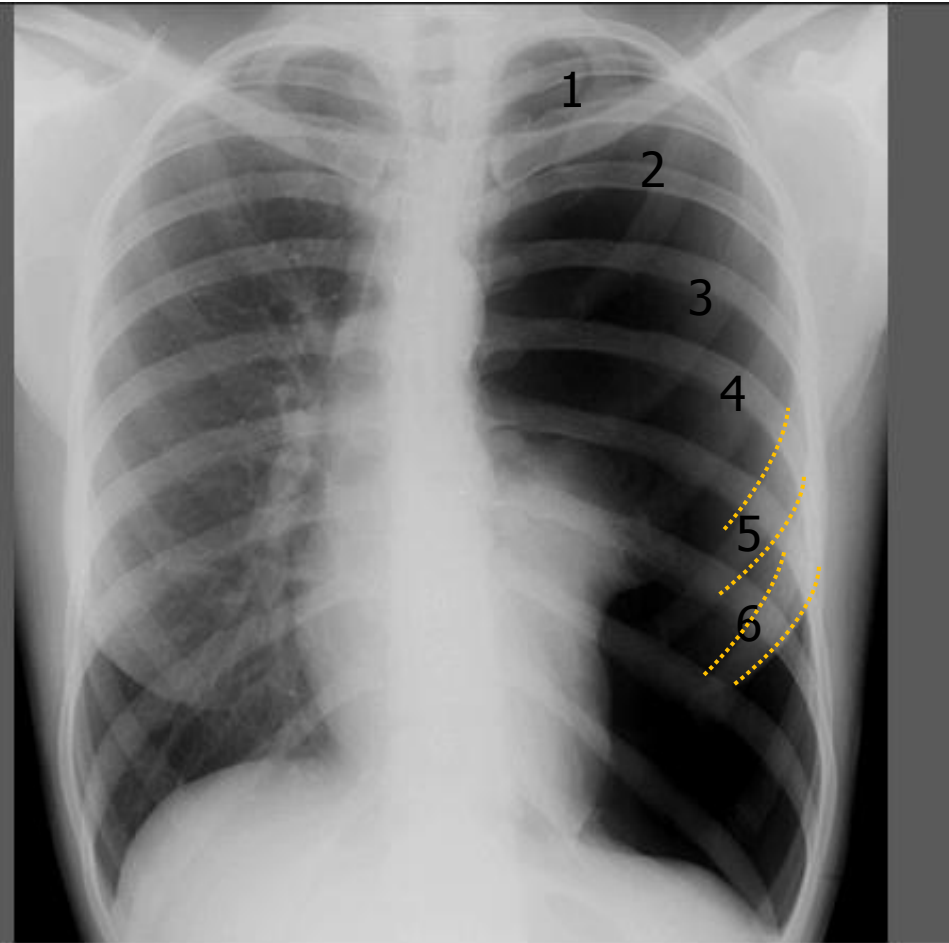
Posterior ribs



Max Inspiration

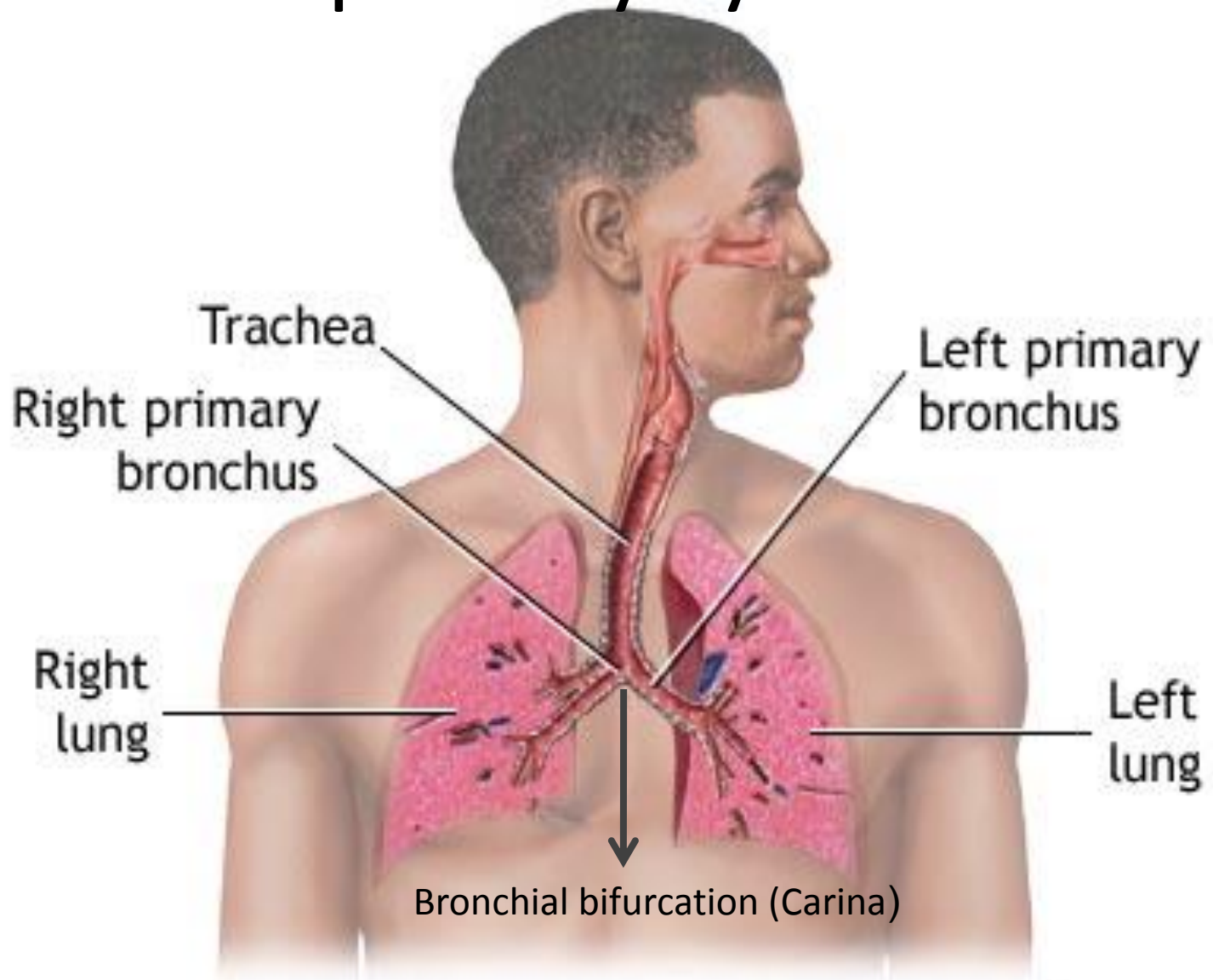


Posterior Ribs



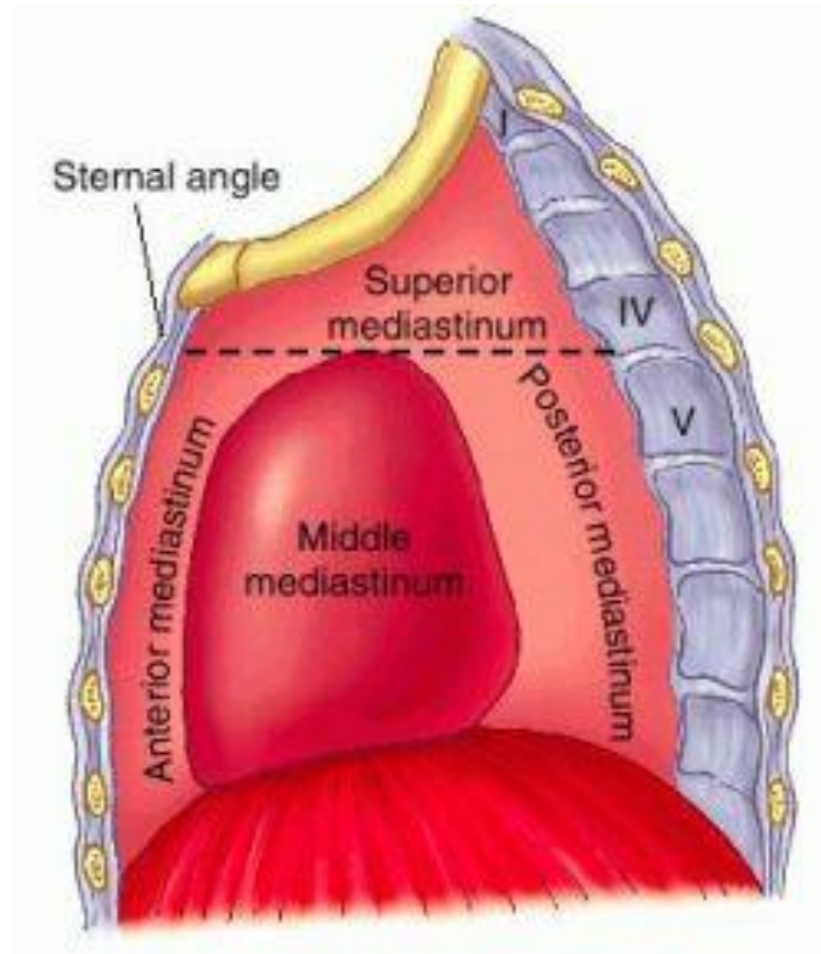
Anterior ribs

Respiratory System



Mediastinum

It is the area of thorax cavity around the lung

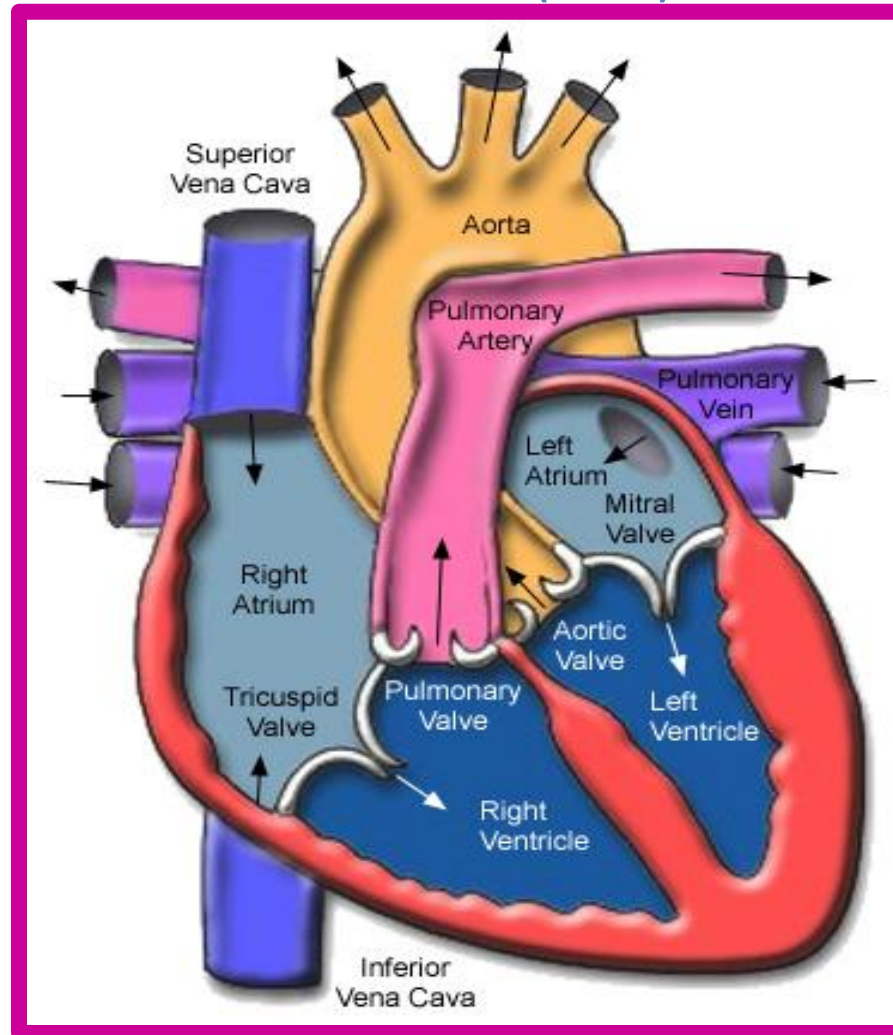


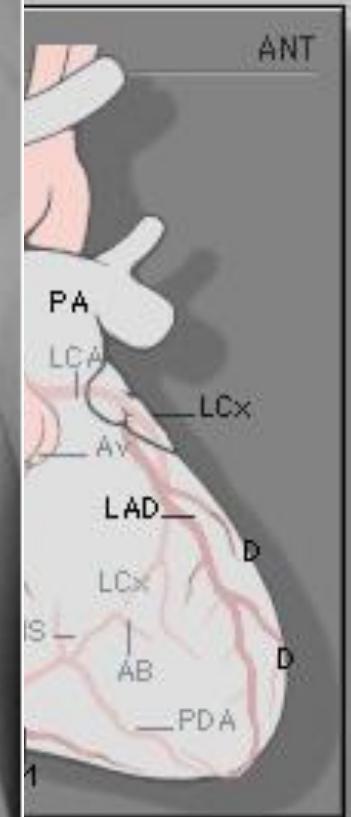
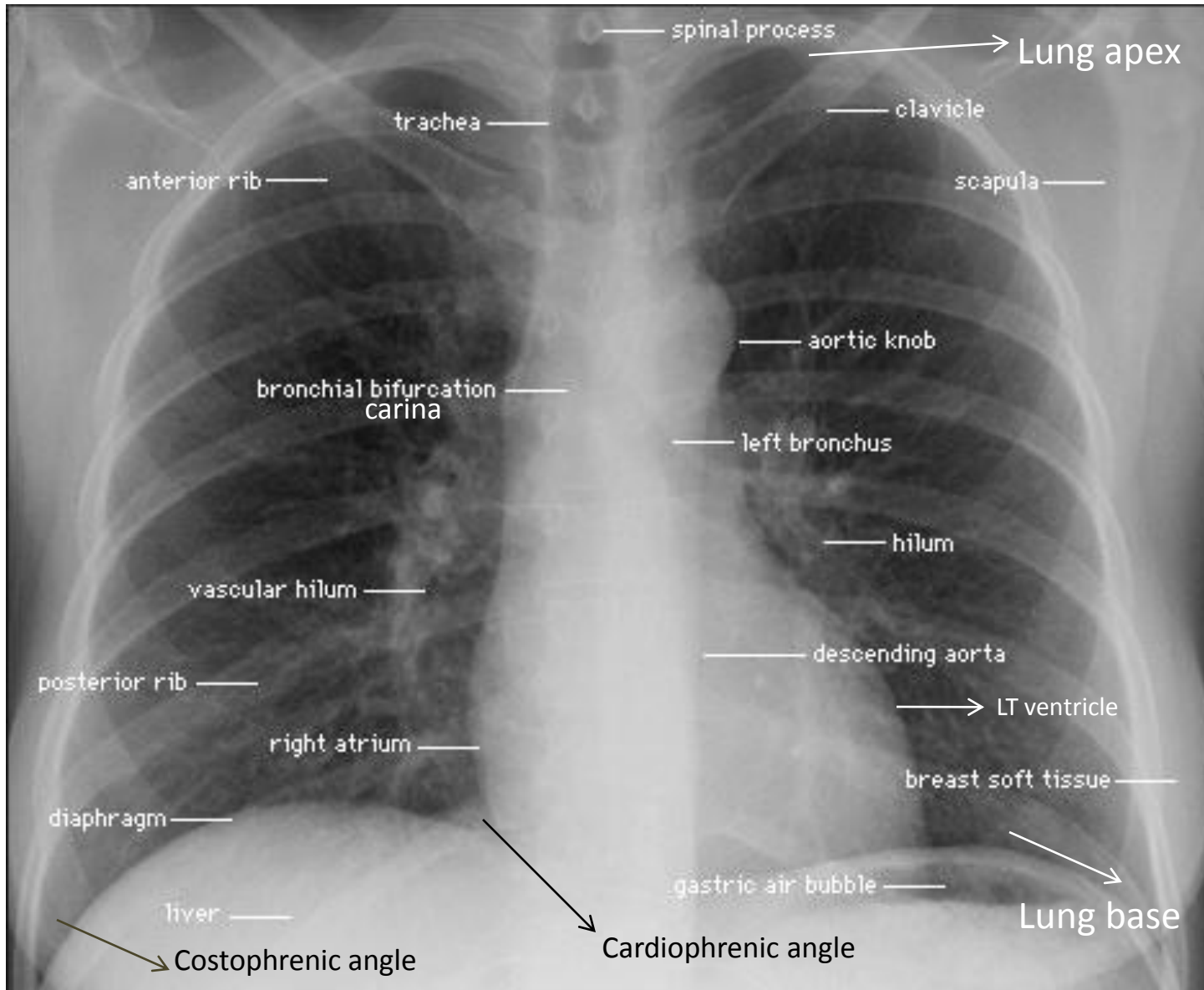
The heart

internally heart is composed of 4 chambers:

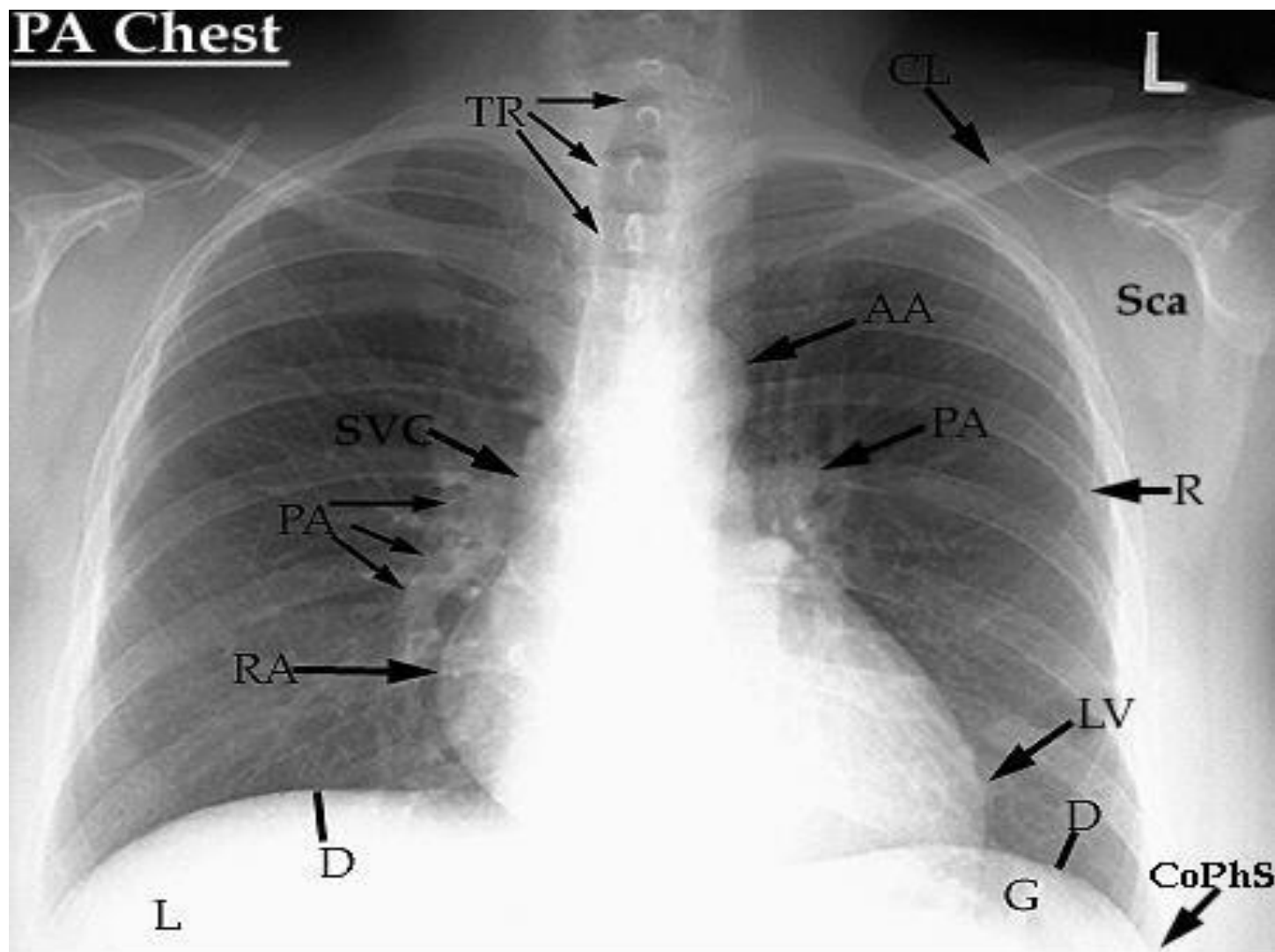
2 atria (R&L)

2 ventricles (R&L)





PA Chest



PA=Pulmonary Artery

TR=Trachea

CL=Clavicle

AA=Aortic Arch

SVC=Superior Vena Cava

RA=Right Atrium

CoPhS=Costophrenic Sulcus

LV=Left Ventricle

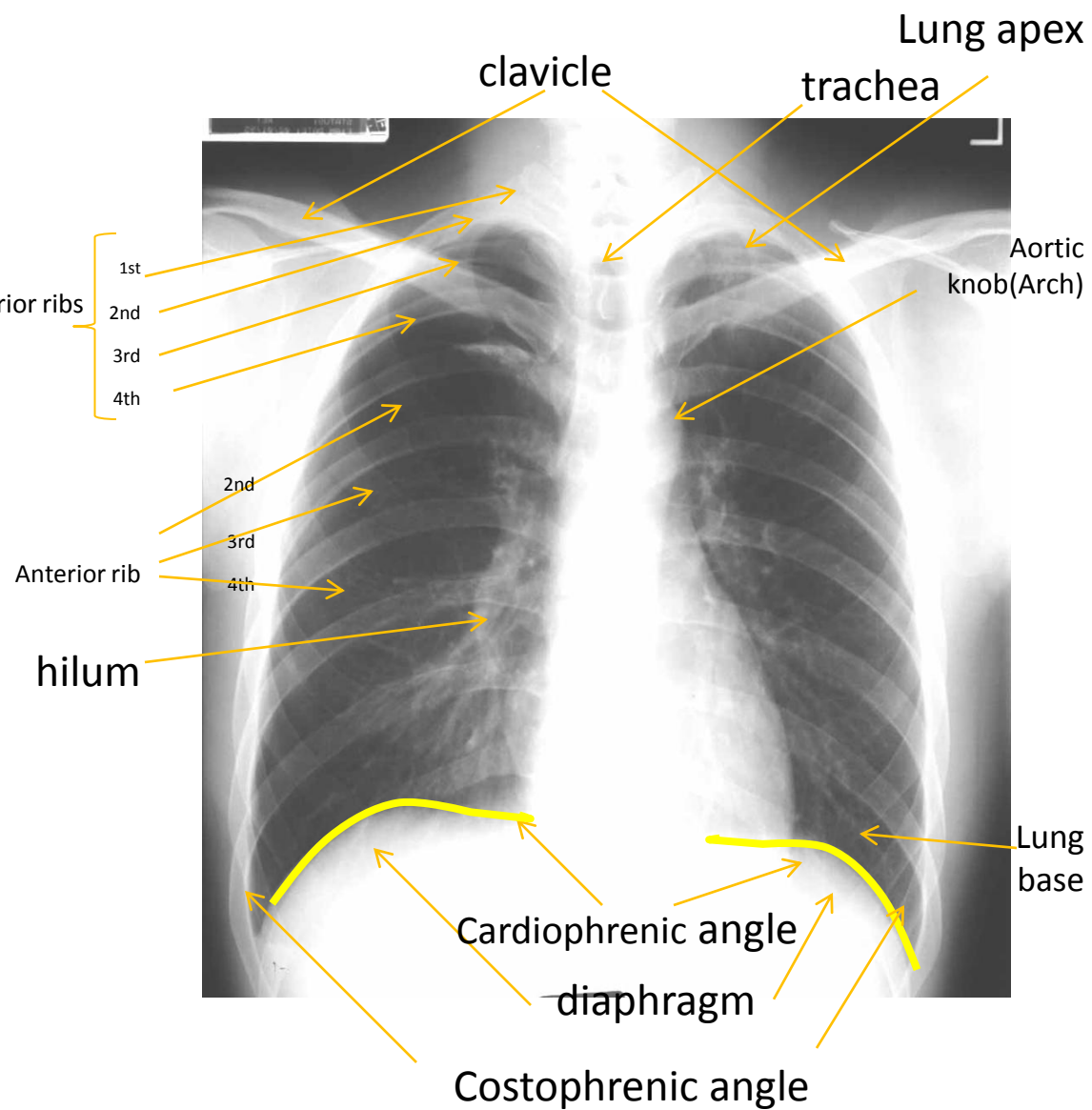
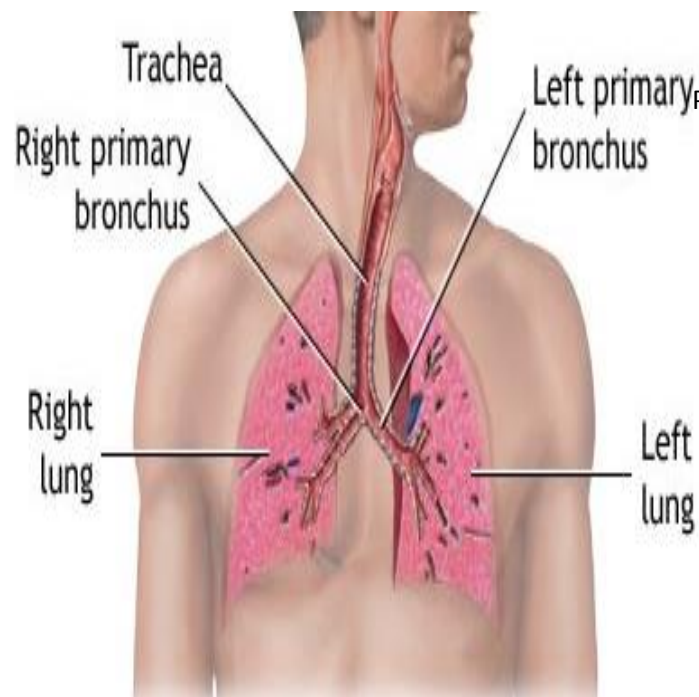
D=Diaphragm

G=Gastric Air Bubble

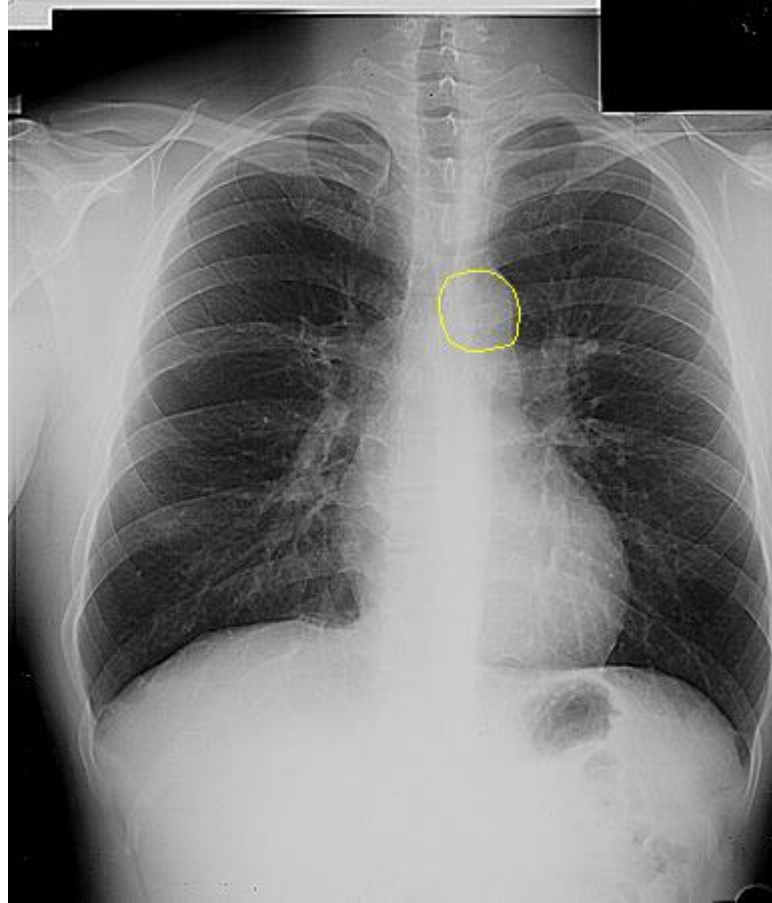
L=Liver

Sca=Scapula

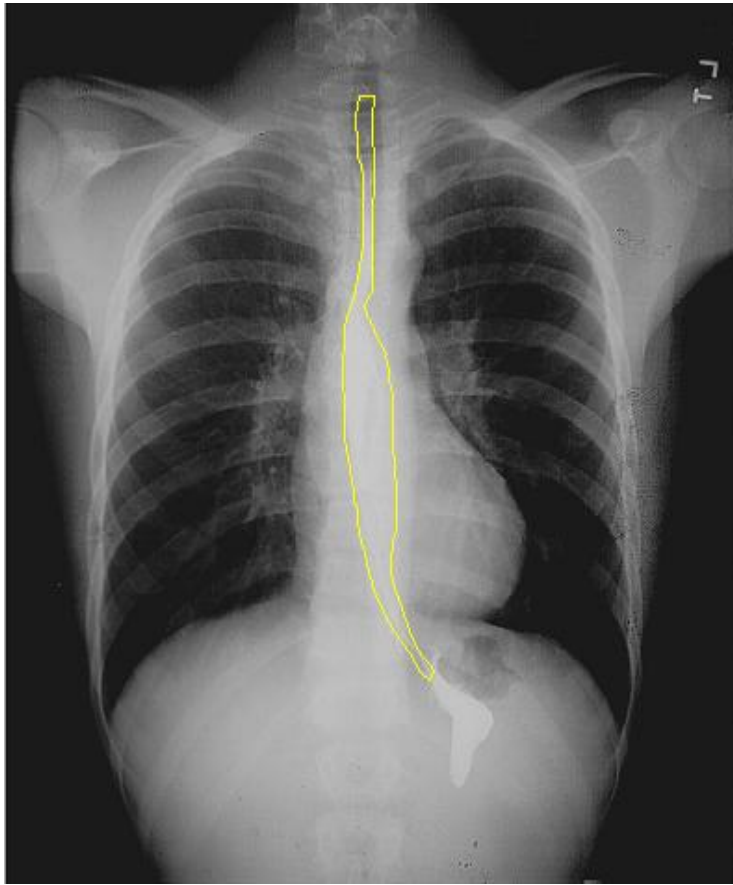
R=Rib



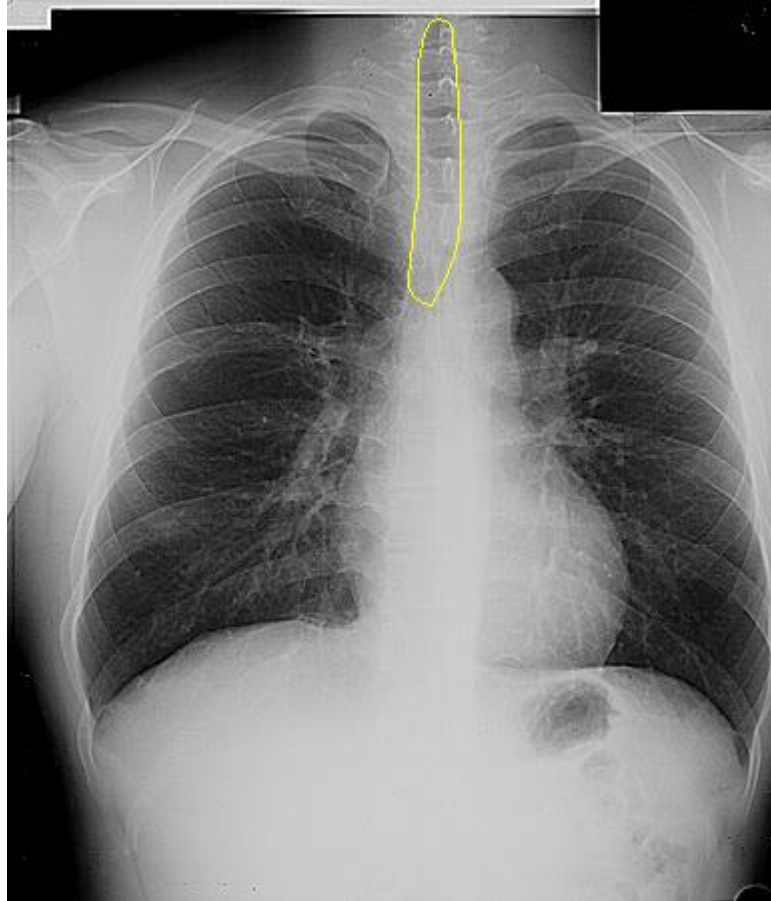
Aortic arch & Aortic knob



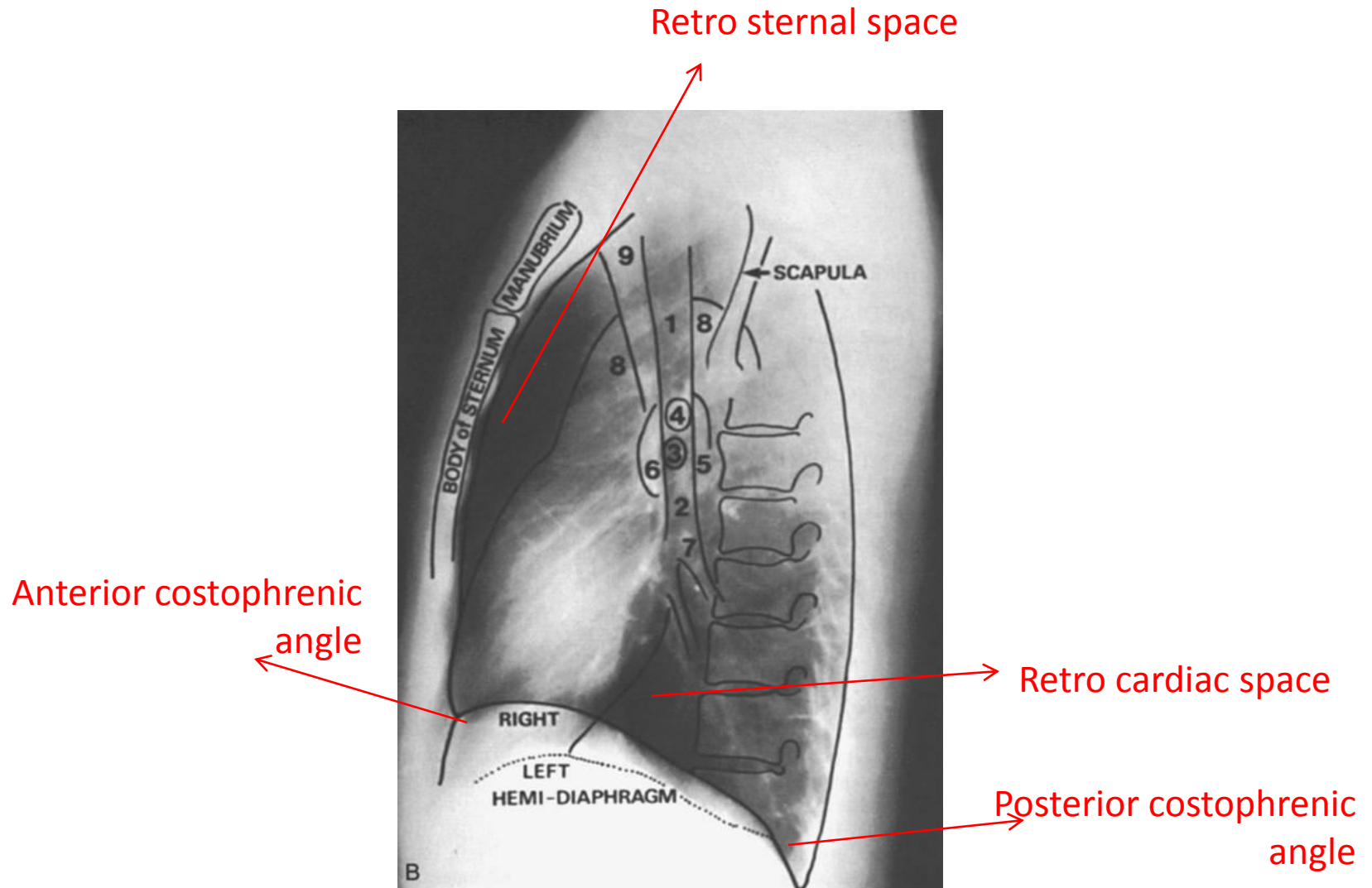
Eosinophagus



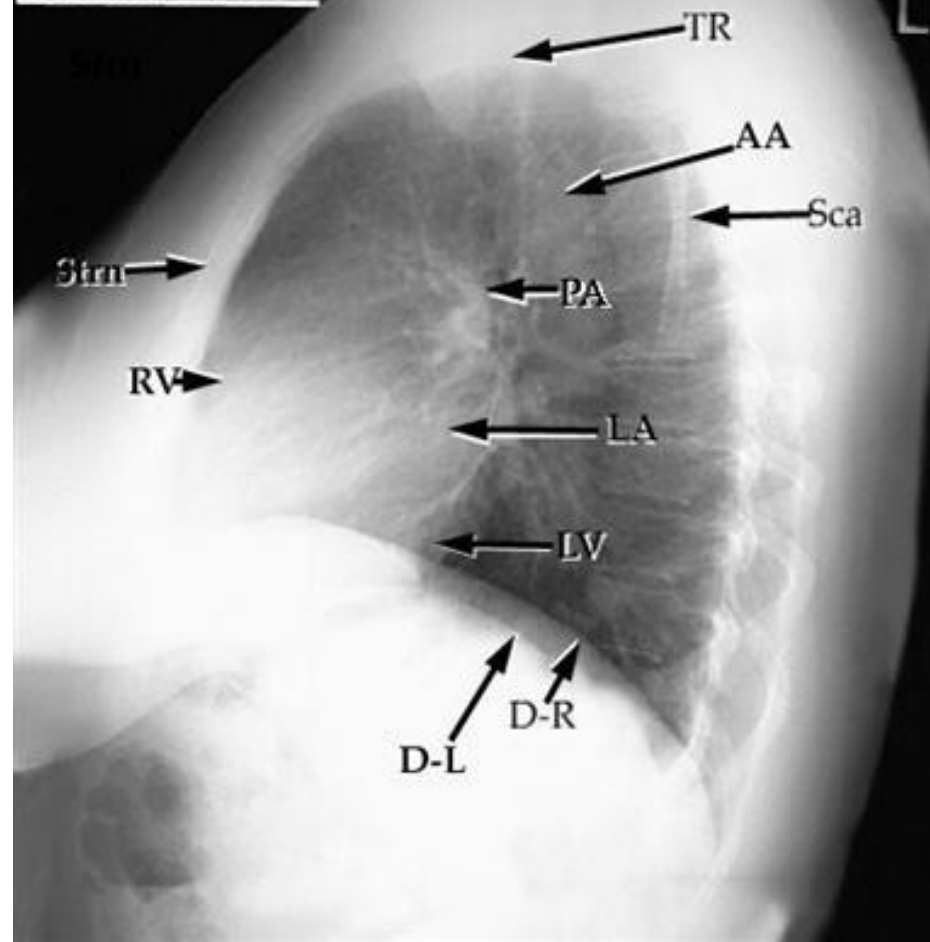
Trachea



Chest lateral

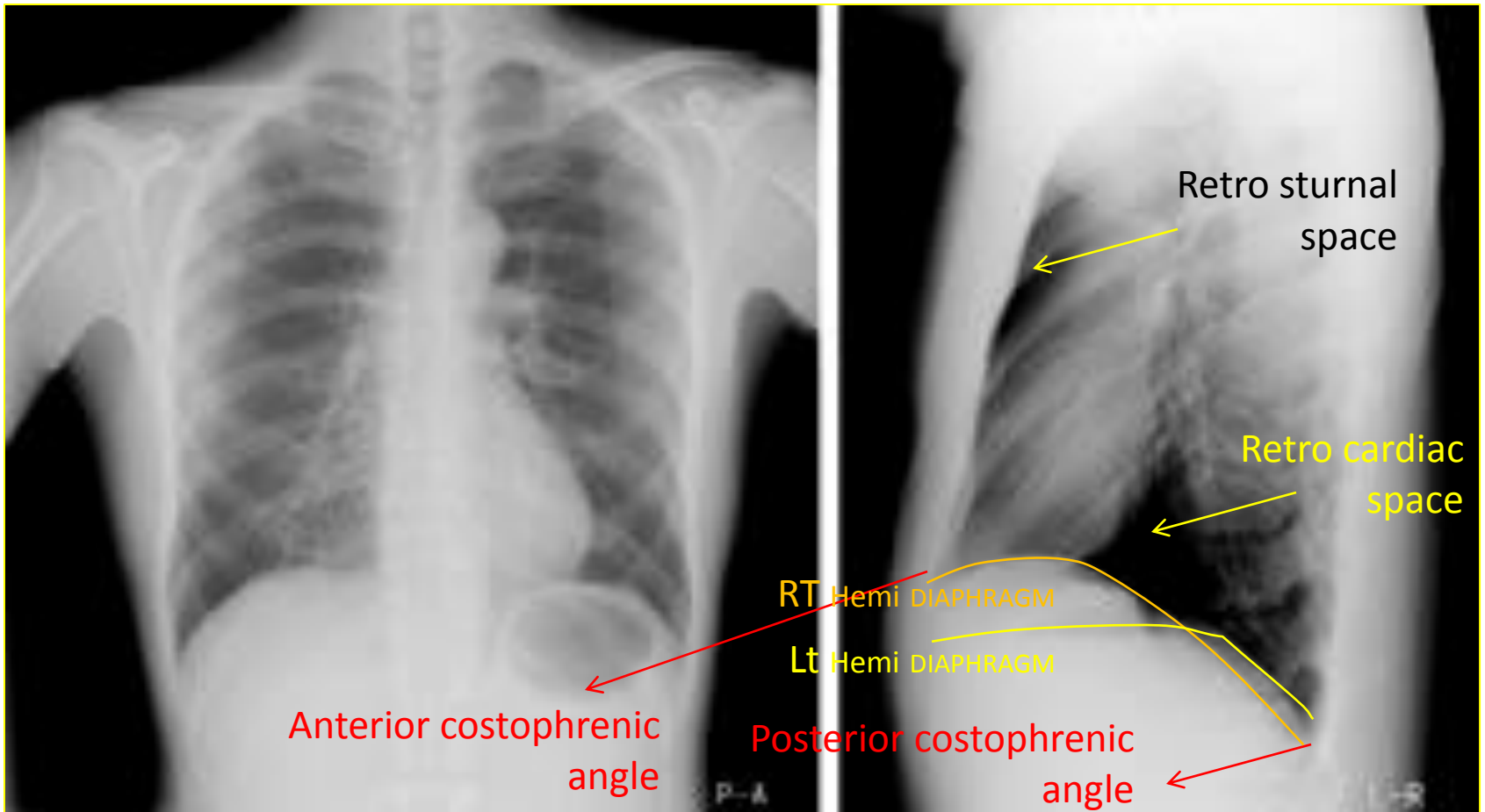


Lateral Chest



TR=Trachea
Strn=Sternum
AA=Aortic Arch
Sca=Scapula
PA=Pulmonary Artery

D-R=Right Hemidiaphragm
D-L=Left Hemidiaphragm
RV=Right Ventricle
LV=Left Ventricle



THANK YOU