

GASTROESOPHAGEAL REFLUX DISEASE (GERD): A CASE STUDY

ABDULAZIZ M ALBAKER

ABSTRACT

Gastroesophageal Reflux Disease (GERD) has different signs and symptom depending on the severity of the disease. One of the early signs is dental erosion. It results from reflux of the gastric contents into the oral cavity. Dental erosion can cause teeth sensitivity, dental caries, lost vertical dimension and dental aesthetic problems. To restore the function and the aesthetic of the oral cavity, full mouth rehabilitation is sometimes indicated. The current case report is about a 45-year-old male who was diagnosed with GERD resulting in dental erosion. He underwent full mouth rehabilitation.

Key Words: *Gastroesophageal Reflux Disease (GERD), dental erosion, gastric reflux, full mouth rehabilitation.*

INTRODUCTION

Gastroesophageal Reflux Disease (GERD) is a relatively common condition, in which stomach acids are refluxed up through the esophagus and oral cavity, causing heartburn in stomach and dental erosion in the mouth.^{1,2,3} The condition is defined as the involuntary passage of gastric contents into the esophagus.⁴ Symptoms of GERD include pyrosis, heartburn, chest pain, hoarseness, asthma, recurrent pneumonia, chronic cough, otitis media, reflux laryngitis, and sore throat.^{5,6} The most important GERD symptom from the dental perspective is regurgitation, resulting in transportation of acidic gastric juices in the mouth following a reflux episode.⁷

Dentists are often the first health care professionals to diagnose systemic diseases through observation of oral manifestations. The GERD patients generally experience frequent vomiting, heartburn, belching, pain on awakening, acidic taste, and stomach pain.⁸ These patients are 31 times more likely to have dental erosion than others. Risk factors for GERD also include obesity, hiatal hernia, and pregnancy.^{9,10}

Dental erosion is defined as the progressive loss of hard dental tissues caused by a chemical process not involving bacterial action. Dental erosion has been associated with ingestion of acidic foods, bulimia, rumination and GERD.¹¹ In addition to causing dental erosion, undiagnosed and/or untreated GERD may also

result in esophagitis, Barrett's epithelium, esophageal adenocarcinoma and aspiration pneumonitis of various degrees. It is necessary that dentists recognize GERD so that timely preventive and curative measures can be instituted.^{12,13} GERD is one of the most common comorbidities, and a factor associated with exacerbation in patients with chronic obstructive pulmonary disease (COPD). Many COPD-related medications (except inhaled anticholinergics) are associated with increased risk of GERD.¹⁴

A survey conducted by the National Heartburn Alliance in 2000 estimated that 60 million Americans have GERD symptoms at least once per month, and 25 million adults have daily symptoms.⁶ A Saudi study in 2013 reported a GERD prevalence of 45% high compared to that reported in the literature.¹⁵ A systematic review reported a GERD range of 18.1-27.8% in North America¹⁶, 8.8-25.9% in Europe^{17,18}, 2.5-7.8% in East Asia¹⁹, and 8.7-33.1% in the Middle East.^{20,21}

CASE REPORT

A 45 year-old male came to the prosthodontic clinic of Marquette University College of Dentistry complaining of "short and ugly frontal teeth". His medical history revealed GERD since four years. The patient has been neglecting his teeth due to financial reason, though brushing his teeth twice a day. There was no history of dental bruxism. There was also no history of over-exposure to the etiologic factors associated with dental erosion such as ingestion of citrus fruits, vinegar and carbonated drinks. Upon clinical examination, generalized dental erosions affect mainly occlusal and buccal surface of posterior teeth and incisal and lingual surfaces of anterior teeth (Fig 1 & 2).

Dr Abdulaziz AlBaker, Associate Professor, Department of Prosthetic Dental Sciences, College of Dentistry, King Saud University, Riyadh, Saudi Arabia. **Correspondence:** Dr Abdulaziz AlBaker, PO Box 60169, Riyadh 11545, Kingdom of Saudi Arabia Email: aalbaker@ksu.edu.sa Phone: +966-11-4677237

Received for Publication: April 30, 2016
Accepted after minor revision: May 28, 2016

The objective of the dental treatment was to restore the lost teeth structures caused by the acid reflux, and ensure optimum dental function and aesthetic. The first 3 visits were for diagnostic data collection and analysis. The treatment plan was then finalized. Full mouth rehabilitation was planned for the patient.

Before starting the prostheses stage; all carious teeth (including recurrent caries) were restored with Filtek™ Supreme Ultra Universal Restorative (3M Center, St. Paul, MN 55144, USA). All abutment teeth were thoroughly examined. As some of the teeth did not have enough remaining coronal tooth structure for

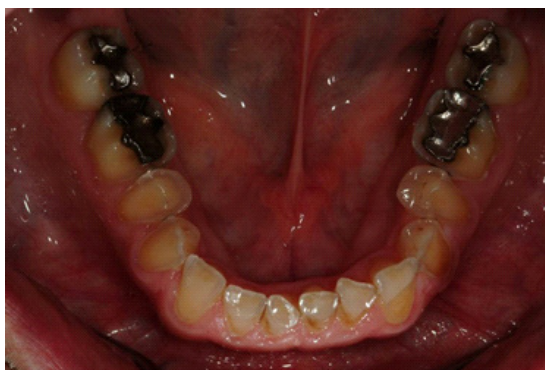

Fig 1: Intraoral mandibular occlusal view photograph showing enamel erosion on the occlusal and buccal surface

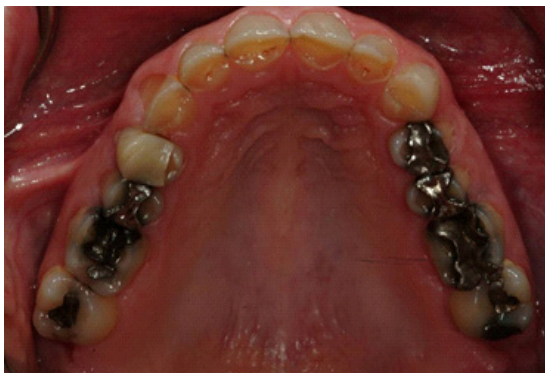

Fig 2: Intraoral maxillary occlusal view photograph showing enamel erosion on incisal and palatal surfaces

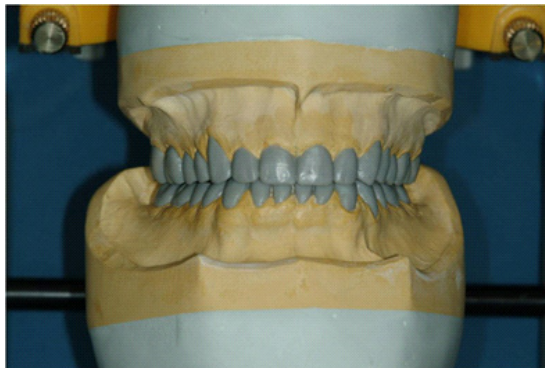


Fig 3: Frontal view photograph of mandibular and maxillary teeth diagnostic wax-up

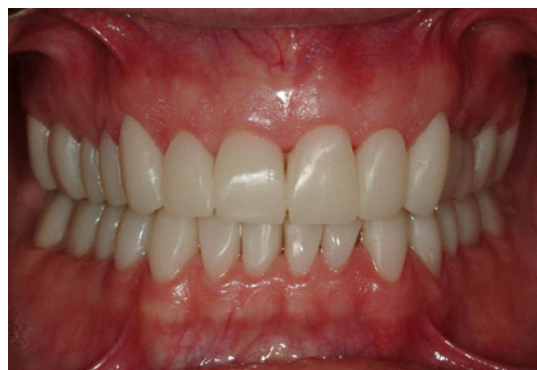

Fig 4: Frontal view photograph of mandibular and maxillary teeth provisional crowns

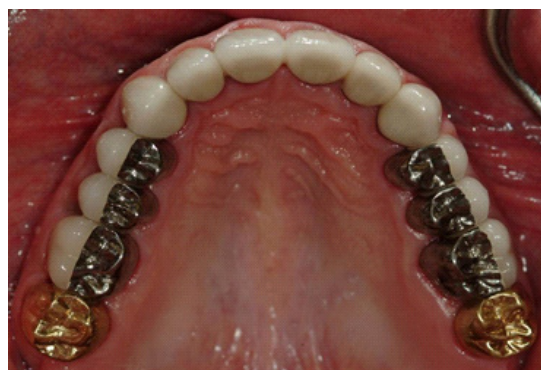

Fig 5: Intraoral Maxillary occlusal view photograph of the final crowns

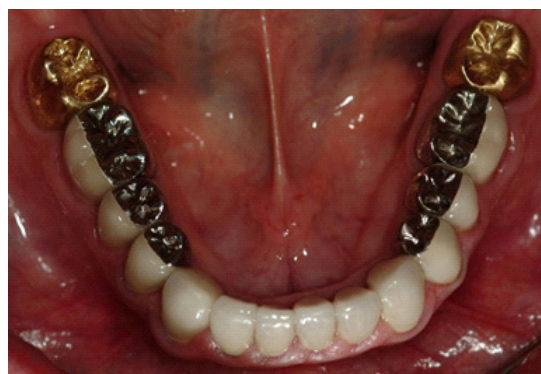

Fig 6: Intraoral Mandibular occlusal view photograph of the final crowns
adequate ferrule effect, crown lengthening surgery was performed.

A diagnostic wax-up was done to plan the anticipated occlusion and aesthetic outcome. Provisional crowns for the teeth were manufactured according to the diagnostic wax-up and index (Fig 3). Provisional crowns and the Fixed Dental Prosthesis (FDPs) were fabricated using autopolymerized acrylic resin ALIKE™ (GC 3737 W. 127th Street Alsip, IL 60803, USA).

The provisional crowns remained in the patients' mouth for one week to test function and aesthetic (Fig 4). A duplicate cast of the provisional crowns were

created to be used as a guide in the process of making final crowns. Final impressions of the prepared teeth were taken and sent to the dental laboratory to manufacture final prostheses which were metal-ceramic crowns except the second molars which were all-metal crowns. The final prostheses received from the dental laboratory were tried and cemented in the patients' mouth (Fig 5 & 6).

After the patient felt comfortable with the new provisional crowns for 3 weeks, impressions of the provisional crowns were made, and casts were poured. Final impressions were taken of all prepared natural teeth with polyvinylsiloxane (PVS) impression material (Virtual XD impressions, Ivoclar Vivadent Inc. 175 Pineview Drive Amherst, NY 14228, USA). Centric relation interocclusal records and preparation against provisional crowns were made with PVS material, LuxaBite from DMG America (242 South Dean Street, Englewood, NJ 07631, USA). Master casts were cross mounted against the casts of the provisional crowns which were used to guide the fabrication of the final prostheses. One week after the final crowns were cemented, the patient was called back to the clinic for re-evaluation. The patient was satisfied with the treatment and was motivated to maintain good oral hygiene practices. The patient was placed on a six month recall schedule.

DISCUSSION

Patients with GERD should be referred for dental consultations and a collaborative management of associated oral manifestations. Although; attrition, abrasion and erosion are part of aging process of any dentition, the wear rates of teeth should be monitored periodically to evaluate any abnormal tooth wear progression.²² Dietary changes may be beneficial if there are obvious dietary precipitants (coffee, chocolate or fatty foods) and, life style changes are warranted to reduce obesity, smoking or excessive alcohol use if present²³ However, lifestyle modifications alone are unlikely to eliminate the symptoms.

Prevention of further tooth wear is a priority in GERD patients. It involves local preventive, restorative and maintenance phases. Erosion of dental enamel in some cases can progress till the complete loss of the dental tissue. As there are many possible causes of enamel erosion, the diagnosis can be often difficult. The erosion of dental enamel is historically been an alarm symptom or warning sign and an indication for early endoscopy to rule out GERD.²⁴

In the present case the patients' ignorance delayed the proper medical intervention for four years causing severe damage to his teeth. Due to strong acidity of gastric juices the GERD patients are less prone to dental caries because of the effect of gastric acid on

bacteria.²⁵ Despite the high prevalence of dental enamel erosion, the etiological factors are not apparent. Intake of carbonated drinks were not exclusively been reported to be the plausible extrinsic factor for dental erosion. However, there is an increased risk which was reported for developing erosion even if someone consumes less than one litre of carbonated drink per week.²⁶

Although there is no special mention about voice problems, earlier studies proved that GERD can cause serious voice problems and laryngopharyngeal disorders influencing the patients' quality of life.^{27,28} This issue should be considered during the phonetic test during the try-in of the final prosthesis.

In this case, the patient never had any previous restorations, therefore, all aspects related to achieving optimum dental function and esthetics were considered before finalizing the treatment plan. The patient did not complain of specific about heartburn, belching, and unexplained sour taste. However, it is not necessary that all the patients with GERD experience all these symptoms, a condition known as "silent GERD".⁸

There is a widely held view that gastroesophageal reflux and its associated symptoms are trivial; leading very often to suboptimal treatment of these patients.²⁹ Recent data also suggest that every second GERD patient leaves dissatisfied with his/her treatment.² However; in this case, the plan for full mouth rehabilitation constructed in consensus with the patient. It was based on the severity of erosion and his functional and esthetic needs.²⁵ The diagnostic wax-up and index helped in teeth preparation and provisional crowns. The provisional crowns were tested and evaluated for their esthetics before going for the final prosthesis. Despite the excellent prognosis of the full mouth rehabilitation, ignoring the medical management of GERD; and lack of periodic dental recall visits can affect the longevity of the prosthodontic treatment.

ACKNOWLEDGEMENT

The author would like to acknowledge the support received from the staff of Prosthetic Dental Clinic in completing the treatment successfully. Special thanks to Mr. Ranan Kamalan for his support in keeping track of each phase in the publication process.

REFERENCES

1. Ali DA, Brown RS, Rodriguez LO, Moody EL, Nasr MF. Dental erosion caused by silent gastroesophageal reflux disease. *JADA* 2002; 133: 4.
2. Malfertheiner P, Hallerback B. Clinical manifestations and complications of gastroesophageal reflux disease (GERD). *Int J Clin Pract*. 2005; 59(3): 10.
3. Polat Z, Akgun ÖM, Turani, Polat GG, Altun C. Evaluation of the relationship between dental erosion and scintigraphically detected gastroesophageal reflux in patients with cerebral palsy. *Turkish Journal of Medical Sciences* 2013; 43: 6.

- 4 Silva MAGS, Damante JH, Stipp ACM, Tolentino MM, Roque P, Carlotto, et al. Gastroesophageal reflux disease: New oral findings. *Oral Surgery Oral Medicine Oral Pathology* 2001; 91(3): 10.
- 5 Broliato GA, Volcato DB, Reston EG, Kramer PF, Marquezan M, Ruzzarin F, et al. Esthetic and functional dental rehabilitation in a patient with gastroesophageal reflux. *Quintessence Int* 2008; 39(2): 7.
- 6 Patrick L. Gastroesophageal Reflux Disease (GERD): A Review of Conventional and Alternative Treatments. *Alternative Medicine Review* 2011; 16(2): 18.
- 7 Ersin NK, Öncag Ö, Tümgör G, Aydogdu S, Hilmioglu S. Oral and Dental Manifestations of Gastroesophageal Reflux Disease in Children: A Preliminary Study. *Pediatric Dentistry* 2006; 28(3): 6.
- 8 Ranjitkar S, Smales RJ, Kaidonis JA. Oral manifestations of gastroesophageal reflux disease. *Journal of Gastroenterology and Hepatology* 2011; 27: 7.
- 9 Roekel NBV. Gastroesophageal Reflux Disease, Tooth Erosion, and Prosthodontic Rehabilitation: A Clinical Report. *Journal of Prosthodontics* 2003; 12(4): 5.
- 10 Carretero JLC, Calleja JML. Gastroesophageal reflux diagnosed by occlusal splint tintion. *Med Oral Patol Oral Cir Bucal* 2006; 11(E): 3.
- 11 Barron RP, Carmichael RP, Marcon MA, GKB. Sándor. Dental Erosion in Gastroesophageal Reflux Disease. *Journal of the Canadian Dental Association* 2003; 69(2): 6.
- 12 Yoshikawa H, Furuta K, Ueno M, Egawa M, Yoshino A, Kondo S, et al. Oral symptoms including dental erosion in gastroesophageal reflux disease are associated with decreased salivary flow volume and swallowing function. *J Gastroenterol* 2012; 47: 9.
- 13 Bartlett D, Anggiansah A, Smith B, Kidd E. The role of regurgitation and other symptoms of reflux disease in palatal dental erosion; an audit project. *Ann R Coll Surg Engl* 2001; 83: 3.
- 14 Kim J, Lee JH, Kim Y, Kim K, Oh YM, Yoo KH, et al. Association between chronic obstructive pulmonary disease and gastroesophageal reflux disease: a national cross-sectional cohort study. *BMC Pulmonary Medicine* 2013; 13(51): 10.
- 15 M. A Almadi, M. A Almousa, A. F Althwainy, A. M Altamimi, H. O Alamoudi, H. S Alshamrani, et al. Prevalence of Symptoms of Gastroesophageal Reflux in a Cohort of Saudi Arabians: A Study of 1265 Subjects. *Saudi J Gastroenterol* 2014; 20: 7.
- 16 H. K Jung, S. Halder, M. McNally, G. R. Locke, C. D. Schleck, A. R. Zinsmeister, et al. Overlap of gastro-oesophageal reflux disease and irritable bowel syndrome: prevalence and risk factors in the general population. *Aliment Pharmacol Ther* 2007; 26: 9.
- 17 M. Diaz-Rubio, C. Moreno-Elola-Olaso, E. Rey, G. R. Locke, Rodriguez-Artalejo F. Symptoms of gastro-oesophageal reflux: prevalence, severity, duration and associated factors in a Spanish population. *Aliment Pharmacol Ther* 2004; 19: 11.
- 18 C. Valle, F. Broglia, A. Pistorio, C. Tinelli, Perego M. Prevalence and Impact of Symptoms Suggestive of Gastroesophageal Reflux Disease. *Digestive Diseases and Sciences* 1999; 44(9): 5.
- 19 J. He, X. Ma, Y. Zhao, R. Wang, X. Yan, H. Yan, et al. A population-based survey of the epidemiology of symptom-defined gastroesophageal reflux disease: the Systematic Investigation of Gastrointestinal Diseases in China. *BMC Gastroenterology* 2010; 10: 10.
- 20 A. Mostaghni, D. Mehrabani, F. Khademolhosseini, S. J Masoumi, F. Moradi, N. Zare, et al. Prevalence and risk factors of gastroesophageal reflux disease in Qashqai migrating nomads, southern Iran. *World Journal of Gastroenterology* 2009; 15(8): 5.
- 21 A. Solhpour, M. A Pourhoseingholi, F. Soltani, A. Zarghi, M. Habibi, F. Ghafarnejad, et al. Gastro-esophageal reflux symptoms and body mass index: no relation among the Iranian population. *Indian J Gastroenterol*. 2008; 27(4): 3.
- 22 Touyz LZG, Anouf A, Borjian A, Ferrari C. Dental erosion and GORD - Gastro Oesophageal Reflux Disorder. *International Dentistry SA* 2014; 12(4): 8.
- 23 Kahrilas PJ. Gastroesophageal Reflux Disease. *The New England Journal of Medicine* 2008; 359: 8.
- 24 Katz PO, Gerson LB, Vela MF. Guidelines for the Diagnosis and Management of Gastroesophageal Reflux Disease. *Am J Gastroenterol* 2013; 22.
- 25 Guo J, Reside G, Cooper LF. Full-mouth rehabilitation of a patient with gastroesophageal reflux disease: a clinical report. *J Prosthodont* 2011; Suppl 2: 5.
- 26 Jensdottir T, Arnadottir IB, Thorsdottir I, Bardow A, Gudmundsson K, Theodors A, et al. Relationship between dental erosion, soft drink consumption, and gastroesophageal reflux among Icelanders. *Clin Oral Invest* 2004; 8: 6.
- 27 Makhadoom N, Abouloyoun A, Bokhary HA, Dhafar KO, Gazzaz ZJ, Azab BA. Prevalence of gastroesophageal reflux disease in patients with laryngeal and voice disorders. *Saudi Med J*. 2007; 28(7): 4.
- 28 Vashani K, Muruges M, Hattiangadi G, Gore G, Keer V, Ramesh VS, et al. Effectiveness of voice therapy in reflux-related voice disorders. *Diseases of the Esophagus* 2010; 23: 6.
- 29 I. M Modlin, S. F Moss, M. Kidd, Lye KD. Gastroesophageal Reflux Disease Then and Now. *J Clin Gastroenterol* 2004; 38(5): 14.