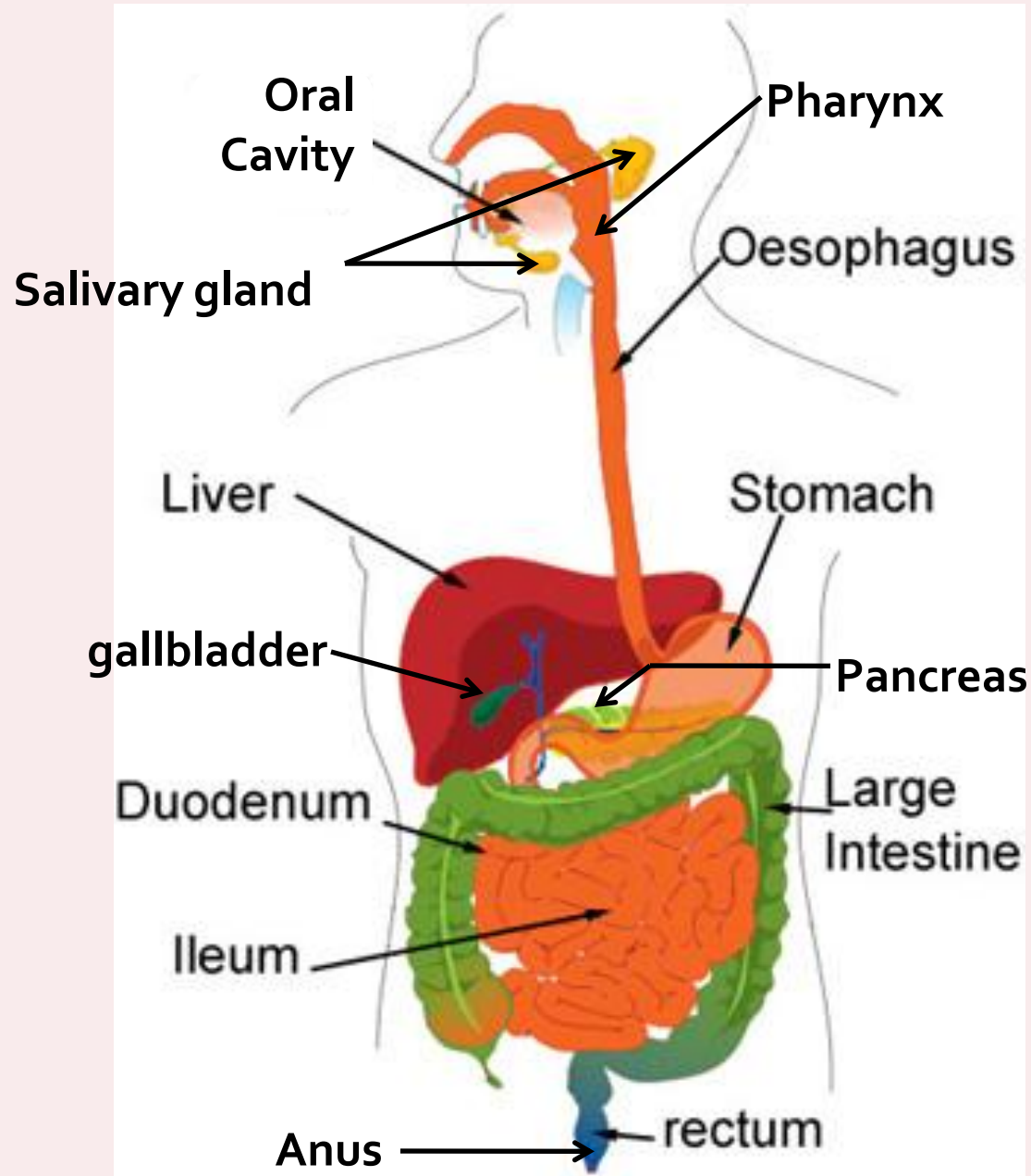


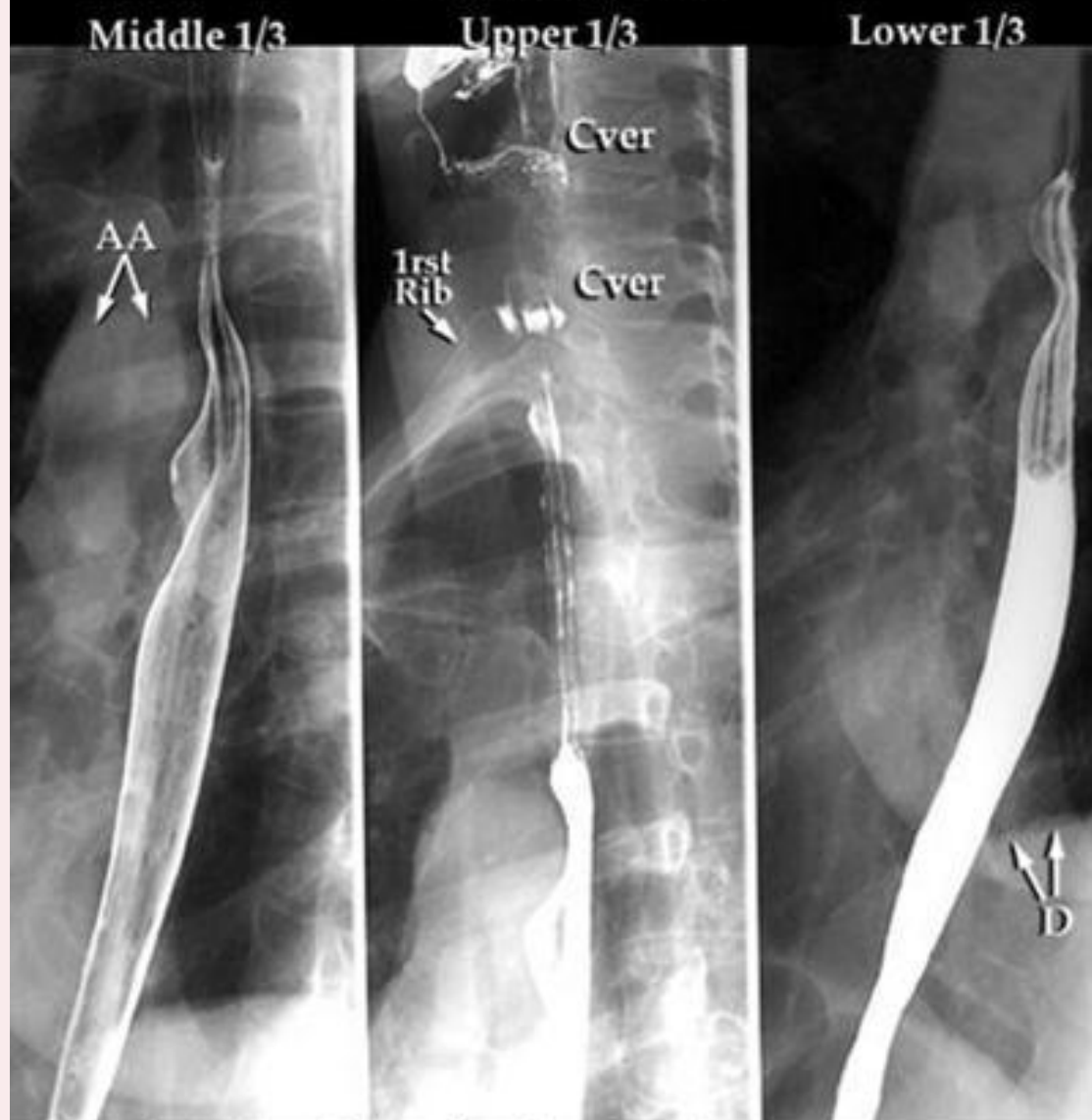


DIGESTIVE SYSTEM

Digestive System



Esophogram

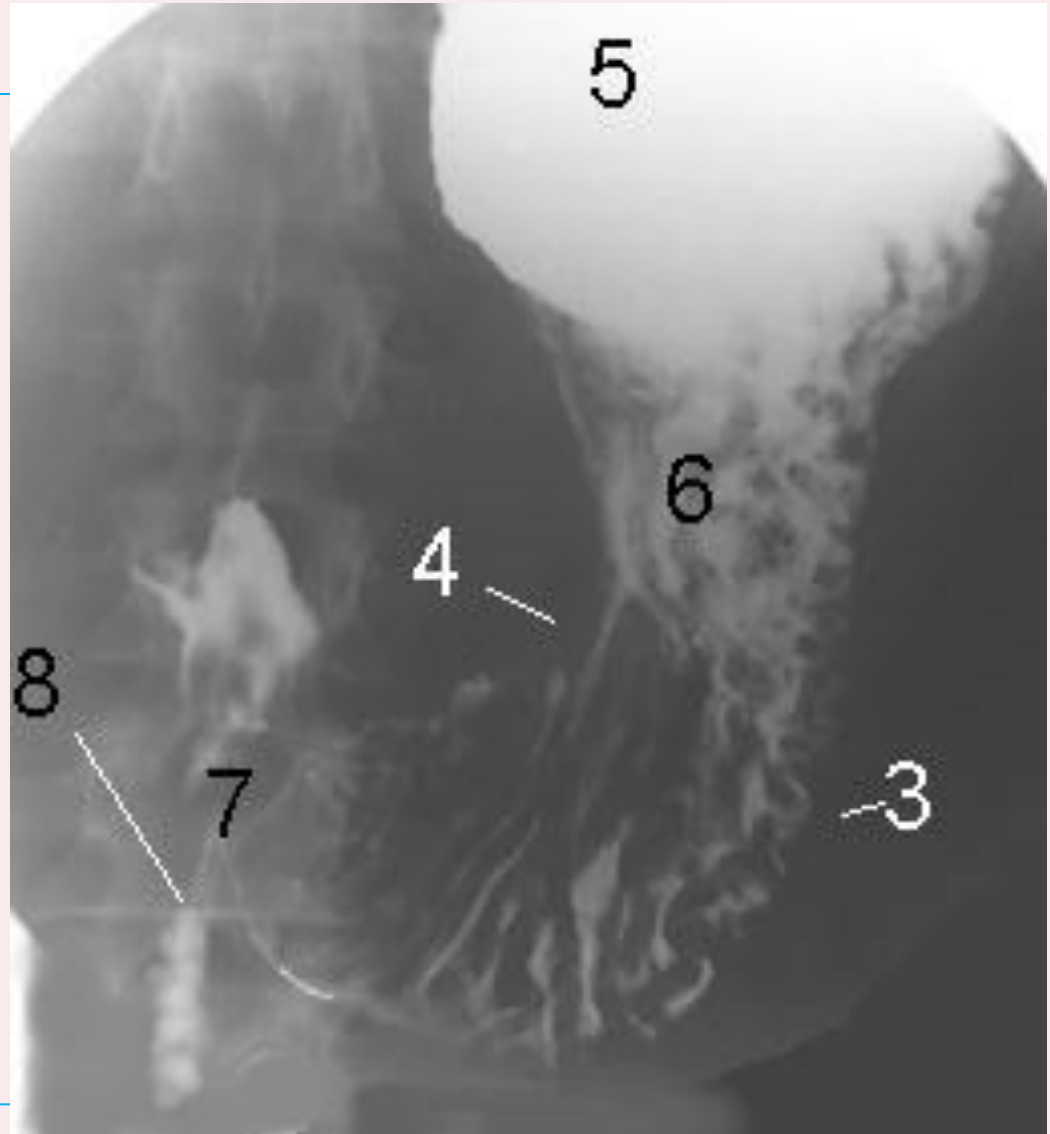


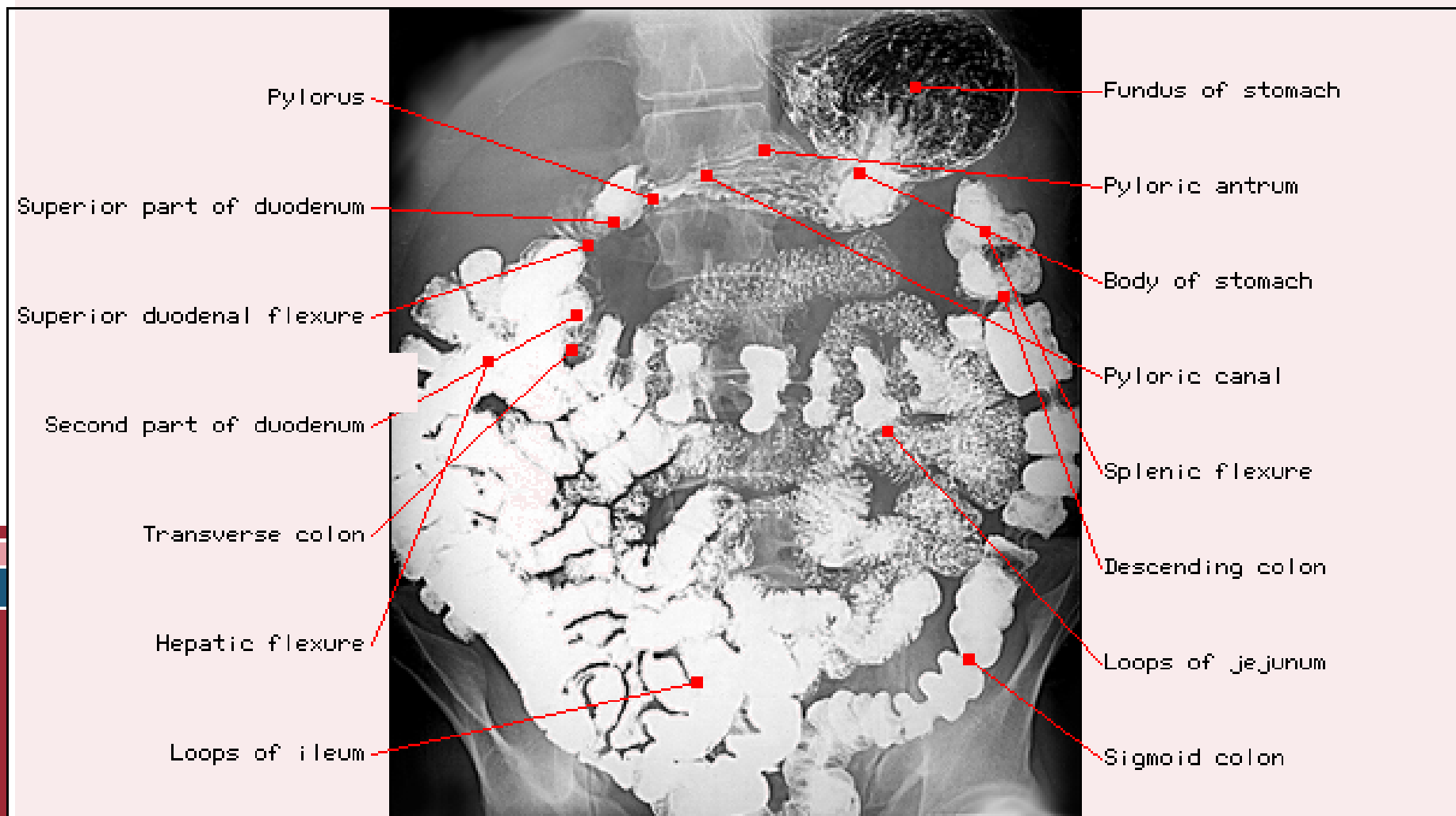
AA=Aortic Arch (note indentation of esophagus)

Cver=Cervical Vertebra

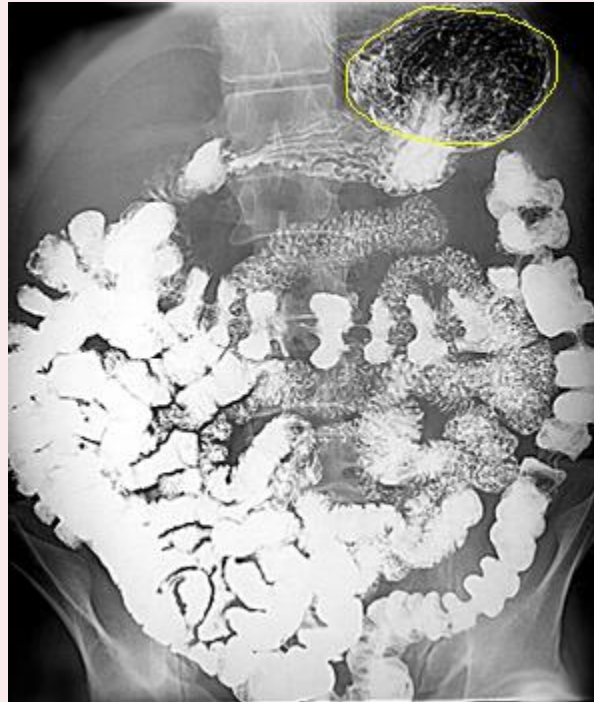
D=Diaphragm

- greater curvature (3)
- lesser curvature (4)
- fundus (5)
- the body (6) of the stomach
- pyloric region (7)
- (8) second part of the duodenum

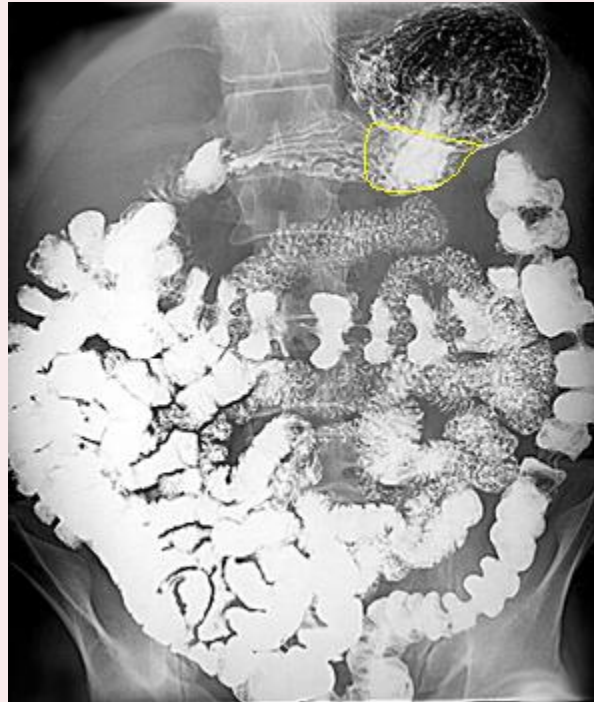



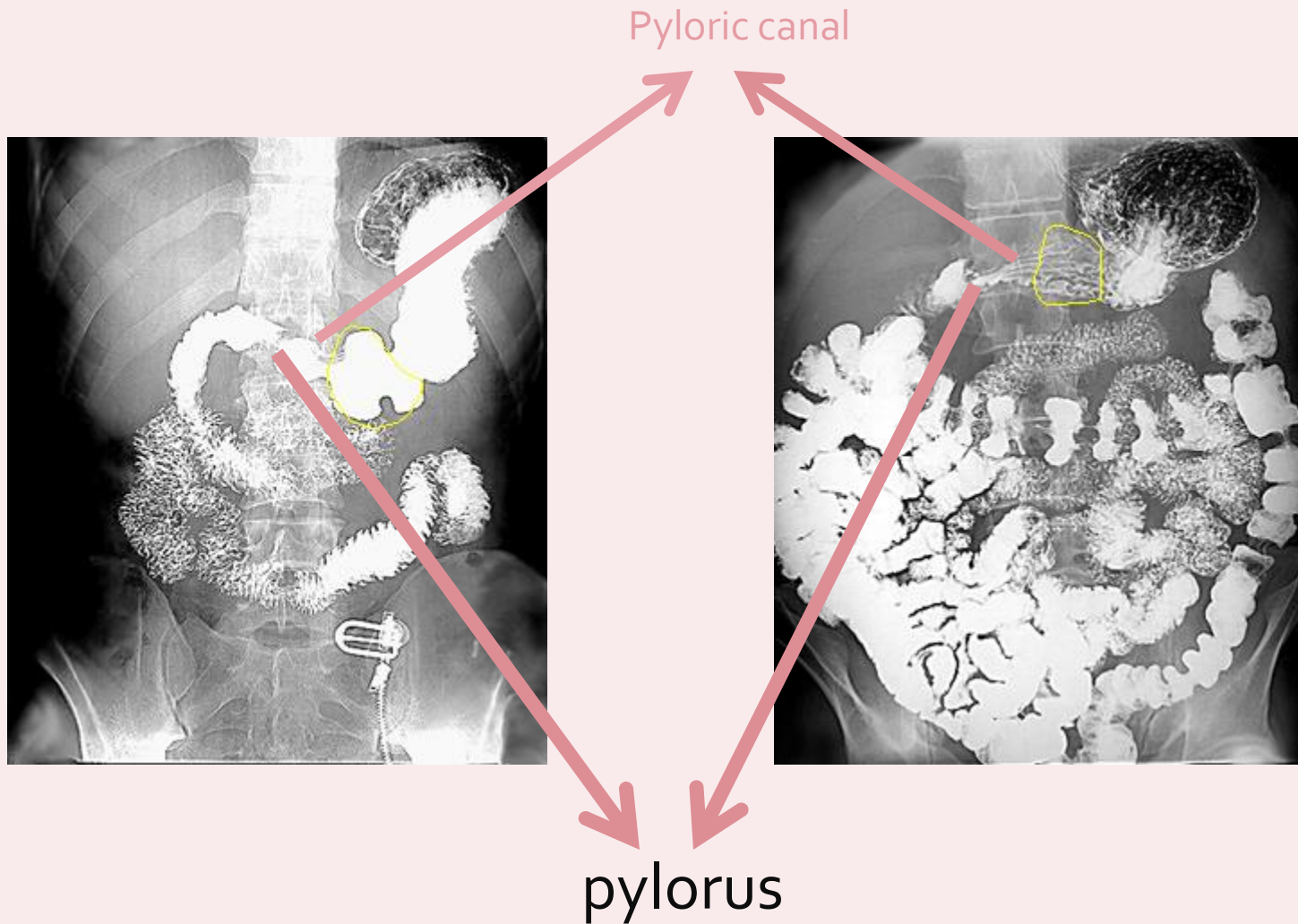
Fundus of stomach



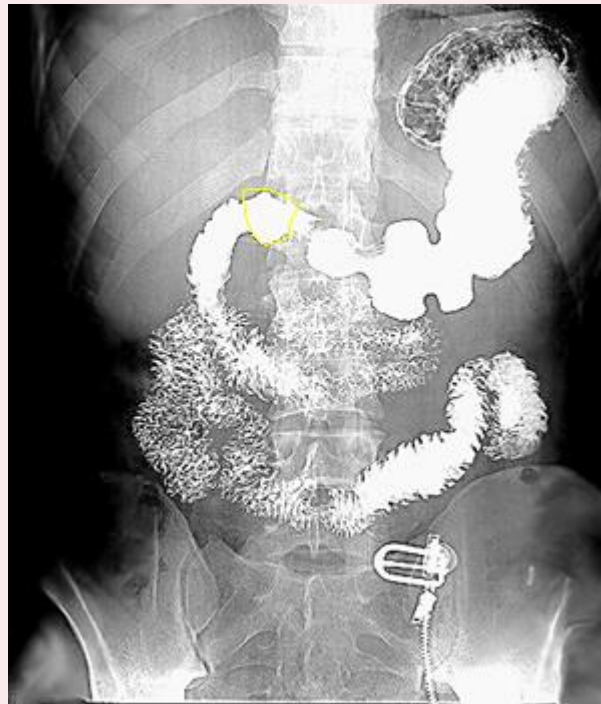
Body of stomach



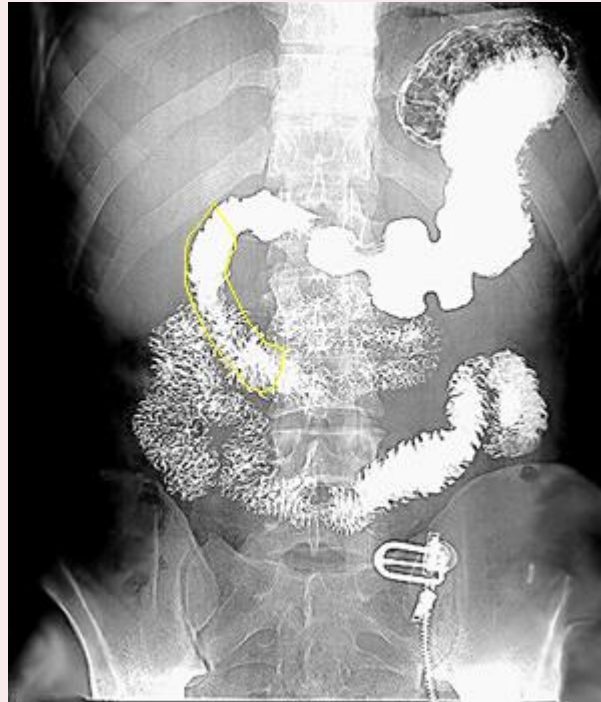
Pyloric antrum



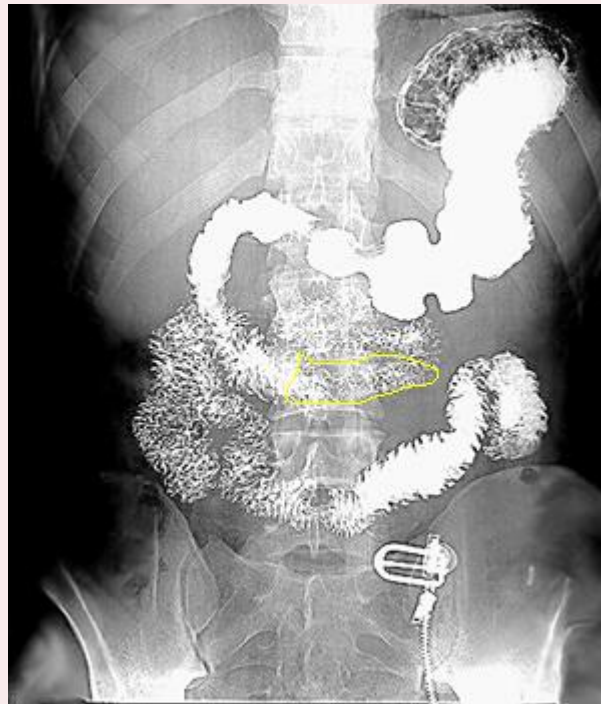
1st superior part of Duodenum)



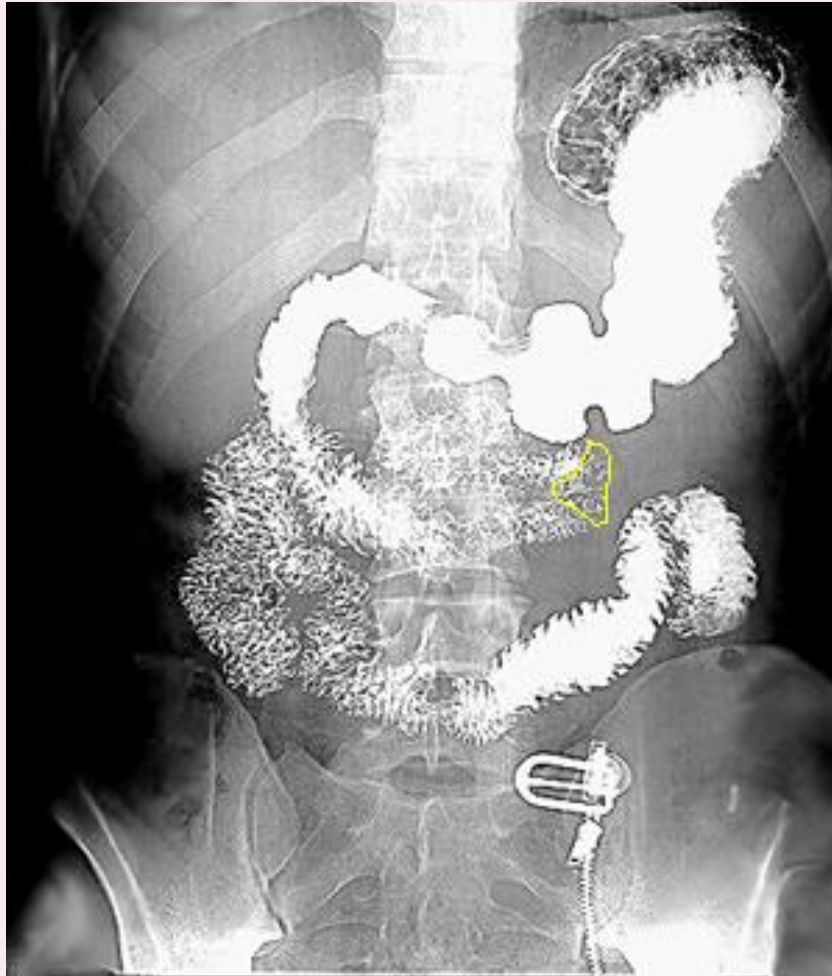
2nd (Descending part of duodenum)



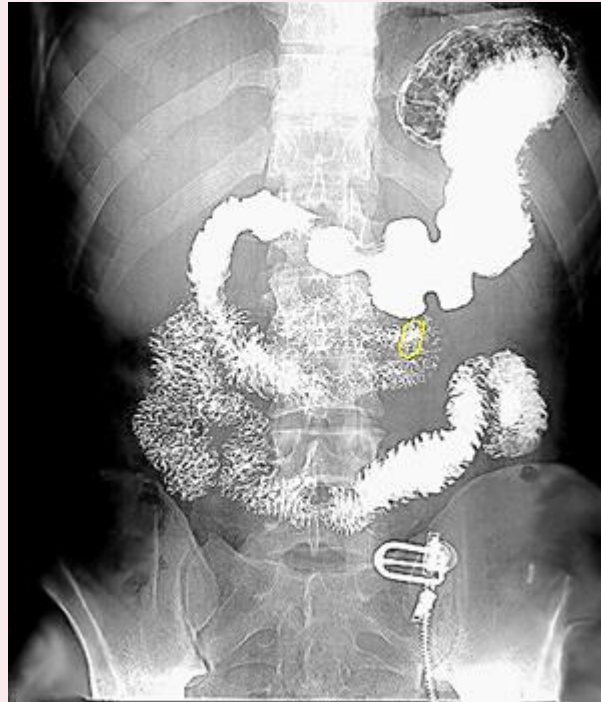
3rd (Horizontal part of duodenam)



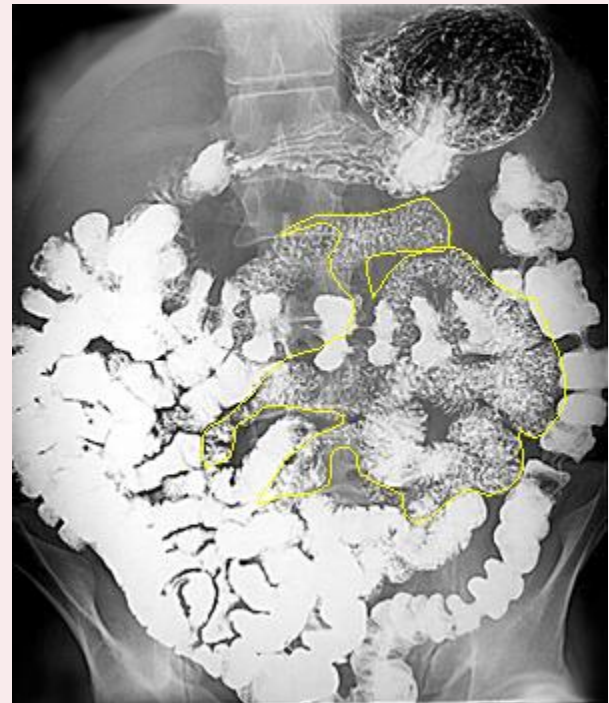
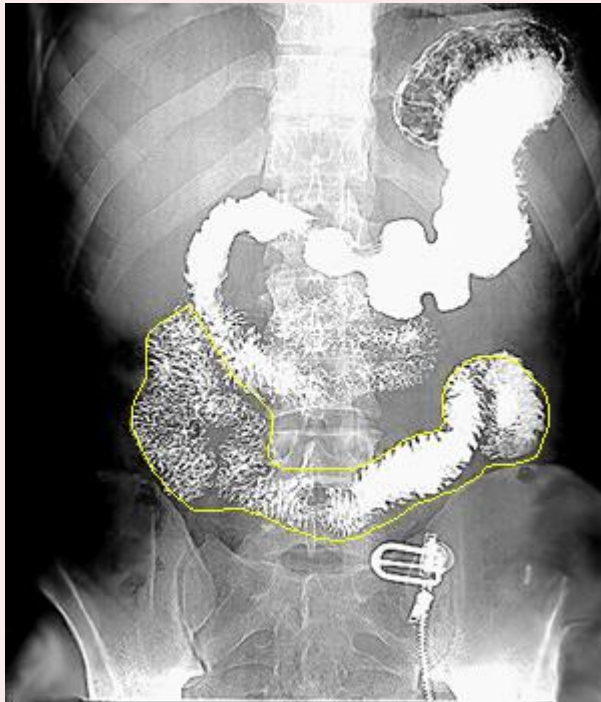
4th (Ascending part of duodenum)



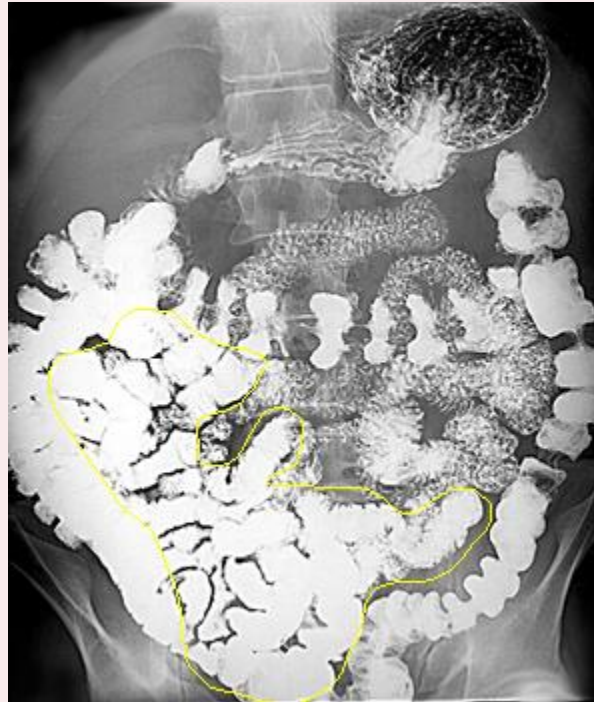Duodenojejunal junction



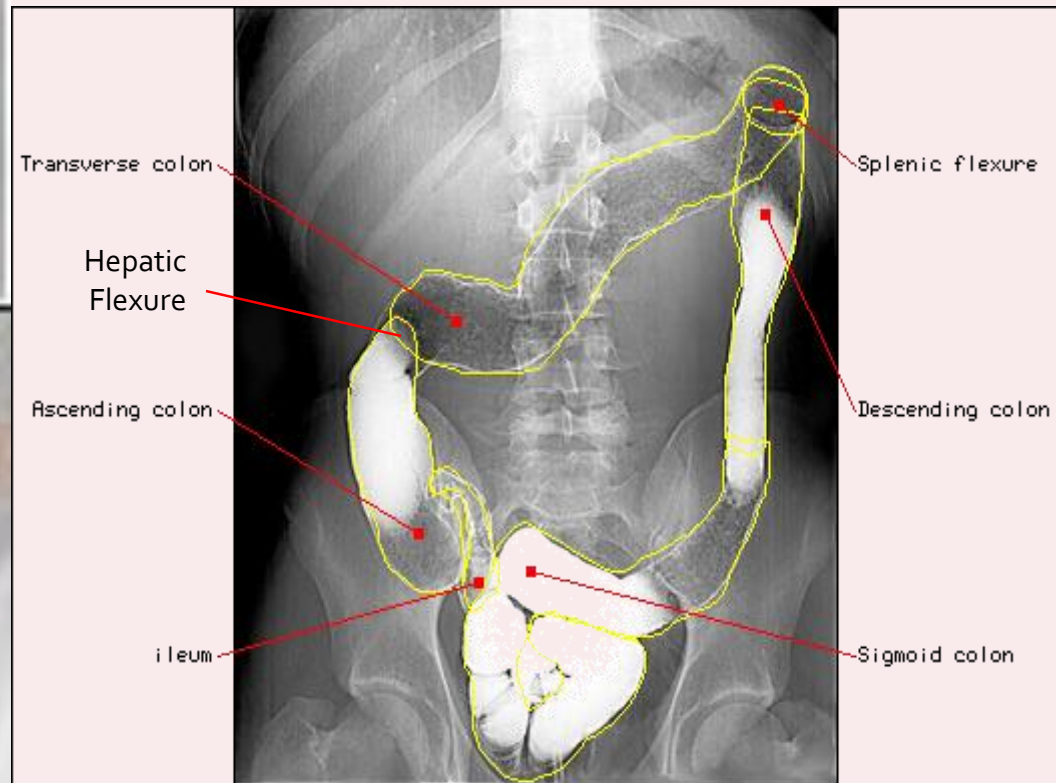
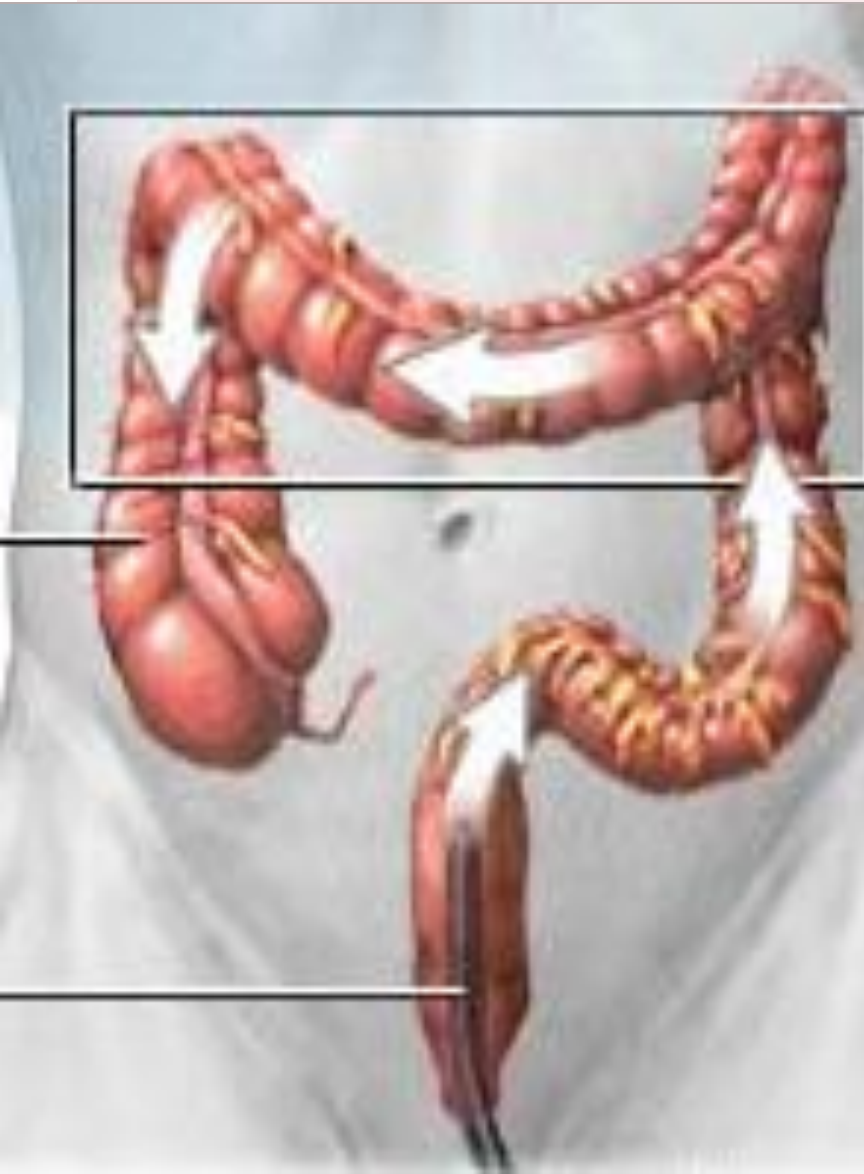Jejunum



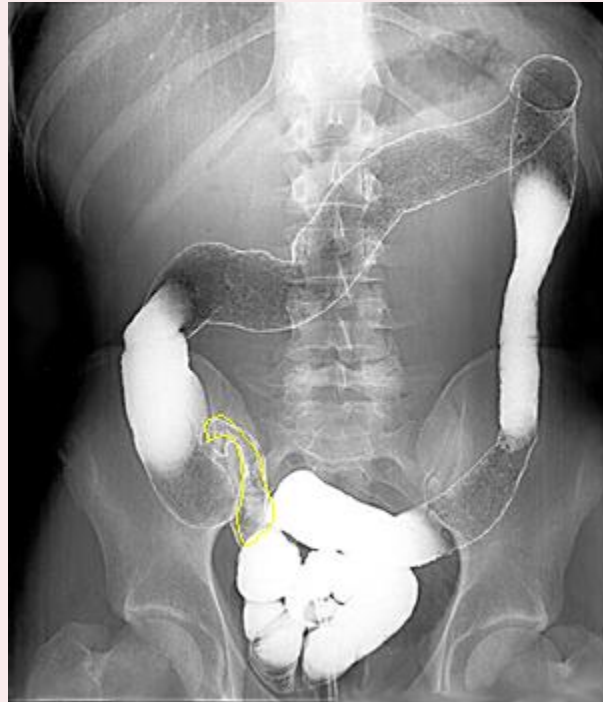
Ileum



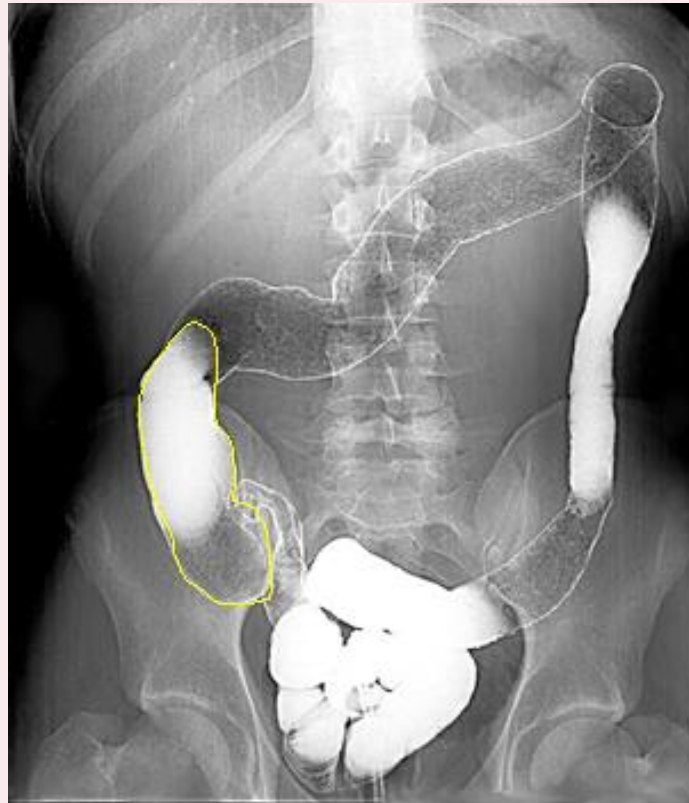
Barium Enema



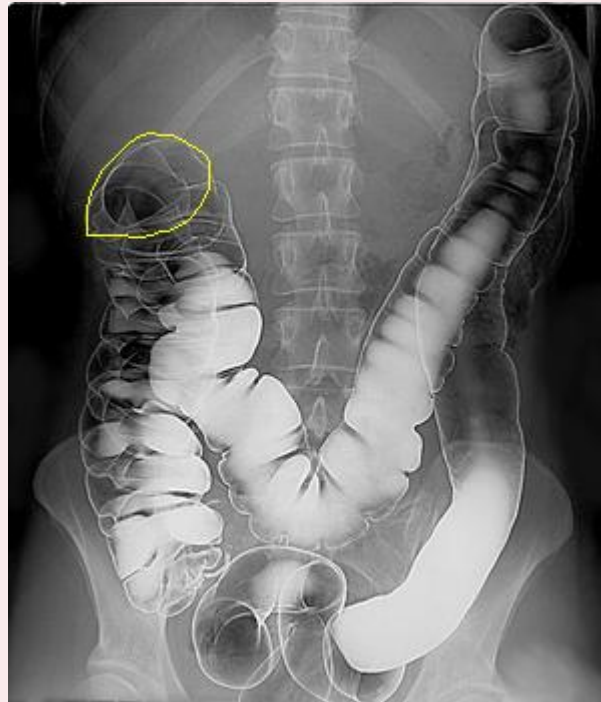
Ileum



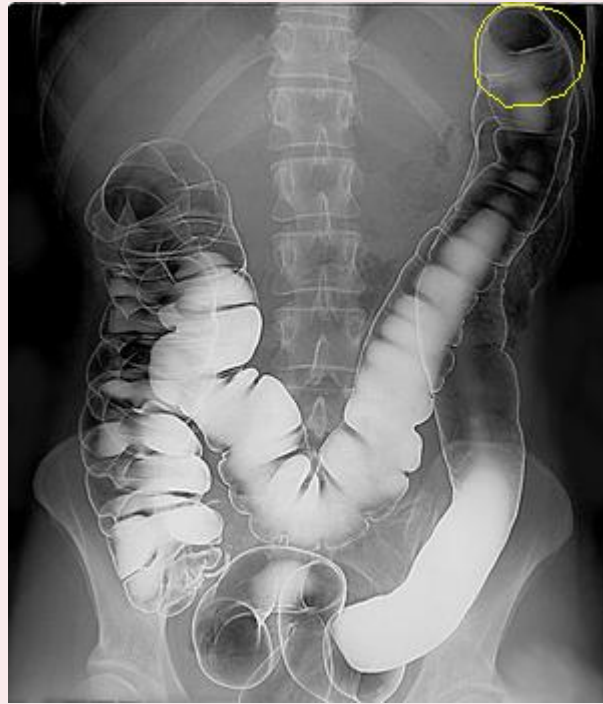Ascending colon



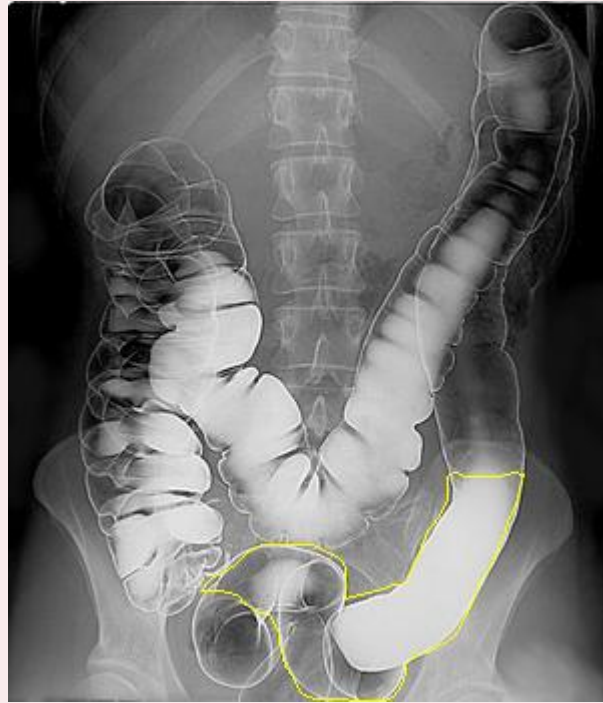
Hepatic flexure

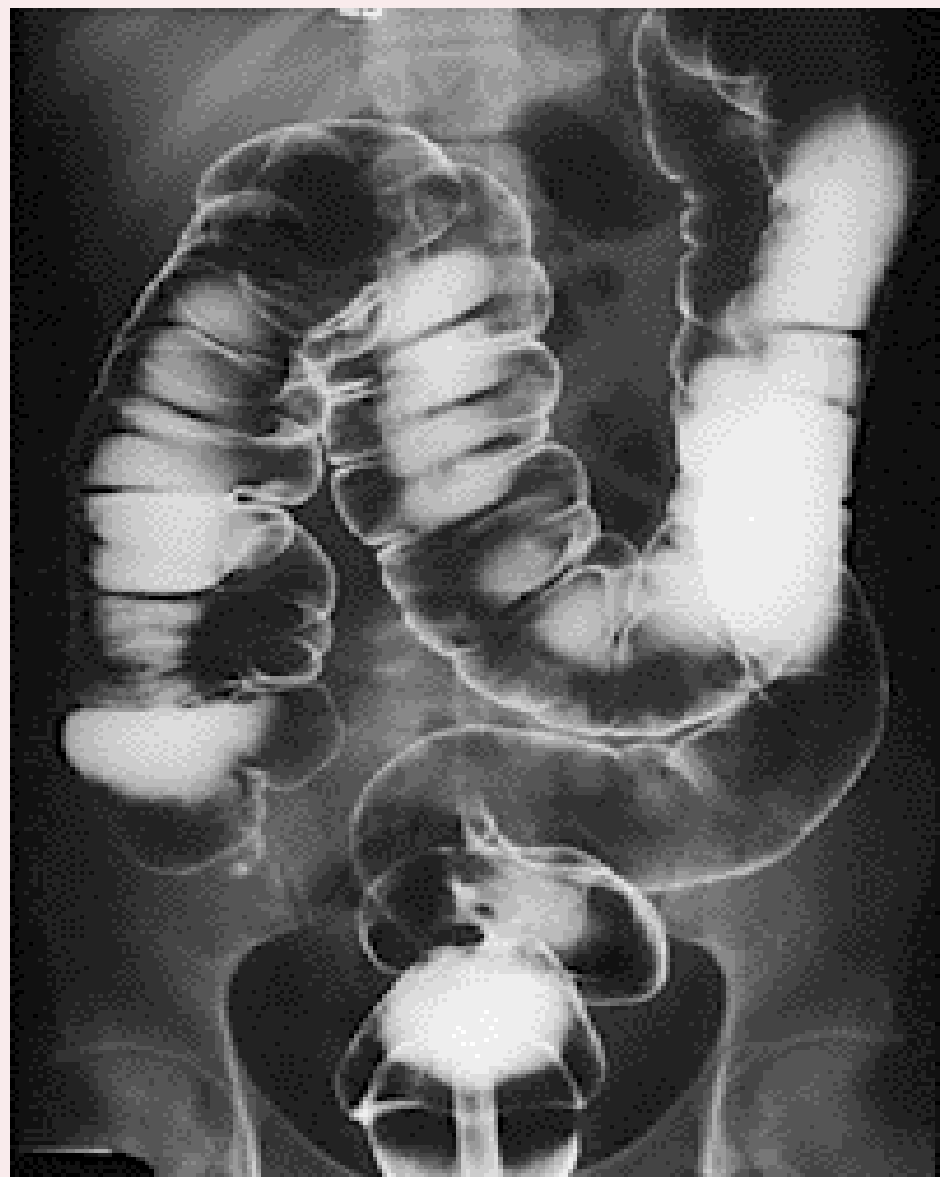
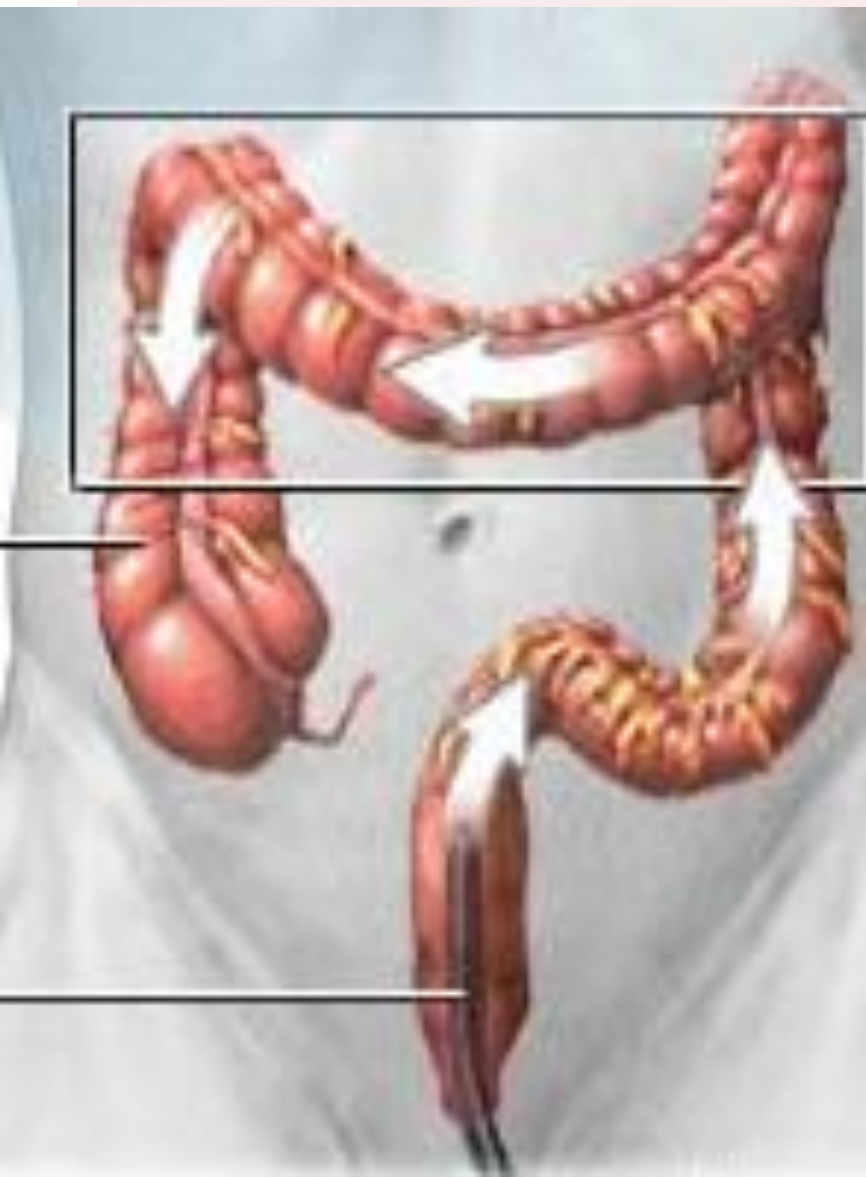

Splenic flexure



Sigmoid







THANK YOU

