



# ABDOMEN

# ABDOMEN TECHNIQUE

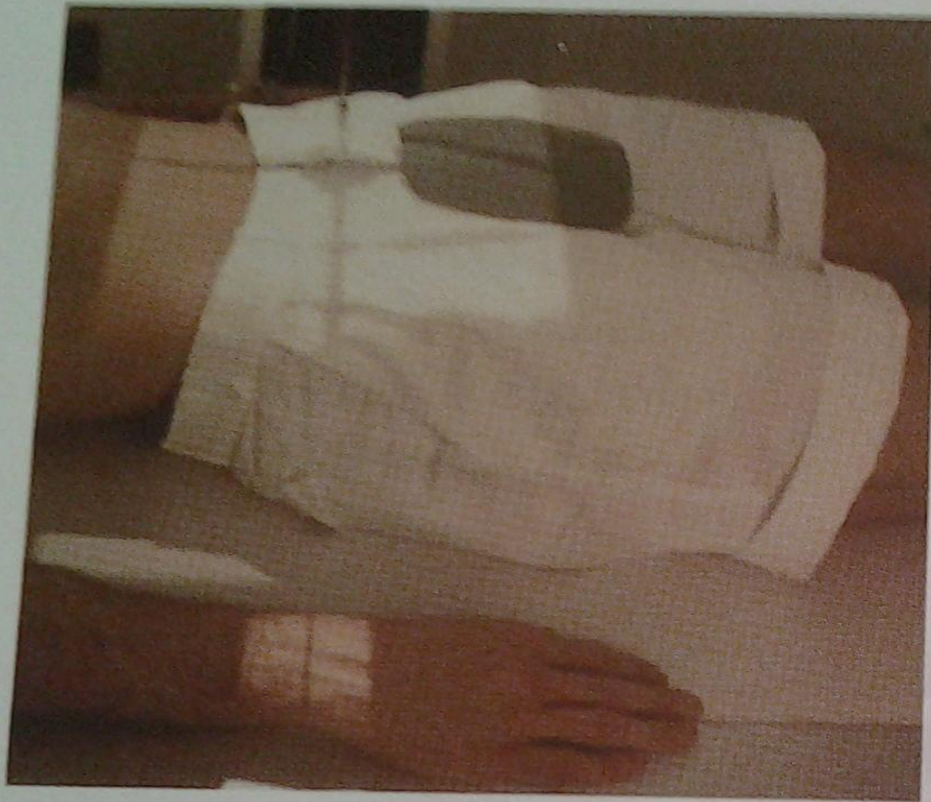High mA and shorter exposure times should be used to freeze voluntary and involuntary organ movements (breathing and bowel peristalsis).

Medium to maximum image contrast with maximum sharpness for soft tissue by using medium kV range (65-80) to visualize abdomen structures.

Correct exposure factor should produce more gray-tone contrast that will show the lateral borders of Psoas muscle, lower liver margin, kidneys outline & the transverse process of L vertebra.

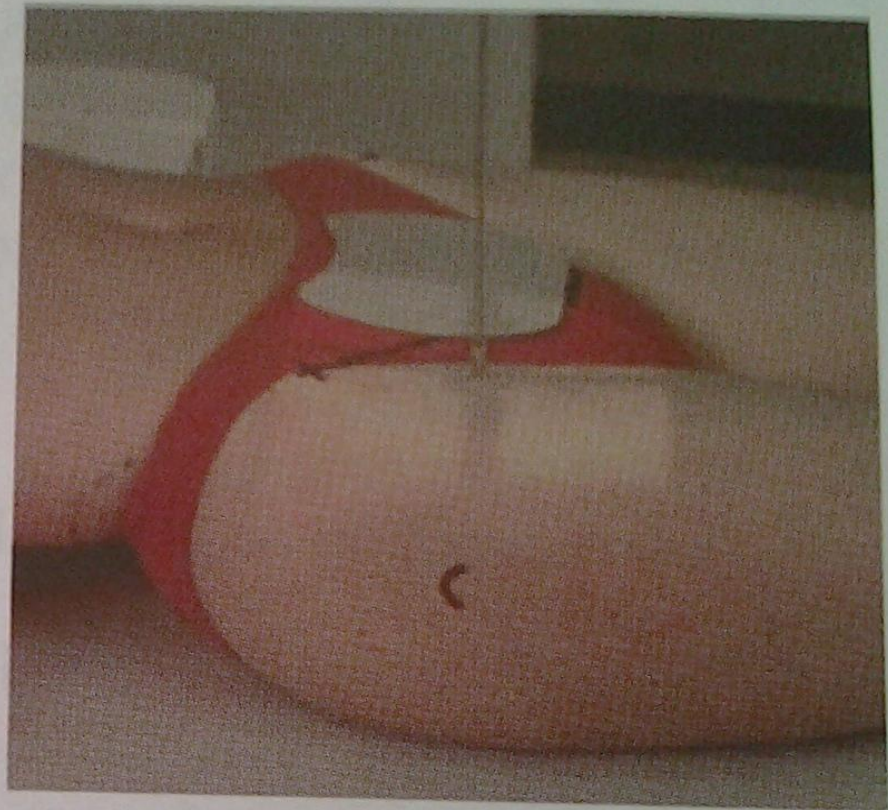
Exposure is taken on full arrested *expiration* (to displace the diaphragm upward). This will give better view of the abdominal structures.

Gonad shields should often be used on males (upper edge of the shield at the Symphysis pubis). For females, shields are used only where they could not obscure essential anatomical structures (lower border of the shield should be at the Symphysis pubis).



**Fig. 1-175.** AP pelvis. Flat contact shield—(1-mm lead equivalent).

—Male gonadal shield



**Fig. 1-176.** AP right hip. Flat contact shield—(1-mm lead equivalent).

—Female ovarian shield





# Technical aspects

✱ Careful preliminary patient *preparation* of the intestinal and gastric contents is important for a clear view of all abdominal structures. For non-acute conditions, patient preparation is as follows:

- (1) Patient placed on a low-residue diet for (2 days) prior to x-ray examination to prevent formation of gas due to the excessive fermentation of the intestinal contents
- (2) Patient should be instructed to take some ( laxative ) the night before the examination, and a cleansing enema next morning (usually normal saline solution) not more than two hours before the examination. The enema must be at the body's normal temperature (37°C).

Basic projections for plain abdomen: AP supine, AP erect and lateral decubitus.  
Special projections : PA prone, lat and dorsal decubitus.

# Acute abdomen

- ✿ Is an **EMERGENCY** case indicated for: Non-mechanical small bowel obstruction (ileus), the mechanical bowel obstruction (from the effects of hernia or adhesions), ascites, intra-abdominal mass, and post-surgery.
- ✿ Exam is carried out with high power x-ray equipment in the x-ray department, or in wards, for patients too ill to come to the department.
- ✿ Radiographs to be taken for the acute abdomen are:
  - (1) Erect PA (or AP) chest to exclude *basal pneumonia* as a cause of upper abdominal pain.
  - (2) AP plain supine abdomen.
  - (3) AP Erect abdomen (or, alternatively, a lateral decubitus).
  - (4) Supine decubitus (lateral recumbent if the patient is uncooperative).

# Technical aspects

REMEMBER

**NEVER ..**

prepare an *acute abdomen* patient !

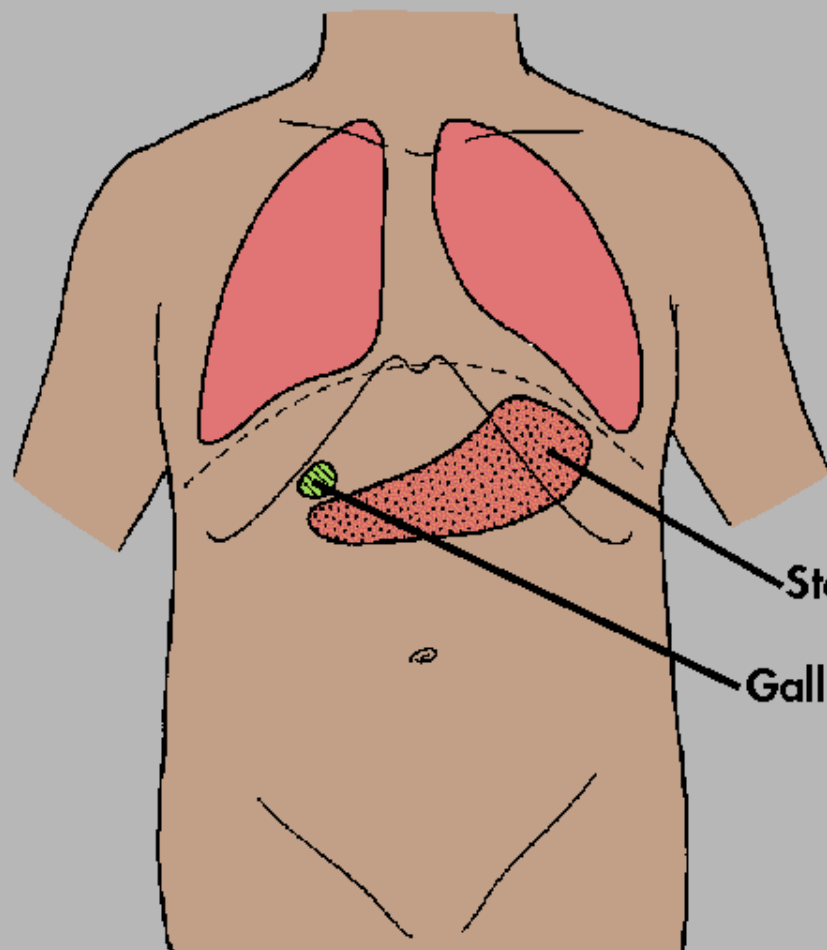




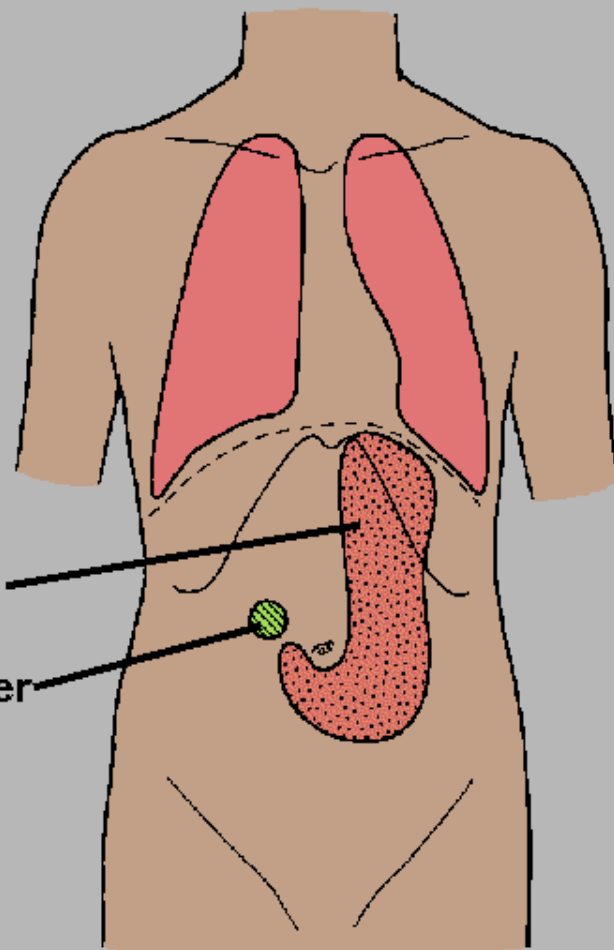
## **PLAIN ABDOMEN(KUB)**

### **Kidney-ureter -bladder**

- The plain abdomen (KUB) shows the kidneys ,ureters, urinary bladder and gallbladder (usually prior to contrast studies such as barium meal, barium enema & IVU) **to exclude radiopaque renal or gallstones, abnormal intra-abdominal masses and the state of bowel preparation.**
- All acute abdomen emergency conditions resulting from intestinal (bowel) obstructions, perforations with intra peritoneal air ,i.e., small free-air outside the digestive tract),will require several projections for the abdomen in different positions.



**HYPERSTHENIC**



**ASTHENIC**

**Stomach**

**Gall bladder**



## **AP PLAIN ABDOMEN – supine (KUB)      B**

**Film:** 35x43 cm lengthwise (must include diaphragm and symphysis pubis).

**Exposure factor:** 75-80 KVp      15-22 mAs

**SID:** 100cm (40 inches)

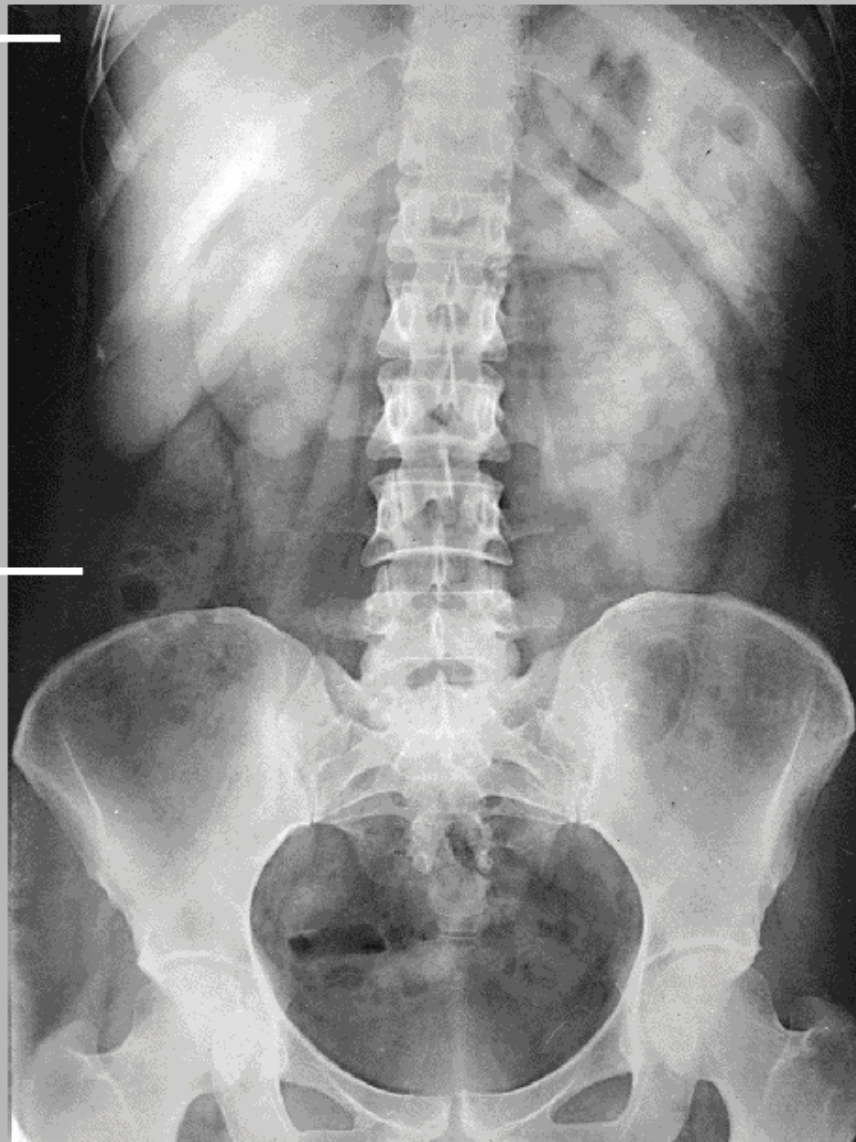
**Respiration:** at end of expiration.

**CR:** 90° vertically to film center.

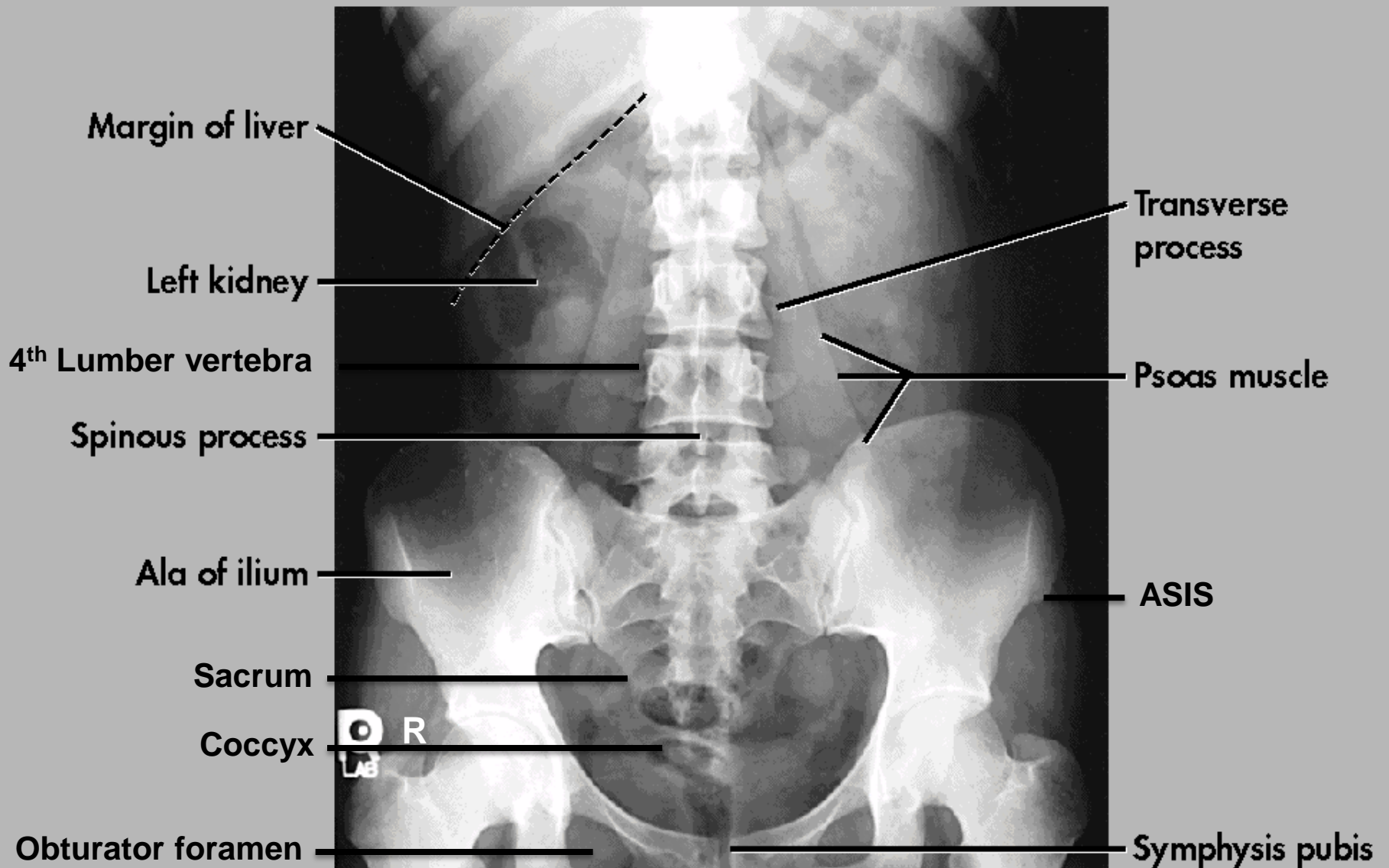
**CP:** Level of iliac crest (L4), with bottom margin of the film at the Symphysis pubis.



Right upper  
quadrant



**AP ABDOMEN**



AP ABDOMEN  
KUB – supine

## PA PLAIN ABDOMEN – prone (KUB) S

Less desirable than AP, why?

**Film:** 35x43 cm lengthwise (must include diaphragm and symphysis pubis).

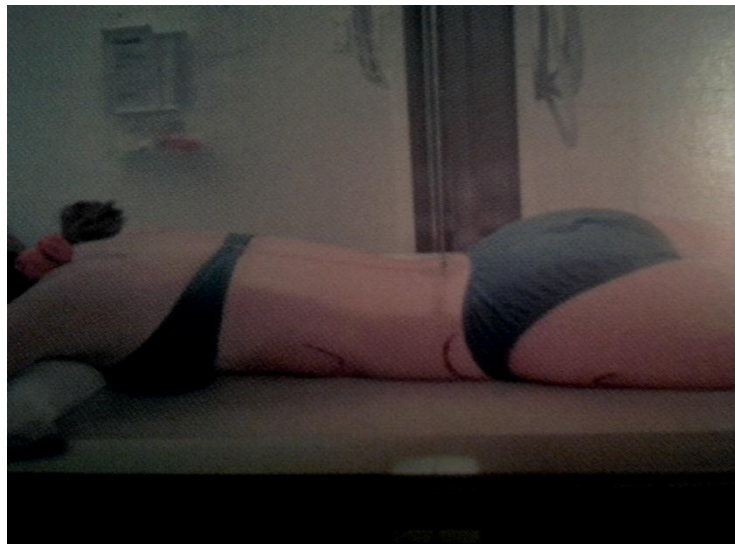
**Expouser factor:** 80 KVp      22 mAs

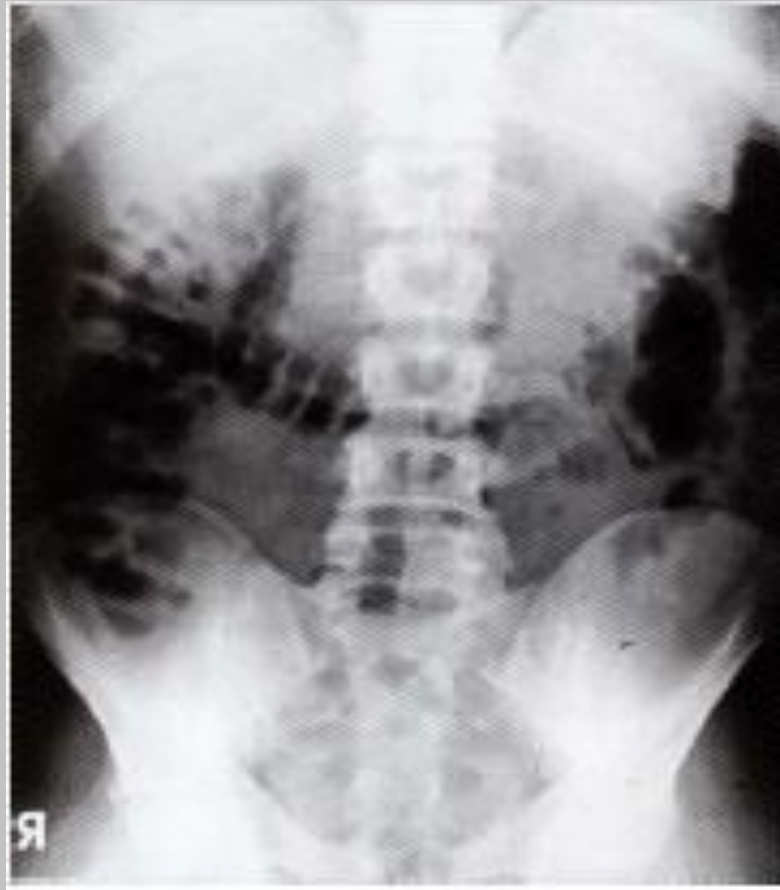**SID:** 100cm (40 inches)

**Respiration:** at end of expiration.

**CR:** 90°vertically to film center.

**CP:** Level of iliac crest (L4), with bottom margin of the film at the Symphysis pubis.





**PA ABDOMEN**

**KUB – prone**



## LATERAL RECUMBENT VIEW S

**Film:** 35x43 cm lengthwise. Lead blocker on tabletop behind pt.(to reduce scatter because L spine is thick area ).

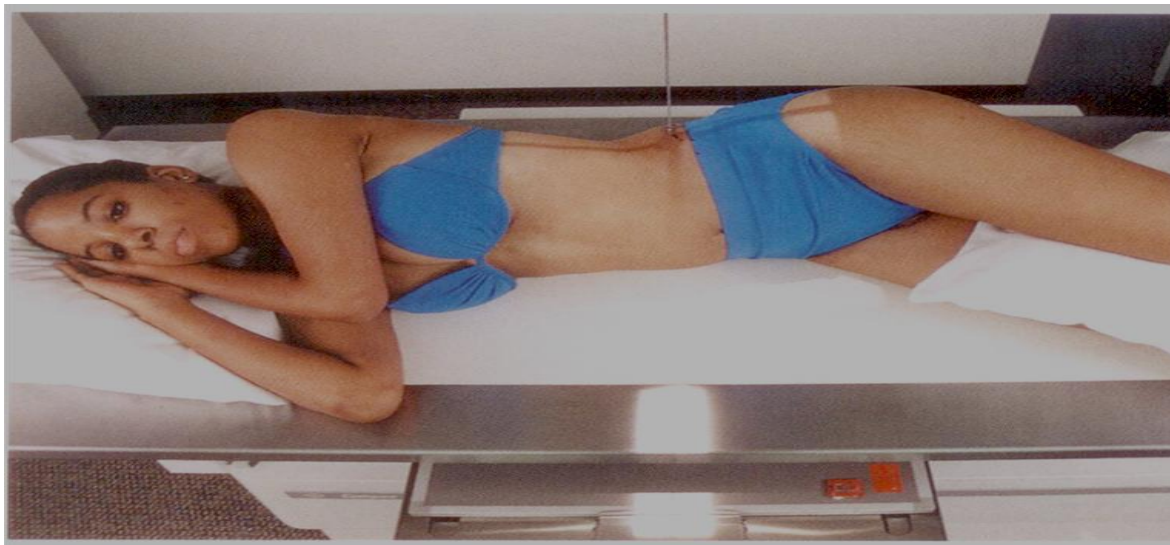
**Exposure factor:** 80 KVP      60 mAs

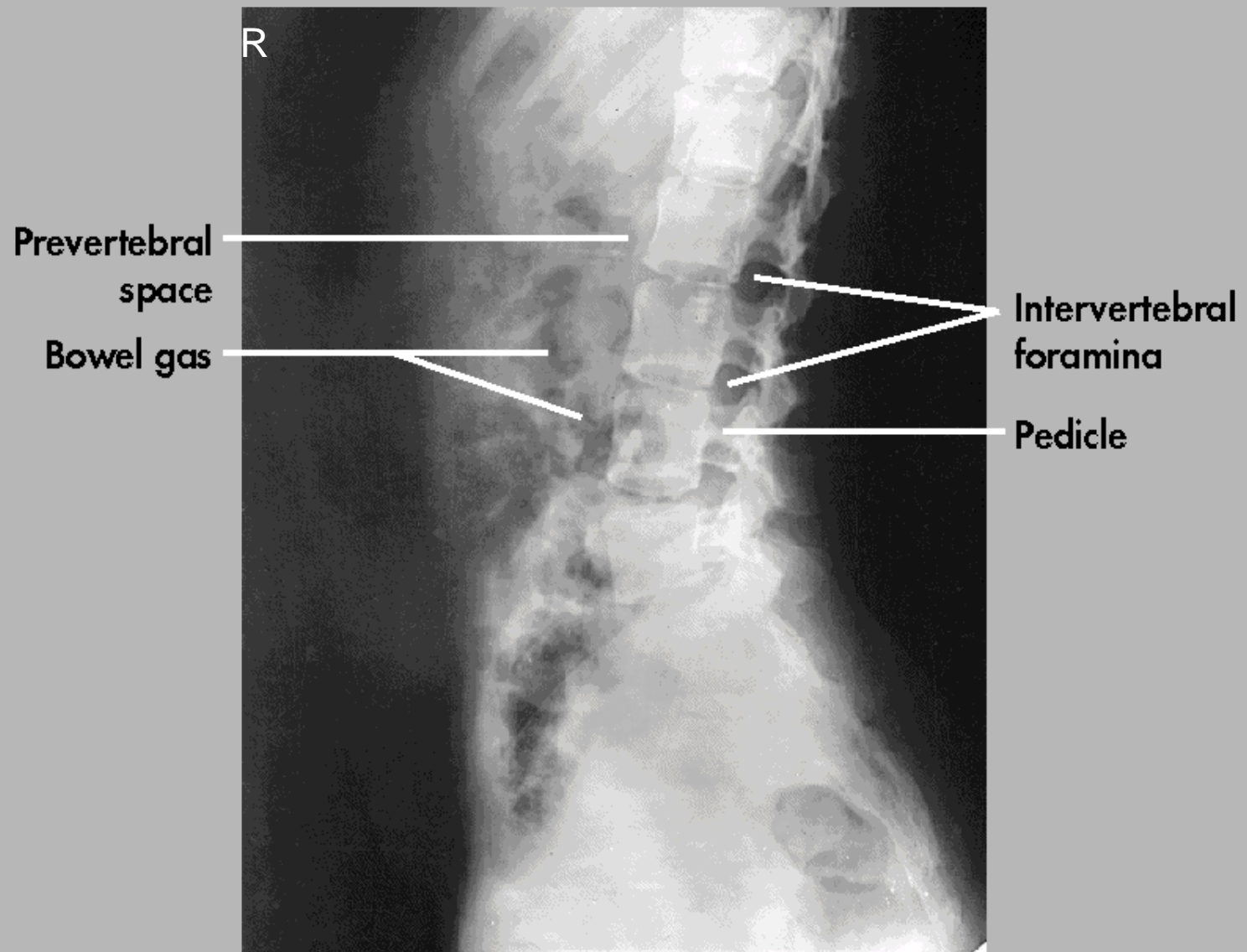
**SID:** 100cm (40 inches)

**Respiration:** at end of expiration.

**CR:** 90°vertically to film center.

**CP:** level of iliac crests (L4), bottom margin of film at Symphysis pubis.





LATERAL ABDOMEN

## AP ABDOMEN – erect (KUB)

S

**Film:** 35x43 cm lengthwise(upper margin of the cassette at level of axilla).

**Exposure factor:** 80 KVP      30 mAs

**SID:** 100cm (40 inches)

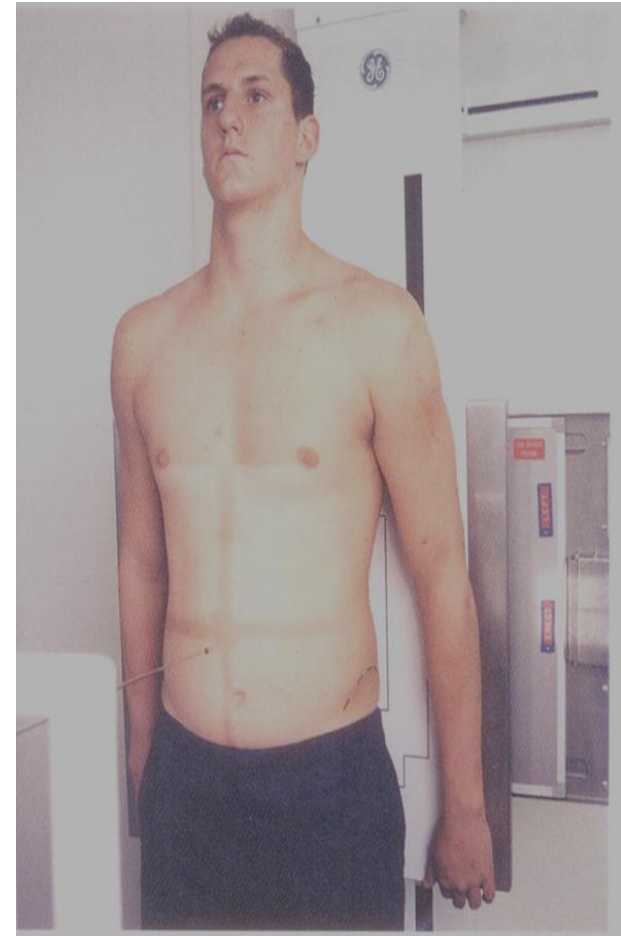
**Respiration:** at end of expiration.

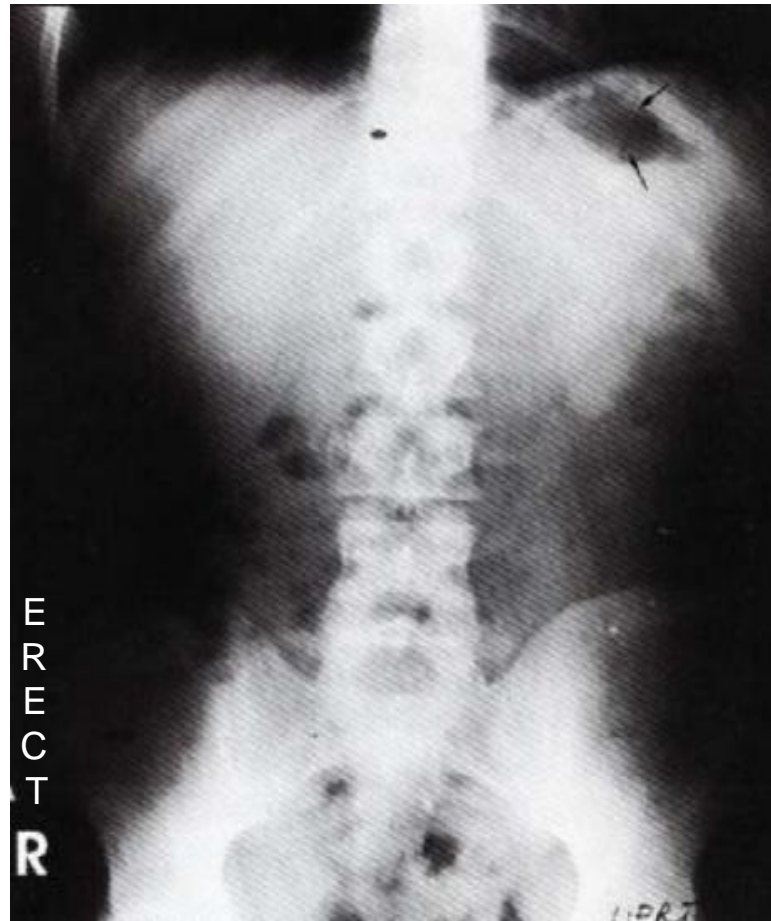
**CR:** horizontal to film center.

**CP:** 5cm above level of iliac crests (L4),

**NB :**

Patient must be upright for 5 minutes before the exposure is made to allow intraperitoneal gas settling.  
For weak patients, a lateral decubitus is generally recommended.





## **LATERAL DICUBETIS ABDOMEN -AP PROJECTION S**

LT lateral best visualized free intraperotonal air away from gastric bubble.

**Film:** 35x43 cm lengthwise with pt. (upper margin of the cassette at level of axilla).

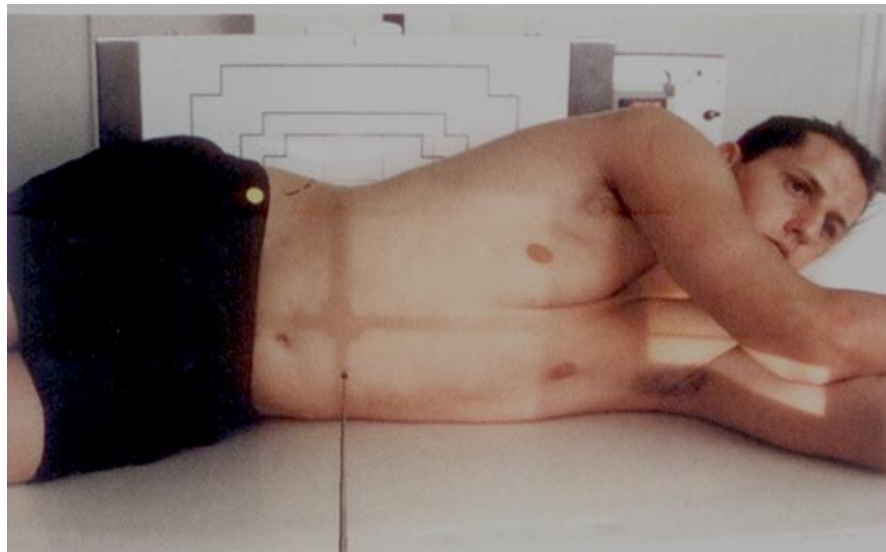
**Expouser factor:** 80 KVp      30 mAs

**SID:** 100cm (40 inches)

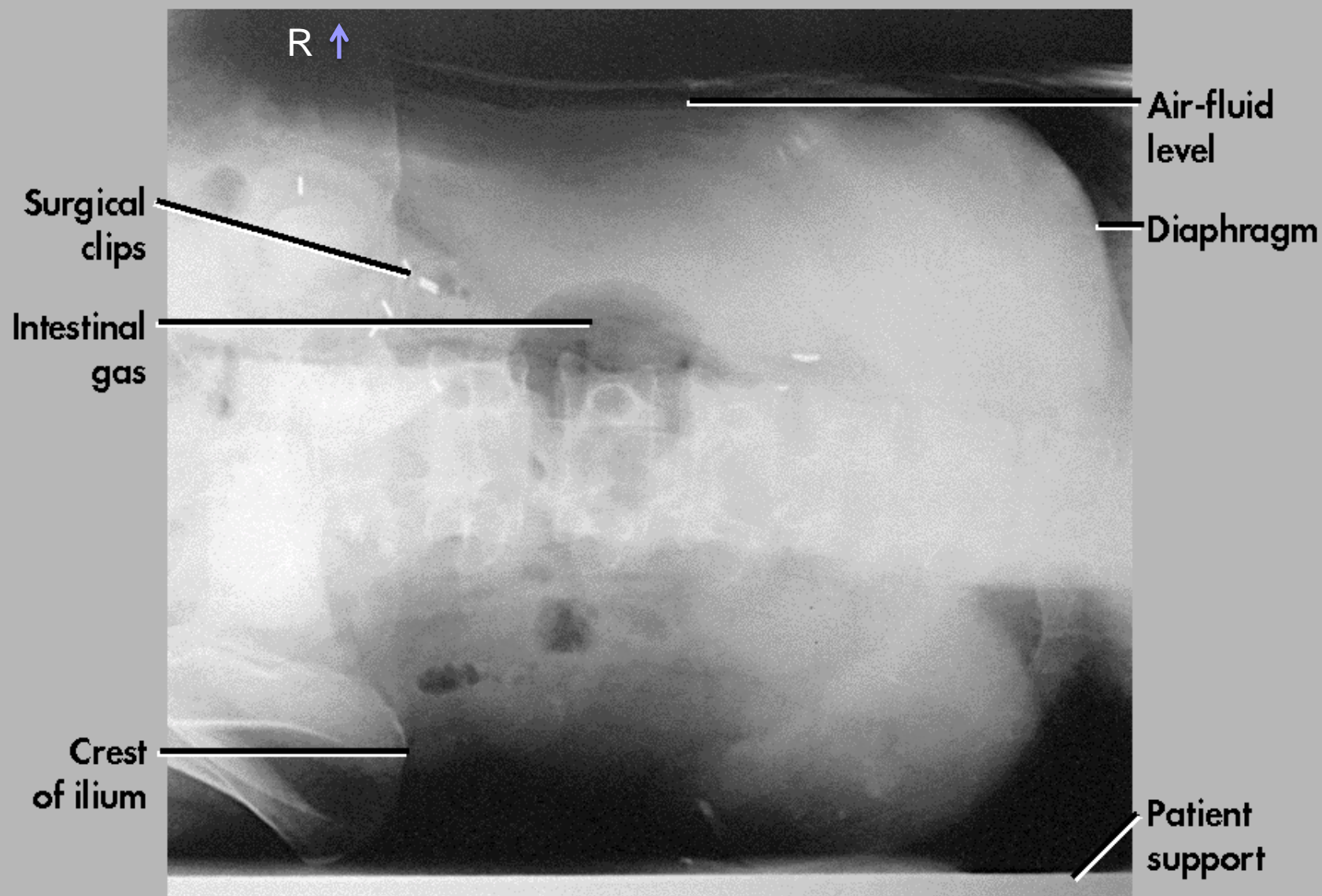
**Respiration:** at end of expiration.

**CR:** 90° horizontal to film center.

**CP:** 5cm above level of iliac crests (L4), to include diaphragm.







AP ABDOMEN — LEFT LATERAL DECUBITUS POSITION

# **DORSAL DECUBITUS ABDOMEN -LAT PROJECTION S**

**Film:** 35x43 cm crosswise .

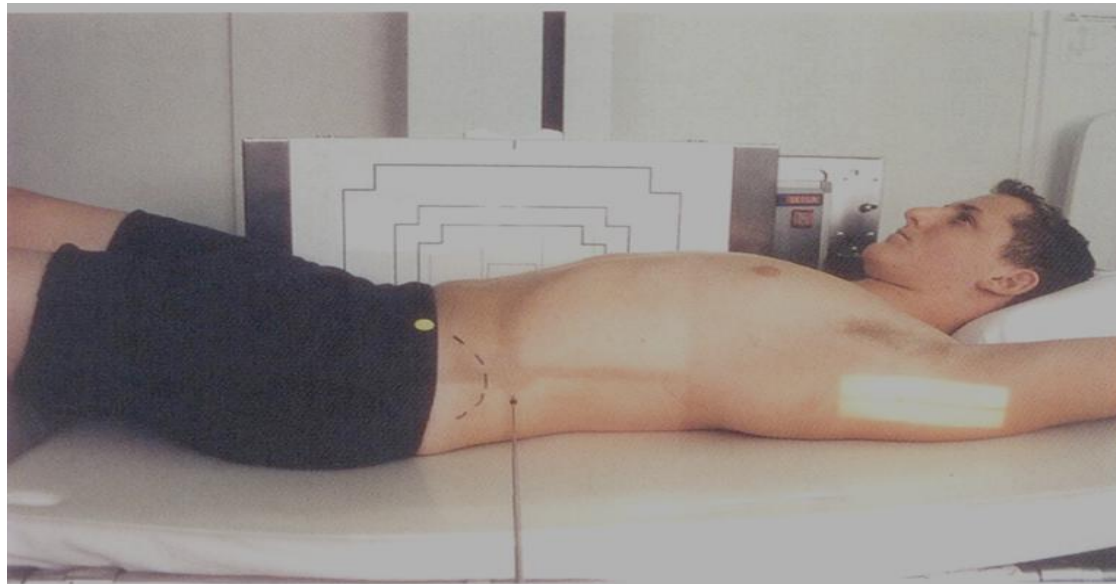
**Exposure factor:** 80 KVp      60 mAs

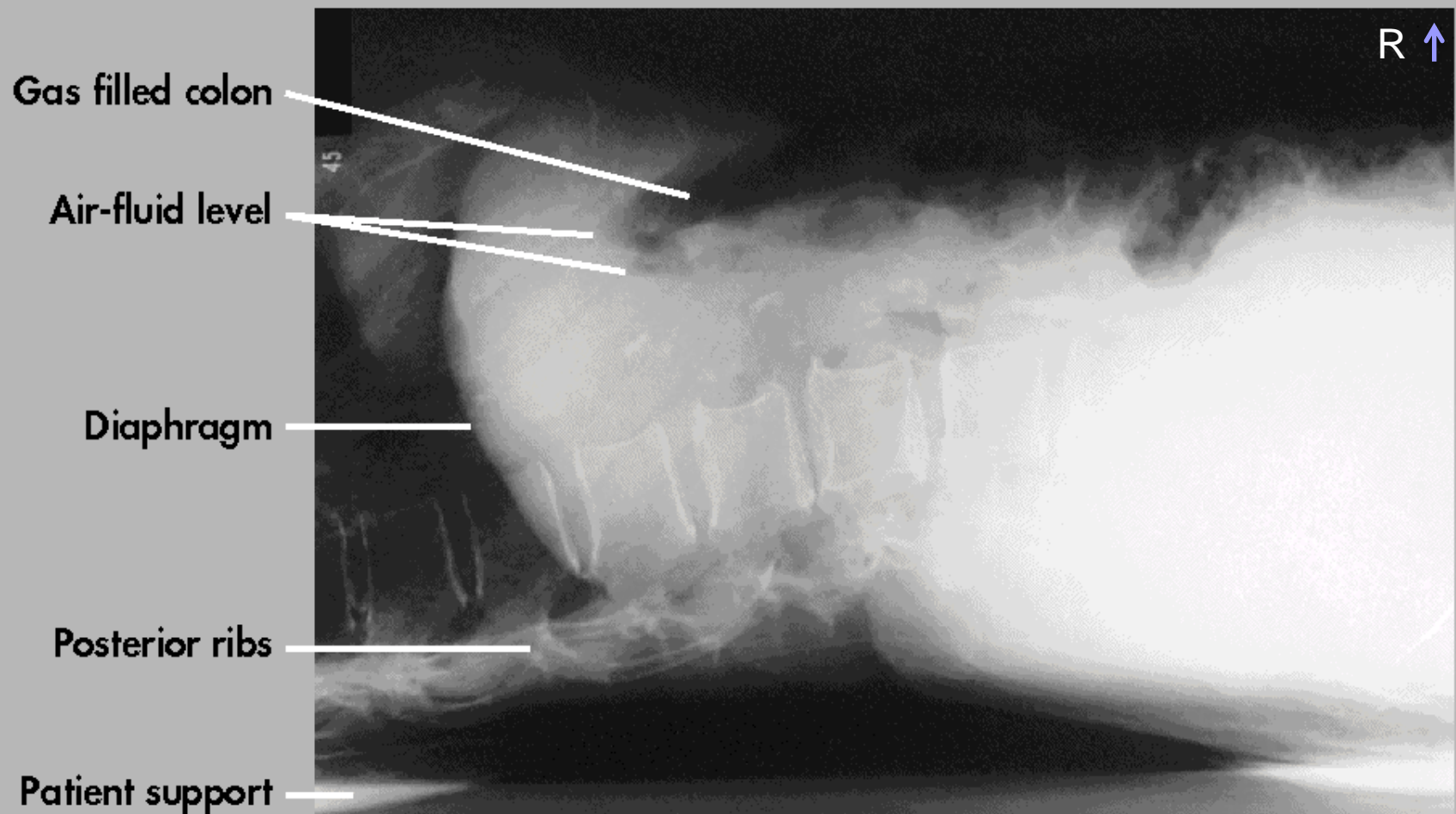
**SID:** 100cm (40 inches)

**Respiration:** at end of expiration.

**CR:** horizontal to film center.

**CP:** 5cm above level of iliac crests L4 (diaphragm must included).





LATERAL ABDOMEN — LEFT DORSAL DECUBITUS POSITION

# ACUTE ABDOMEN

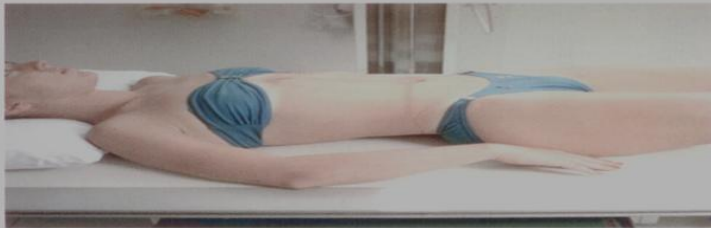

Fig. 4-44. AP supine.

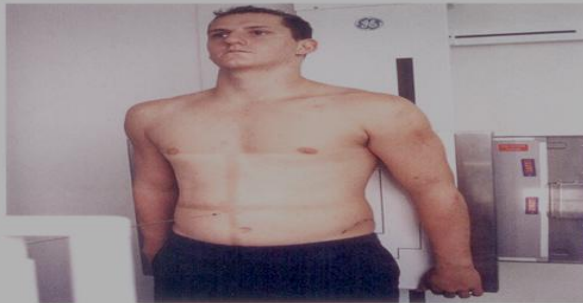

Fig. 4-45. AP erect.

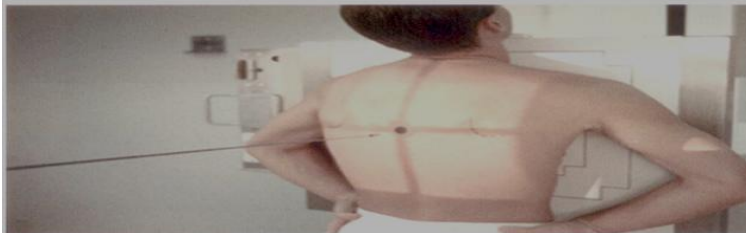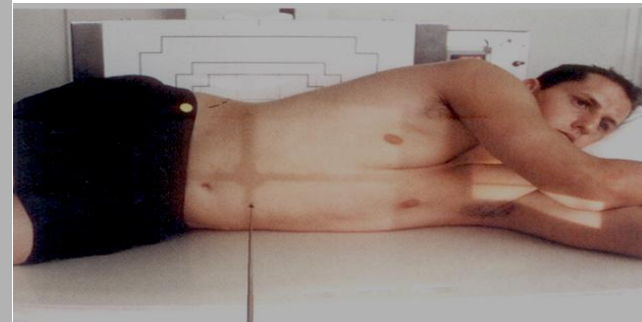


Fig. 4-47. PA chest erect.