

MAMMOGRAM

- Is an x-ray examination of the breast that can detect breast lesions as tiny as 2mm i.e. 2-4 years before it's palpated .

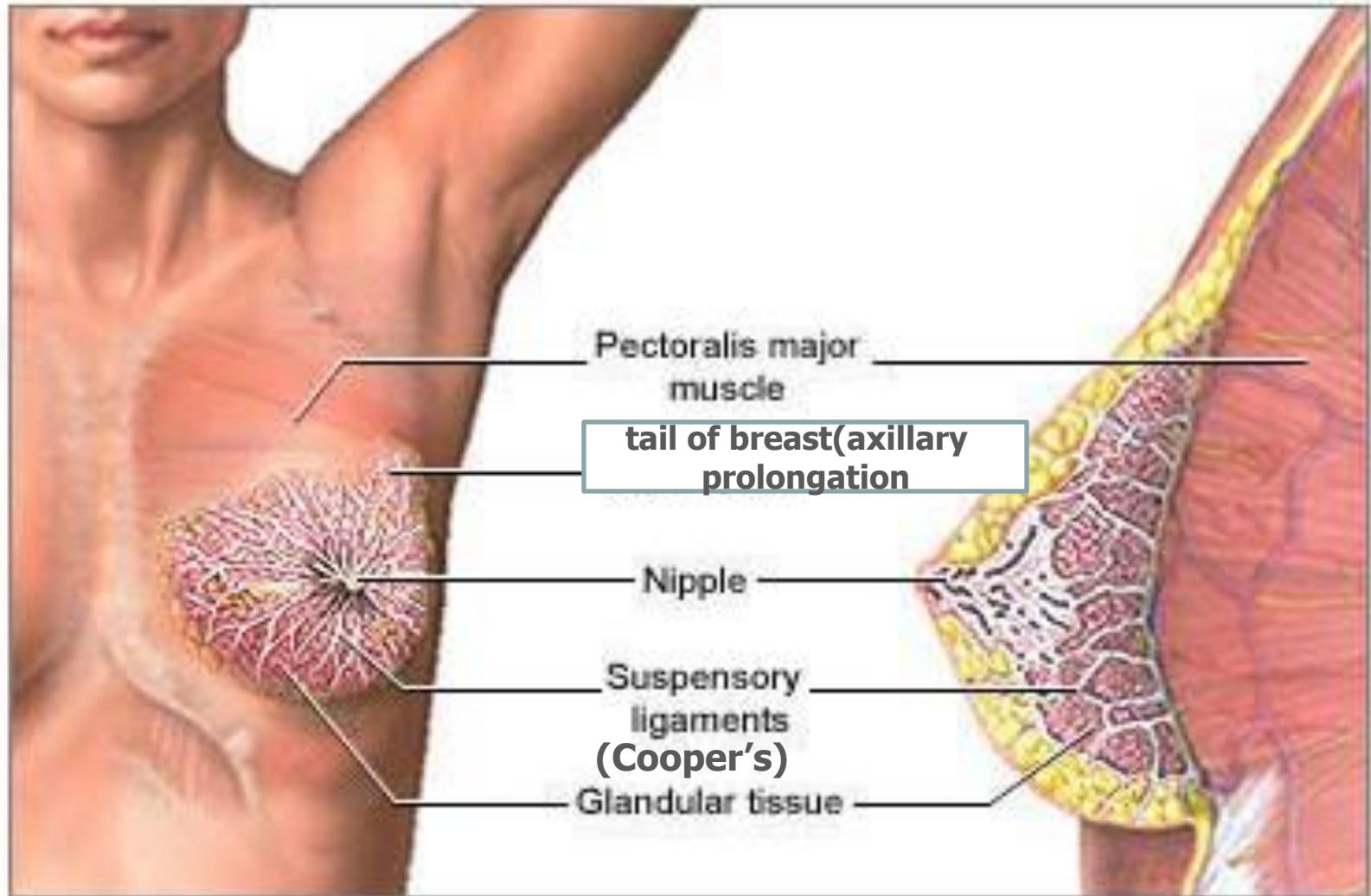
- Accurate Positioning of the breast

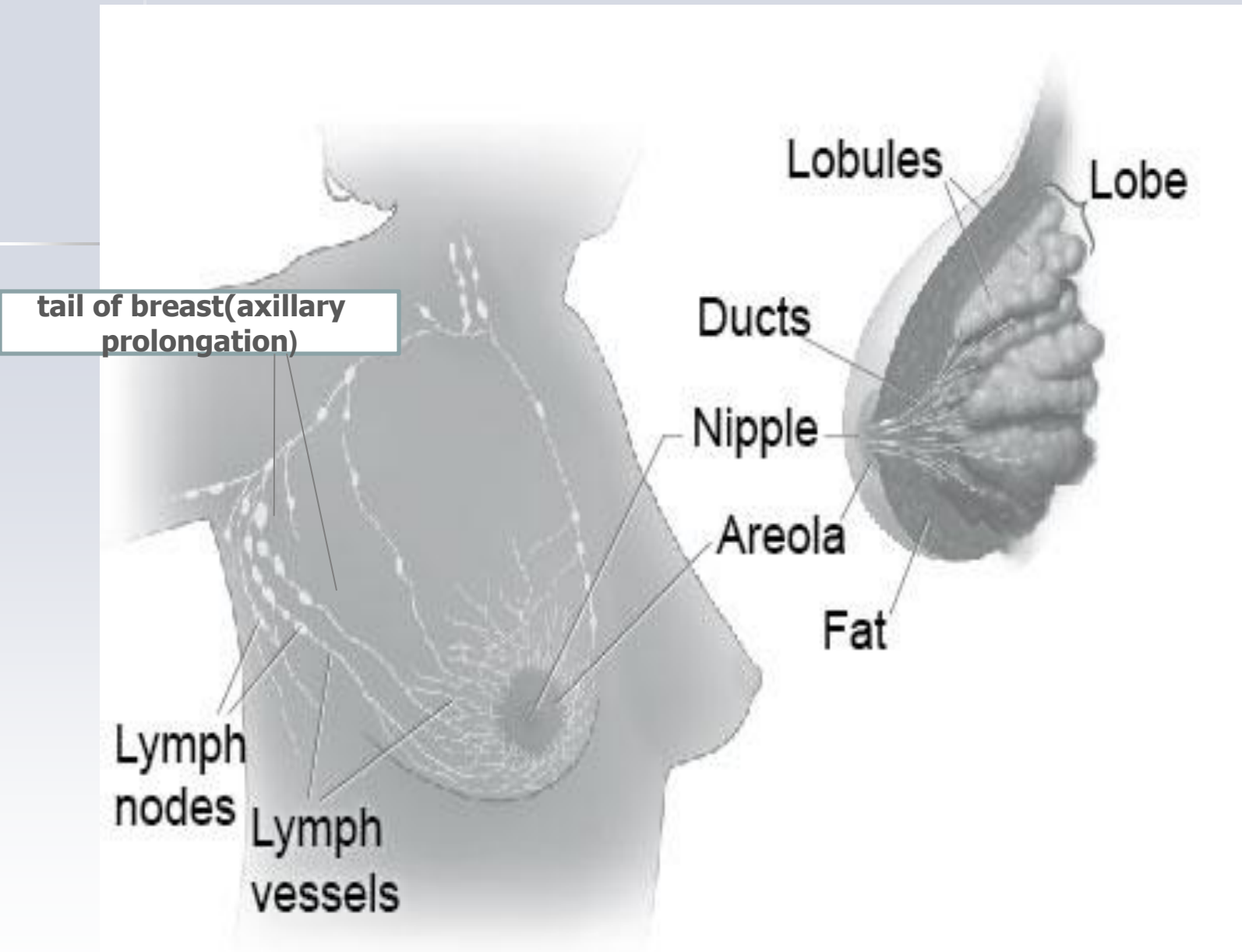
Is very important in diagnosing breast cancer

- Maximum amount of breast tissue must be clearly demonstrated on each projection.

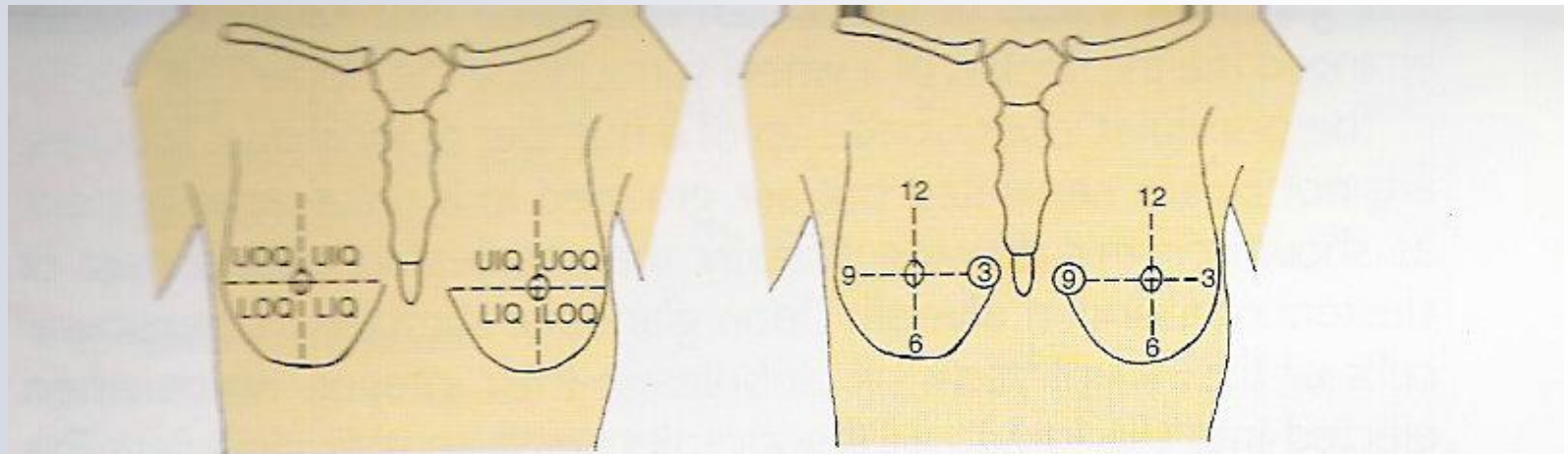
- Current recommendations are that woman over 40 should undergo annual screening. High risk patients with a family history should have screening mammograms at an earlier age.

Breast anatomy





Divisions of the breast



Right

Left

Fig. 18-2. Breast localization: —quadrant and clock system methods.

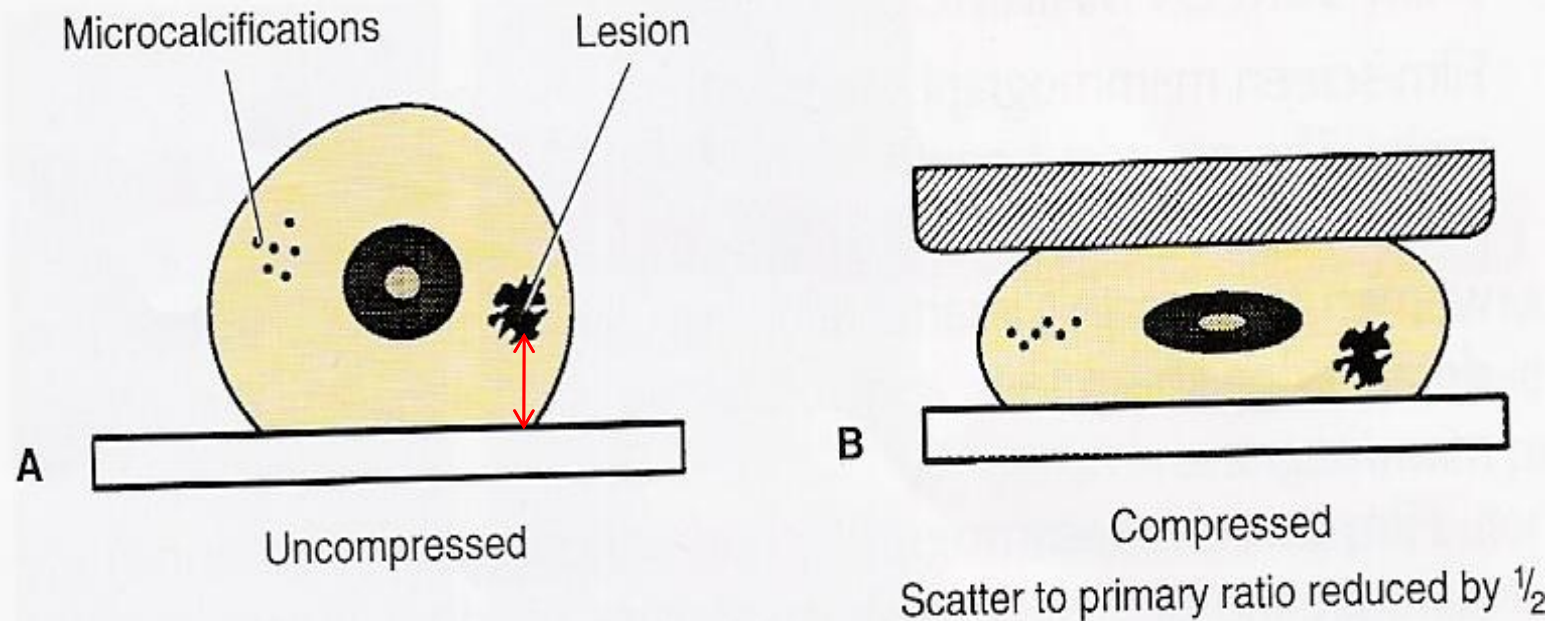
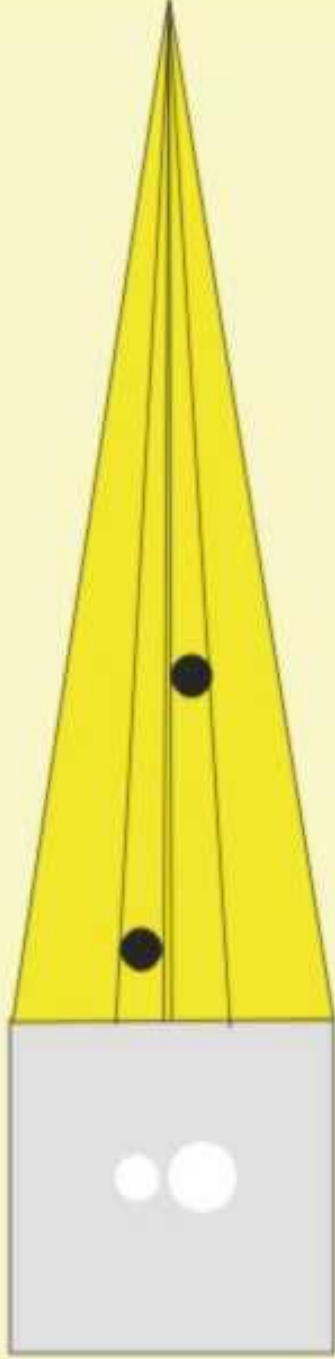


Fig. 18-9. The effect of breast compression:

1. Decreased tissue thickness (less scatter, better resolution) Less mag
2. Breast structures closer to IR

DISTORTION

POSITION


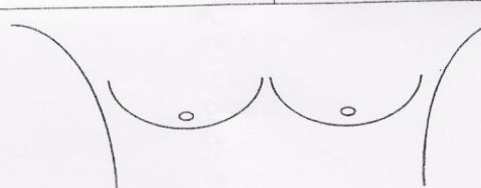


Spurwut

Why do we use compression?

- Decrease thickness of the breast.
- Bring breast structure as close to IR as possible.
- Decrease dose & scatter radiation.
- Decrease motion & geometric unsharpness.
- Increase contrast .
- Separate breast structures .

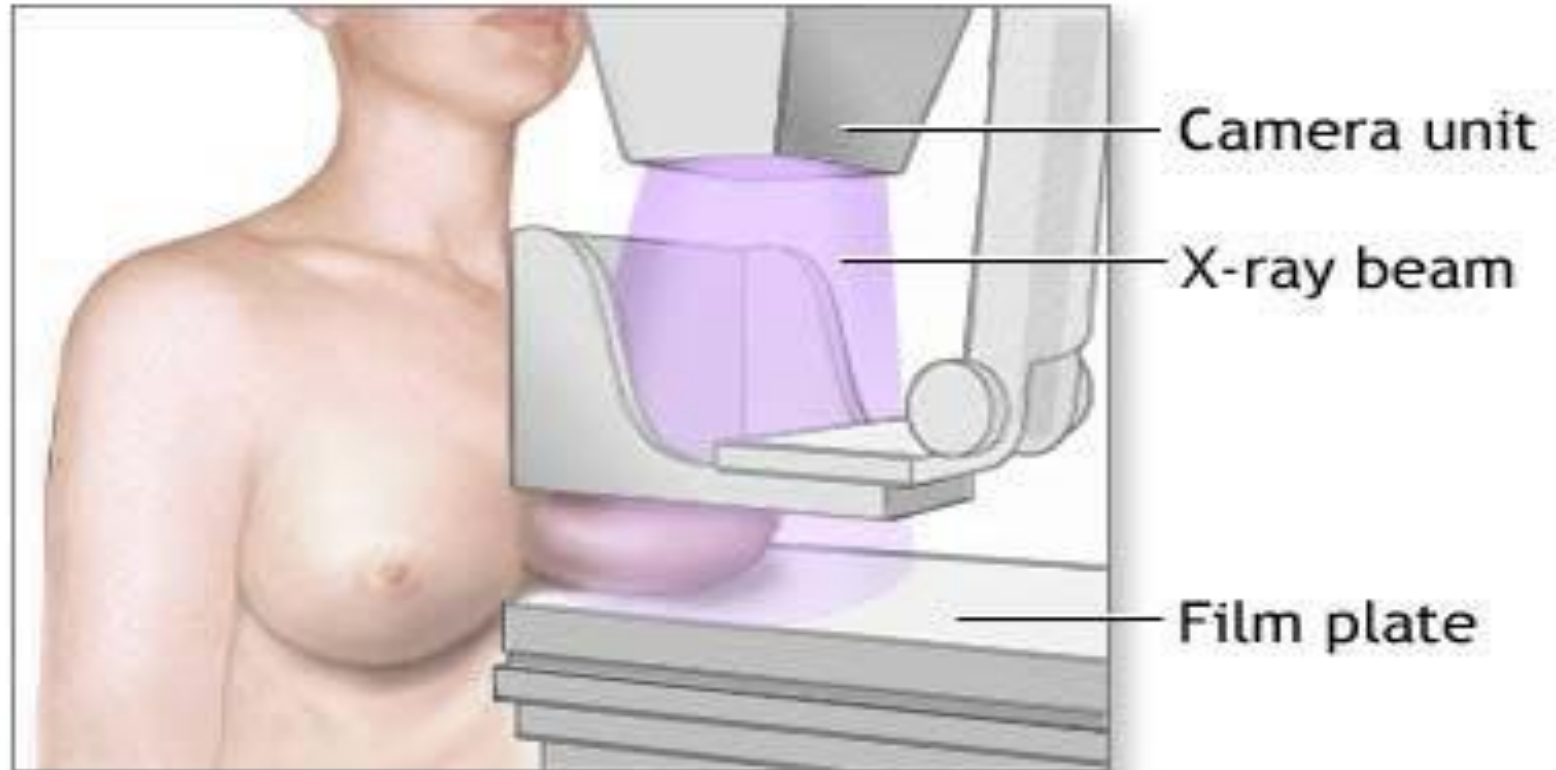
Mammography request

<div style="display: flex; justify-content: space-between; align-items: center;">  <div> KING KHALID UNIVERSITY HOSPITAL <i>Department of Radiology & Medical Imaging</i> MAMMOGRAPHY EXAMINATION FORM </div> </div>				
Date: _____		File Number: _____		
Patient Name: _____		Marital Status: _____		
Age: _____		Telephone No.: _____		
Nationality: _____				
CLINICAL INFORMATION				
		REMARKS	YES	NO
1	Presenting Complaints			
	Mass			
	Pain (if Yes)			
	Nipple Discharge (if yes, state colour)			
	Others			
2	Duration of Symptoms			
3	Side of Quadrant of symptoms			
4	Children (number) ages of oldest & youngest			
5	Breastfeeding			
6	Menstruation (regular)			
7	Age of Menarche			
8	Age of first childbirth			
9	Family history of cancer (if Yes, state relationship and organ involved)			
10	Previous mammogram (when)			
11	Previous surgery (biopsy) findings, if known			
12	Birth control tables (duration of use)			
13	Findings at Clinical Examination			
14	Mammographic Findings			
	<div style="display: flex; justify-content: space-between; align-items: center;"> R  L </div>			

PT Preparation:

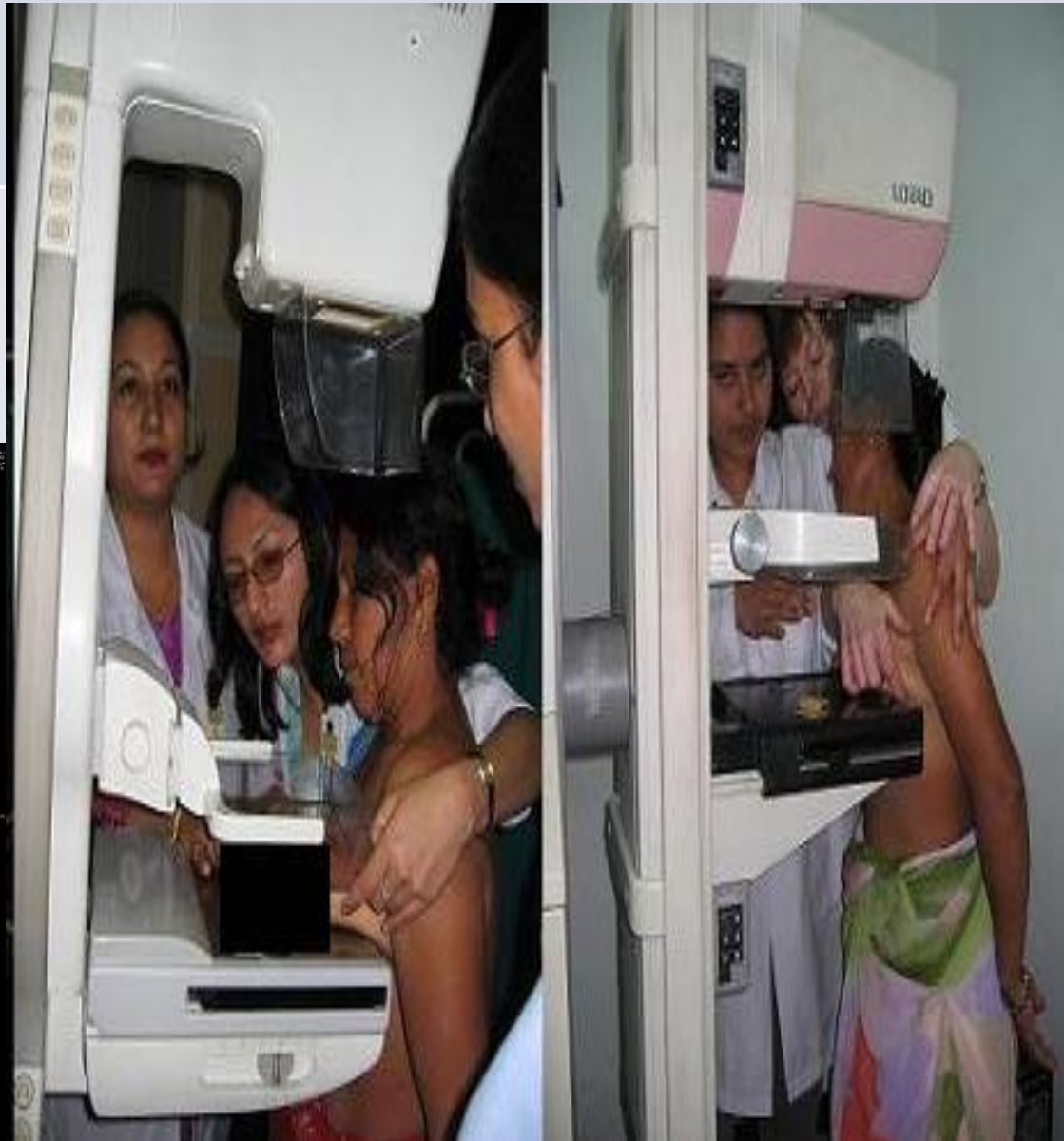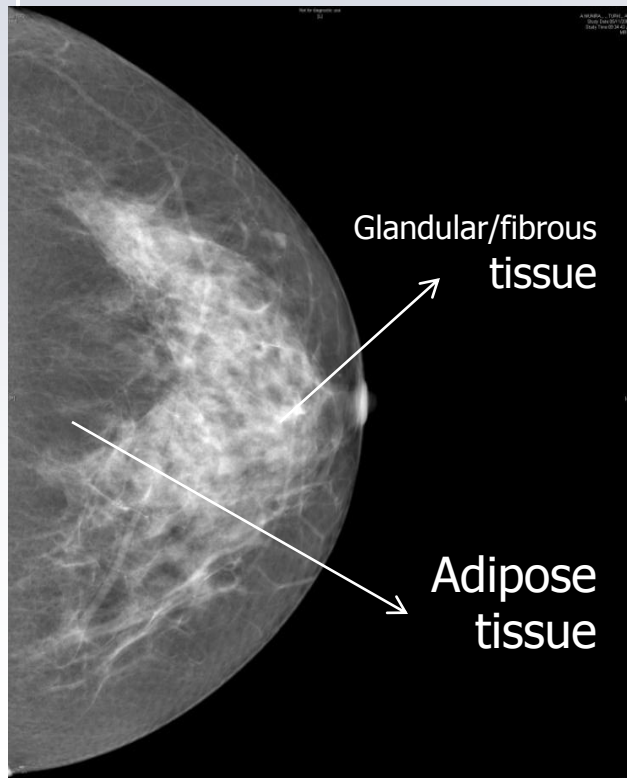
- Make sure the pt is not pregnant (10 day rule)
- Take off the top clothes & wear hospital gown tied in front
- fill the questioner
- Remove any jewelry, talcum powder that may cause artifacts on the image
-

Technique



In mammography, each breast is compressed horizontally, then obliquely and an x-ray is taken of each position

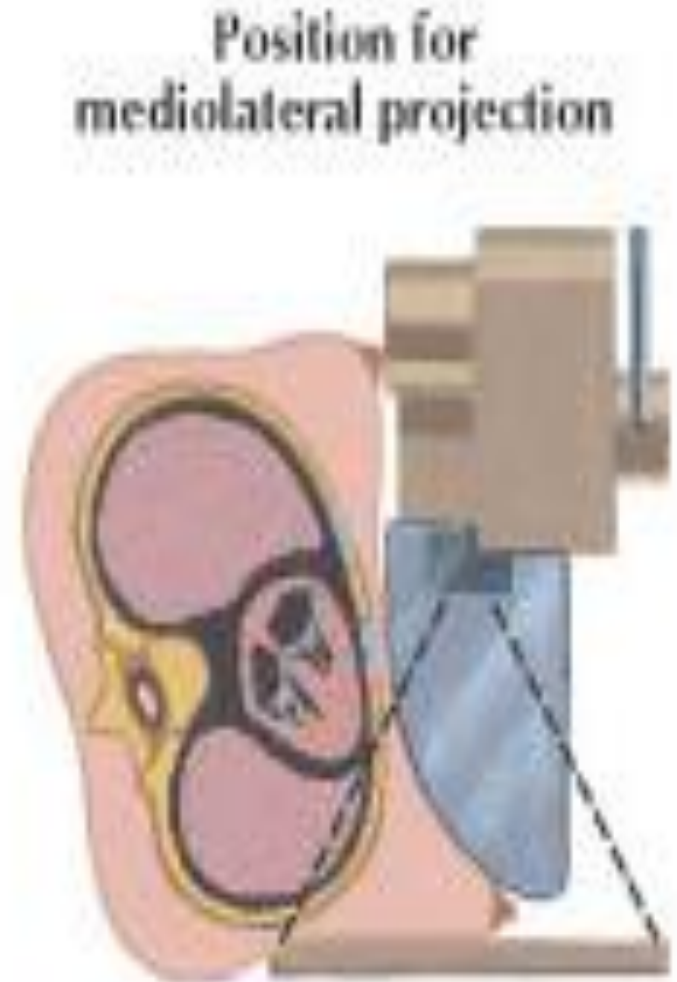
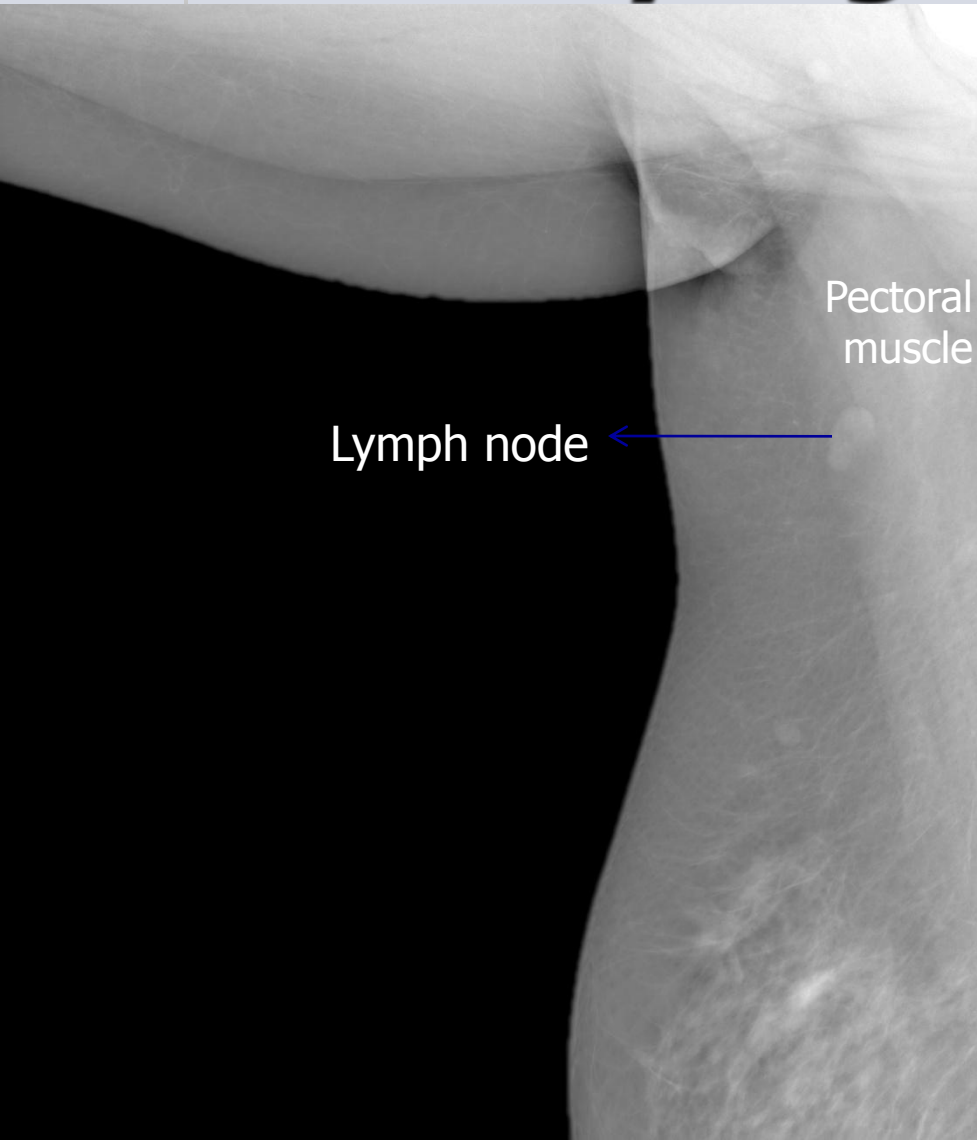
Crainocaudal projection (CC)



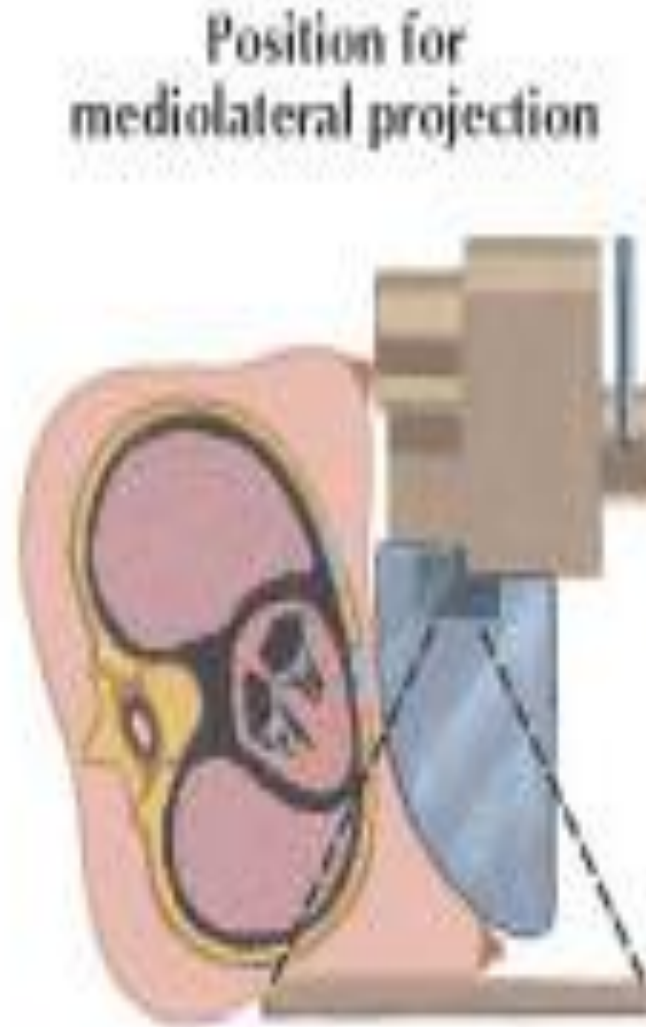
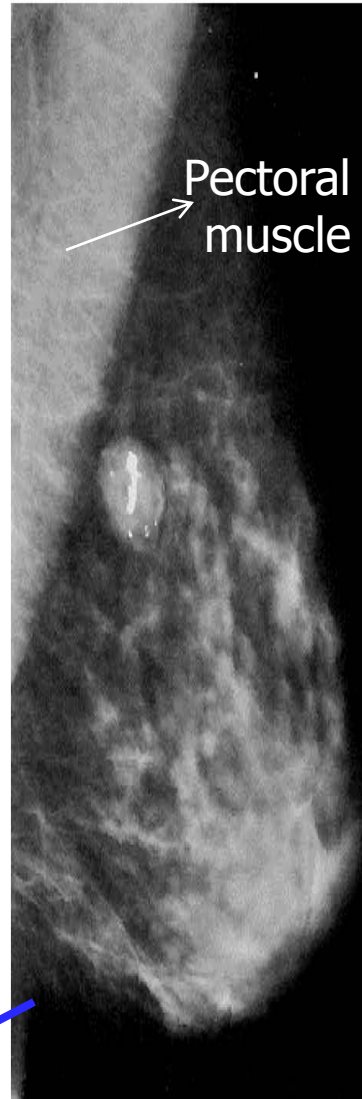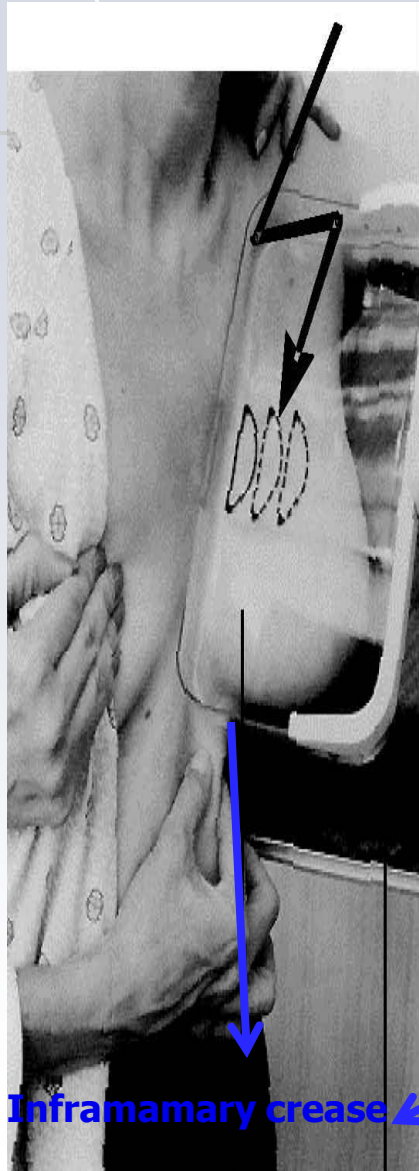
Positioning for CC

- Lift the breast to achieve a 90 degree angle to the chest wall .The IR should be at the level of the inframammary fold at its upper limits.
- Head is turned away from the side being imaged
- Maximum breast tissue is pulled forward onto The IR centrally with the nipple in profile.
- Wrinkles & folds should be smoothed out.
- The Tissue of the opposite breast is pulled away
 - exposure criteria :Entire breast should be visualized, Pectoral muscle ,nipple should be in profile ,tissue thickness distributed evenly, marker .

Medio lateral oblique for axillary region



Medio lateral oblique for the rest of the breast



Requirements for MLO

- Move tube to 45 angle, the top of the IR will be at the level of the axilla , hand on bar .
- pull breast tissue and pectoral muscle anteriorly & medially away from chest wall.
- The upper edge of the compression device should rest under the clavicle & lower edge should include the inframammary fold.
- The opposite breast should be moved away .
- exposure criteria:Entire breast tissue should be visualized, pectoral muscle , (IMF) must be seen ,breast must not be drooping ,nipple must be in profile, even thickness, marker

Extra images

Magnified compression films

Different spot compression Devices

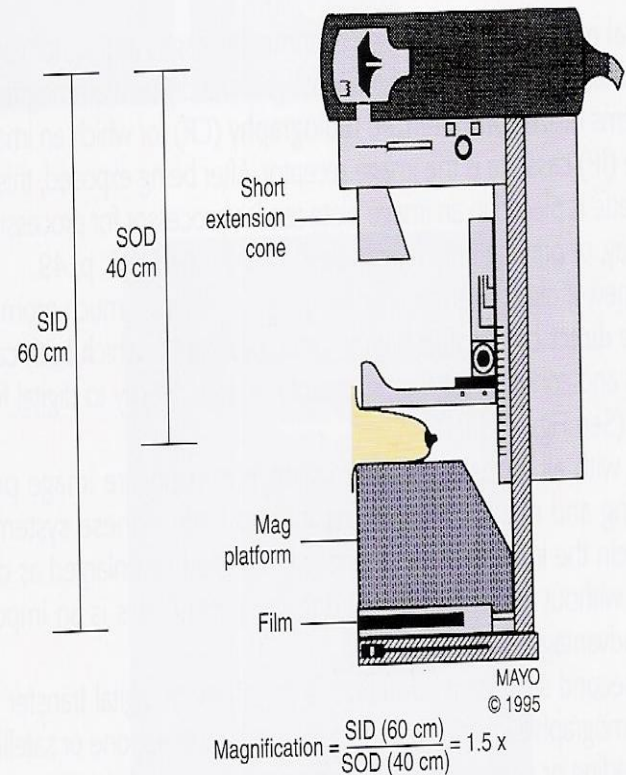


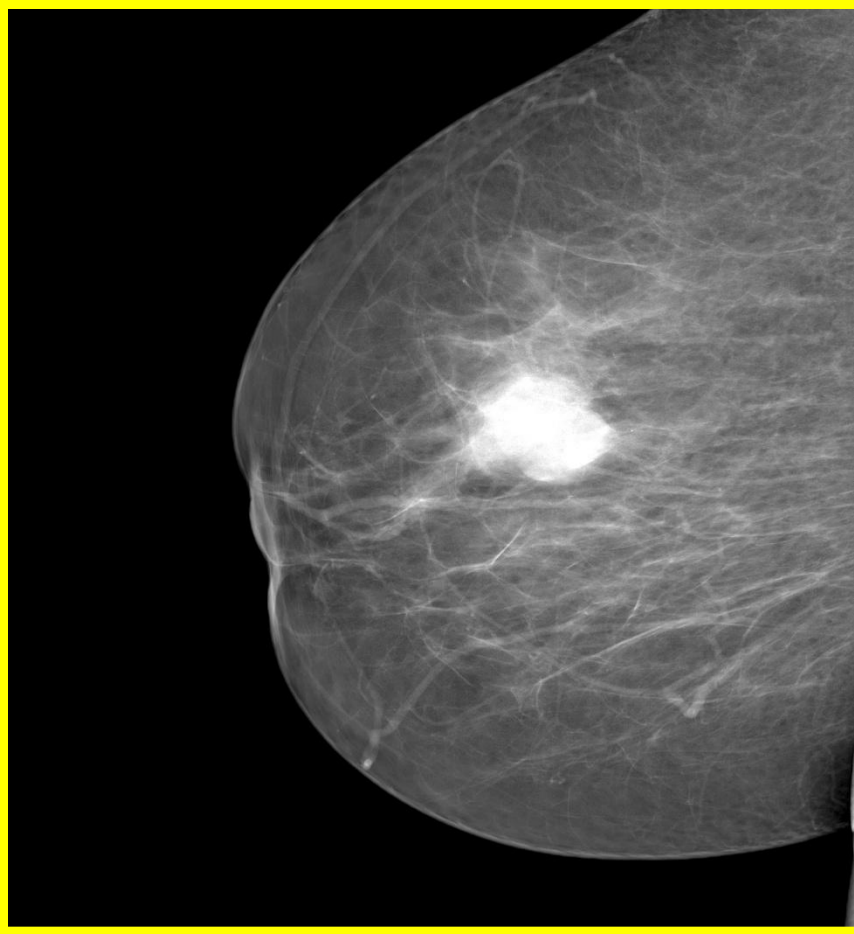
MAGNEFYING PLAT FORM



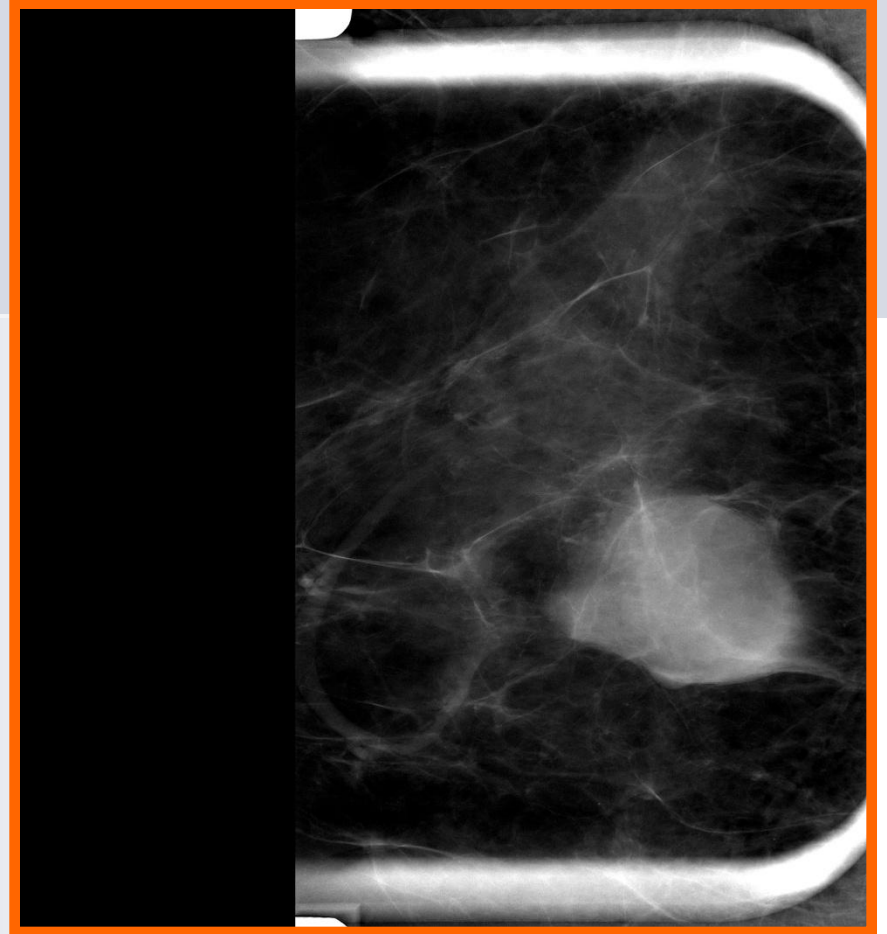
Magnification

Magnification is used to enlarge specific areas such as lesions or microcalcifications by increasing OID(object image distance)





MLO Rt breast ■



**spot view Rt
breast**

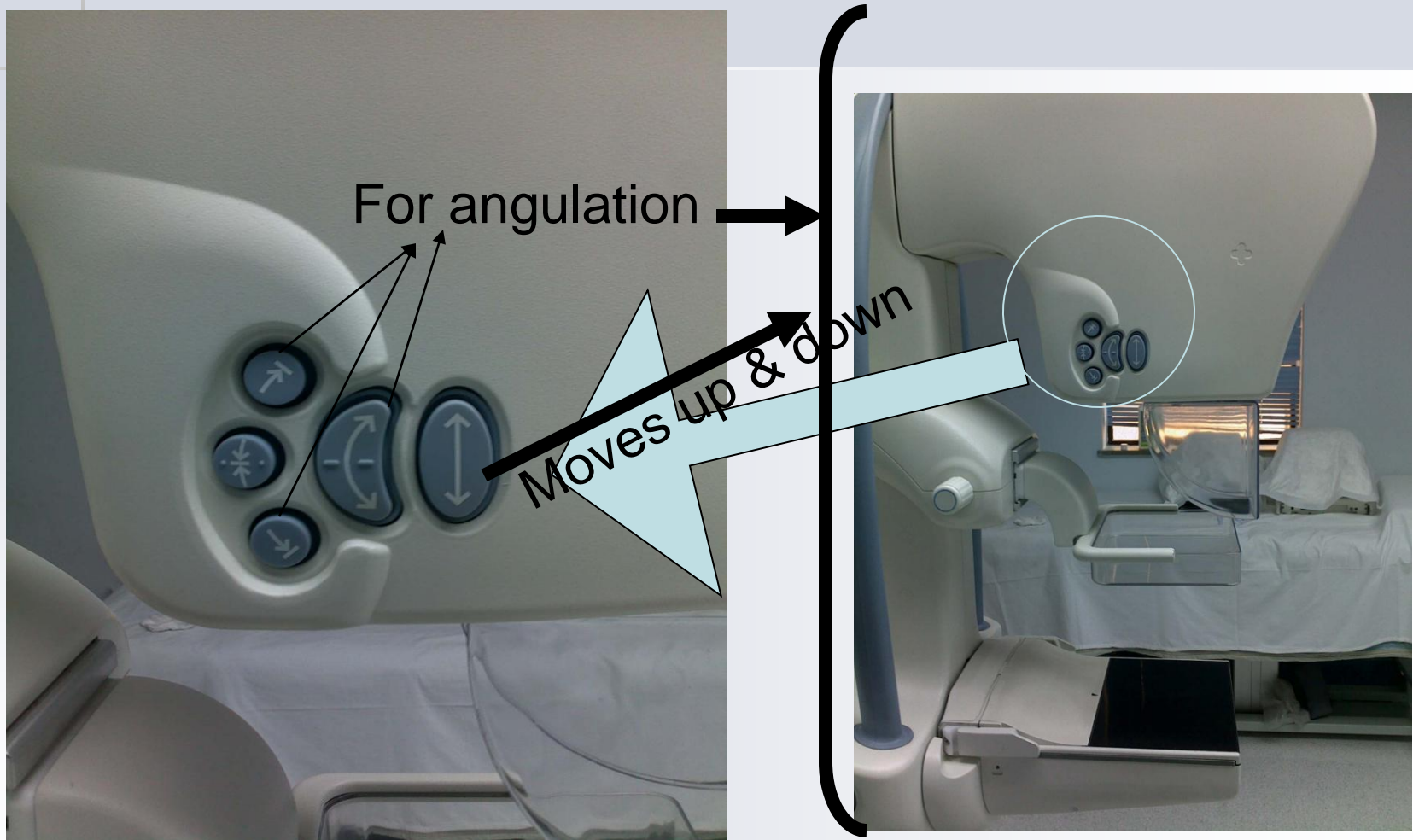
Why do we use U/S after mammo?

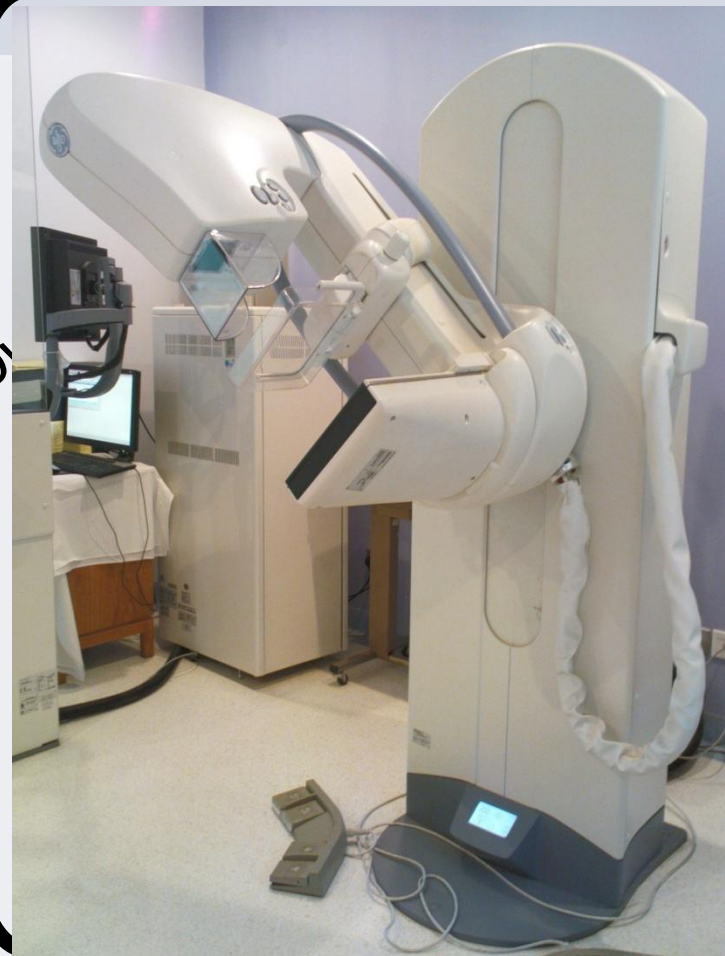
- To distinguish a cyst from a solid mass.
- To determine , hematoma , Silicon gel, fluid and abscess.
- U/S can also find cancer in woman with dense breasts .

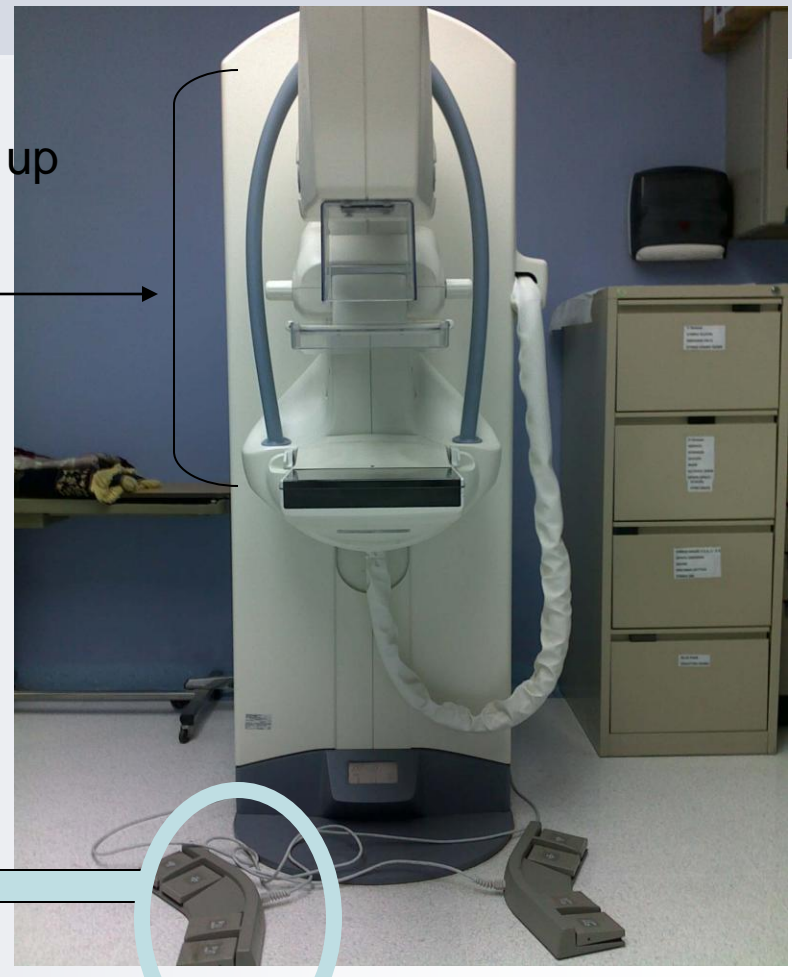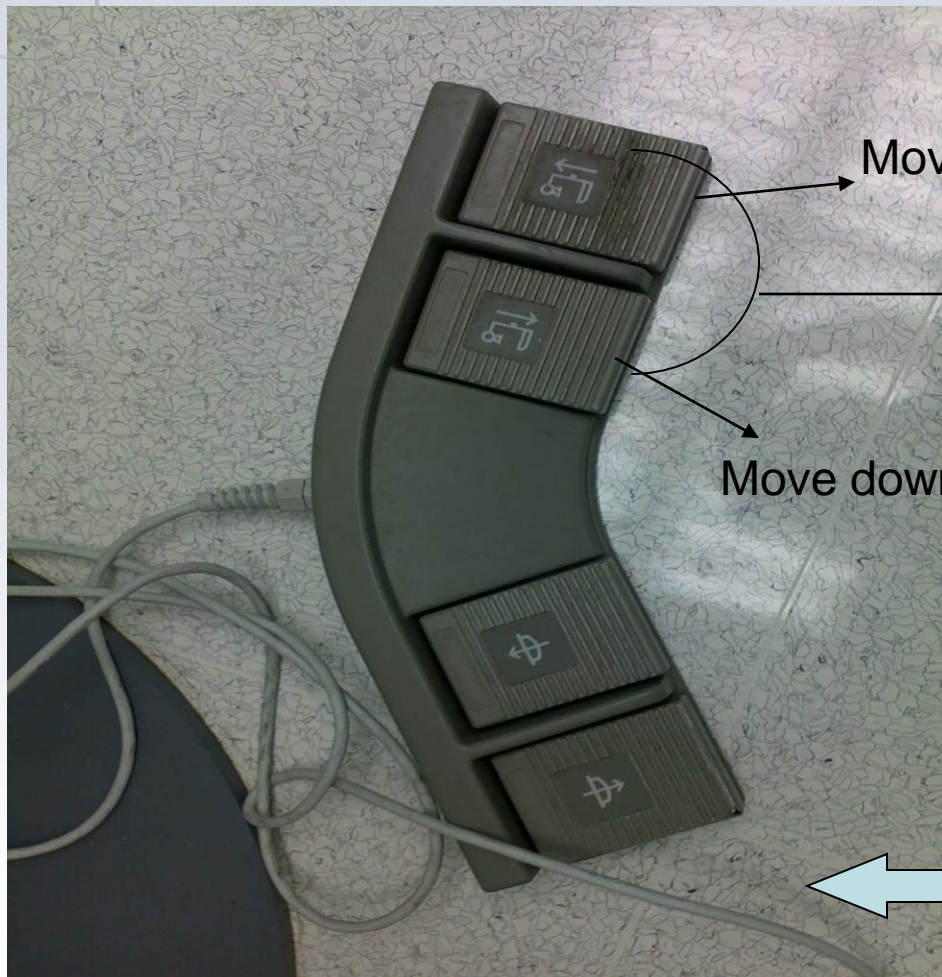
Case study

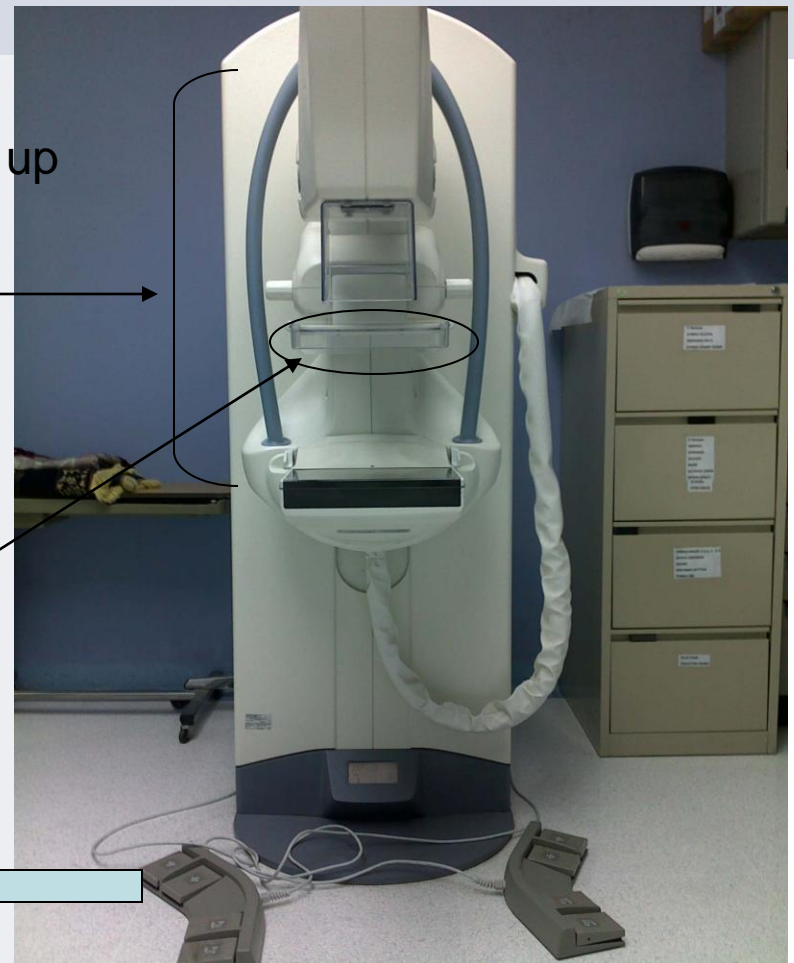
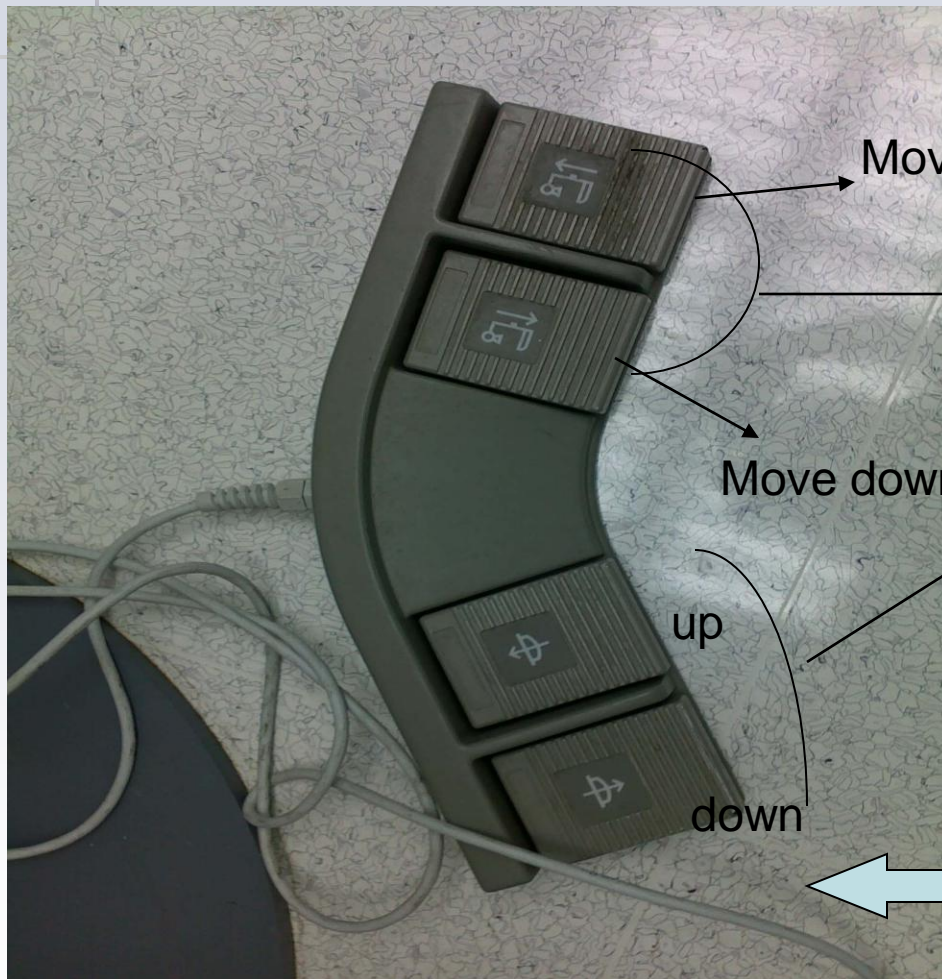
- Pt history +reason for exam
- preparation
- Images(CC,ML...)
- Reason for taking out of protocol images (ex: compression)
- Anatomy & pathology shown in the images
- Talk shortly about the pt disease

Mammo machine





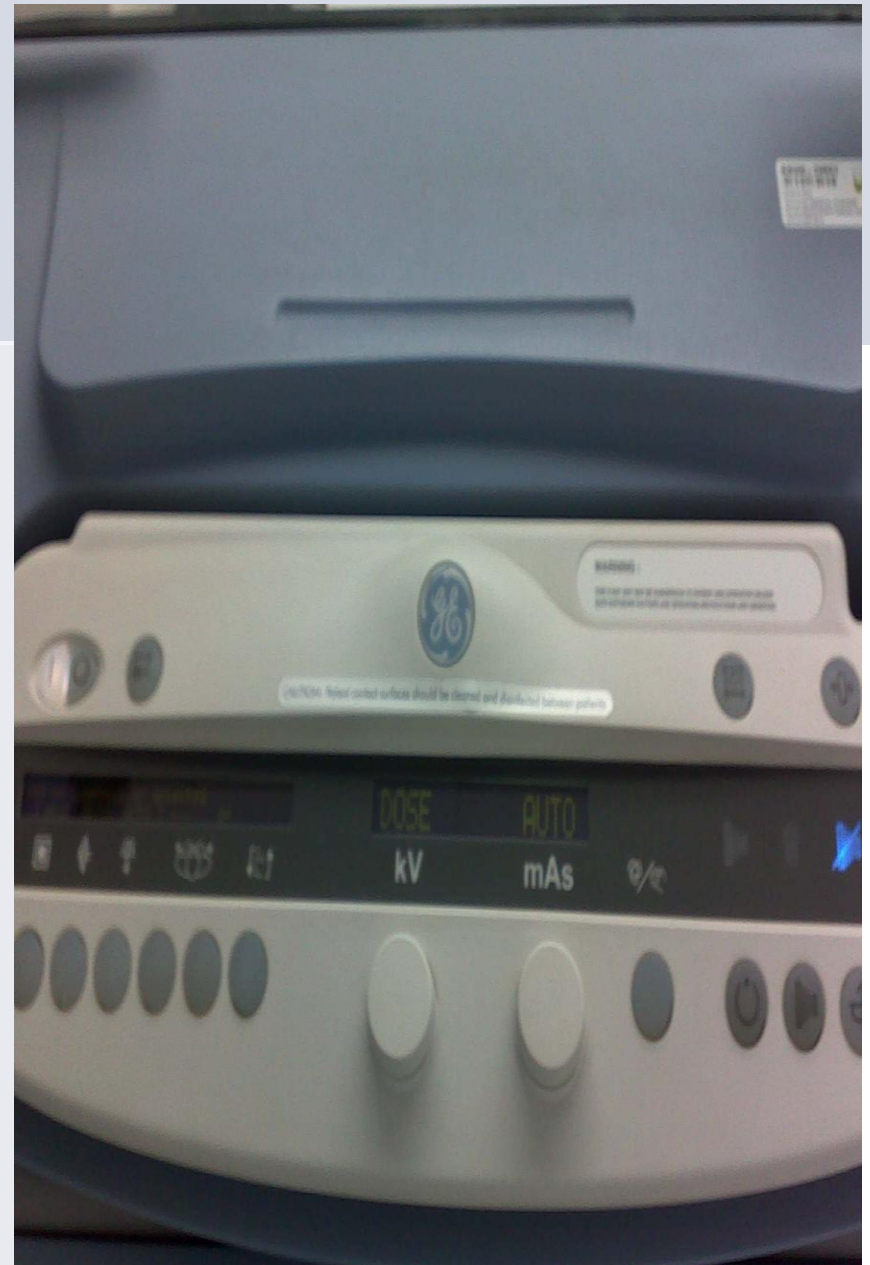




**When taking exposure
press both buttons**



**Keep pressing until
this illuminate.
Release both fingers**





First click here

AWG - V42.10.1

MXWS-001 PACS CDR read/write

No Filler

Remaining exposure(s): 2614

GE Medical Systems

Oct 27 2008 10:56
Auto delete: OFF

Sort by: Last study date

Patient Name	ID
Mheish Mariam Mub	KK244379
Alkelaibi Jawaher	KK244437
Maqsousa Wosal Ra	KK132965
Alshammari Wasifa	KK513016
AL SEHLI HAYA	KK224124
Al Ajaian Sara Ab	KK12134
Albasri Sharma Al	KK293708
Al Qahtani Nora H	KK572191
Filomena Roy Filo	KK204071
Albesher Ghaida M	KK417577
Alowaissh Hessa S	KK146590
Brabante Thelma V	KK307229
Alomran Asma Ali	KK301451
Alfawzan Haila Fa	KK74552
Hessa Alotayani	KK485692
Al Saleh Hessa Sa	KK126272

1 / 138 patients

Sort by: Date

Study ID	Accession Number	Description	Date
927594	927594	MAMMOGRAM	Oct 27 2008

1 / 1 examination

Sort by: Type

Series	Type	Imgs	Procedure Description	Status
1518	PROCES	6	MAMMOGRAM	U S
1517	RAW	6	MAMMOGRAM	U

1 / 2 series

Sort by: Number

Image	Anatomical View	View Name	Laterality	Processing	Date	Time	Angulation	Status
1	BREAST	LCC	L	PREMIUM_VIEW	Oct 27 200	10:37:29	0	S
2	BREAST	RCC	R	PREMIUM_VIEW	Oct 27 200	10:38:36	0	S
3	BREAST	LMLO	L	PREMIUM_VIEW	Oct 27 200	10:40:21	0	S
4	BREAST	RMLO	R	PREMIUM_VIEW	Oct 27 200	10:41:35	0	S
5	BREAST	RMLO	R	PREMIUM_VIEW	Oct 27 200	10:42:57	0	S
6	BREAST	RMLO	R	PREMIUM_VIEW	Oct 27 200	10:43:44	0	S

1 / 6 images

click query

Worklist as of 10:01, October 27 2008

Selection Criteria

Patient ID Patient Last Name Accession Number

Status	Input	+ Start Date&Time	Patient Name	Patient ID	Procedure Description	Accession #	Study ID
*		Oct 26 2008 08:43	AL EHLI HAYA	KK224124		929331	537
	RIS	Oct 27 2008 10:00	Marcouf Shaza	KK855372	MAMMOGRAM	927483	927483

Buttons: Refresh Worklist, Query..., Edit..., New Patient..., Delete, Delete All, Browser, Start Exam

Type Of Exam: Routine

Chose the pt name

Worklist as of 10:02, October 27 2008

Selection Criteria

Patient ID Patient Last Name Accession Number

Status	Input	+ Start Date&Time	Patient Name	Patient ID
*		Oct 26 2008 08:43	AL SEHLI HAYA	KK224124

Write pt ID number

Worklist as of 10:01, October 27 2008

Patient Last Name: [] Accession Number: []

+ Start Date&Time	Patient Name	Patient ID	Procedure Description	Ac
ct 26 2008 08:43	AL SEHLI HAYA	KK124124		929
ct				927

Query definition


Which system
☒ This system ☐ All systems in modality ☐ All systems

Date
☒ Today ☒ Tomorrow

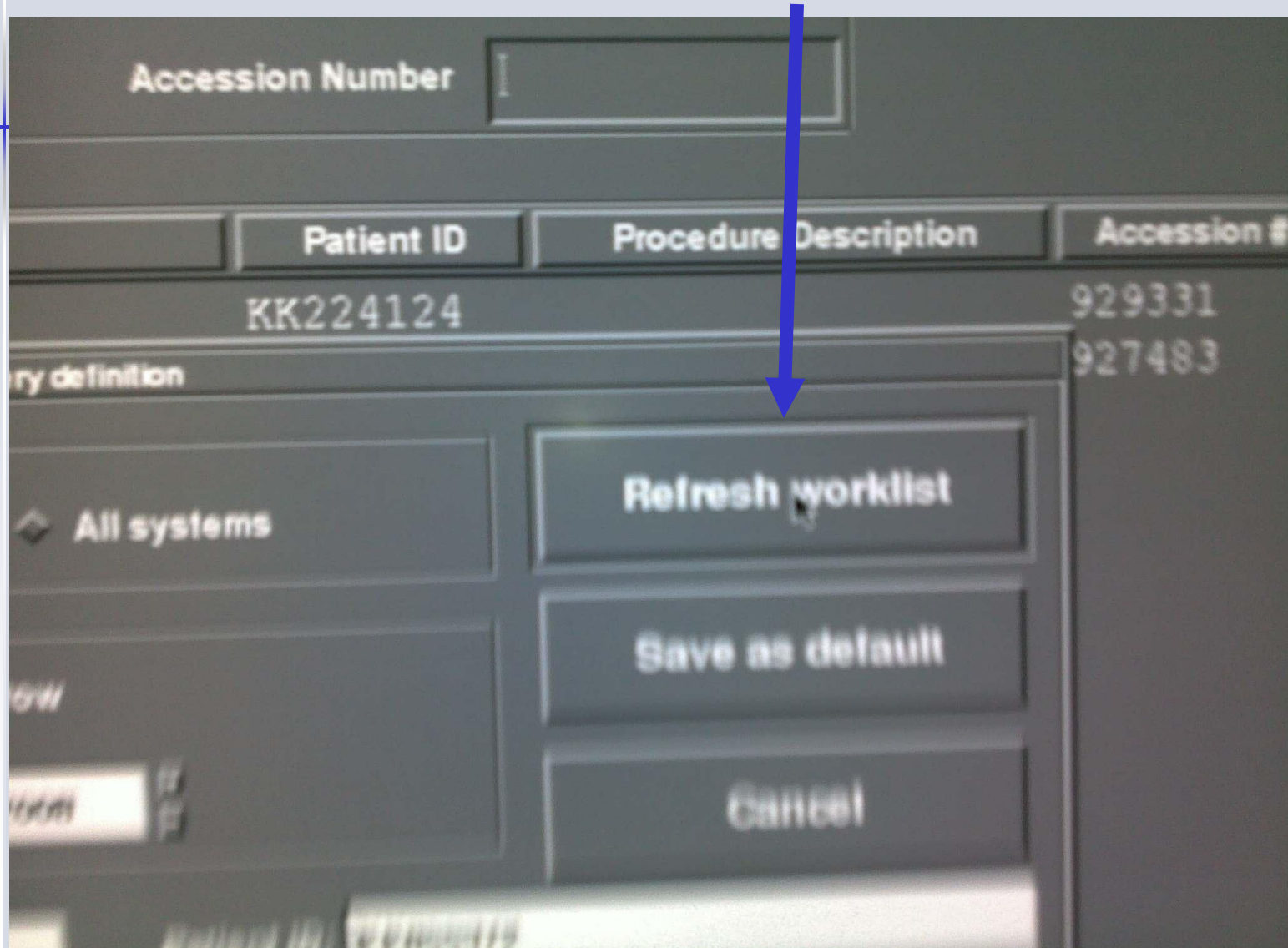
From: [Oct 27 2008] To: [Oct 27 2008]

Refresh worklist
Save as default
Cancel

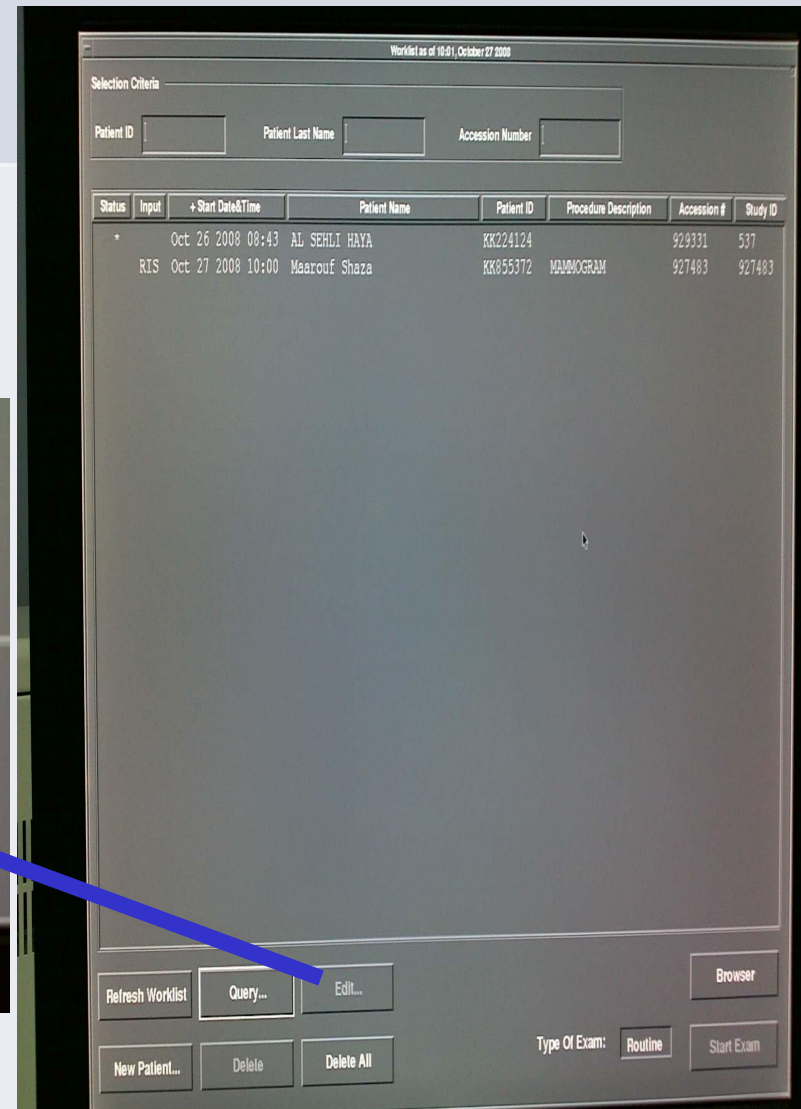
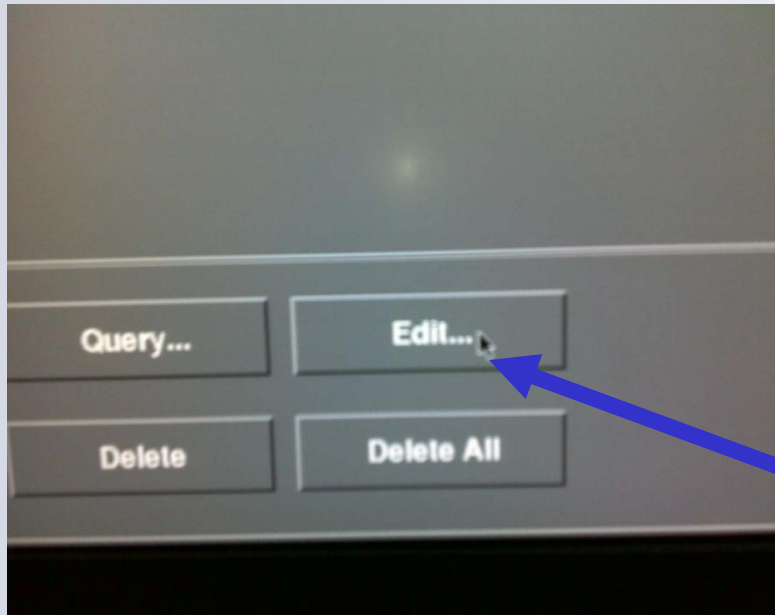
Patient Name: [] Patient ID: [KK855372]



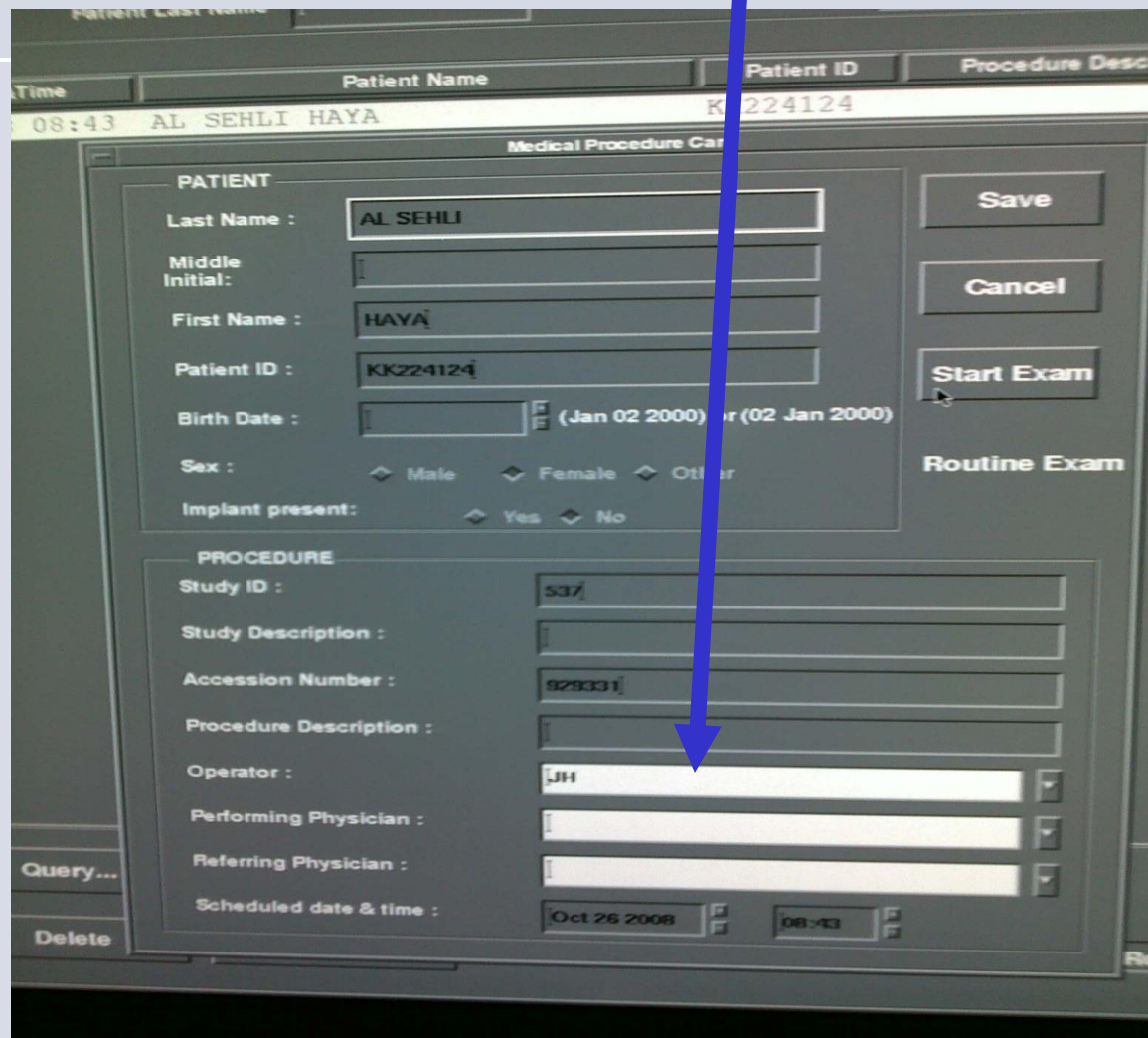
Click refresh worklist



Click Edit



Write operator name



The screenshot shows a medical procedure form titled "Medical Procedure Card". At the top, there are fields for "Time" (08:43), "Patient Name" (AL SEHLI HAYA), "Patient ID" (KK224124), and "Procedure Desc". Below this, the form is divided into two main sections: "PATIENT" and "PROCEDURE".

PATIENT Section:

- Last Name : AL SEHLI
- Middle Initial:
- First Name : HAYA
- Patient ID : KK224124
- Birth Date : (Jan 02 2000) or (02 Jan 2000)
- Sex : ☐ Male ☐ Female ☐ Other
- Implant present: ☐ Yes ☐ No

PROCEDURE Section:

- Study ID : 537
- Study Description :
- Accession Number : 929331
- Procedure Description :
- Operator : JH
- Performing Physician :
- Referring Physician :
- Scheduled date & time : Oct 26 2008 08:43

On the right side of the form, there are buttons for "Save", "Cancel", and "Start Exam". Below these buttons is a label "Routine Exam". At the bottom left, there are buttons for "Query..." and "Delete".

A blue arrow points from the top of the form down to the "Operator" field, which contains the text "JH".

Click start exam

Medical Procedure Card

PATIENT

Last Name : Maarouf

Middle Initial:

First Name : Shaza

Patient ID : KK855372

Birth Date : Jul 25 1977 (Jan 02 2000) or (02 Jan 2000)

Sex : ☐ Male ☐ Female ☐ Other

Implant present: ☐ Yes ☐ No

PROCEDURE

Study ID : 927/803

Study Description : MAMMOGRAM

Accession Number : 927/803

Procedure Description : MAMMOGRAM

Operator : JH

Performing Physician : A


Referring Physician : 13993

Scheduled date & time :

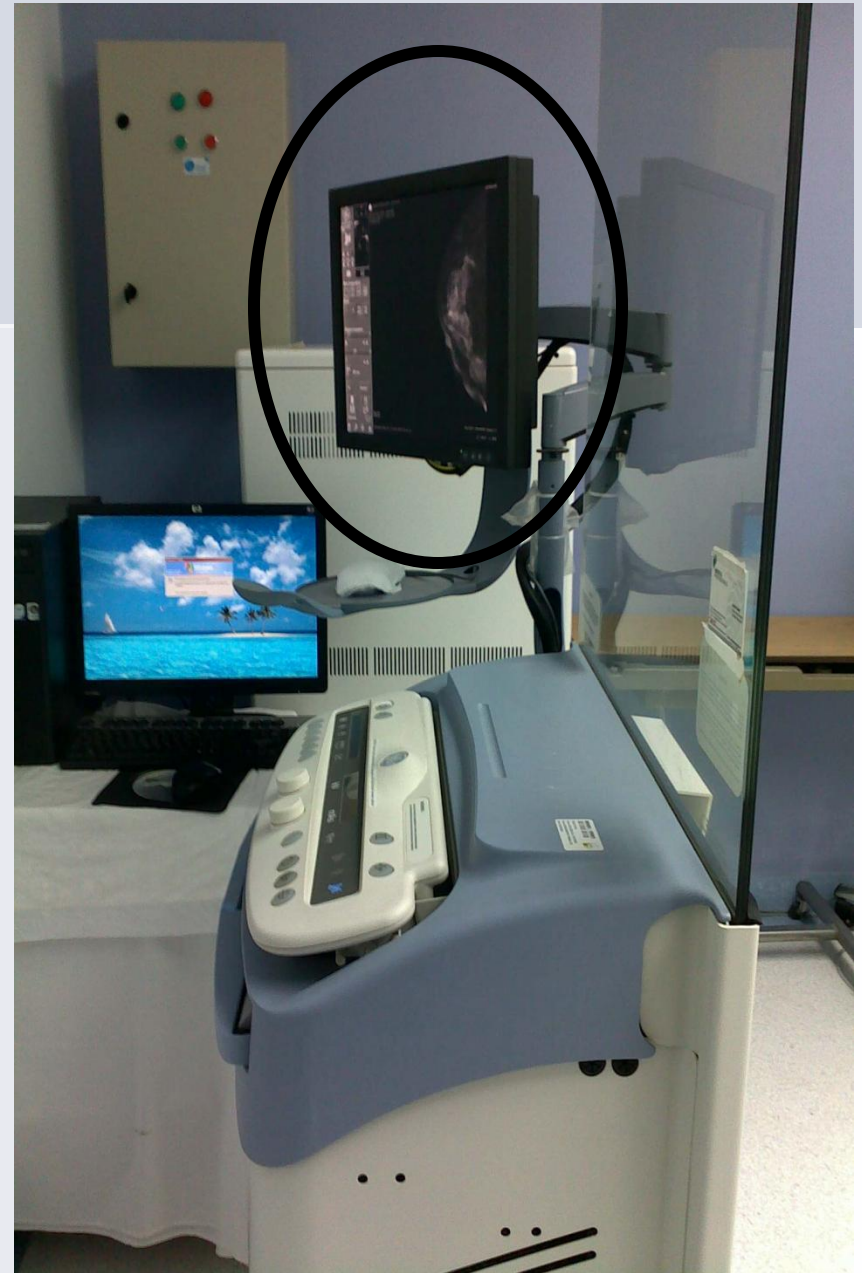Save

Cancel

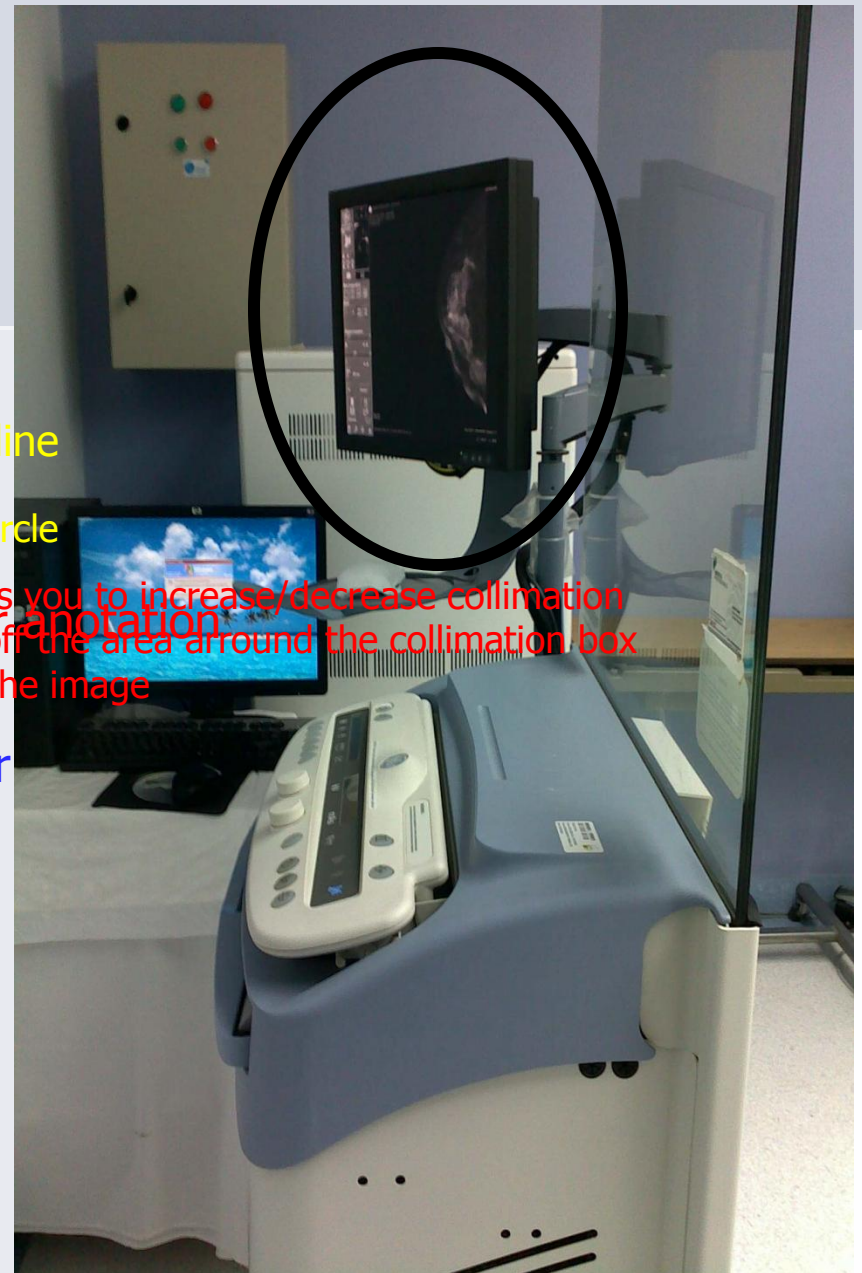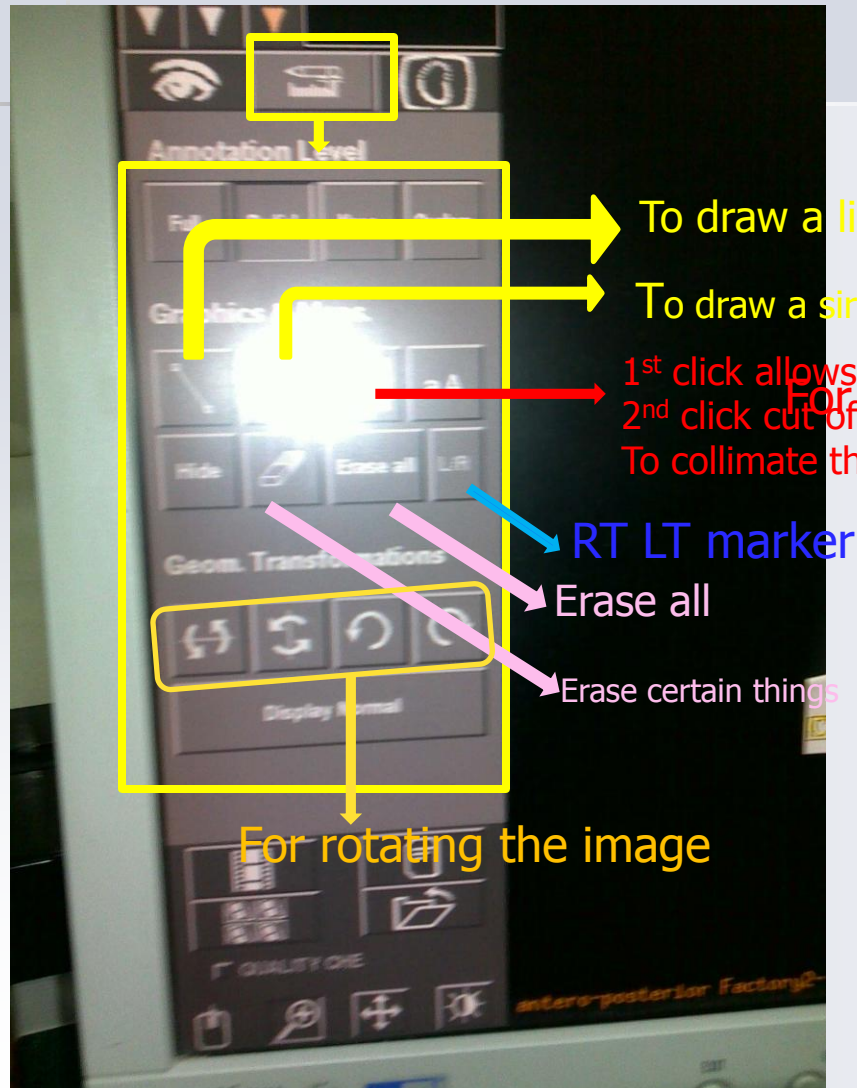
Start Exam



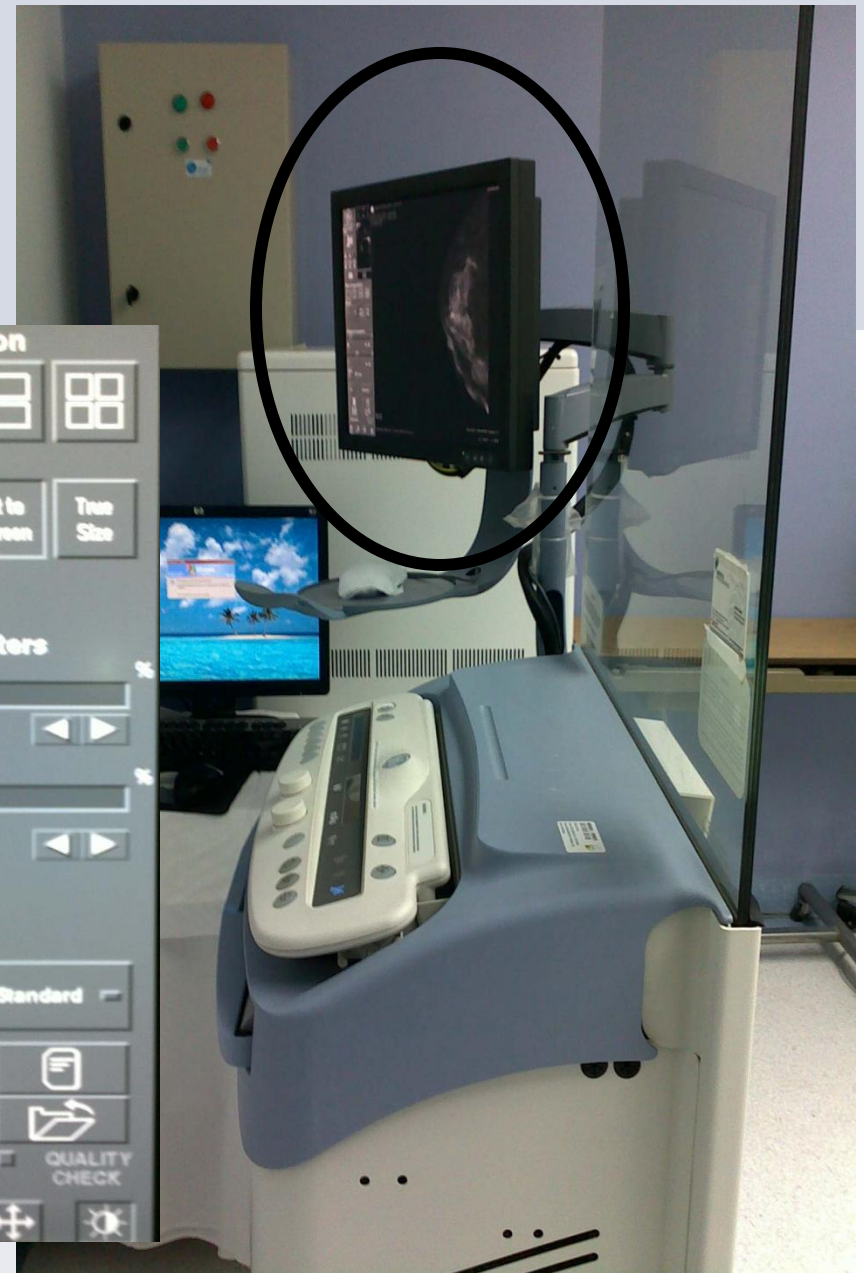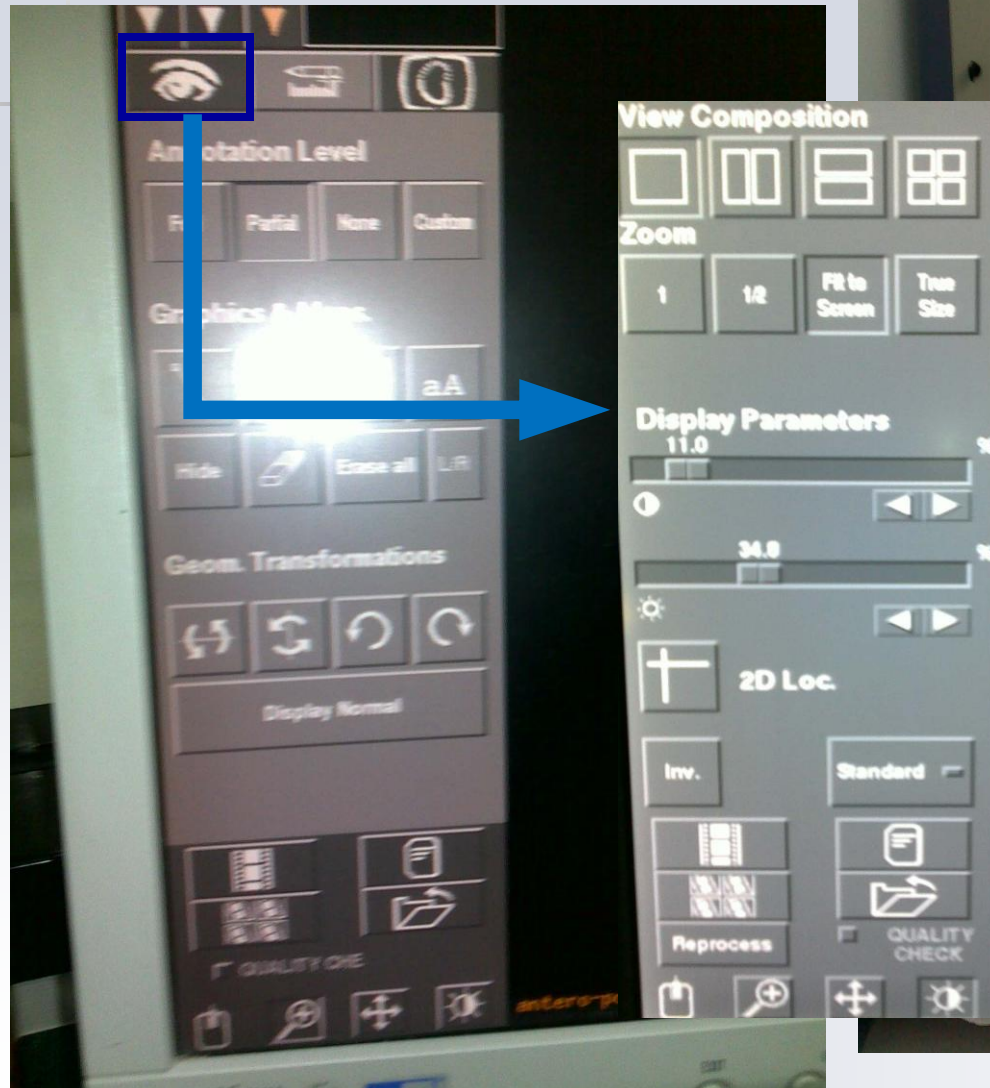screen



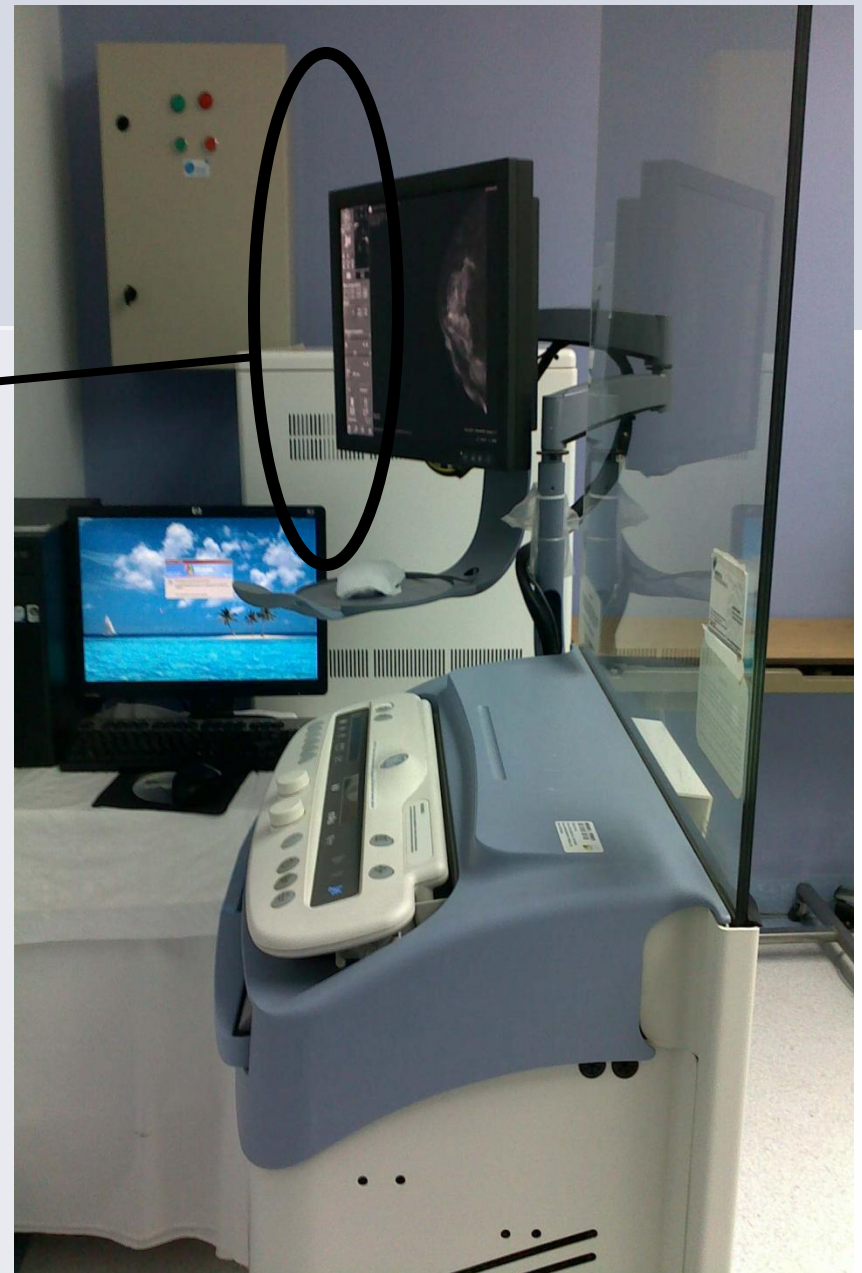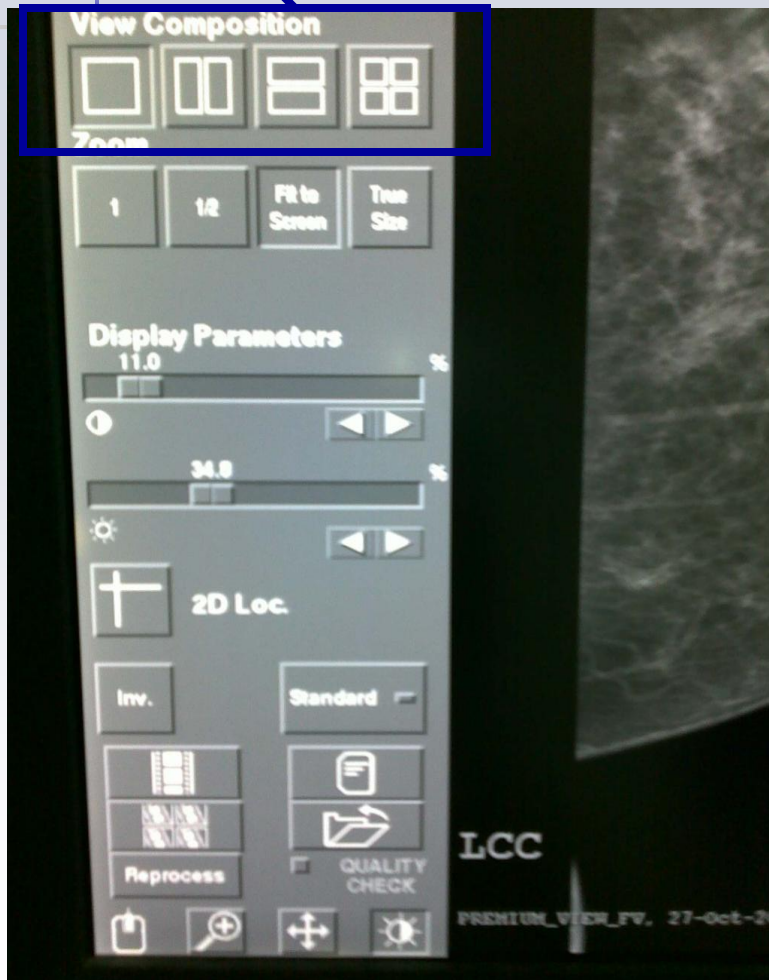
screen



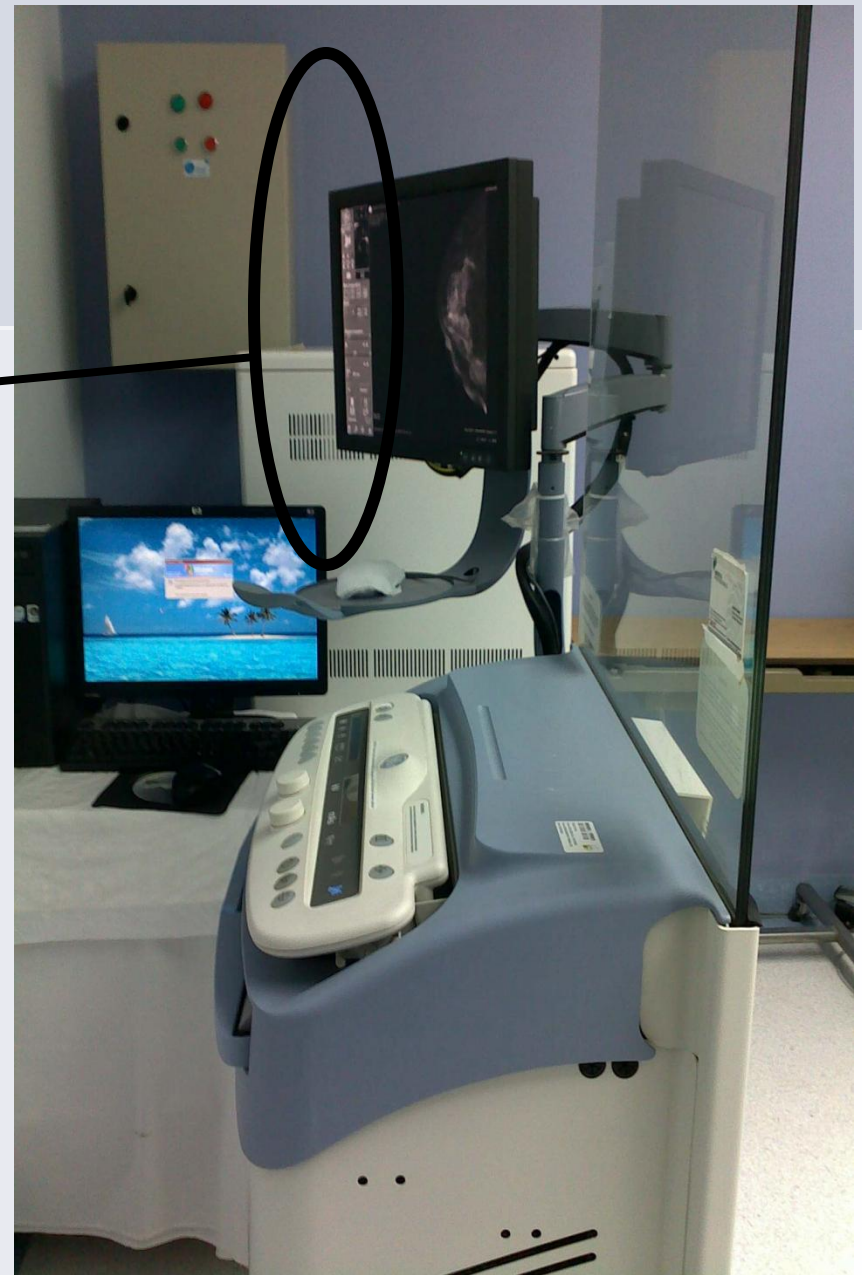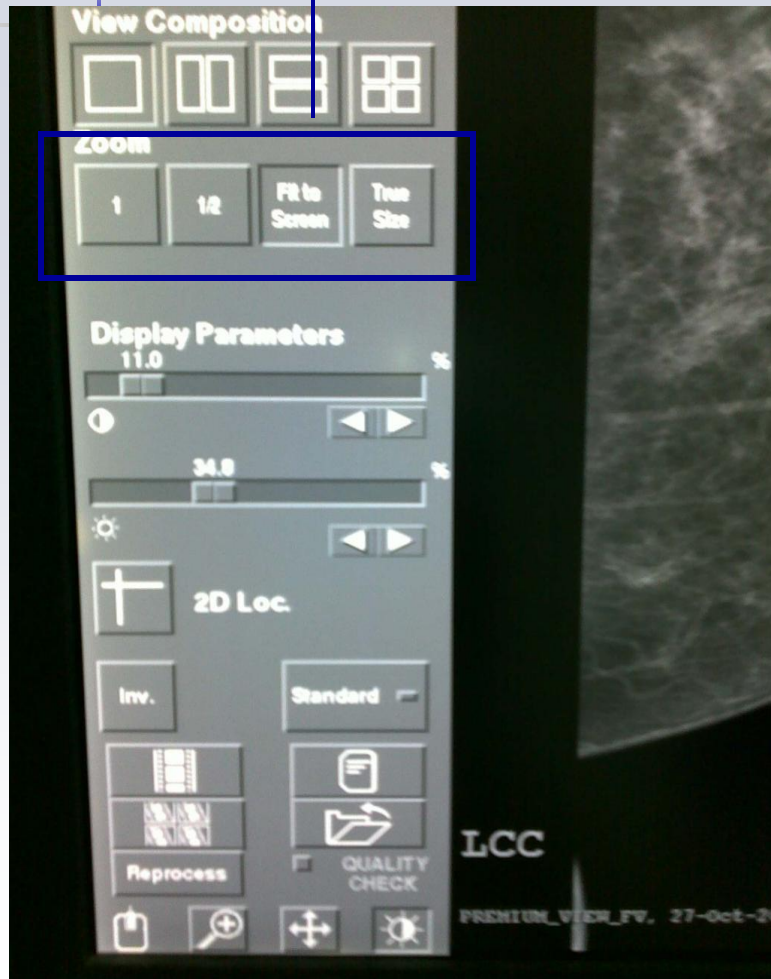
screen



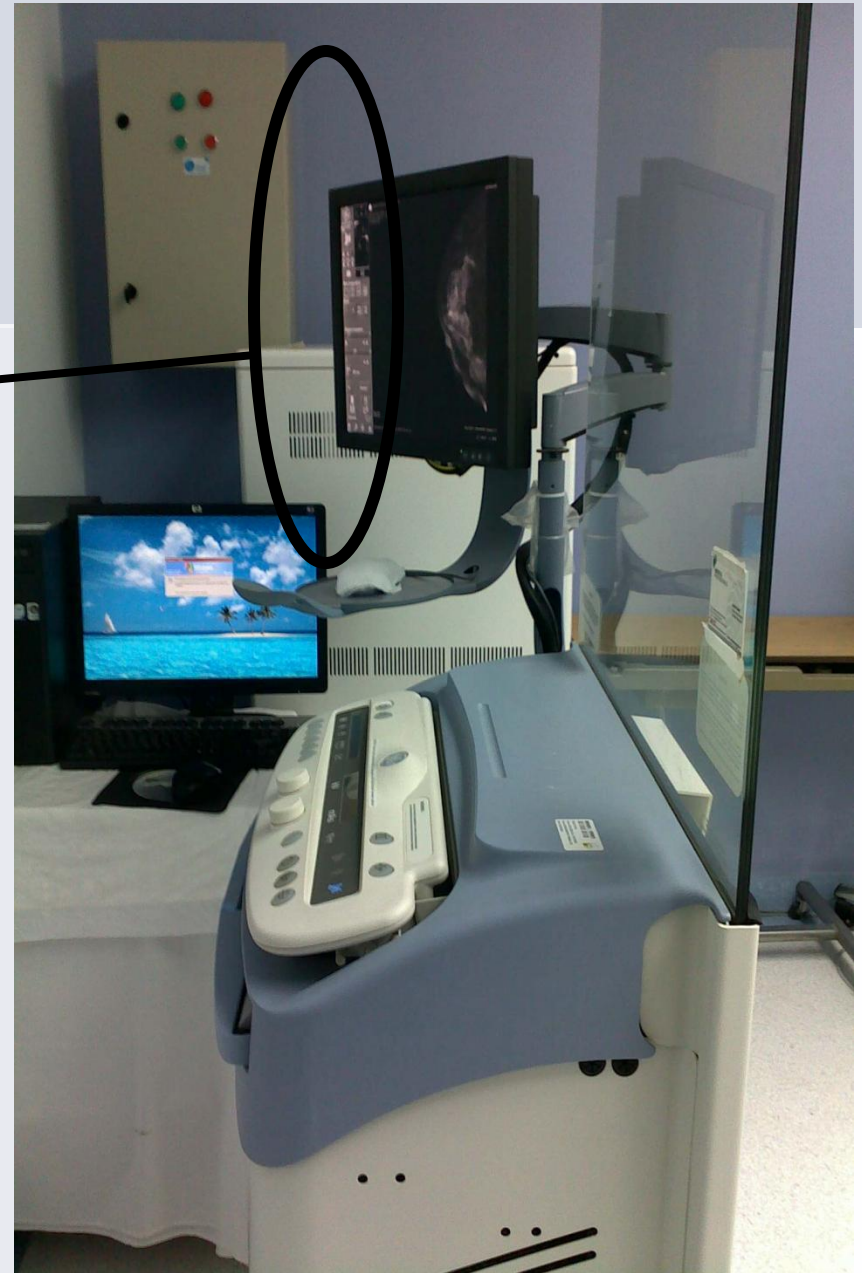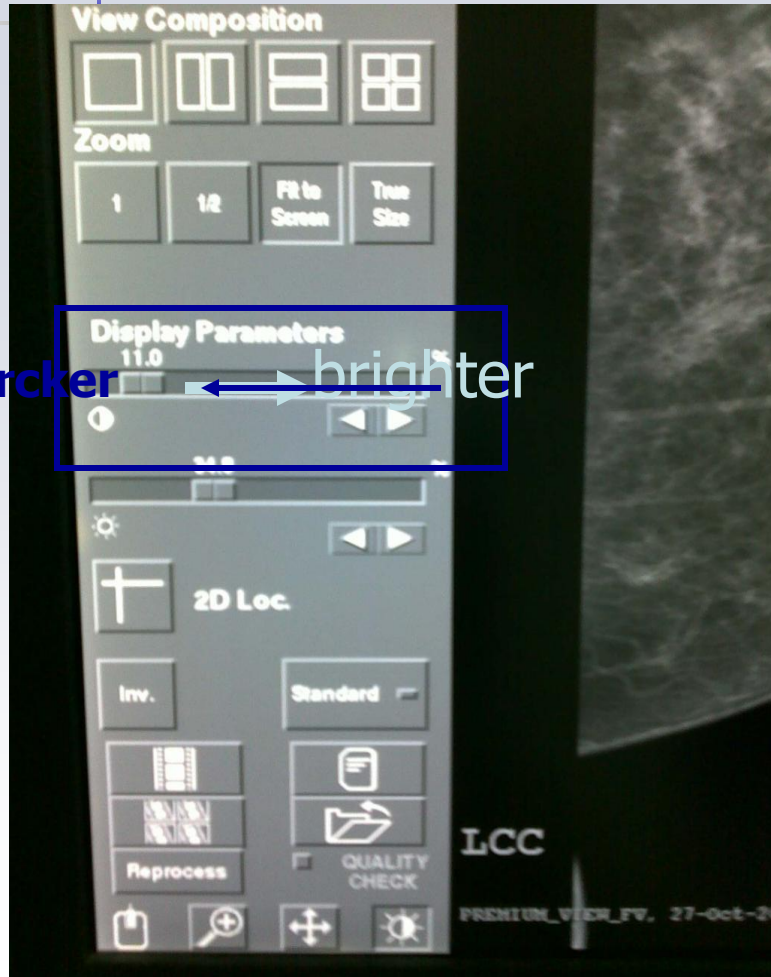
**To chose the number of
images displayed on the
screen**



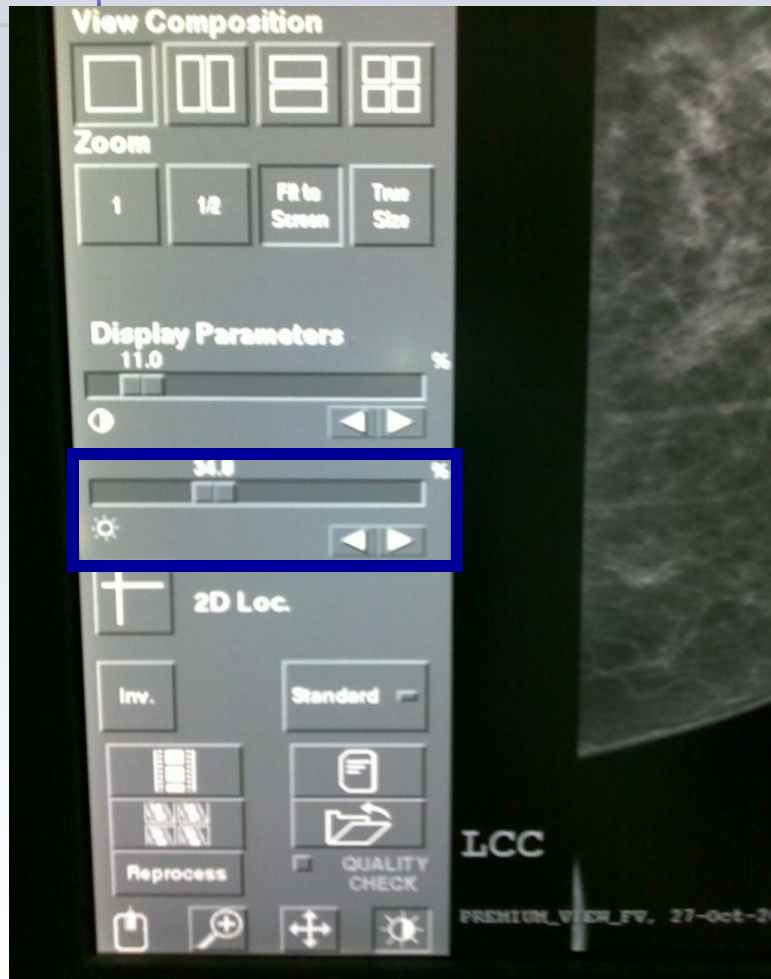
For zooming



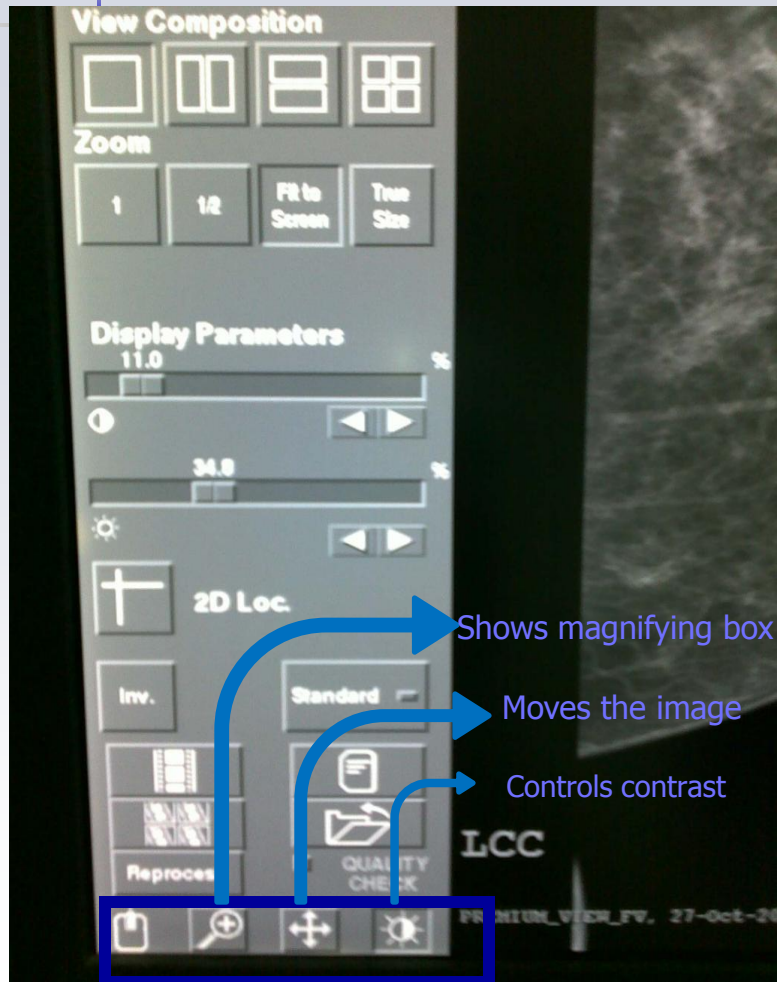
Controls image brightness



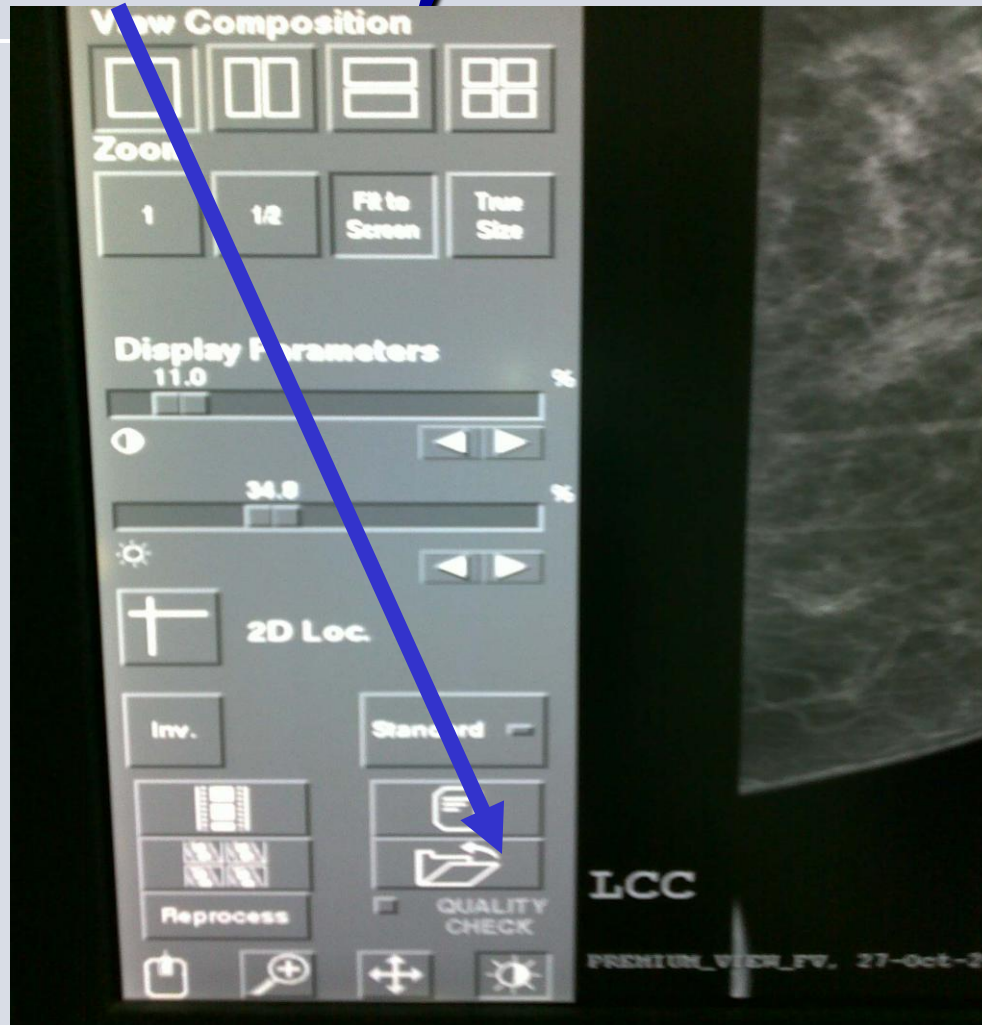
Controls contrast



While middle clicking



**When imaging is done
click here ,then click yes**



Chose pt name

MXWS-001 PACS CDR read/write

Remaining exposure(s): 2614

Oct 27 2008 10:56
Auto delete: OFF

Sort by: Last study date

Patient Name	ID
Mheish Mariam Mub	KK393798
Alkelaibi Jawaher	KK244437
Maqsousa Wosal Ra	KK132965
Alshammari Wasifa	KK513016
AL SEHLI HAYA	KK224124
Al Ajaian Sara Ab	KK12134
Albasri Shamma Al	KK293708
Al Qahtani Nora H	KK572191
Filomena Roy Felo	KK204071
Albeshar Ghaida M	KK417577
Alowaisshz Hessa S	KK146590
Brabante Thelma V	KK307229
Alomran Asma Ali	KK301451
Alfawzan Haila Fa	KK74552
Hessa Alotayani	KK485692
Al Saleh Hessa Sa	KK126272

1 / 138 patients

Sort by: Date

Study ID	Accession Number	Description	Date
927594	927594	MAMMOGRAM	Oct 27 2008

1 / 1 examination

Sort by: Type

Series	Type	Imgs	Procedure Description	Status
1518	PROCES	6	MAMMOGRAM	U S
1517	RAW	6	MAMMOGRAM	U

1 / 2 series

Sort by: Number

Image	Anatomical View	View Name	Laterality	Processing	Date	Time	Angulation	Status
1	BREAST	LCC	L	PREMIUM_VIEW	Oct 27 200	10:37:29	0	S
2	BREAST	RCC	R	PREMIUM_VIEW	Oct 27 200	10:38:36	0	S
3	BREAST	LMLO	L	PREMIUM_VIEW	Oct 27 200	10:40:21	0	S
4	BREAST	RMLO	R	PREMIUM_VIEW	Oct 27 200	10:41:35	0	S
5	BREAST	RMLO	R	PREMIUM_VIEW	Oct 27 200	10:42:57	0	S
6	BREAST	RMLO	R	PREMIUM_VIEW	Oct 27 200	10:43:44	0	S

1 / 6 images

Press , then ok

AW5 - V.43.10.1

MXWS-001 PACS CDR read/write

Remaining exposure(s): 2614

GE Medical Systems

Oct 27 2008 10:56

Auto delete: OFF

Sort by: Last study date

Patient Name	ID	Study ID	Accession Number	Description	Date
Mheish Mariam Mub	KK893798	927594	927594	MAMMOGRAM	Oct 27 2008
Alkelaibi Jawaher	KK244437				
Maqsousa Wosal Ra	KK132965				
Alshammari Wasifa	KK513016				
AL SEHLI HAYA	KK224124				
Al Ajaian Sara Ab	KK121134				
Albasri Shamma Al	KK293708				
Al Qahtani Nora H	KK572191				
Filomena Roy Filo	KK204071				
Albeshar Ghaida M	KK417577				
Alowaishz Hessa S	KK146590				
Brabante Thelma V	KK307229				
Alomran Asma Ali	KK301451				
Alfawzan Haila Fa	KK74552				
Hessa Alotayani	KK485692				
Al Saleh Hessa Sa	KK126272				

1 / 138 patients

Sort by: Date

Series	Type	Imgs	Procedure Description	Status
1518	PROCES	6	MAMMOGRAM	U S
1517	RAW	6	MAMMOGRAM	U

1 / 2 series

Sort by: Type

Image	Anatomical View	View Name	Laterality	Processing	Date	Time	Angulation	Status
1	BREAST	LCC	L	PREMIUM_VIEW	Oct 27 200	10:37:29	0	S
2	BREAST	RCC	R	PREMIUM_VIEW	Oct 27 200	10:38:36	0	S
3	BREAST	LMLO	L	PREMIUM_VIEW	Oct 27 200	10:40:21	0	S
4	BREAST	RMLO	R	PREMIUM_VIEW	Oct 27 200	10:41:35	0	S
5	BREAST	LMLO	L	PREMIUM_VIEW	Oct 27 200	10:42:57	0	S
6	BREAST	RMLO	R	PREMIUM_VIEW	Oct 27 200	10:43:44	0	S

1 / 6 images

Auto print: OFF

Auto push: OFF