

R. Jagger



Synopsis

Occlusal considerations for removable prostheses are essentially the same as for fixed restorations.

The approach to establishing occlusion for removable partial dentures is usually conformative. Partial dentures should not transmit excessive forces to supporting tissues nor interfere with any contacts in intercuspal position or in functional movements. Occasionally a reconstructive approach using onlays is used.

Occlusion for complete dentures has three significant differences:

- The absence of natural teeth in edentulous patients may present significant difficulties in determining an acceptable occlusal vertical dimension.
- Complete denture occlusion is always a reorganised occlusion.
- Absence of teeth produces problems of denture stability (resistance to displacement by lateral forces), particularly of the mandibular complete denture. The stability of complete dentures is optimised by a balanced occlusion/articulation.

This chapter provides an overview of occlusion for partial and complete removable prostheses, including discussion of both clinical and laboratory procedures.

- Occlusal analysis
- Clinical stages
- Onlay dentures
- Complete dentures
 - Occlusion for complete dentures
 - Occlusal vertical dimension
 - Artificial teeth
 - Balanced occlusion
 - Lingualised occlusion
 - Occlusion and patient satisfaction
 - Clinical stages

Good occlusal practice for removable dentures is very similar to that described for fixed prostheses.

Partial dentures should not transmit excessive forces to supporting tissues nor interfere in intercuspal position or in functional movements. The occlusal form is usually conformative with the natural teeth. Occasionally a reconstructive approach using onlays is used. Occlusion for complete dentures, however, has three significant differences:

- The absence of natural teeth in edentulous patients may present significant difficulties in determining an acceptable occlusal vertical dimension (OVD).
- Complete denture occlusion is always a 'reorganised' occlusion.
- Absence of teeth produces problems of denture stability (resistance to displacement by lateral forces), particularly of the mandibular complete denture. The stability of complete dentures is optimised by a balanced occlusion.



Key points

- Partial dentures
 - Occlusion: conformative/reorganised approaches
 - Treatment planning for partial dentures

PARTIAL DENTURES

Occlusion: conformative/reorganised

The usual goal of partial denture treatment (in respect of the occlusion) is to position the artificial teeth so that there is even contact and maximum intercuspation (MI) in the

intercuspal position (ICP). For more extensive partial dentures, such as bilateral distal extension saddle dentures, the aim might also be to achieve a balanced occlusion.

Occasionally, instead of this conformative approach a reorganised approach is used when onlays or an onlay appliance covers some or all of the occluding surfaces of the dental arch.

Treatment planning for partial dentures

When replacing missing teeth, it is of evident importance that treatment is based on a comprehensive treatment plan. The treatment plan must be derived from a careful history, examination and the use of appropriate special investigations. For the partially dentate patient, special investigations include radiographs, tooth vitality tests and usually articulated, surveyed study casts. The treatment plan for the partially dentate patient must include a detailed design of any prosthesis.

Occlusal analysis

During the treatment-planning phase it is important to analyse the occlusion to detect any tooth alignment problems, such as overeruption, that might prevent the construction of a prosthesis with a satisfactory occlusion. A decision must be made as to whether any preprosthetic occlusal adjustments or alterations are necessary; for example, the removal of any tooth cusp interferences along the arc of closure into ICP. Occlusal analysis is done both in the mouth and by the use of articulated study casts.

A detailed account of clinical occlusal analysis has been given in Chapter 5.

Study casts may be articulated without an occlusal record if intercuspal position is coincident with centric relation (CR) and if there are sufficient teeth to provide stable intercuspal position of study casts. If there are insufficient teeth, wax occlusal rims are usually used to determine centric jaw relation (CR).

Clinical stages

Recording centric jaw relation

The working casts also may be articulated without an occlusal record if centric occlusion (CO) is coincident with CR and if there are sufficient teeth to provide stable ICP of the casts. If there are insufficient teeth, wax occlusal rims are used. The wax may be placed on shellac or acrylic base plates, or more commonly on the metal framework. If the wax rims are to be placed on the framework it is important to ensure beforehand that the framework fits accurately and does not interfere with the occlusion in retruded contact position (RCP, ICP) or in lateral excursions.

Insertion – occlusal correction

Minor interferences are often present, as in complete dentures, due to previous clinical or laboratory errors. The dentures must be adjusted so that the natural teeth meet in precisely the same way both with and without the dentures in place.

Often chairside adjustment by selective grinding is sufficient. Marks produced by articulating paper must be interpreted with caution, by visual confirmation and by asking the patient for his or her perception of how the teeth contact. The patient should be asked whether the teeth contact evenly or meet on one side first. If aware of a premature contact, can the patient feel which tooth or teeth meet first. Again, this information must be used with caution.

When maxillary and mandibular dentures are being inserted, each denture must be checked and corrected separately. A final correction is done with both dentures in place.

Very occasionally the occlusal errors are so large that chairside correction is not possible. In these cases, the artificial teeth causing the interferences should be ground off. Wax can be placed on the base in those regions and CR can be rerecorded. If the denture has been returned to the clinic with the casts, a new occlusal record can be taken, the casts remounted and the occlusion corrected in the laboratory. Otherwise an overall impression should be taken with the denture(s) in place. The impressions should be cast and the dentures rearticulated, reset and retried.

Onlay/overlay dentures

Whereas complete dentures always have a reorganised occlusion, partial dentures usually have a 'conformative' occlusion.

A reorganised approach for partial dentures may be considered:

- to correct an overclosed occlusion
- to improve the occlusion, for example when there is a gross discrepancy between RCP and the intercuspal position.

This approach is achieved by the use of onlays.

When a component of the partial denture extends to cover the greater proportion of the occlusal or incisal surface of a tooth it is called an onlay or overlay. Onlays may be used to cover one, many or all of the teeth in the dental arch. They may be made of acrylic resin or cast-metal denture base materials. An alternative method is to add acrylic resin onto retention tags in metal that has been cast to the fitting surface of the teeth. This has the advantage that the occlusal surface may be easily adjusted.

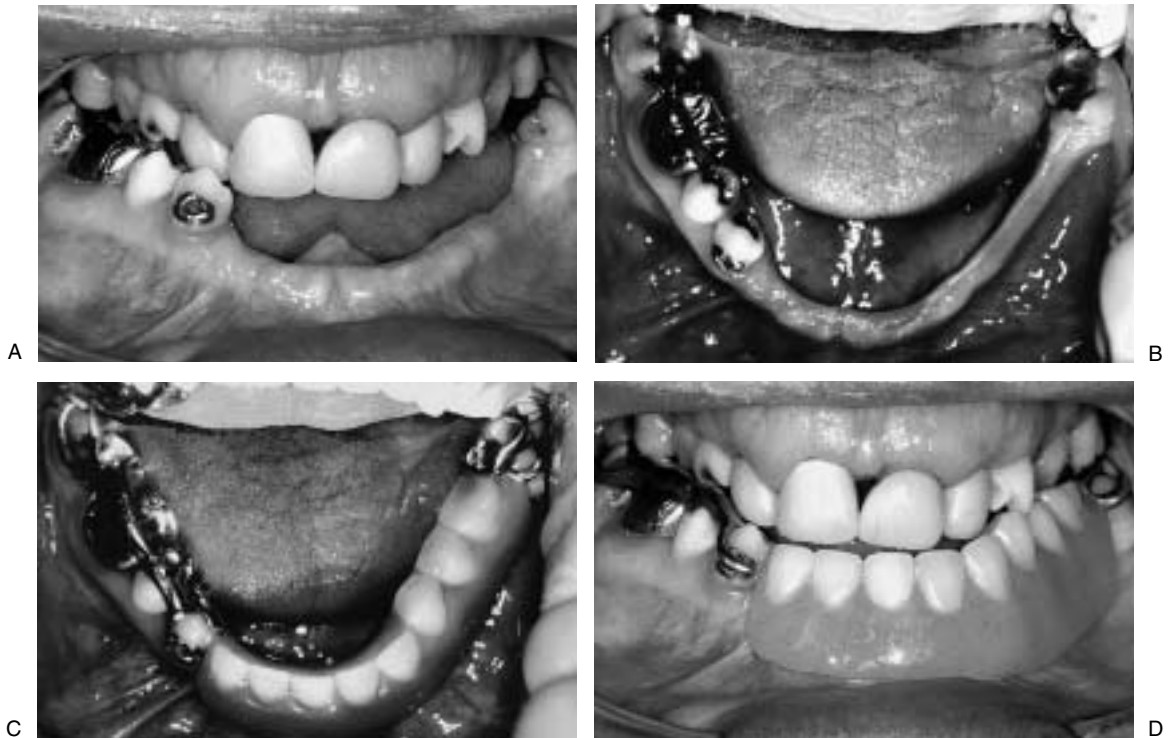


Fig. 12.1 A–D A mandibular partial onlay denture. The appliance replaces one of similar design that had been worn for approximately 20 years.

Diagnostic or temporary onlays are usually constructed in acrylic resin.

The use of an onlay appliance to correct an overclosed occlusion is shown in Figure 12.1.

Extensive coverage of teeth by occlusal onlays can predispose to dental caries. If clinical conditions allow, fixed restorations are the preferred treatment.

COMPLETE DENTURES

Occlusion

In a detailed overview of the literature of occlusal considerations in complete dentures, Palla (1997) noted that patients' satisfaction with complete dentures is a complex phenomenon and that the occlusion plays only a minor part. Further, there is little evidence to support commonly held views on the advantages or disadvantages of tooth form, tooth arrangement or occlusal schemes.

Patient satisfaction with dentures does not correlate closely with technical quality. For example, patients with greatly decreased vertical dimension and severely worn occlusal surfaces may have no complaint about their dentures. Indeed they may be unable to adapt to new

'better' dentures. Nevertheless, it is important to understand the principles of occlusion related to removable prostheses in order to try to provide optimum treatment best suited to each individual. The clinician should have a clear picture of the occlusion that he or she is trying to achieve for each patient.

Recommended occlusion for complete dentures

- Recommended practice is to develop *maximum intercuspation of complete dentures to coincide with CR at an acceptable OVD*. Failure to achieve that can lead to intolerance, usually because of instability of the dentures or because of pain of the alveolar mucosa as a result of uneven load distribution and high stress concentrations.
- It is also recommended that a *balanced occlusion* (i.e. harmonious contacts between maxillary and mandibular teeth in all excursive movements) is provided in order to help give occlusal stability.

Occlusal vertical dimension

There is much evidence to show that it is possible to increase OVD without adverse consequences, in both the natural dentition and in complete dentures (Palla 1997).

There are limits to an individual's ability to adapt to opening or closing an OVD. The OVD has a great influence on facial appearance. Complete dentures with insufficient freeway space cause difficulties with speech and may result in pain beneath the denture.

It can be very difficult to determine an acceptable correct OVD once it is lost and many methods have been developed to help establish OVD (Table 12.1). These are described in detail in standard prosthetic dentistry texts. Perhaps the most commonly used method has been to determine postural jaw position (PJP, 'resting vertical dimension'). OVD is then established 2–4 mm less than PJP. PJP is not constant, however, and methods used to

measure it generally have poor reproducibility. It varies with, among other things, head posture, the instructions given to the patient to achieve 'rest' and with time. It is also known that altering an OVD will lead to the establishment of a new PJP.

The clinician must register an OVD and pass that information to the technician. Experienced clinicians usually rely on a combination of methods at the registration stage; for example, measuring PJP, observing patient appearance at selected OVD and measuring the OVD of previously satisfactory dentures. Clinicians must then try to verify the dimension at try-in stage, again by the use of a similar combination of methods.

It is usually possible to provide a patient with new dentures with a greater OVD than that of the previous old dentures. It is wise to test any increase by the progressive addition of autopolymerising acrylic to the occlusal surfaces of the artificial teeth of the old dentures.

Table 12.1 Some methods used to determine occlusal vertical dimension

- Postural position (PJP, resting vertical dimension); OVD is approximately 2–4 mm less
- Measure OVD of satisfactory previous dentures
- Aesthetics
- Ridge parallelism: Paralleling the crests of maxillary and mandibular edentulous ridges plus a 5° posterior opening gives an indication of correct vertical dimension.
- Pre-extraction records
- Lateral skull radiographs
- Facial measurement
- Phonetics
- Patient reported position of comfort
- Intraoral central bearing pin

Artificial teeth

Artificial teeth are made from either acrylic resin or porcelain. The quality of acrylic teeth has improved greatly in recent years and porcelain teeth are no longer commonly used.

Two types of posterior cusp form are produced by manufacturers of artificial teeth (Fig. 12.2):

- Anatomical teeth – may have different cuspal angulations, e.g. 20°, 30° or 40° cuspal angle; 20° cuspal angle teeth are commonly used for complete dentures.

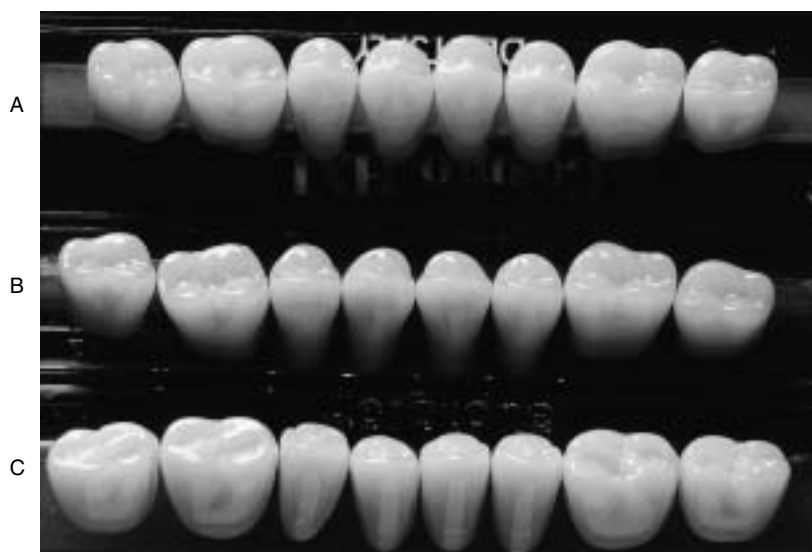

Fig. 12.2 Artificial posterior teeth. **A** anatomical teeth; **B** 10° cusps; **C** zero degree teeth.

- Zero-degree teeth (flat-cusped, cusplless) – are said to be indicated for cases with flat alveolar ridges or where there is great difficulty recording CR.

Research has not provided evidence to support commonly held views on advantages and disadvantages of artificial tooth form. For example, while it is possible that selection of artificial posterior teeth, such as cusped rather than cusplless, may have a marginal effect on chewing efficiency, other factors, in particular retention and stability of the dentures, have far more effect.

Balanced occlusion

Balanced occlusion refers to occlusion with simultaneous contacts of the occlusal surface of all or some of the teeth on both sides of the arch in all mandibular positions. A balanced occlusion is developed by the dental technician on the articulator.

The five determinants or variables affecting occlusal contacts are known as Hanau's quint:

1. *Orientation of occlusal plane.* Average-value articulators have preset distances between the condylar components and the incisal tips. The orientation of the occlusal plane is determined by the clinician when trimming the upper occlusal rim.
2. *Condylar guidance.* Condylar angles of average value articulators are also preset, usually at 30°.
3. *Incisal guidance.* Incisal guidance is commonly set arbitrarily at 10 or 15°.
4. *Cuspal angle.* The cuspal angles of the artificial teeth are produced by the manufacturer.
5. *Compensating curve.* The dental technician sets the artificial teeth with a compensating curve that allows for a balanced occlusion.

The extent to which the balanced occlusion/articulation developed on an articulator will be present in the mouth will depend on the accuracy of the centric jaw registration used to articulate the casts. It will also depend on the degree to which the settings of the articulator replicate the corresponding parameters of the patient's jaws. Use of a semiadjustable articulator and a facebow record, and lateral and protrusive records to set condylar angles, will more accurately replicate the mouth than an average value articulator. In most cases when inserting dentures it will be necessary to adjust the occlusion, for example using articulating foil in the mouth and specific occlusal adjustment at the chairside, in order to produce a balanced occlusion.

Lingualised occlusion

In conventional artificial tooth arrangement the lower artificial buccal cusps occlude with the fossae of the

opposing upper teeth. The upper palatal cusps occlude with the fossae of the lower teeth. In a so-called lingualised occlusion, the lower buccal cusps are cut back so that there is only contact on the upper palatal cusps. This scheme allows the ease of obtaining a balanced occlusion comparable with the use of zero cusped teeth, together with the advantage of retaining posterior tooth cusp form and therefore a pleasing appearance.

Clinical considerations relating to occlusion

Determining occlusal vertical dimension

As described above, determining an acceptable OVD can be difficult. As discussed, the clinician has, however, to register an OVD and pass that information to the technician. Experienced clinicians usually rely on a combination of methods at the registration.

Recording centric jaw relation

Centric jaw relationship is a reproducible position that is used to articulate edentulous casts. The artificial teeth are set so that maximum intercuspation occurs at this position. Centric occlusion for complete dentures is the same as IP.

Many different methods have been described for recording CR. They may be classified as static or functional (Table 12.2). Most methods are capable of giving accurate results but functional techniques such as 'chew-in' techniques are not commonly used. The most common is the use of interocclusal wax occlusal rims.

Selecting an articulator for complete denture prosthodontics

As discussed previously, an average value articulator can be used with good results. However, in order to produce dentures with a balanced occlusion/articulation that should need minimal adjustment at insertion, a semiadjustable articulator together with the use of a facebow, and lateral and protrusive transfer records, should be considered.

Table 12.2 Methods of recording centric jaw relation

Static	Functional
<ul style="list-style-type: none"> • Wax occlusal rims • Extraoral tracing (gothic arch) technique • Intraoral tracing device 	<ul style="list-style-type: none"> • Chew-in techniques • Swallowing techniques

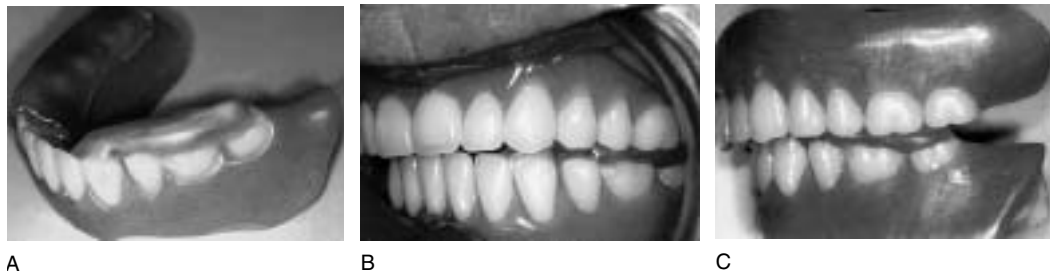

Fig. 12.3 Precentric check record. **A** Softened wax on the posterior mandibular teeth. **B** Patient has closed into the wax in the retruded arc of closure. Closing has stopped before the artificial teeth contact. **C** Precentric record removed from the mouth.

Setting up complete dentures

Setting of teeth requires considerable skill. The determinants of a balanced occlusion have been described above. Setting procedures for artificial teeth have been described in detail elsewhere (Zarb et al 1990).

Split-cast technique

As the acrylic resin cures during the processing of complete dentures, the artificial teeth can move slightly in the moulds. A split-cast technique is recommended to relocate complete dentures on the articulator following processing. This allows any minor occlusal errors that have occurred during processing to be corrected.

Occlusal correction at insertion

There are often occlusal interferences at the insertion stage as a result of inaccuracy of recording CR and limitations imposed by the articulator. Three methods are used to correct the occlusion: selective grinding, precentric (check) record and rerecording CR.

Selective grinding Minor errors are commonly detected with the use of articulating foil and corrected at the chairside. Because of the inherent instability of the denture bases, caution must be used when interpreting the marks made by the paper. Some clinicians consider that any adjustments should only be made with the use of a precentric (check) record, as described below.

There are two stages to chairside occlusal adjustment:

- The first objective is to ensure MI occurs in CR. Two possible errors may be present. One error occurs when the cusp–fossa relationships are correct but one or more teeth meet prematurely. To correct this type of error, the opposing fossae should be deepened until there is even

bilateral contact. The other error is when there is misalignment of cusp–fossa relationships. This is corrected by first grinding mesial and distal slopes of opposing teeth, until cusp–fossa realignment is regained. The opposing fossae can then be deepened until even contact is established.

- The second objective of occlusal adjustment is to obtain a balanced occlusion. To readily achieve this the BULL (buccal upper, lingual lower) rule is recommended. It is the contacting surfaces of these cusps (the palatal surface of the upper buccal cusps and the buccal surfaces of the lower lingual cusps) that are ground, rather than the cusp tips.

If there is misalignment of cusp–fossa relationships, the cusps and their opposing embrasures should be adjusted by grinding mesial and distal cusp slopes of opposing teeth. The adjustment process should be continued until balanced occlusion is achieved.

Precentric (check) record More extensive errors can be eliminated using a precentric record. To do this, two layers of warm softened baseplate wax are placed on the lower premolars and molars. The patient is instructed/guided to close into the wax (but not to close into tooth contact) in the retruded position. The dentures are then articulated using this record and any errors are removed (Fig. 12.3). When the dentures are inserted, minor errors can be readily corrected as described.

Rerecording CR Occasionally the occlusal errors may be so large that chairside adjustment or even a check record could not correct the problem. In these cases, if the appearance of the anterior teeth is satisfactory, the posterior teeth should be ground off, wax can be placed on the base in those regions and CR can be rerecorded. The dentures can then be rearticulated, teeth reset and a denture try-in is repeated.



References

- Palla S 1997 Occlusal considerations in complete dentures. In: McNeil C (ed) *Science and practice of occlusion*, Quintessence, Chicago, pp 457–467
- Zarb G A, Bolender C L, Hickey J C, Carlsson G E (eds) 1990 *Boucher's prosthodontic treatment for edentulous patients*, 10th edn. Mosby, St Louis



Further reading

- Dixon D L 2000 Overview of articulation materials and methods for the prosthodontic patient. *Journal of Prosthetic Dentistry* 235–247

- Fenlon M R, Sherriff M, Walter J D 1999 Association between the accuracy of intermaxillary relations and complete denture usage. *Journal of Prosthetic Dentistry* 81: 520–525
- Freilich M A, Altieri J V, Wahle J J 1992 Principles for selecting interocclusal records for articulation of dentate and partially dentate casts. *Journal of Prosthetic Dentistry* 68: 361–367
- Murray M C, Smith P W, Watts D C, Wilson N G F 1999 Occlusal registration: science or art? *International Dental Journal* 49: 41–46
- Rahn A O, Heartwell C M 1993 Relating inclinations of teeth to concepts of occlusion. In: *Textbook of complete dentures*, 5th edn. Lea & Febiger, Philadelphia, pp 357–371
- Zarb G A, Bergman B, Clayton J A, MacKay H F (eds) 1978 *Prosthodontic treatment for partially edentulous patients*. Mosby, St Louis

