

## Recent advances in etched cast restorations

Gerald Barrack, DDS\*

New York University, College of Dentistry, New York, NY

Conservation of tooth structure precipitated the development of the acid-etched enamel composite resin bonded restorations. Bonding an etched cast restoration to minimally prepared etched enamel was a natural evolution of the concept. This article suggests modifications to increase the retention and longevity of etched-metal bonded restorations.

### HISTORY OF DEVELOPMENT

The pioneering research of Buonocore,<sup>1</sup> the father of modern adhesive restorative dentistry, began in 1955. The current composite resins that contain BIS-GMA were introduced by Bowen<sup>2</sup> in 1962. Composite resins became commercially available in the late 1960s, and after dentists gained experience and confidence with individual restorations, fixed partial denture restorations were attempted. This initially involved bonding an acrylic resin pontic to abutment teeth.<sup>3</sup> Threaded pins and bars were introduced later to reinforce the resin.<sup>4</sup> Rochette,<sup>5</sup> and later Howe and Denehy,<sup>6</sup> described a technique that used a cast metal perforated framework that increased the strength of the retainer that was necessary for longevity.<sup>7</sup>

Thompson et al<sup>8</sup> refined the framework by electrolytically etching nonprecious castings to improve the resin bond to the casting. This etching process was first described by Dunn and Reisbick<sup>9</sup> and Tanaka et al.<sup>10</sup> The resin provided mechanical linkage between the micropores of the alloy and the enamel (Fig. 1). The bond strength of the resin to the etched alloy surface is two to three times greater than the bond strength of the resin to etched enamel.<sup>11</sup> Improved retention and sealing of the restoration over its entire surface are the major advantages of the etched over the perforated framework design.

### INDICATIONS

Etched-metal bonded restorations are indicated in the following situations.

1. As retainers for a fixed partial denture if the abutments provide enough tooth structure for bond-

ing; caries-free abutments or teeth with lesions that do not limit the enamel available for retention are acceptable

2. Periodontal splints replacing the traditional "A" splints
3. Postorthodontic fixed stabilization
4. Innovative applications such as etched inlays and onlays; bonded attachments for removable partial dentures, combined with traditional retainers in a fixed partial denture; and altering tooth morphology for occlusion

### CONTRAINDICATIONS

Bonding is contraindicated if there are (1) abutment teeth with large carious lesions, extensive restorations, or severely abraded teeth; (2) unsightly abutment teeth where esthetics cannot be improved by bonding from the lingual surface; and (3) patients with known sensitivity to nickel or other metals in the nonprecious alloys.

### FRAMEWORK DESIGN

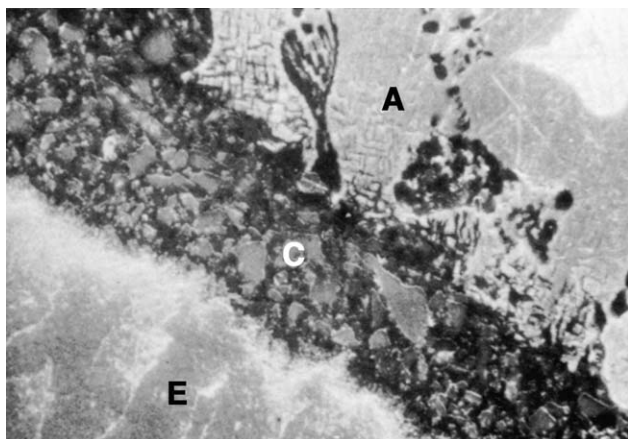
Basic principles of retention and resistance form must be observed; that is, near parallel (6 degree taper) opposing walls, a single path of insertion and withdrawal, maximum coverage, and vertical stops. While these requirements may prove unnecessary for patients in whom the forces applied to the prosthesis are minimal or if the bonding procedures improve, it is presently safer to control the distribution of force with traditional principles. However, the success rate has been impressive over a 4½-year period with the design introduced by Thompson et al.<sup>8,11</sup>

A vertical path of insertion is developed so that the restoration will not be displaced during function. The force is distributed through a "wrap-around" design that includes substantial enamel coverage. This provides the greatest surface area for bonding and a vertical path of insertion. The framework must be rigid enough to resist distortion and designed to limit the stresses applied to the luting resin. This is accomplished with the following principles:


*Anterior design principles.* An incisogingival path of insertion is preferable to a lingual path to resist lingual displacement (Fig. 2). The interproximal framework should extend sufficiently labially to aid stability without compromising esthetics (Fig. 3). A cingulum rest or

Presented at the American Academy of Restorative Dentistry, Chicago, Ill.

\*Clinical Professor, Advanced Education in Prosthodontics.  
Reprinted with permission from J Prosthet Dent 1984;52:619-26.  
J Prosthet Dent 2005;93:1-7.



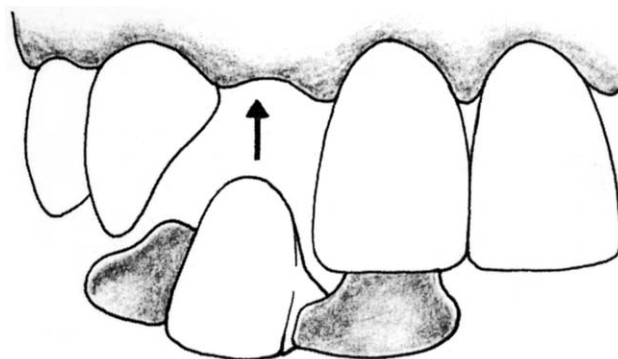
**Fig. 1.** Scanning electron microscopy cross section of etched casting (A) bonded to acid-etched enamel (E). Luting resin (C) is low film thickness composite resin (Comspan, L.D. Caulk Co, Milford, Del) in a field of 35  $\mu$ m. Photo courtesy Dr Van Thompson.



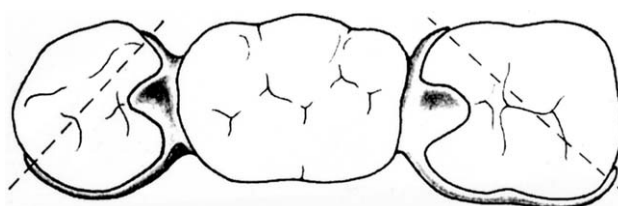
**Fig. 3.** Curved interproximal guide plane provides wrap-around design necessary for vertical path of insertion thus restricting lingual displacement.

notch provides a vertical stop. The location of the lingual incisal margin is determined by the thickness and translucency of the incisal edge of the abutments and the occlusion. The gingival margin is usually 1 mm from the gingival crest but normally not past the cementoenamel junction. Shallow vertical grooves can be incorporated interproximally for additional retention if an adequate wrap-around design is technically unobtainable. The casting should be finished approximately 0.3 to 0.4 mm thick for rigidity but should be knife-edged at the margins.

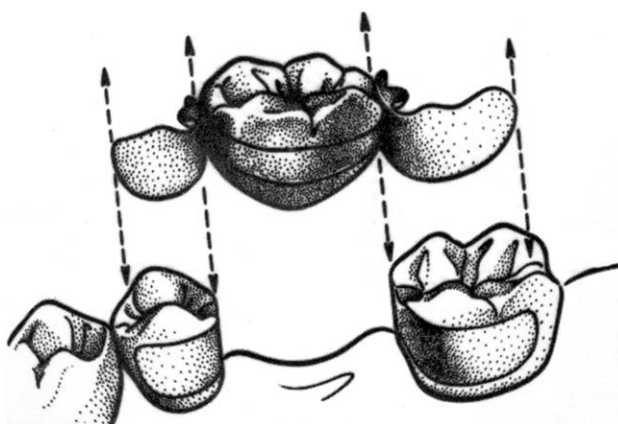
**Posterior design principles.** The wrap-around design is easier because of the anatomy of the posterior teeth, and esthetics is not critical. The entire lingual surface and the interproximal surfaces adjacent to the edentulous space are commonly covered. Engaging the tooth slightly past



**Fig. 2.** Framework design provides an incisogingival path of insertion (arrow).



**Fig. 4.** Rigid framework encompassing more than 180 degrees around each abutment creates resistance form necessary to limit path of insertion.



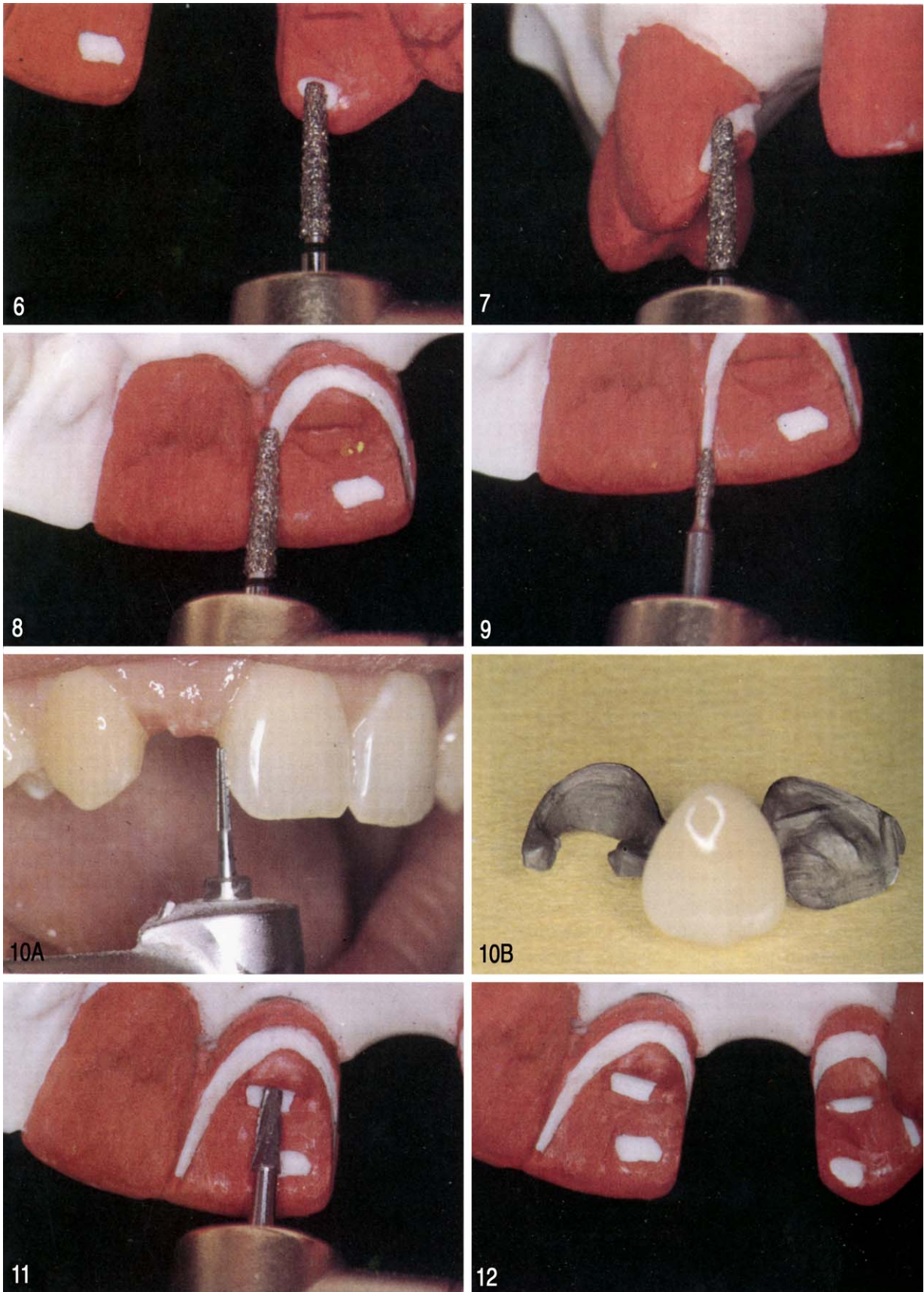
**Fig. 5.** Occlusal rests curtail vertical displacement, and wrap-around design prevents horizontal displacement.

the proximobuccal line angle results in more than 180-degree coverage (Fig. 4). This preparation, in conjunction with a small occlusal rest in each abutment to prevent vertical displacement, provides the necessary retention and resistance (Fig. 5).

## TOOTH MODIFICATION

The natural shape of the abutment teeth is altered to accommodate the appropriate framework design.





Figs. 6 to 12. For legends see next page.

## Anterior region

Tooth preparation is accomplished with minimal but precise removal of enamel. The sequence involves sufficient clearance for occlusion, creation of a path of insertion with a definite finishing line, and development of a cingulum rest. The occlusal relationships determine the lingual surface reduction of the maxillary teeth to accommodate a casting 0.3 mm thick (Fig. 6). The second step requires lowering the height of contour and providing a proximal curved guide plane on the proximal surfaces adjacent to the edentulous space. This preparation allows the casting to engage the proximal surfaces and prevents lingual displacement (Fig. 7). A slight “mini-chamfer” is then created with the same round-end tapered diamond stone approximately 1 mm from the height of the gingival crest (Fig. 8). This provides a smoother margin between the casting and the tooth and guides the technician. Proximal reduction where there are contacting teeth involves slight reduction with a flame diamond stone short of breaking contacts (Fig. 9). Shallow vertical grooves can also be prepared interproximally for additional retention (Fig. 10). Care must be exercised in tooth preparation and framework design to maintain the interproximal embrasure. The third and final step to create a shallow-cingulum rest provides a vertical stop and creates a definite seat for the restoration (Figs. 11 and 12).

## Posterior region

The first step is to modify the proximal surfaces by creating opposing parallel walls. The preparation is confined to enamel, and the restoration is finished at least 1 mm from the gingival crest. The curved buccolingual configuration of the proximal surface is retained to allow proximal wrap-around of the framework with a minimum of 2 mm occlusogingival length for the alloy connector (Fig. 13). Creating these parallel interproximal guide planes lowers the height of contour of the abutment and concomitantly increases the bonding surface. The buccal extension is determined by esthetics and tooth morphology. Increasing the bonding area for the lingual portion of the retainer is achieved by extending guide planes to the most distant linguoproximal line angle from the edentulous space (Fig. 14). Small proximal lesions and/or class II restorations can be managed by a Class II inlay preparation. This can be included in

the casting as shown in Fig. 15. Although tooth preparation and seating are more complex, retention is definitely enhanced. Posterior modifications require occlusal rests in combination with guide planes. The rests are not shaped the same as those used in removable partial dentures because they do not serve the same purpose. They resemble a Class I inlay on the marginal ridge and limit horizontal displacement as well as provide for a vertical stop (Fig. 16).

## IMPRESSIONS

Accurate complete arch elastomeric impressions of the prepared teeth are made with relative ease because there are no subgingival margins. An opposing complete arch cast and occlusal registrations are also necessary.

## LABORATORY PHASE

The laboratory phase involves pouring the cast in die stone, epoxy resin, or in a refractory die material (DVP or Divestment; WhipMix Corp, Louisville, Ky). When stone or epoxy resin is used, the pattern must be removed from the die for investing and casting. If refractory dies are used and/or when the original casts are duplicated in a manner similar to removable partial dentures, the frameworks are waxed on the refractory casts. The cast is trimmed and invested without removing the pattern from the cast. The choice depends on the experience of the technician and the complexity of the casting.

Most nonprecious alloys will be available after specific etching procedures are developed for them. Research that involves the etching of precious and semiprecious alloys is being conducted. Etching procedures for nonprecious alloys have been developed by Thomson as cited by Simonsen et al.<sup>11</sup> Etching the alloy is not performed until after the restoration is seated and the esthetics are acceptable.

After the framework is fitted on the master cast, the pontic can be completed before the try in of the casting. With more complex restorations, the dentist may wish to try in the framework before the pontics are fabricated.

## TRY IN

After the prosthesis is completed, it is rechecked for accuracy, the pontic is evaluated for ridge adaptation, shade, and form, and the occlusion is perfected. The

**Fig. 6.** Relieving occlusal contacting areas for minimum thickness of 0.3 to 0.4 mm in framework.

**Fig. 7.** Providing curved guide plane interproximally to established path of insertion.

**Fig. 8.** Creating gingival minichamfer with round-end diamond stone for smoother transition from restoration to tooth.

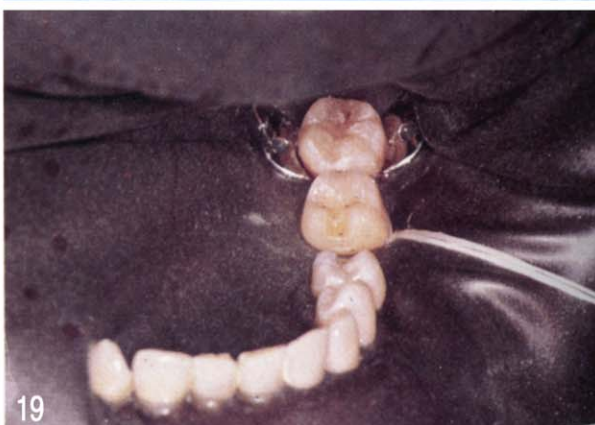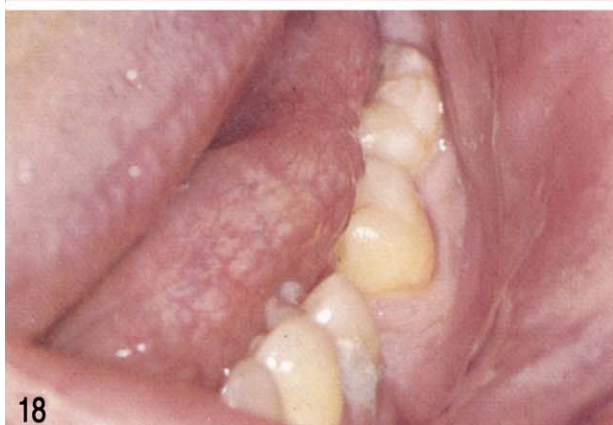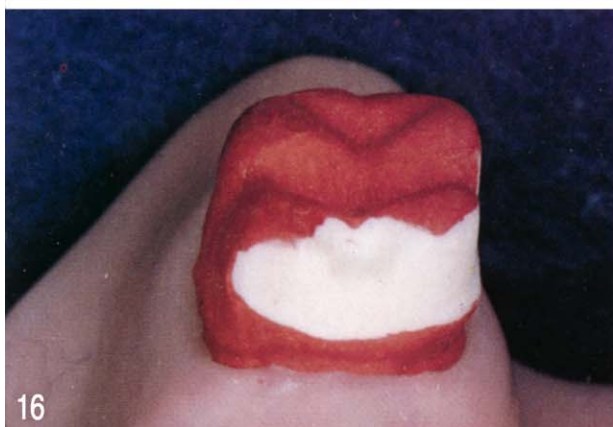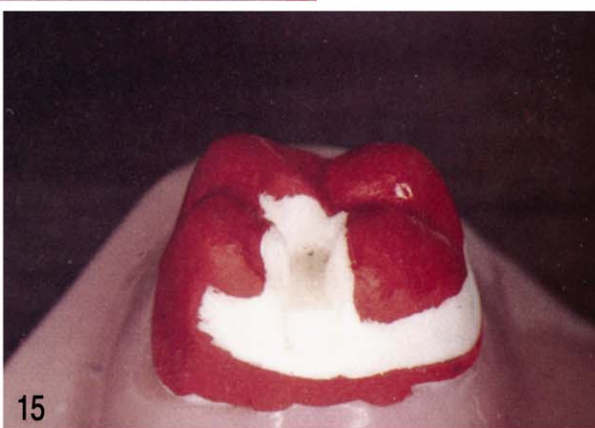
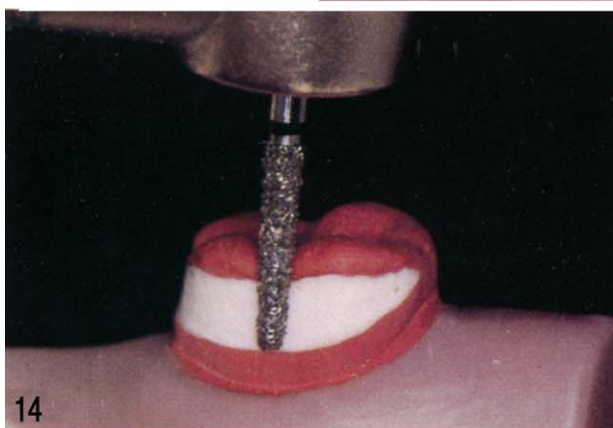
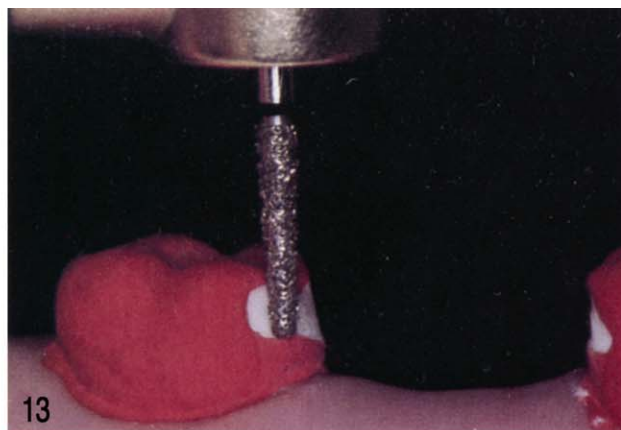**Fig. 9.** Flame-shaped diamond stone to open lingual embrasures for maximum wrap-around.

**Fig. 10. A,** Creating vertical groove with No. 169 L fissure bur ensures resistance to lingual displacement. **B,** Vertical groove on distal surface of central incisor.

**Fig. 11.** Cingulum rest is created with square-end diamond stone to provide positive seat at bonding stage.

**Fig. 12.** Completed preparation demonstrating curved guide plane, minichamfer, and cingulum rest.





Figs. 13 to 19. For legends see next page.

possibility of “greying out” of anterior abutments should be determined and an opaque luting resin selected to effectively mask this phenomenon. This is tested by placing either part A or part B (Fig. 1) on the casting and seating the restoration. Parts A and B can also be mixed with a drop of eugenol to prevent setting. If there is an obvious change at the incisal edge because of the resin, the casting should be cut back from the incisal edge until the esthetics are acceptable. Characterization of the porcelain must be completed and the ground surfaces refinished before the casting is etched.

## ETCHING

The final laboratory phase involves etching the metal surfaces that will be in contact with enamel. The procedure is commonly performed in a commercial dental laboratory. The procedure is not difficult; however, the new technique requires careful and specific routines. The major piece of new equipment is a direct current power supply with accurate regulators for current and voltage. Manufacturers are currently distributing the power supply in addition to the other necessary equipment and supplies (Fig. 17). The casting is connected to the anode, and a stainless steel rod serves as the cathode. Surfaces not being etched are covered with a hard sticky wax. This includes the veneer as well as the polished outer surface of the restoration.

The surface to be etched is cleaned with an air abrasive with 50  $\mu\text{m}$  particle size aluminum oxide (before the casting is placed in the acid). The etching occurs when a current passes through the acid and turns the etched alloy surface black. This layer must be removed by placing the casting in 18% hydrochloric acid in an ultrasonic cleaner for 10 to 15 minutes. A properly etched surface can be determined by viewing it under a microscope or by noting water removal from the surface when an air syringe is directed obliquely. The water remains on the surface for a few seconds and appears to evaporate rather than slide off. After it is etched, care must be taken not to contaminate this surface in handling and storage.

## BONDING AND PLACEMENT

Strict moisture control is necessary during the bonding phase. The rubber dam is the accepted method and has predictable results, especially in the mandibular arch

(Figs. 18 and 19). The teeth should be cleaned with a nonfluoridated, nonflavored pumice. The pumice is rinsed off and the teeth dried. If the path of insertion is complex, seating can be confirmed at this time without contaminating the teeth or the prosthesis.

The enamel is etched with 30% to 40% phosphoric acid (supplied with composite resin bonding kits) for 1 minute, washed thoroughly, and dried with oil-free and moisture-free air.

The restoration is bonded to the enamel with a bonding agent (unfilled resin) and a luting composite resin. Any chemically cured bonding agent may be used, but a stronger bond to enamel (25% to 50%) and dentin is obtained with the new dentin-bonding agent Scotch-bond (3M Co, Minneapolis, Minn), which binds chemically as well as mechanically. The dentin-bonding agent should contact only the tooth because it causes the luting resin to cure rapidly. A regular bonding agent should be used on the etched casting. The luting resins for this technique have a film thickness of 25  $\mu\text{m}$  which is comparable to the American Dental Association accepted dental cements.

Although the greying out of thin or translucent anterior teeth has been improved with the new opaque luting resins, shade changes still occur and further research is necessary.

Contrary to traditional bonding, in which the bonding agent cures before the filled resin is applied, in this technique the unfilled resin must not harden during placement of the restoration because it affects seating and occlusion. It is applied sparingly to the etched casting and the etched enamel while the luting resin is mixed. After it is mixed, the resin is applied to the casting with a syringe (CR Syringe; Centrix, Inc, Stamford, Conn) and the restoration is seated and held firmly in place while the assistant removes the uncured excess material. The excess resin when cured is an insoluble irritant that retains plaque and requires time-consuming but necessary removal.

## ADVANTAGES

Advantages include: (1) conservative tooth preparation only in enamel, (2) supragingival margins, (3) no pulpal irritation, (4) optional anesthesia with minimal stress to the patient, (5) satisfactory esthetics, (6) restorations fabricated on unaltered casts, (7) reduced chair-time, and (8) cost reduction.

**Fig. 13.** Providing curved proximal guide plane with tapered round-end diamond stone.

**Fig. 14.** Lingual surface is modified for maximum bonding area.

**Fig. 15.** Class II inlay preparation used for additional retention and as vertical stop.

**Fig. 16.** Ideal shallow occlusal rest is made with wide, tapered, square-end diamond stone.

**Fig. 17.** A commercially available etching unit (Oxy-etch, Oxydental, Hillside, NJ).

**Fig. 18.** Rubber dam offers visibility and moisture control.

**Fig. 19.** Rubber dam offers visibility and moisture control.

## DISADVANTAGES

Disadvantages include the following considerations: (1) relatively new technique and longitudinal studies are unavailable; (2) contraindicated for abutments with large carious lesions and/or restorations; (3) display of metal posteriorly; (4) possible alterations in abutment appearance because of the greyiness of the etched casting or an increase in opacity from the luting resin; (5) difficulty in determining if the alloy has been etched properly; (6) equipment required by laboratory or dental office; (7) acids must be handled with care; (8) because soldering is difficult, frameworks usually are cast in one piece; (9) temporary cementation usually is not possible; and (10) esthetics, pontic contour, and ridge adaptation must be confirmed at try in.

## DISCUSSION

The most popular alternate to this new technique is the complete coverage retainer. Complete crowns have advantages and indications, and much has been written about their overuse and periodontal disadvantages. The partial coverage fixed partial denture with inlays, onlays, pin ledges, or three-quarter crowns, are excellent but difficult restorations and require conscientious laboratory support. A removable partial denture is a viable alternative often selected for economic reasons, or in younger patients for endodontic considerations; but psychologic resistance to a removable restoration is common.

If the etched cast restoration can be maintained intra-orally for extended periods of time, it should be considered as an alternative treatment.

## SUMMARY

This article described the etched cast restoration. The advantages, disadvantages, indications, contraindications, and technique were discussed. The rationale for modifications in the original framework design and tooth preparation was also presented; some unique advantages over traditional fixed prosthodontics are provided. A retentive framework with maximum coverage is recommended until research expands and simplifies the technique.

## REFERENCES

1. Buonocore MG. A simple method of increasing the adhesion of acrylic filling material to enamel surfaces. *J Dent Res* 1955;34:849.
2. Bowen RL. Synthesis of a silica-resin direct filling material. *J Dent Res* 1958;37:90.
3. Stolpa JB. An adhesive technique for small anterior fixed partial dentures. *J Prosthet Dent* 1975;34:513.
4. Jordan RE, Suzuki M, Sills PS, Gratton DR, Gwinnett JA. Temporary fixed partial dentures fabricated by means of the acid-etch resin technique: A report of 86 cases followed for up to three years. *J Am Dent Assoc* 1978;96:994.
5. Rochette AL. Attachment of splint to enamel of lower anterior teeth. *J Prosthet Dent* 1973;30:418.
6. Howe DF, Denehy GE. Anterior fixed partial dentures utilizing the acid etch technique and cast metal framework. *J Prosthet Dent* 1977;37:28.
7. Sweeney EJ, Moore DL, Donner JJ. Retentive strength of acid-etched anterior fixed partial dentures: An in vitro comparison of attachment techniques. *J Am Dent Assoc* 1980;100:198.
8. Thompson VP, Livaditis GS, Del-Castillo E. Resin bond to electrolytically etched nonprecious alloys for resin bonded prostheses [abstract 265]. *J Dent Res* 1981(Special issue A).
9. Dunn B, Reisbick MH. Adherence of ceramic coatings on chromium-cobalt structure structures. *J Dent Res* 1976;55:328.
10. Tanaka T, Atsutz M, Uchiyama Y, Kawashima I. Pitting corrosion for retaining acrylic resin facings. *J Prosthet Dent* 1979;42:282.
11. Simonsen R, Thompson V, Barrack G. Etched cast restorations: clinical and laboratory techniques. Chicago: Quintessence; 1983. p. 41-56.

0022-3913/\$30.00

Copyright © 2005 by The Editorial Council of *The Journal of Prosthetic Dentistry*.

doi:10.1016/j.prosdent.2004.10.025