

Anchorage condition during canine retraction using transpalatal arch with continuous and segmented arch mechanics

Adel Alhadlaq^a; Thamer Alkhadra^a; Tarek El-Bialy^b

ABSTRACT

Objective: To compare anchorage condition in cases in which transpalatal arch was used to enhance anchorage in both continuous and segmented arch techniques.

Materials and Methods: Twenty cases that required first premolar extraction for orthodontic treatment and transpalatal arch to enhance anchorage were included in this study. Ten cases were treated using the continuous arch technique, while the other 10 cases were treated using 0.019 × 0.025-inch TMA T-loops with posterior anchorage bend according to the Burstone and Marcotte description. Lateral cephalometric analysis of before and after canine retraction was performed using Ricketts analysis to measure the anteroposterior position of the upper first molar to the vertical line from the Pt point. Data were analyzed using an independent sample *t*-test.

Results: There was a statistically significant forward movement of the upper first molar in cases treated by continuous arch mechanics (4.5 ± 3.0 mm) compared with segmented arch mechanics (-0.7 ± 1.4 mm; $P = .01$).

Conclusions: The posterior anchorage bend to T-loop used to retract the maxillary canine can enhance anchorage during maxillary canine retraction. (*Angle Orthod.* 0000;00:000–000.)

KEY WORDS: Anchorage loss; Canine retraction; Continuous arch technique; Segmented arch technique

INTRODUCTION

Tooth extraction in orthodontics is performed for a variety of reasons, including teeth crowding/arch length deficiency, dentoalveolar protrusion, anteroposterior dentoalveolar mal relationships, and presurgical compensation in skeletal mal relationships that are combined with malocclusion. The mechanics of closing the extraction spaces depend on the diagnostic criteria that dictate the required type of anchorage. Anchorage is considered maximum when less than one-third of the extraction space is lost by forward movement of the posterior teeth, moderate anchorage when up to half of the extraction space is lost by forward

movement of the posterior teeth, and minimum anchorage when more than two-thirds of the extraction space is lost by forward movement of the posterior teeth.^{1–3} In most cases of maximum anchorage, anchorage control may be achieved by a variety of mechanics/techniques or appliances.

There has been a recent trend for using noncompliant appliances, such as headgear combined with transpalatal arch (TPA) and temporary anchorage devices (TADs). Headgear is known to be inconvenient for most patients, and full-time wear is questionable. The TADs have recently been used extensively in orthodontics. However, regardless of the published encouraging results, risks of complications and failure remain unavoidable side effects.² It is widely believed that friction is one of the main sources in anchorage loss when continuous arch mechanics are used. Recent reports showed that self-ligating brackets do not provide better anchorage control, especially with respect to less friction, which is believed to be obtained with self-ligating bracket systems.^{4–9} The TPA has been widely used in orthodontics either with continuous or segmented arch mechanics to minimize anchorage loss and/or control rotation of the upper first molars.^{1,3,10–20} Although TPA has been shown not to improve anchorage control during space closure,¹⁸

^a Associate Professor, Department of Pediatric Dentistry and Orthodontics, College of Dentistry, King Saud University, Riyadh, Saudi Arabia.

^b Associate Professor, Department of Orthodontics, School of Dentistry, University of Alberta, Edmonton, Canada.

Corresponding author: Dr Tarek El-Bialy, 7-020D Katz Group Centre for Pharmacy and Health Research, University of Alberta, Edmonton, Alberta T6G 2E1, Canada (e-mail: telbialy@ualberta.ca)

Accepted: July 2015. Submitted: April 2015.

Published Online: August 10, 2015

© 0000 by The EH Angle Education and Research Foundation, Inc.

many clinicians still believe that the TPA alone can control anchorage during space closure in orthodontic extraction cases.^{18,19} The TPA has been studied extensively in order to evaluate its possible role in controlling anchorage.^{21–25} It has been recently suggested that TPA can control anchorage, especially when it is combined with TADs.^{24–26} In segmented arch mechanics, canine retraction T-loops have been used to control anchorage during space closure by modulating moments of the posterior teeth/part of the T-loop.^{3,10,11}

The aim of this study was to compare anchorage loss between two groups of patients who were treated either with continuous arch or segmented arch technique using T-loops to close extraction spaces while TPA was used to support the upper first molars.

MATERIALS AND METHODS

Records of 20 orthodontic patients treated either by continuous arch technique ($n = 10$) or segmented arch technique using T-loops and TPA were studied. Analyzed records included lateral cephalometric radiographs before treatment (T0) and immediately after complete canine retraction (T1). This study was approved by the Health Ethics Review Board at the University of Alberta (protocol Pro00041075).

The bracket system used in all patients was the Synergy bracket system (0.022×0.025 inches; RMO, Denver, Colo). The TPA was fabricated from 0.036 stainless steel wire soldered to previously fit upper first molar bands. In the continuous arch wire group, sliding of upper canines was performed along 0.018×0.025 -inch stainless steel wire using an elastomeric chain connected between the upper canines and upper molars' band hooks (Energy chain, RMO). In the segmented arch technique cases, initial leveling within the buccal segment was performed using 0.018-inch round nickel titanium wire (RMO), and then the posterior teeth (second premolar to second molar) were stabilized by rigid 0.018×0.025 -inch stainless steel wires (RMO). Canine retraction was performed using a T-loop fabricated from 0.019×0.025 -inch titanium-molybdenum alloy (RMO). The anterior part of the T-loop (alpha) was bent 35° apical, while the posterior part (beta) was bent 60° apical to produce a posterior moment-to-force ratio of about 12 (moment of couple $[M_C]/$ moment of force $[M_F] > 1$) in the posterior segment. The anterior segment would produce a moment-to-force ratio of approximately 6 ($M_C/M_F < 1$) at 6-mm activation of the T-loop that is positioned initially off center mesially (Figure 1). This way, the constructed T-loop would produce retraction of the canines with a controlled tipping movement while the higher moment at the posterior segment

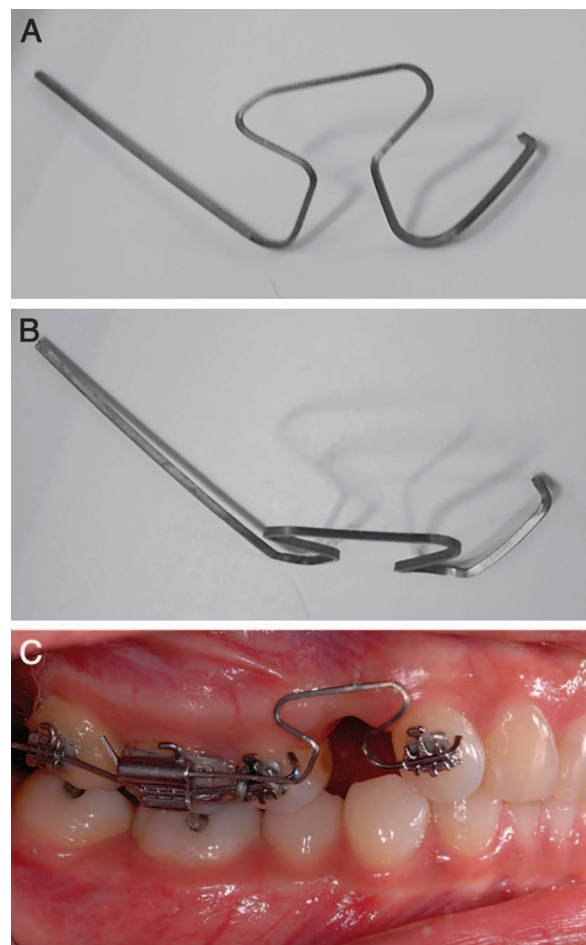


Figure 1. (A) T-loop side view. (B) T-loop top view. (C) T-loop side intraoral view.

would minimize the forward movement of the posterior teeth.^{1–3,7–12,20} Also, anterior and posterior toe-in bends were added to prevent rotation of the canine during retraction.^{1–3,7–12,20} The T-loops were reactivated after 3 mm of space closure.

Cephalometric radiographs were obtained at the beginning of the treatment and after space closure. Cephalometric measurements are outlined in Table 1. All cephalometric radiographs were digitized using Dolphin imaging software (Dolphin Imaging & Management Solution, Chatsworth, Calif), and Ricketts cephalometric analysis was used.²⁷ Anchorage was assessed by evaluating the anteroposterior movement of the distal surface of the upper first molar to a vertical line drawn from the Pt point perpendicular to the Frankfurt plane.²⁷ Five random radiographs were digitized twice at 3-week intervals, and comparison between the two measurements was performed using a paired *t*-test to evaluate possible error in digitization and measurements.

Table 1. Cephalometric Analysis

	Continuous Arch Group Difference Between T0 and T1		Segmented Arch Group Difference Between T0 and T1		t-Test
	Mean \pm SD	Max/Min	Mean \pm SD	Max/Min	P Value
Dental relationships					
Molar relation, mm	-0.3 ± 1.4	1.7/−2.3	0.9 ± 2.2	4.5/−2.1	.08
Overjet, mm	-1.5 ± 1.1	0.2/−3.7	-0.2 ± 2.7	3.1/−6.3	.47
Overbite, mm	0.3 ± 2.3	6.2/−2.5	-1.1 ± 2.3	1.8/−6.3	.50
Mandibular incisor extrusion, mm	0.1 ± 1.2	3.1/−1.3	-0.3 ± 0.7	1/−1.5	.37
Interincisal angle (U1-L1), °	7.4 ± 13.8	29/−23.5	-1.7 ± 8.7	8.6/−19.9	
Skeletal/dental					
U-incisor protrusion (U1-APo), mm	-3.6 ± 1.0	−2.4/−5.8	0.5 ± 2.4	6.6/−2.6	.11
L1 protrusion (L1-APo), mm	-1.3 ± 2.6	5.8/−4.1	0.6 ± 2.2	5.1/−2.6	.36
U-incisor inclination (U1-APo), °	-4.6 ± 8.2	11.5/−14	0.6 ± 7.3	11.4/−11	.36
L1 to A-Po, °	-2.9 ± 6.9	12/−15	1.1 ± 5.8	10.9/−6.6	.49
Occlusal plane to FH, °	-3.1 ± 4.0	2.4/−8.4	-1.6 ± 3.6	7.2/−4.7	.27
U6-PT vertical, mm	4.5 ± 3.0	10.1/0.3	-0.7 ± 1.4	1.9/−2.8	.01
Maxillo-mandibular relationships					
Convexity (A-NPo), mm	-0.7 ± 1.2	0.8/−3.4	0.8 ± 0.7	2.3/0	.03
Mandibular arc, °	3.8 ± 3.7	9.2/−3.7	-9.2 ± 21.1	5.5/−68.8	.56
Craniofacial relation					
FMA (MP-FH), °	-0.4 ± 2.3	3.3/−3.9	0.5 ± 3.6	8.3/−4.7	.09
Maxillary depth (FH-NA), °	0.3 ± 2.7	4.1/−4.5	0.8 ± 2.7	3.5/−6.8	.31
Facial axis (NaBa-PtGn), °	0.2 ± 1.3	2.2/−2.6	-0.7 ± 1.7	3.3/−3.2	.18
Facial angle (FH-NPo), °	1.1 ± 2.1	4.9/−1	-0.1 ± 2.7	2.7/−7.2	.18
Facial taper, °	-0.7 ± 1.0	1.4/−2.5	-0.5 ± 2.3	2.5/−4.7	.14
Deep skeletal structure					
Porion location, mm	-1.1 ± 2.5	2.8/−5.7	-2.0 ± 4.5	4.7/−9.1	.57
Cranial deflection, °	0.2 ± 1.7	3/−2.3	0.7 ± 3.0	4.4/−6.3	.52
Ramus position, °	-0.8 ± 2.5	2.9/−5.1	4.8 ± 33.9	62.5/−60	.43
Lower face height (ANS-Xi-Pm), °	-0.8 ± 1.9	2.4/−4.2	5.2 ± 24.9	49.3/−42	.50
Esthetic					
Lower lip to E-plane, mm	-2.7 ± 2.9	3.9/−6.9	0.9 ± 2.8	6.4/−4	.03

RESULTS

Paired *t*-test showed no statistical difference between the two measurements of the five selected cephalometric radiographs that were digitized for measuring cephalometric landmark identification and measurement errors ($P > .05$), which indicates that digitization of landmarks and cephalometric measurements are reliable. In the continuous arch group, cephalometric analysis and superimposition showed that the upper first molars moved forward significantly (4.5 ± 3 , $P < .05$) compared with the segmented arch group (-0.7 ± 1.4 , $P < .05$; Figures 2–4). Also, the upper incisors' protrusion to Apo showed a relatively increased forward position of the upper incisors in the continuous arch group as compared with the segmented arch group, but the difference was not statistically significant. The molar relationship has become more class II in the continuous arch group compared with the segmented arch group due to the forward movement of the upper molars (loss of anchorage). Also, the Frankfurt-Mandibular plane angle (FMA) showed a greater increase after canine retraction in the continuous arch group than in the segmented arch group, but the difference was not statistically significant.

cant. There was no other significant difference between the two groups.

DISCUSSION

Anchorage control has continuously been an area of concern in orthodontic clinical practice. A noncompliant anchorage control measure is always preferable over headgear. Although TADs have shown significant anchorage control in the literature, their risk of failure and complications, including loosening or fracture of the TADs, pain, and soft tissue inflammation, remain a concern for some clinicians.² Segmented arch mechanics have not received wide acceptance in orthodontic clinical practice, possibly because of their complexity and challenges facing the clinician in maintaining a continuous and reproducible force system. The use of TPA for anchorage control has been reported in the literature with the use of continuous arch mechanics.

However, comparing anchorage control using TPA between continuous and segmented arch mechanics has not been reported. The minimum anchorage loss when using the segmented arch mechanics in our study agrees with previous reports that showed

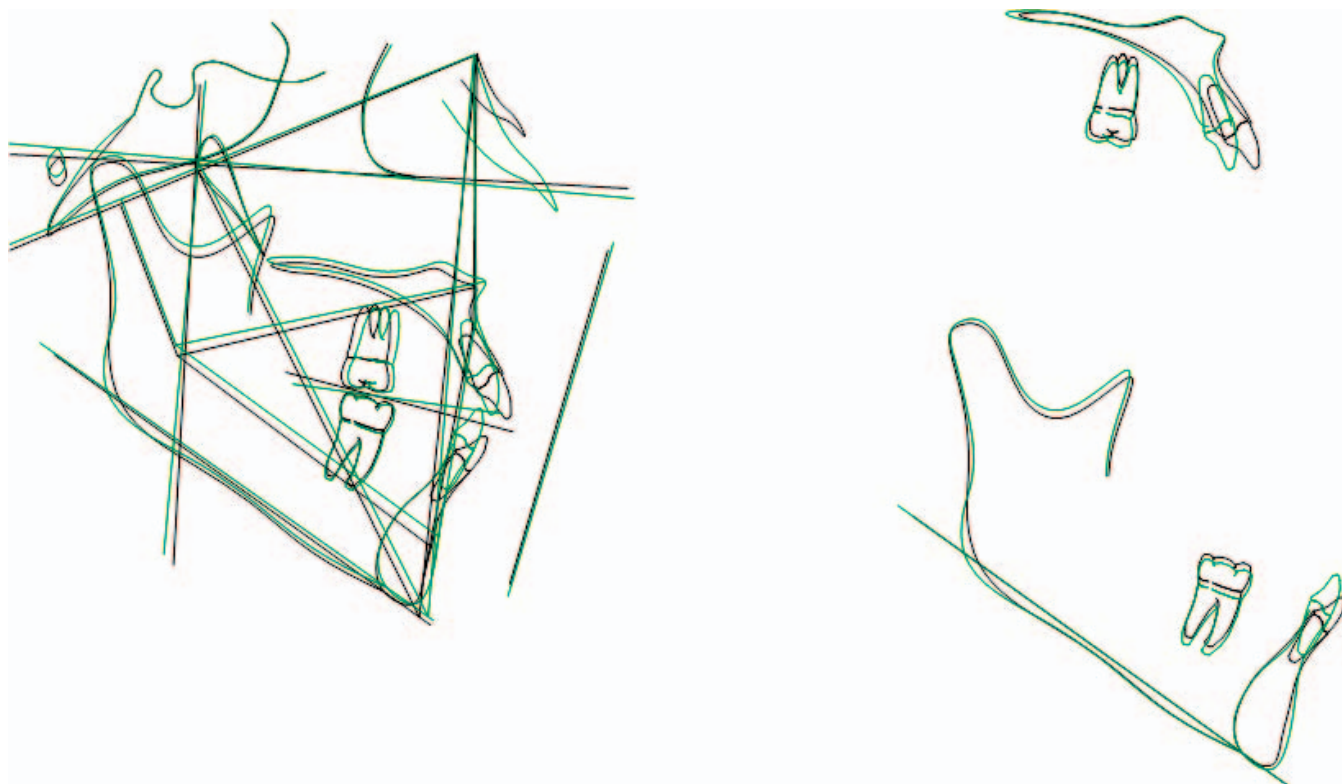


Figure 2. Cephalometric tracing superimposition of a case treated with segmented arch mechanics.

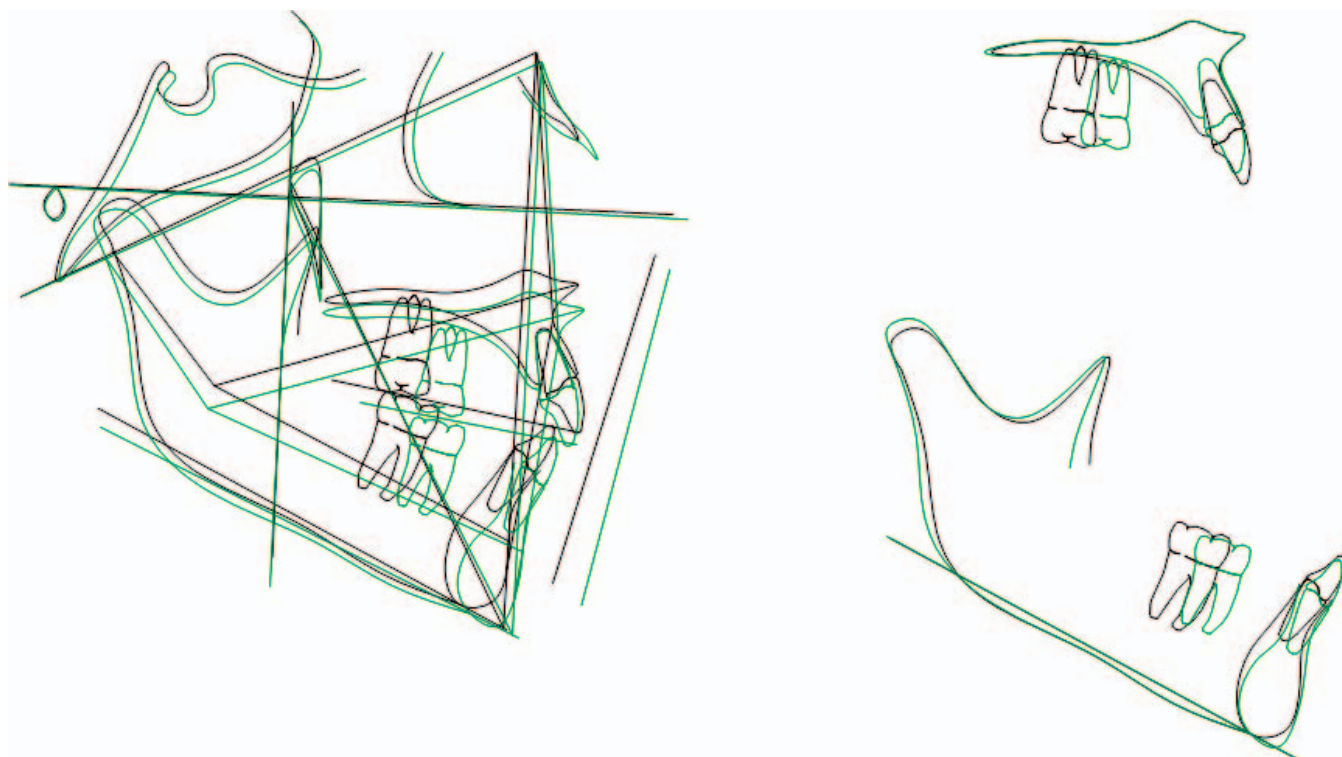


Figure 3. Cephalometric tracing superimposition of a case treated with continuous arch mechanics.

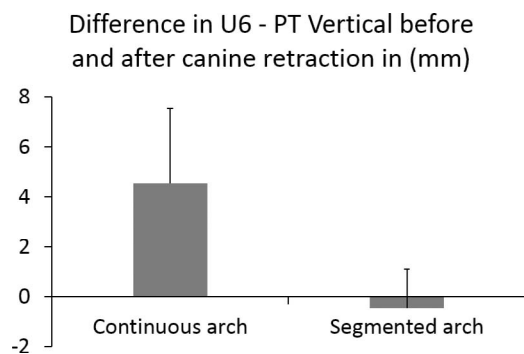


Figure 4. Graph showing anchorage loss in both segmented and continuous arch mechanics.

anchorage control using the beta bend in the retraction T-loop while using TPA mainly to prevent the rotation of upper molars.^{3,18} The enhanced control of the force system applied to the active units (teeth being moved) and the reactive units (anchorage teeth) and avoidance of the frictional element associated with the sliding mechanics can explain the minimum anchorage loss when using segmented arch mechanics.¹¹ Nonetheless, despite the maximum anchorage control shown in our study when retracting the upper canines with the segmented arch technique, other reports have shown greater anchorage conservation when an en masse vs two-step retraction approach has been used for maximum anchorage treatment.²⁸

There has been some perception in the literature about the efficiency of using TPA for anchorage control when using continuous arch mechanics. However, based on our results, which agree with a previous report,¹⁷ it can be suggested that TPA alone does not minimize anchorage loss when used with continuous arch mechanics. The perception is possibly due to the fact that different and unequal moments can be applied with TPA, as in cases of unilateral arch expansion.^{11,13} A buccally applied root torque to the upper molars was believed to produce a cortical anchorage by driving the roots of the upper molars into the rigid buccal plate of bone.^{17,23} The increased FMA after canine retraction in the continuous arch group confirms anchorage loss. When the upper molars move forward, there is always tendency for them to tip mesially, which leads to extrusion of their distal part and consequently backward rotation of the mandible—hence, increased FMA.

This study is a retrospective study with a small number of cases. Every effort was made to minimize adjustments and to follow the treatment protocol strictly, at least during the canine retraction stage, which is the area of concern of this study. More prospective controlled clinical trials may be needed to confirm these results with a larger sample size and

wide distribution of cases with respect to their facial forms and anchorage requirements.

CONCLUSION

- The use of a TPA when combined with segmented arch mechanics results in more anchorage control than when used with continuous arch sliding mechanics during upper canine retraction.

REFERENCES

1. Burstone CJ. Rationale of the segmented arch. *Am J Orthod.* 1962;48:805–822.
2. Dalessandri D, Salgarello S, Dalessandri M, et al. Determinants for success rates of temporary anchorage devices in orthodontics: a meta-analysis (n > 50). *Eur J Orthod.* 2014;36:303–313.
3. Burstone CJ. The segmented arch approach to space closure. *Am J Orthod.* 1982;82:361–378.
4. Mezomo M, de Lima ES, de Menezes LM, Weissheimer A, Allgayer S. Maxillary canine retraction with self-ligating and conventional brackets. *Angle Orthod.* 2011;81:292–297.
5. Oz AA, Arici N, Arici S. The clinical and laboratory effects of bracket type during canine distalization with sliding mechanics. *Angle Orthod.* 2011;82:326–332.
6. Burrow SJ. Canine retraction rate with self-ligating brackets vs conventional edgewise brackets. *Angle Orthod.* 2010;80:438–445.
7. Machibya FM, Bao X, Zhao L, Hu M. Treatment time, outcome, and anchorage loss comparisons of self-ligating and conventional brackets. *Angle Orthod.* 2013;83:280–285.
8. de Almeida MR, Herrero F, Fattal A, Davoodi AR, Nanda R, Uribe F. A comparative anchorage control study between conventional and self-ligating bracket systems using differential moments. *Angle Orthod.* 2013;83:937–942.
9. Moninia AC, Juniorb LG, Martinsc RP, Vianna AP. Canine retraction and anchorage loss: self-ligating versus conventional brackets in a randomized split-mouth study. *Angle Orthod.* 2014;84:846–852.
10. Kuhlberg AJ, Burstone CJ. T-loop position and anchorage control. *Am J Orthod Dentofacial Orthop.* 1997;112:12–18.
11. Braun S, Marcotte MR. Rationale of the segmented approach to orthodontic treatment. *Am J Orthod Dentofacial Orthop.* 1995;108:1–8.
12. Katona TR, Isikbay SC, Chen J. Effects of first- and second-order gable bends on the orthodontic load systems produced by T-loop archwires. *Angle Orthod.* 2014;84:350–357.
13. Burstone CJ, Koenig HA. Precision adjustment of the transpalatal lingual arch: computer arch form predetermination. *Am J Orthod.* 1981;79:115–134.
14. Gollner P, Bantleon HP, Ingervall B. Force delivery from a transpalatal arch for the correction of unilateral first molar cross-bite. *Eur J Orthod.* 1993;15:411–420.
15. Ingervall B, Honigl KD, Bantleon H. Moments and forces delivered by transpalatal arches for symmetrical first molar rotation. *Eur J Orthod.* 1996;18:131–139.
16. Ten Hoeve A. Palatal bar and lip bumper in nonextraction treatment. *J Clin Orthod.* 1985;19:272–291.
17. Gunduz E, Zachrisson BU, Honigl KD, Crismani AG, Bantleon HP. An improved transpalatal bar design. Part I. Comparison of moments and forces delivered by two bar designs for symmetrical molar derotation. *Angle Orthod.* 2003;73:239–243.

18. Dahlquist A, Gebauer U, Ingervall B. The effect of a transpalatal arch for the correction of first molar rotation. *Eur J Orthod*. 1996;18:257–267.
19. Ingervall B, Gollner P, Gebauer U, Fröhlich K. A clinical investigation of the correction of unilateral first molar crossbite with a transpalatal arch. *Am J Orthod Dentofacial Orthop*. 1995;107:418–425.
20. Kuhlberg AJ, Priebe D. Testing force systems and biomechanics—measured tooth movements from differential moment closing loops. *Angle Orthod*. 2003;73:270–280.
21. Zablocki HL, McNamara JA Jr, Franchi L, Baccetti T. Effect of the transpalatal arch during extraction treatment. *Am J Orthod Dentofacial Orthop*. 2008;133:852–860.
22. Bobak V, Christiansen RL, Hollister SJ, Kohn DH. Stress-related molar responses to the transpalatal arch: a finite element analysis. *Am J Orthod Dentofacial Orthop*. 1997;112:512–518.
23. Ingervall B, Gollner P, Gebauer U, Fröhlich K. A clinical investigation of the correction of unilateral first molar crossbite with a transpalatal arch. *Am J Orthod Dentofacial Orthop*. 1995;107:418–425.
24. Borsos G, Vokó Z, Gredes T, Kunert-Keil C, Vegh A. Tooth movement using palatal implant supported anchorage compared to conventional dental anchorage. *Ann Anat*. 2012;194:556–560.
25. Lee J, Miyazawa K, Tabuchi M, Sato T, Kawaguchi M, Goto S. Effectiveness of en-masse retraction using midpalatal miniscrews and a modified transpalatal arch: treatment duration and dentoskeletal changes. *Korean J Orthod*. 2014;44:88–95.
26. Wilmes B, Olthoff G, Drescher D. Comparison of skeletal and conventional anchorage methods in conjunction with pre-operative decompensation of a skeletal class III malocclusion. *J Orofac Orthop*. 2009;70:297–305.
27. Ricketts RM. New perspectives on orientation and their benefits to clinical orthodontics—part I. *Angle Orthod*. 1975;45:238–248.
28. Xu TM, Zhang X, Oh HS, Boyd RL, Korn EL, Baumrind S. Randomized clinical trial comparing control of maxillary anchorage with 2 retraction techniques. *Am J Orthod Dentofacial Orthop*. 2010;138:544. e1–9.