

Research Article

Assessment of Choroidal Morphology and Vasculature in Healthy Young Saudi Adults

Haya Maatuoq Al Farhan*, Lulwah Ahmed Al Shibel and Mohammed Abdulmaboud

Department of Optometry and Vision Sciences, King Saud University, Saudi Arabia

***Corresponding author:** Haya Maatuoq Al Farhan, Department of Optometry and Vision Sciences, College of Applied Medicine Sciences, King Saud University, P.O. Box 10219, Riyadh 11433, Saudi Arabia, Email: halfarhan@ksu.edu.sa

Received: February 14, 2014; **Accepted:** March 12, 2014; **Published:** March 21, 2014

Abstract

Purpose: The aim of this prospective study was to assess choroidal morphology and vasculature in healthy young Saudi adults by spectral-domain optical coherence tomography imaging with confocal scanning laser ophthalmoscopy (OCT-SLO).

Methods: Eyes with the most visible choroid-sclera junction in 110 consecutive healthy subjects (mean age = 30 ± 6.20 years; range = 20–40 years; 53 women) were imaged by one examiner using an Optos OCT-SLO system. Choroidal morphologic and vascular parameters were subjectively assessed by one experienced rater.

Results: All the eyes had normal foveal contour and no retinal or choroidal abnormalities. The choroid was thicker sub foveally than 750 μm nasally and temporally in all cases. Regression analysis indicated strong negative correlation between age and subfoveal choroidal thickness (SFCT) ($r = -0.81$; $P = 0.0001$) and weak positive correlation between refractive error and SFCT ($r = 0.10$; $P = 0.35$). SFCT was greater in the female subjects ($P = 0.04$, paired t-test).

Conclusion: The subfoveal region is the thickest part of the choroid in healthy Saudi adults aged 20–40 years and is thicker in women. SFCT decreases by 5.54 μm per year of age and 1.58 μm per diopter increase in myopia.

Keywords: Subfoveal choroidal thickness; Choriocapillaris; Optical coherence tomography; Refractive error; age; Gender

Abbreviations

OCT: Optical Coherence Tomography; SLO: Scanning Laser Ophthalmoscopy; CT: Choroidal Thickness; SFCT: Sub Foveal Choroidal Thickness; CVL: Choroidal Vessel Layer; CCT: Choriocapillaris Thickness; RPE: Retinal Pigment Epithelium

Introduction

The choroid is a vascular pigmented tissue that extends from the ora serrata to the optic nerve. It plays an important role in most of the ocular blood supply and oxygen and nutrition distribution to the outer retinal layers [1]. Any disturbance in choroidal blood flow may lead to photoreceptor dysfunction and death. Several reports have described choroidal morphology of normal American [2,3], Japanese [4], Chinese [5], and Danish [6] populations. Assessment of the choroid in normal eyes would provide clinically relevant information on the effects of factors such as age and refractive error as well pathophysiologic conditions such as glaucoma, diabetic retinopathy, and age-related macular degeneration [7].

Indocyanine green angiography allows visualization of choroidal vessels and blood flow below the retinal pigment epithelium (RPE) from the posterior pole to the periphery as well as the vortex veins [8,9]. Laser Doppler flowmetry is a noninvasive method for measuring hemodynamic parameters of the optic nerve head, iris, and subfoveal choroidal circulation [10,11]. However, these methods do not provide three-dimensional (3D) anatomic information on the RPE and choroid [2,12]. Recent reports have described examination

and measurement of choroidal thickness in normal and pathologic states by spectral-domain optical coherence tomography (OCT), despite the choroid's posterior location and presence of pigmented cells in the RPE that attenuate incident light [2,12]. The aim of this study was to assess choroidal morphology and vasculature in healthy young Saudi adults by spectral-domain OCT imaging with confocal scanning laser ophthalmoscopy (SLO).

Subjects and Methods

Study design

This prospective study was conducted at Elite Medical & Surgical Centre in Riyadh, Saudi Arabia between September and December 2013. It adhered to the tenets of the 2008 Declaration of Helsinki, and the study protocol was approved by the research ethics review board of the College of Applied Medicine Sciences of King Saud University. Written consent was obtained from each participant after the purpose of the study was explained.

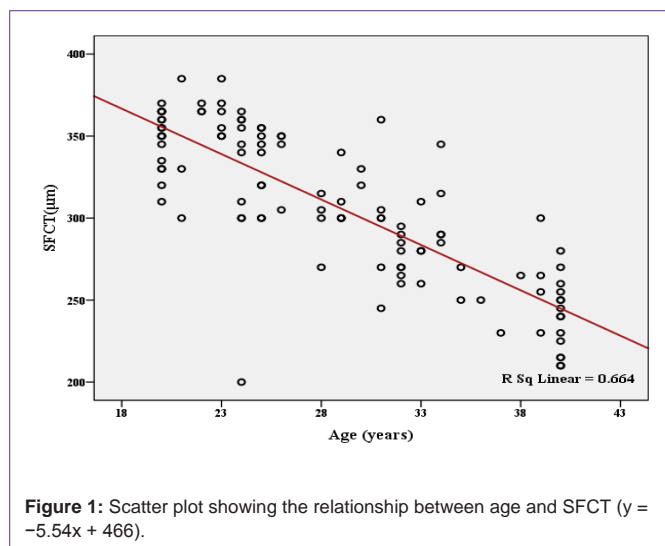
One hundred ten consecutive healthy adults (53 women) were recruited. The exclusion criteria were existing ocular disease (e.g., corneal anomalies, cataract, glaucoma, retinopathy, or retinitis pigmentosa), prior intraocular surgery, intraocular pressure of ≥ 21 mmHg, and myopia or hyperopia with spherical equivalent more than 6.00 diopters [3]. Those with systemic disease (e.g., diabetes mellitus or hypertension) and taking any medication were also excluded. Comprehensive examinations were conducted by using a slit lamp. Spherical and cylindrical refractions and intraocular pressure were

Table 1: Morphologic features of the choroid (N = 110) eyes.

Feature	%
Smooth convexity of choroid–sclera junction	77.37
Clear choroid–sclera junction	78.28
Maximum choroidal thickness subfoveally	100
Focal choroidal thinning	0.00
Even continuum of choroidal vessel size	96.63
Even distribution of large choroidal vessels in the nasotemporal plan	95.45

Table 2: Vascular parameters of the choroid (N = 110) eyes.

Parameter	750 μm temporally	Subfoveally	750 μm nasally
CT (μm)	290.50 \pm 45.45	306.59 \pm 46.61	282.09 \pm 45.64
Large CVL (μm)	247.86 \pm 43.70	258.22 \pm 44.09	242.59 \pm 43.77
Medium CVL/CCT ratio	42.81 \pm 13.24	48.36 \pm 12.78	39.5 \pm 13.21
Large CVL/CT ratio	0.05 \pm 0.85	0.05 \pm 0.84	0.05 \pm 0.86



determined by auto refractometry (Auto Kerato-Refracto-Tonometer TRK-1P; Topcon Corporation, Tokyo, Japan).

OCT-SLO procedure

The OCT-SLO system (Optos, Scotland, UK) used in the study is a noncontact, noninvasive device indicated for 3D imaging and measurement of posterior ocular structures; its axial and transverse resolutions are <10 and $20 \mu\text{m}$, respectively. It uses light generated by an infrared broadband superluminescent diode with a center wavelength of 830 nm . The interferometer combines the reflected light from the retina with the reflected light from a reference arm (mirror). A spectrometer with a linear charge-coupled device detects and measures the interference and sends the returned signal(s) to a computer that generates the OCT image.

For the study, the eye with the most visible choroid–sclera junction was selected in each subject [13]. The scan mode was 3D retinal topography, which collects a set of sequential B-scans and creates a 3D reconstructed image and topographic map of posterior ocular structures. Scanning was performed in a dark room by a single examiner. The patient's head and chin were fixed and the patient

was asked to fixate on a target for a few seconds without blinking. All images had an intensity of 6/10 or higher and were obtained as close to the fovea as possible to capture the thinnest part of the macula, thus avoiding minute differences in positioning and ensuring accurate assessment [13]. Finally, one experienced rater subjectively evaluated the resultant images.

Statistical analysis

Demographic data were analyzed by using Microsoft Excel 2007. Statistical software (SPSS 20; IBM Corp., Armonk, NY, USA) was used for statistical analyses. The paired t-test was used for age and gender comparisons. Correlation coefficient and regression analysis were used to investigate the relationship of choroidal morphology with age and refractive error. The level of statistical significance was set at 0.05.

Results

The mean age of the subjects was 30 ± 6.20 years and age range was 20–40 years. Their mean spherical equivalent was -0.50 ± 1.25 diopters and their spherical equivalent ranges for myopia and hyperopia were plano to -5.50 diopters and plano to $+2.00$ diopters, respectively. All the imaged eyes show normal foveal contour and no retinal or choroidal abnormalities. The choroidal morphologic features are summarized in Table 1.

The choroid was thicker in the subfoveal region than in the 750- μm nasal and temporal regions. Table 2 summarizes the results of the vascular assessment of the choroid. Table 2.

To investigate the effect of age on subfoveal choroidal thickness (SFCT), the subjects were divided into two age groups. The paired t-test showed a significant difference between the 20–30 ($n = 63$) and the 31–40 ($n = 47$) age groups (335.24 ± 31.67 and $266.11 \pm 32.12 \mu\text{m}$, respectively; $P < 0.001$). The regression analysis indicated strong negative correlation between age and SFCT ($r = -0.81$; $P < 0.0001$) (Figure 1). Further, weak positive correlation was found between refractive error and SFCT ($r = 0.10$; $P < 0.35$) (Figure 2).

SFCT was significantly greater in the female subjects than in the male subjects (314.72 ± 47.73 vs. $295.36 \pm 43.49 \mu\text{m}$; $P = 0.04$). The

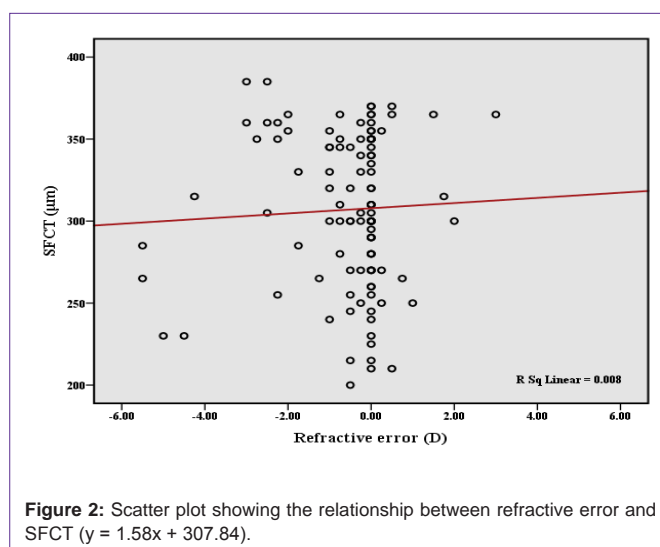


Table 3: Comparison of choroidal morphologic features between the present and the Branchini [3]. Studies.

Feature	Branchini et al. (%)	Present study (%)
Convex choroid-sclera junction	100	77.37
Clear choroid-sclera junction	92.8	78.28
Focal choroidal thinning	0	0
Even continuum of choroidal vessel size	97.6	96.63
Even distribution of large choroidal vessels in the nasotemporal plan	98.8	95.45

Table 4: Comparison of choroidal vascular parameters between the present and the Branchini [3] studies

Parameter	Branchini et al			Present study		
	750 μ m temporally	Subfoveally	750 μ m nasally	750 μ m temporally	Subfoveally	750 μ m nasally
CT (μ m)	255.00 \pm 75.70	256.8 \pm 75.80	243.20 \pm 69.30	290.50 \pm 45.45	306.59 \pm 46.61	282.09 \pm 45.64
Large CVL (μ m)	203.70 \pm 60.30	204.30 \pm 65.90	198.60 \pm 62.50	247.86 \pm 43.70	258.22 \pm 44.09	242.59 \pm 43.77
Medium CVL/CCT ratio	51.70 \pm 23.10	52.90 \pm 20.60	44.70 \pm 19.70	42.81 \pm 13.24	48.36 \pm 12.78	39.50 \pm 13.21

Table 5: Comparison of SFCT according to age groups between the present and the Ding [5] studies.

Age groups	Ding 2011 [5]	The present study 2013
	SFCT(μ m)	
20 – 30	293.51 \pm 66.87	335.24 \pm 31.67
31 – 40	287.87 \pm 72.80	266.11 \pm 32.12
Sample size	210	110

age difference between the male and the female subjects was also significant (29.94 \pm 6.86 and 27.70 \pm 6.70 years, respectively; $P = 0.03$).

Discussion

In this study, OCT images showed that more than 70% of the healthy eyes had a clear choroid-sclera junction. The choroid was the thickest subfoveally in all the eyes. No choroidal thinning was observed and the continuum of choroidal vessel size was even in most eyes (96.63%). The large choroidal vessels showed an even nasotemporal distribution in 95.45% of the eyes. All these features indicate that healthy Saudi adults aged 20–40 years have normal choroidal morphology and vasculature.

Our findings of choroidal morphology are similar to those of Branchini [3] (Table 3). The lesser convexity and clarity of the choroid-sclera junction in the present study might be explained by the fact that the assessments were performed subjectively by one rater. In the Branchini et al. study, two independent raters conducted the evaluations and a third acted as a mediator in case of disagreement. Further, different instruments were used in these studies [12].

With regard to choroidal vasculature (Table 4), the Branchini [3] findings are lower than our results, probably because of the subjective measurement and different age range in the present study. For instance, the mean age (range) of the present subjects was 30 \pm 6.20 (20–40) years, whereas the mean age (range) in the Branchini, sample was 51.60 \pm 21.02 (23–89) years. Further, the data of 42 subjects were pooled in the earlier study.

Considering age, SFCT differed slightly in this study compared

with the Ding [5] study despite the same age grouping (Table 5). This could be explained by differences in ethnicity and instruments between the studies [12].

Margolis [12] reported slight negative correlation between SFCT and age ($r = -0.42$; $P = 0.001$) and that SFCT decreases by 1.56 μ m for each year of age. However, strong negative correlation was found in the present study ($r = -0.81$; $P = 0.0001$), and regression analysis showed that SCFT decreases by 5.54 μ m per year of age. These differences might be attributable to the techniques used to assess SFCT [7]. In case of refractive error, Ding [5] reported that SFCT is positively correlated with refractive error ($r = 0.297$; $P < 0.05$) and decreases by 10.87 μ m for each diopter increase in myopia in subjects younger than 60 years. On the other hand, we found a very weak positive correlation ($r = 0.10$; $P = 0.35$) and that SFCT decreases by 1.58 μ m for each diopter increase in myopia in subjects younger than 40 years. This discrepancy might be explained by the mean age of the samples. Previous studies have confirmed that SFCT decreases with aging especially beyond 60 years [3,14,15]. Furthermore, Ding [5] reported that SFCT is greater in men than in women, but our study showed that SFCT of women is slightly greater, possibly because of the significant age difference between the male and the female subjects ($P = 0.03$).

Conclusion

The subfoveal region is the thickest part of the choroid in healthy young Saudi adults. SFCT decreases by 5.54 μ m annually and 1.58 μ m for each diopter increase in myopia. Women have thicker choroid than men. In Saudi Arabia, the age range of 20 to 40 years includes a large portion of the population. Therefore, the results could be used as a reference for studies of the pathogenesis of choroidal diseases affecting this age group.

References

- Ryan SJ. Retina. 4th edn, Philadelphia, PA: Elsevier Mosby. 2006; 33-34.
- Manjunath V, Taha M, Fujimoto JG, Duker JS. Choroidal thickness in normal eyes measured using Cirrus HD optical coherence tomography. Am J Ophthalmol. 2010; 150: 325-329.
- Branchini L, Regatieri CV, Flores-Moreno I, Baumann B, Fujimoto JG, Duker JS. Reproducibility of choroidal thickness measurements across three spectral domain optical coherence tomography systems. Ophthalmology. 2012; 119: 119-123.
- Ikuno Y, Kawaguchi K, Nouchi T, Yasuno Y. Choroidal thickness in healthy Japanese subjects. Invest Ophthalmol Vis Sci. 2010; 51: 2173-2176.
- Ding X, Li J, Zeng J, Ma W, Liu R, Li T. et al. Choroidal thickness in healthy Chinese subjects. Invest Ophthalmol Vis Sci. 2011; 52: 9555-9560.
- Li XQ, Larsen M, Munch IC. Subfoveal choroidal thickness in relation to sex and axial length in 93 Danish university students. Invest Ophthalmol Vis Sci. 2011; 52: 8438-8441.
- McCourt EA, Cadena BC, Barnett CJ, Ciardella AP, Mandava N, Kahook MY. Measurement of subfoveal choroidal thickness using spectral domain optical coherence tomography. Ophthalmic Surg Lasers Imaging. 2010; 41: S28-S33.
- Rosen RB, Hathaway M, Rogers J, Pedro J, Garcia P, Dobre GM, et al. Simultaneous OCT/SLO/ICG imaging. Invest Ophthalmol Vis Sci. 2009; 50: 851-860.
- Yannuzzi LA. Indocyanine green angiography: a perspective on use in the clinical setting. Am J Ophthalmol. 2011; 151: 745-751.
- Pemp B, Schmetterer L. Ocular blood flow in diabetes and age-related

- macular degeneration. *Can J Ophthalmol*. 2008; 43: 295-301.
11. Falsini B, Anselmi GM, Marangoni D, D'Esposito F, Fadda A, Di Renzo A, et al. Subfoveal choroidal blood flow and central retinal function in retinitis pigmentosa. *Invest Ophthalmol Vis Sci*. 2011; 52: 1064-1069.
 12. Margolis R, Spaide RF. A pilot study of enhanced depth imaging optical coherence tomography of the choroid in normal eyes. *Am J Ophthalmol*. 2009; 147: 811-815.
 13. Branchini LA, Adhi M, Regatieri CV, Nandakumar N, Liu JJ, Laver N. et al. Analysis of choroidal morphologic features and vasculature in healthy eyes using spectral-domain optical coherence tomography. *Ophthalmology*. 2013; 120: 1901-1908.
 14. Regatieri CV, Branchini L, Fujimoto JG, Duker JS. Choroidal imaging using spectral-domain optical coherence tomography. *Retina*. 2012; 32: 865-876.
 15. Fujiwara T, Imamura Y, Margolis R, Slakter JS, Spaide RF. Enhanced depth imaging optical coherence tomography of the choroid in highly myopic eyes. *Am J Ophthalmol*. 2009; 148: 445-450.