© The McGraw–Hill Companies, 2001

Skeletal System: Introduction and the Axial Skeleton

6

Organization of the Skeletal System 132
Functions of the Skeletal System 134
Bone Structure 135
Bone Tissue 138
Bone Growth 140
Developmental Exposition: The Axial Skeleton 141
Skull 144
Vertebral Column 158
Rib Cage 164

CLINICAL CONSIDERATIONS 165

Clinical Case Study Answer 168
Important Clinical Terminology 169
Chapter Summary 170
Review Activities 170

Clinical Case Study

A 68-year-old man visited his family doctor for his first physical examination in 30 years. Upon sensing a disgruntled patient, the doctor gently tried to determine the reason. In response to the doctor's inquiry, the patient blurted out, "The nurse who measured my height is incompetent! I know for a fact I used to be six feet even when I was in the Navy, but she tells me I'm 5′10″!" The doctor then performed the measurement himself, noting that although the patient's posture was excellent, he was indeed 5′10″, just as the nurse had said. He explained to the patient that the spine contains some nonbony tissue, which shrivels up a bit over the years. The patient interrupted, stating indignantly that he knew anatomic terms and principles and would like a detailed explanation. How would you explain the anatomy of the vertebral column and the changes it undergoes during the aging process?

Hints: The patient's normal posture and the fact that he had no complaints of pain indicated good health for his age. Examine figure 6.32 and carefully read the accompanying caption. Also see the Clinical Considerations section at the end of the chapter.

FIGURE: Decreased height, postural changes, and loss of bone density are just a few of the age-related alterations that may afflict the skeleton.

ORGANIZATION OF THE SKELETAL SYSTEM

The axial and appendicular components of the skeletal system of an adult human consist of 206 individual bones arranged to form a strong, flexible body framework.

Objective 1 Describe the division of the skeletal system into axial and appendicular components.

The adult skeletal system consists of approximately 206 bones. The exact number of bones differs from person to person depending on age and genetic factors. At birth, the skeleton consists of about 270 bones. As further bone development (ossification) occurs during infancy, the number increases. During adolescence, however, the number of bones decreases, as separate bones gradually fuse. Each bone is actually an organ that plays a part in the total functioning of the skeletal system. The science concerned with the study of bones is called *osteology*.

Some adults have extra bones within the sutures (joints) of the skull called **sutural** (*wormian*) **bones.** Additional bones may develop in tendons in response to stress as the tendons repeatedly move across a joint. Bones formed this way are called **sesamoid** (*ses'ă-moid*) **bones.** Sesamoid bones, like the sutural bones, vary in number. The patellae ("kneecaps") are two sesamoid bones all people have.

For convenience of study, the skeleton is divided into *axial* and *appendicular portions*, as summarized in table 6.1 and shown in figure 6.1. The **axial skeleton** consists of the bones that form the axis of the body and support and protect the organs of the head, neck, and trunk. The components of the axial skeleton are as follows:

1. **Skull.** The skull consists of two sets of bones: the cranial bones that form the cranium, or braincase, and the facial bones that support the eyes and nose and form the bony framework of the oral cavity.
2. **Auditory ossicles.** Three auditory ossicles ("ear bones") are present in the middle-ear chamber of each ear and serve to transmit sound impulses.
3. **Hyoid bone.** The hyoid bone is located above the larynx ("voice box") and below the mandible ("jawbone"). It supports the tongue and assists in swallowing.
4. **Vertebral column.** The vertebral column ("backbone") consists of 26 individual bones separated by cartilaginous intervertebral discs. In the pelvic region, several vertebrae

wormian bone: from Ole Worm, Danish physician, 1588–1654

sesamoid: Gk. *sesamon*, like a sesame seed

TABLE 6.1 Bones of the Adult Skeleton

Axial Skeleton

Skull—22 Bones

14 Facial Bones
maxilla (2)
palatine (2)
zygomatic (2)
lacrimal (2)
nasal (2)
vomer (1)
inferior nasal concha (2)
mandible (1)

8 Cranial Bones
frontal (1)
parietal (2)
occipital (1)
temporal (2)
sphenoid (1)
ethmoid (1)

Auditory Ossicles—6 Bones
malleus (2)
incus (2)
stapes (2)

Hyoid—1 bone

Vertebral Column—26 Bones
cervical vertebra (7)
thoracic vertebra (12)
lumbar vertebra (5)
sacrum (1) (4 or 5 fused bones)
coccyx (1) (3–5 fused bones)

Rib Cage—25 Bones
rib (24)
sternum (1)

Appendicular Skeleton

Pectoral Girdle—5 Bones
sternum* (1)
scapula (2)
clavicle (2)

Upper Extremities—60 Bones
humerus (2)
radius (2)
ulna (2)
carpal bones (16)
metacarpal bones (10)
phalanges (28)

Pelvic Girdle—3 Bones
sacrum* (1)
os coxae (2) (each contains 3 fused bones)

Lower Extremities—60 Bones
femur (2)
tibia (2)
fibula (2)
patella (2)
tarsal bones (14)
metatarsal bones (10)
phalanges (28)

*Although the sternum and sacrum are bones of the axial skeleton, technically speaking they are also considered bones of the pectoral and pelvic girdles, respectively.

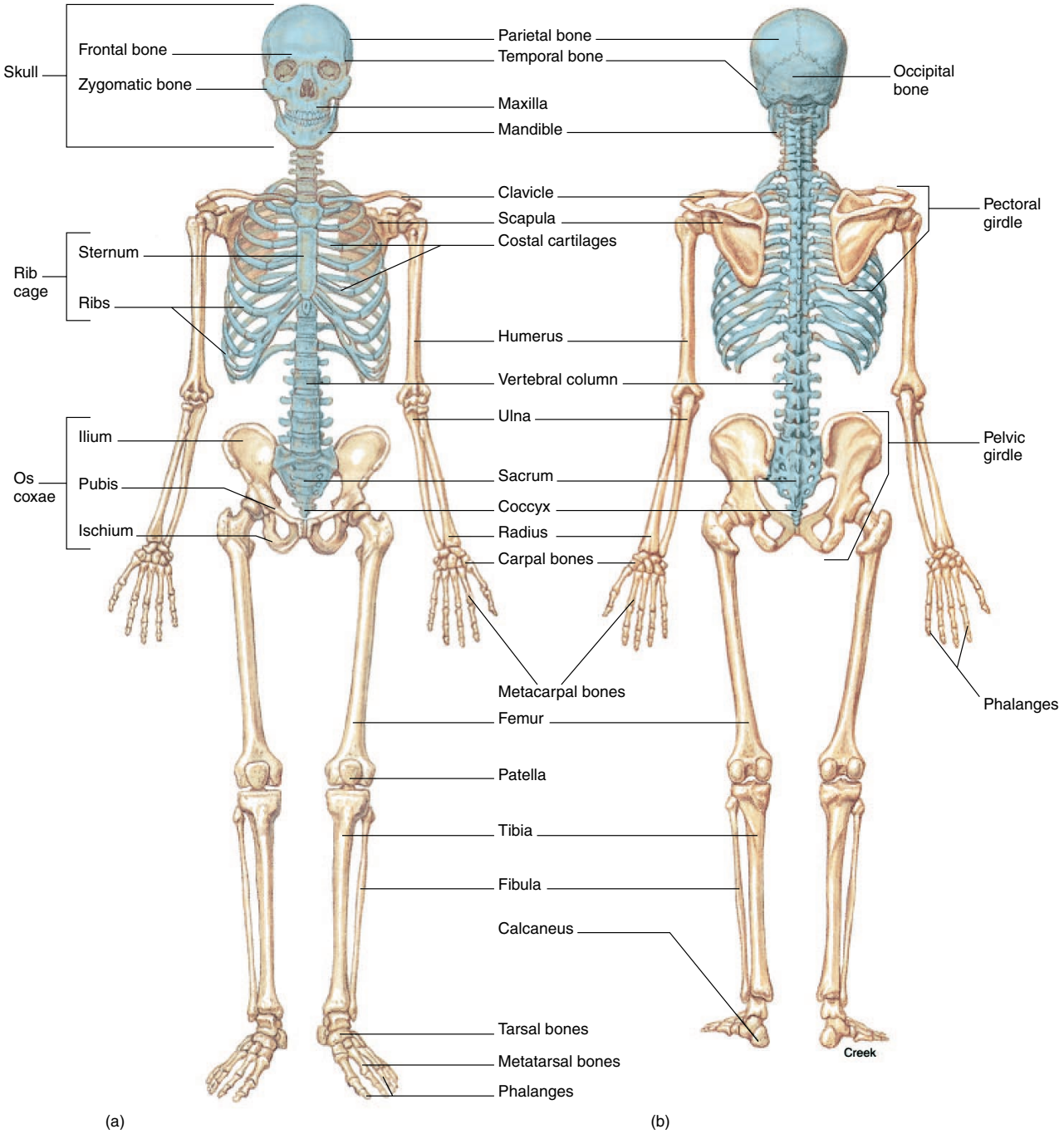

FIGURE 6.1 The human skeleton. (*a*) An anterior view and (*b*) a posterior view. The axial portion is colored light blue.

are fused to form the *sacrum*, which is the attachment portion of the pelvic girdle. A few terminal vertebrae are fused to form the *coccyx* ("tailbone").

5. **Rib cage.** The rib cage forms the bony and cartilaginous framework of the thorax. It articulates posteriorly with the thoracic vertebrae and includes the 12 pairs of *ribs*, the flattened *sternum*, and the *costal cartilages* that connect the ribs to the sternum.

The **appendicular** (*ap''en-dik'yoo-lar*) **skeleton** is composed of the bones of the upper and lower extremities and the bony girdles that anchor the appendages to the axial skeleton. The components of the appendicular skeleton are as follows:

1. **Pectoral girdle.** The paired *scapulae* ("shoulder blades") and *clavicles* ("collarbones") are the appendicular components of the pectoral girdle, and the *sternum* ("breastbone") is the axial component. The primary function of the pectoral girdle is to provide attachment for the muscles that move the brachium (arm) and antebrachium (forearm).
2. **Upper extremities.** Each upper extremity contains a proximal *humerus* within the brachium, an *ulna* and *radius* within the antebrachium, the *carpal bones*, the *metacarpal bones*, and the *phalanges* ("finger bones") of the hand.
3. **Pelvic girdle.** The two *ossa coxae* ("hipbones") are the appendicular components of the pelvic girdle, and the sacrum is the axial component. The ossae coxae are united anteriorly by the *symphysis* (*sim'fĭ-sis*) *pubis* and posteriorly by the sacrum. The pelvic girdle supports the weight of the body through the vertebral column and protects the viscera within the pelvic cavity.
4. **Lower extremities.** Each lower extremity contains a proximal *femur* ("thighbone") within the thigh, a *tibia* ("shinbone") and *fibula* within the leg, the *tarsal bones*, the *metatarsal bones*, and the *phalanges* ("toe bones") of the foot. In addition, the *patella* (*pă-tel'ă;* "kneecap") is located on the anterior surface of the knee joint, between the thigh and leg.

Knowledge Check

1. List the bones of the body that you can palpate. Indicate which are bones of the axial skeleton and which are bones of the appendicular skeleton.
2. What are sesamoid bones and where are they found?
3. Describe the locations and functions of the pectoral and pelvic girdles.

ossicle: L. *ossiculum*, little bone

FUNCTIONS OF THE SKELETAL SYSTEM

The bones of the skeleton perform the mechanical functions of support, protection, and leverage for body movement and the metabolic functions of hemopoiesis and storage of fat and minerals.

Objective 2 Discuss the principal functions of the skeletal system and identify the body systems served by these functions.

The strength of bone comes from its inorganic components, of such durability that they resist decomposition even after death. Much of what we know of prehistoric animals, including humans, has been determined from preserved skeletal remains. When we think of bone, we frequently think of a hard, dry structure. In fact, the term *skeleton* comes from a Greek word meaning "dried up." Living bone, however, is not inert material; it is dynamic and adaptable. It performs many body functions, including support, protection, leverage for body movement, hemopoiesis in the red bone marrow (fig. 6.2), fat storage in the medullary cavity, and mineral storage.

1. **Support.** The skeleton forms a rigid framework to which the softer tissues and organs of the body are attached. It is of interest that the skeleton's 206 bones support a mass of muscles and organs that may weigh 5 times as much as the bones themselves.
2. **Protection.** The skull and vertebral column enclose the brain and spinal cord; the rib cage protects the heart, lungs, great vessels, liver, and spleen; and the pelvic girdle supports and protects the pelvic viscera. Even the sites where blood cells are produced are protected within the spongy bone tissue of certain bones.
3. **Body movement.** Bones serve as anchoring attachments for most skeletal muscles. In this capacity, the bones act as levers (with the joints functioning as pivots) when muscles contract and cause body movement.
4. **Hemopoiesis.** The process of blood cell formation is called hemopoiesis (*hem''ŏ-poi-e'sis*). It takes place in tissue called *red bone marrow* located internally in some bones (fig. 6.2). In an infant, the spleen and liver produce red blood cells, but as the bones mature, the bone marrow takes over this formidable task. It is estimated that an average of 2.5 million red blood cells are produced every second by the red bone marrow to replace those that are worn out and destroyed by the liver.
5. **Fat storage.** Lipid is stored in the adipose tissue within the medullary cavity of certain bones. The adipose tissue and its lipid content are known as *yellow bone marrow* (fig. 6.2).
6. **Mineral storage.** The inorganic matrix of bone is composed primarily of the minerals calcium and phosphorus. These

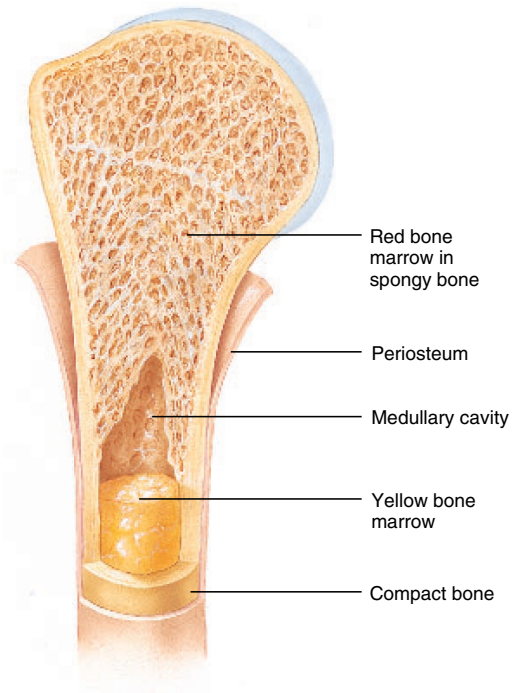

FIGURE 6.2 Hemopoiesis is the process by which blood cells are formed. In an adult, blood cells are formed in the red bone marrow.

minerals which account for approximately two-thirds of the weight of bone, give bone its firmness and strength. About 95% of the calcium and 90% of the phosphorus within the body are deposited in the bones and teeth. Although the concentration of these inorganic salts within the blood is kept within narrow limits, both are essential for other body functions. Calcium is necessary for muscle contraction, blood clotting, and the movement of ions and nutrients across cell membranes. Phosphorus is required for the activities of the nucleic acids DNA and RNA, as well as for ATP utilization. If mineral salts are not present in the diet in sufficient amounts, they may be withdrawn from the bones until they are replenished through proper nutrition. In addition to calcium and phosphorus, lesser amounts of magnesium, sodium, fluorine, and strontium are stored in bone tissue.

Vitamin D assists in the absorption of calcium and phosphorus from the small intestine into the blood. As bones develop in a child, it is extremely important that the child's diet contain an adequate amount of these two minerals and vitamin D. If the diet is deficient in these essentials, the blood level falls below that necessary for calcification, and a condition known as *rickets* develops (see fig. 5.11). Rickets is characterized by soft bones that may result in bowlegs and malformation of the head, chest, and pelvic girdle.

In summary, the skeletal system is not an isolated body system. It is associated with the muscle system in storing calcium needed for muscular contraction and providing attachments for muscles as they span the movable joints. The skeletal system serves the circulatory system by producing blood cells in protected sites. Directly or indirectly, the skeletal system supports and protects all of the systems of the body.

Knowledge Check

4. List the functions of the skeletal system.
5. Discuss two ways in which the skeletal system serves the circulatory system in the production of blood. What are two ways in which it serves the muscular system?

BONE STRUCTURE

Each bone has a characteristic shape and diagnostic surface features that indicate its functional relationship to other bones, muscles, and to the body structure as a whole.

Objective 3 Classify bones according to their shapes and give an example of each type.

Objective 4 Describe the various markings on the surfaces of bones.

Objective 5 Describe the gross features of a typical long bone and list the functions of each surface feature.

The shape and surface features of each bone indicate its functional role in the skeleton (table 6.2). Bones that are long, for example, provide body support and function as levers during body movement. Bones that support the body are massive and have large articular surfaces and processes for muscle attachment. Roughened areas on these bones may serve for the attachment of ligaments, tendons, or muscles. A flattened surface provides an attachment site for a large muscle or may provide protection. Grooves around an articular end of a bone indicate where a tendon or nerve passes, and openings through a bone permit the passage of nerves or blood vessels.

Shapes of Bones

The bones of the skeleton are grouped on the basis of shape into four principal categories: *long bones*, *short bones*, *flat bones*, and *irregular bones* (fig. 6.3).

1. **Long bones.** Long bones are longer than they are wide and function as levers. Most of the bones of the upper and lower extremities are of this type (e.g., the humerus, radius,

TABLE 6.2 Surface Features of Bone

Structure	Description and Example
Articulating Surfaces	
condyle (*kon'dil*)	A large, rounded articulating knob (the occipital condyle of the occipital bone)
facet	A flattened or shallow articulating surface (the costal facet of a thoracic vertebra)
head	A prominent, rounded articulating end of a bone (the head of the femur)
Depressions and Openings	
alveolus (*al-ve'ŏ-lus*)	A deep pit or socket (the dental alveoli [tooth sockets] in the maxilla and mandible)
fissure	A narrow, slitlike opening (the superior orbital fissure of the sphenoid bone)
foramen (*fŏ-ra'men*—plural, *foramina*)	A rounded opening through a bone (the foramen magnum of the occipital bone)
fossa (*fos'ă*)	A flattened or shallow surface (the mandibular fossa of the temporal bone)
sinus	A cavity or hollow space in a bone (the frontal sinus of the frontal bone)
sulcus	A groove that accommodates a vessel, nerve, or tendon (the intertubercular sulcus of the humerus)
Nonarticulating Prominences	
crest	A narrow, ridgelike projection (the iliac crest of the os coxae)
epicondyle	A projection adjacent to a condyle (the medial epicondyle of the femur)
process	Any marked bony prominence (the mastoid process of the temporal bone)
ramus	A flattened angular part of a bone (the ramus of the mandible)
spine	A sharp, slender process (the spine of the scapula)
trochanter	A massive process found only on the femur (the greater trochanter of the femur)
tubercle (*too'ber-k'l*)	A small, rounded process (the greater tubercle of the humerus)
tuberosity	A large, roughened process (the radial tuberosity of the radius)

ulna, metacarpal bones, femur, tibia, fibula, metatarsal bones, and phalanges).

2. **Short bones.** Short bones are somewhat cube-shaped and are found in the wrist and ankle where they transfer forces of movement.
3. **Flat bones.** Flat bones have a broad surface for muscle attachment or protection of underlying organs (e.g., the cranial bones, ribs, and bones of the shoulder girdle).

facet: Fr. *facette*, little face
trochanter: Gk. *trochanter*, runner
tuberosity: L. *tuberosus*, lump

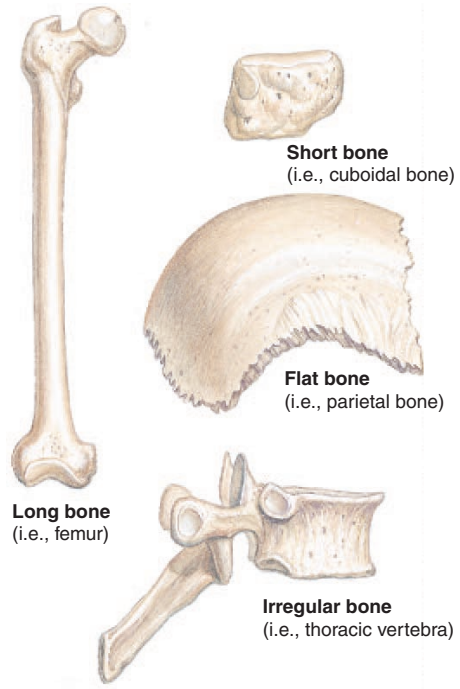

FIGURE 6.3 Examples of bone types, as classified by shape.

4. **Irregular bones.** Irregular bones have varied shapes and many surface features for muscle attachment or articulation (e.g., the vertebrae and certain bones of the skull).

Bone tissue is organized as *compact* (*dense*) *bone* or *spongy* (*cancellous*) *bone*, and most bones have both types. Compact bone is hard and dense, and is the protective exterior portion of all bones. The spongy bone, when it occurs, is deep to the compact bone and is quite porous. The microscopic structure of spongy and compact bone will be considered shortly.

In a flat bone of the skull, the spongy bone is sandwiched between the compact bone and is called a *diploe* (*dip'lo-e*) (fig. 6.4). Because of this protective layering of bone tissue, a blow to the head may fracture the outer compact bone layer without harming the inner compact bone layer and the brain.

Structure of a Typical Long Bone

The long bones of the skeleton have a descriptive terminology all their own. In a long bone from an appendage, the bone **shaft,** or **diaphysis** (*di-af'ĭ-sis*), consists of a cylinder of compact bone surrounding a central cavity called the **medullary** (*med'yoo-lar-e*) **cavity** (fig. 6.5). The medullary cavity is lined with a thin layer

diploe: Gk. *diplous*, double
diaphysis: Gk. *dia*, throughout; *physis*, growth

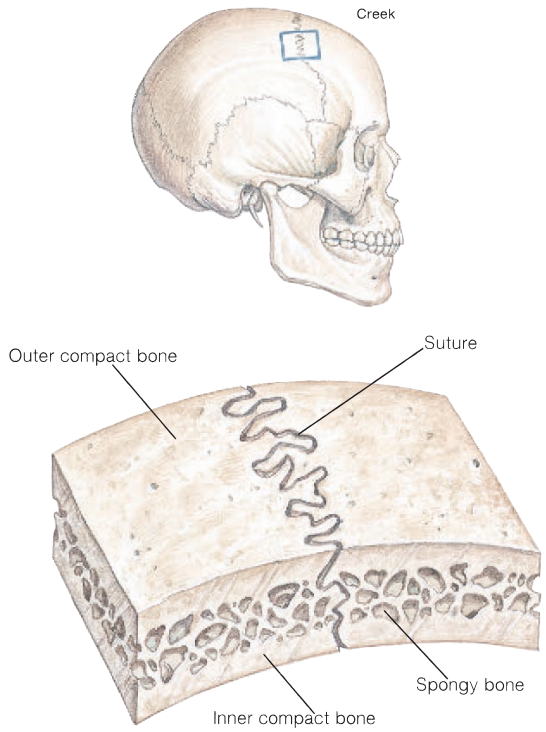

FIGURE 6.4 A section through the skull showing diploe. Diploe is a layer of spongy bone sandwiched between two surface layers of compact bone. It is extremely strong yet light in weight.

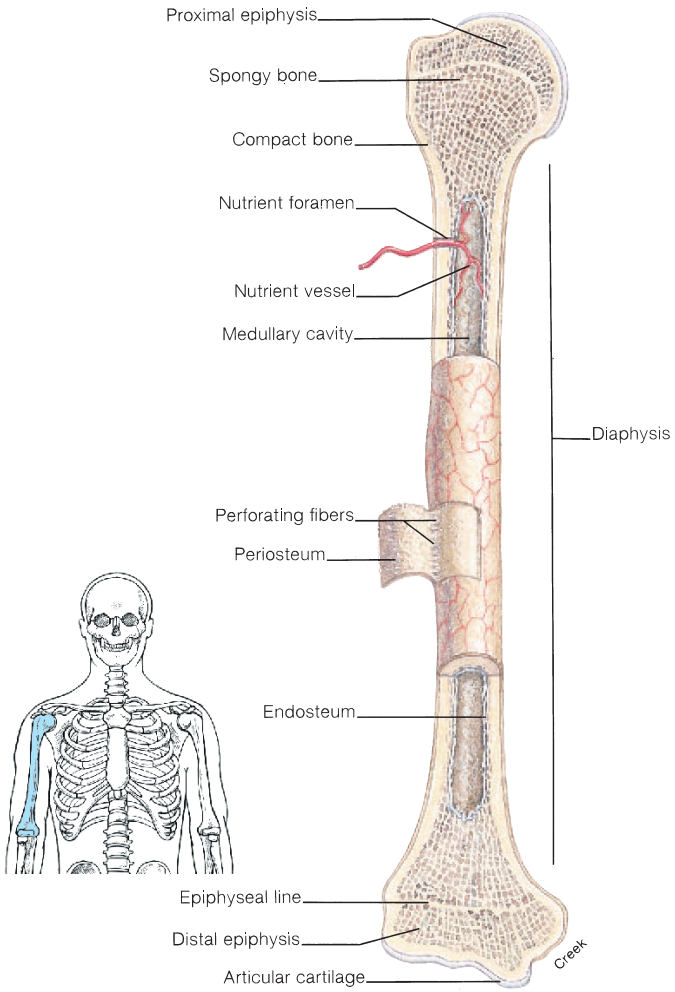

FIGURE 6.5 A diagram of a long bone (the humerus) shown in a partial longitudinal section.

of connective tissue called the **endosteum** (*en-dos′te-um*). In an adult, the cavity contains **yellow bone marrow,** so named because it contains large amounts of yellow fat. On each end of the diaphysis is an **epiphysis** (*ĕ-pif′ĕ-sis*), consisting of spongy bone surrounded by a layer of compact bone. **Red bone marrow** is found within the porous chambers of spongy bone. In an adult, hemopoiesis (the production of blood cells; see chapter 16) occurs in the red bone marrow, especially that of the sternum, vertebrae, portions of the ossa coxae, and the proximal epiphyses of the femora and humeri. **Articular cartilage,** which is composed of thin hyaline cartilage, caps each epiphysis and facilitates joint movement. Along the diaphysis are **nutrient foramina**—small openings into the bone that allow nutrient vessels to pass into the bone for nourishment of the living tissue.

Between the diaphysis and epiphysis is a cartilaginous **epiphyseal** (*ep″ĭ-fiz′e-al*) **plate**—a region of mitotic activity that is responsible for *linear bone growth*. As bone growth is completed, an **epiphyseal line** replaces the plate and final ossification occurs between the epiphysis and the diaphysis. A **periosteum** (*per″e-os′te-um*) of dense regular connective tissue covers the surface of the bone, except over the articular cartilage. This highly vascular layer serves as a place for a tendon-muscle attachment and is responsible for *appositional bone growth* (increase in width). The periosteum is secured to the bone by **perforating** (Sharpey's) **fibers** (fig. 6.5), composed of bundles of collagenous fibers.

Fracture of a long bone in a young person may be especially serious if it damages an epiphyseal plate. If such an injury goes untreated, or is not treated properly, longitudinal growth of the bone may be arrested or slowed, resulting in permanent shortening of the affected limb.

epiphysis: Gk. *epi*, upon; *physis*, growth
periosteum: Gk. *peri*, around; *osteon*, bone

Sharpey's fibers: from William Sharpey, Scottish physiologist and histologist, 1802–80

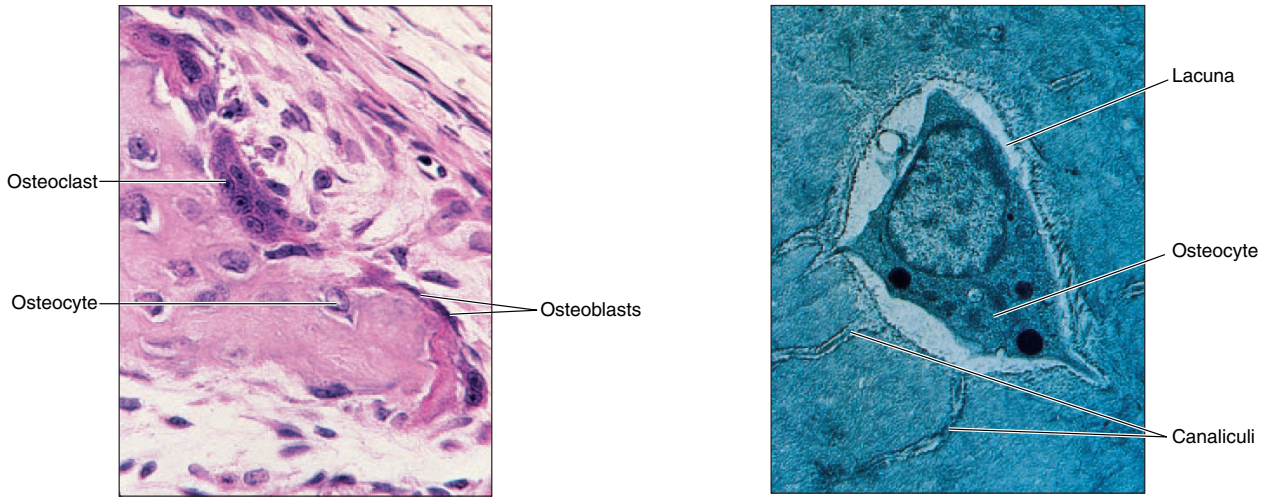

(a) (b)

FIGURE 6.6 (*a*) Types of bone cells. (*b*) A photomicrograph of an osteocyte within a lacuna.

Knowledge Check

6. Using examples, discuss the function of each of the four kinds of bones as determined by shape.
7. Define each of the following surface markings on bones: *condyle*, *head*, *facet*, *process*, *crest*, *epicondyle*, *fossa*, *alveolus*, *foramen*, and *sinus*.
8. Diagram a sagittal view of a typical long bone of a child and label the diaphysis, medullary cavity, epiphyses, articular cartilages, nutrient foramen, periosteum, and epiphyseal plates. Explain the function of each of these structures.

BONE TISSUE

Bone tissue is composed of several types of bone cells embedded in a matrix of ground substance, inorganic salts (calcium and phosphorus), and collagenous fibers. Bone cells and ground substance give bone flexibility and strength; the inorganic salts give it hardness.

Objective 6 Identify the five types of bone cells and list the functions of each.

Objective 7 Distinguish between spongy and compact bone tissues.

Bone Cells

There are five principal types of bone cells contained within bone tissue. **Osteogenic** (*os''te-ŏ-jen'ik*) **cells** are found in the bone tissues in contact with the endosteum and the periosteum. These cells respond to trauma, such as a fracture, by giving rise to bone-forming cells (*osteoblasts*) and bone-destroying cells (*osteoclasts*). **Osteoblasts** (*os'te-ŏ-blasts*) are bone-forming cells (fig. 6.6) that synthesize and secrete unmineralized ground substance. They are abundant in areas of high metabolism within bone, such as under the periosteum and bordering the medullary cavity. **Osteocytes** (*os'te-ŏ-sĭts*) are mature bone cells (figs. 6.6 and 6.7) derived from osteoblasts that have secreted bone tissue around themselves. Osteocytes maintain healthy bone tissue by secreting enzymes and influencing bone mineral content. **Osteoclasts** (*os'te-ŏ-klasts*) are large multinuclear cells (fig. 6.6) that enzymatically break down bone tissue, releasing calcium, magnesium, and other minerals to the blood. These cells are important in bone growth, remodeling, and healing. **Bone-lining cells** are derived from osteoblasts along the surface of most bones in the adult skeleton. These cells are thought to regulate the movement of calcium and phosphate into and out of bone matrix.

Spongy and Compact Bone Tissues

As mentioned earlier, most bones contain both spongy and compact bone tissues (fig. 6.7). **Spongy bone tissue** is located deep to the compact bone tissue, and is quite porous. Minute spikes of bone tissue, called **trabeculae** (*tră-bek'yŭ-le*), give spongy bone a latticelike appearance. Spongy bone is highly vascular and provides great strength to bone with minimal weight.

Compact bone tissue forms the external portion of a bone and is very hard and dense. It consists of precise arrangements of microscopic cylindrical structures oriented parallel to the long axis of the bone (fig. 6.7). These columnlike structures are the **osteons** (*os'te-onz*), or **haversian systems,** of the bone tissue. The matrix of an osteon is laid down in concentric rings, called **lamellae** (*lă-mel'e*), that surround a **central** (haversian) **canal** (fig. 6.8). The central canal contains minute

osteoblast: Gk. *osteon*, bone; *blastos*, offspring or germ
osteoclast: GK. *osteon*, bone; *klastos*, broken
haversian system: from Clopton Havers, English anatomist, 1650–1702

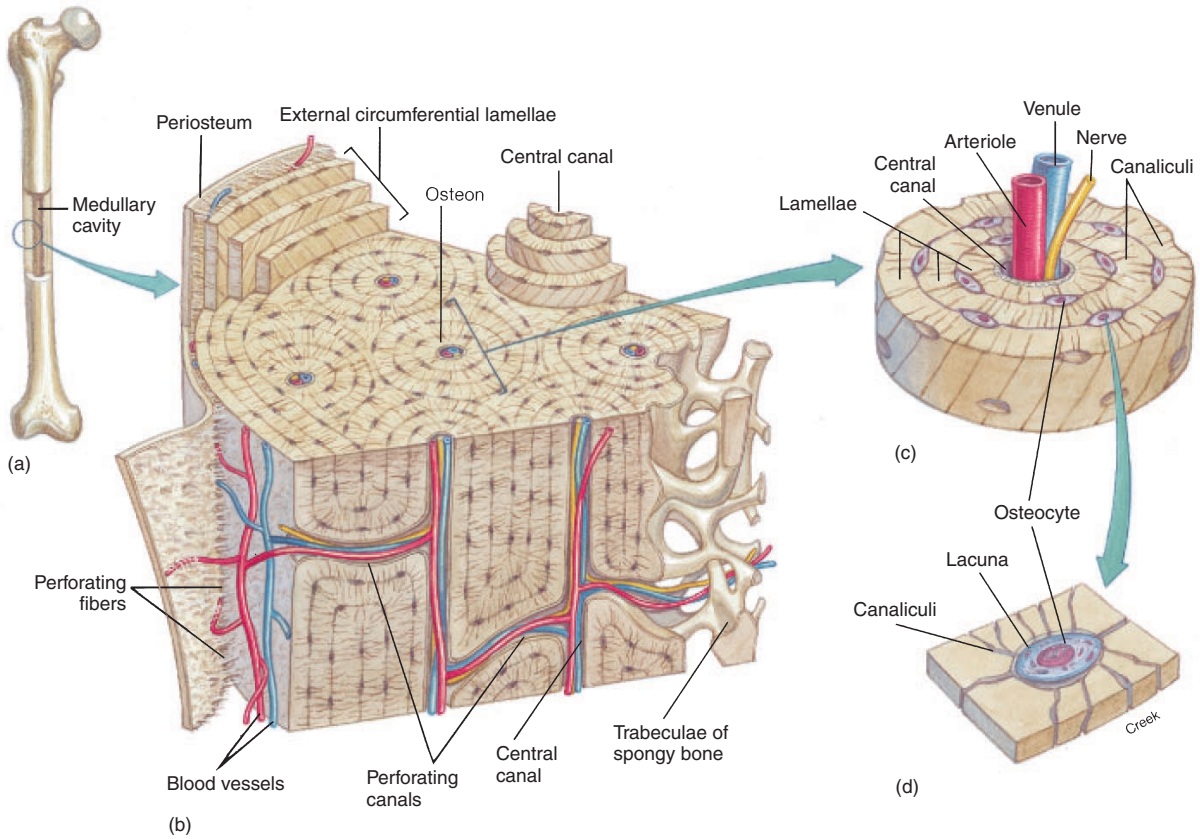

FIGURE 6.7 Compact bone tissue. (*a*) A diagram of the femur showing a cut through the compact bone into the medullary cavity. (*b*) The arrangement of the osteons within the diaphysis of the bone. (*c*) An enlarged view of an osteon showing the osteocytes within lacunae and the concentric lamellae. (*d*) An osteocyte within a lacuna.

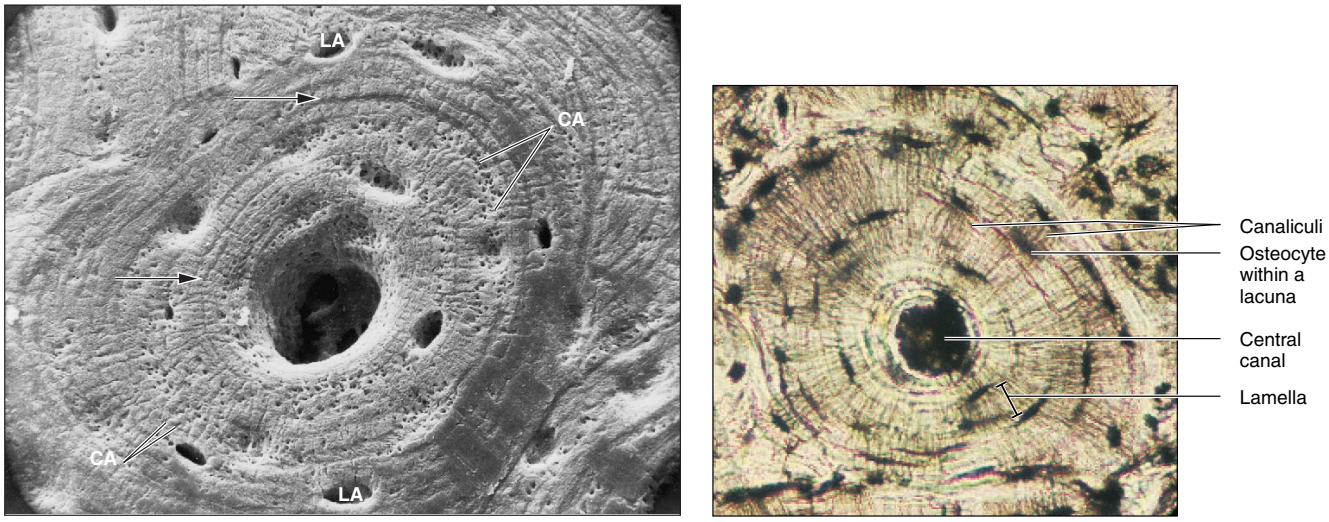

(a) (b)

FIGURE 6.8 Bone tissue as seen in (*a*) a scanning electron micrograph and (*b*) a photomicrograph. The lacunae (LA) provides spaces for the osteocytes, which are connected to one another by canaliculi (CA). Note the divisions between the lamellae (see arrows).

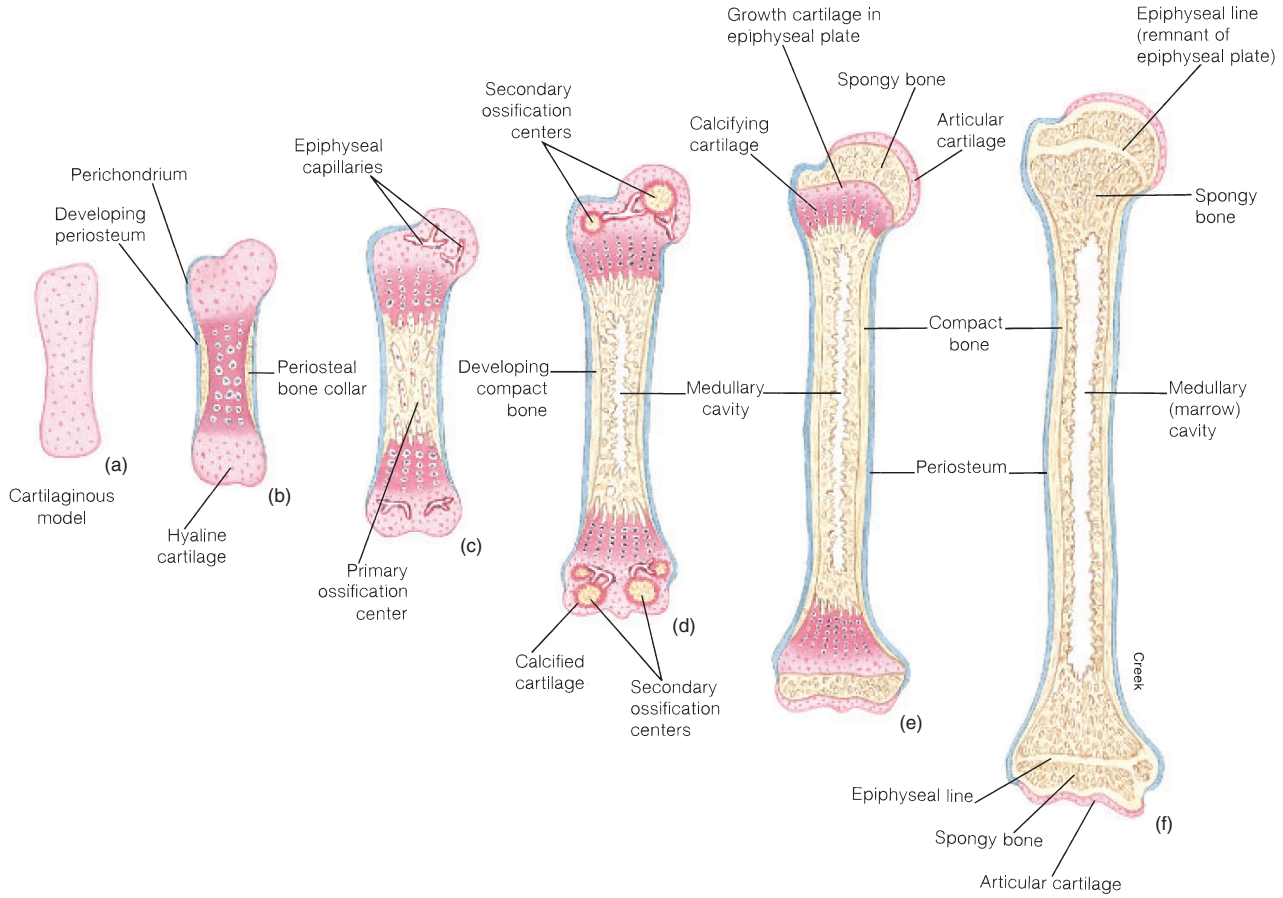

FIGURE 6.9 The growth process of a long bone, beginning with (*a*) the cartilaginous model as it occurs in an embryo at 6 weeks. The bone develops (*b–e*) through intermediate stages to (*f*) adult bone.

nutrient vessels and a nerve. Osteocytes within spaces called **lacunae** (*lă-kyoo′ne*) are regularly arranged between the lamellae. The lacunae are connected by tiny channels called **canaliculi** (*kan′′ ă-lik′yŭ-li*), through which nutrients diffuse. Metabolic activity within bone tissue occurs at the osteon level. Between osteons there are incomplete remnants of osteons, called **interstitial systems. Perforating** (Volkmann's) **canals** penetrate compact bone, connecting osteons with blood vessels and nerves.

Knowledge Check

9. Construct a sample table listing the location and function of each type of cell found within bone tissue
10. Define *osteon* and sketch the arrangement of osteons within compact bone tissue.

Volkmann's canal: from Alfred Volkmann, German physiologist, 1800–77

BONE GROWTH

The development of bone from embryo to adult depends on the orderly processes of cell division, growth, and ongoing remodeling. Bone growth is influenced by genetics, hormones, and nutrition.

Objective 8 Describe the process of endochondral ossification as related to bone growth.

In most bone development, a cartilaginous model is gradually replaced by bone tissue during *endochondral bone formation* (see Developmental Exposition, pp. 141–142). As the cartilage model grows, the *chondrocytes* (cartilage cells) in the center of the shaft hypertrophy, and minerals are deposited within the matrix in a process called *calcification* (fig. 6.9). Calcification restricts the passage of nutrients to the chondrocytes, causing them to die. At the same time, some cells of the perichondrium (dense regular connective tissue surrounding cartilage) differentiate into *osteoblasts*. These cells secrete **osteoid** (*os′te-oid*), the hardened organic

Developmental Exposition

The Axial Skeleton

EXPLANATION

Development of Bone

Bone formation, or *ossification*, begins at about the fourth week of embryonic development, but ossification centers cannot be readily observed until about the tenth week (exhibit I). Bone tissue derives from specialized migratory cells of mesoderm (see fig. 4.13) known as *mesenchyme*. Some of the embryonic mesenchymal cells will transform into *chondroblasts (kon′dro-blasts)* and develop a cartilage matrix that is later replaced by bone in a process known as **endochondral** *(en′′dŏ-kon′dral)* **ossification.** Most of the skeleton is formed in this fashion—first it goes through a hyaline cartilage stage and then it is ossified as bone.

A smaller number of mesenchymal cells develop into bone directly, without first going through a cartilage stage. This type of bone-formation process is referred to as **intramembranous** *(in′′tră-mem′bră-nus)* **ossification.** The clavicles, facial bones, and certain bones of the cranium are formed this way. *Sesamoid bones* are specialized intramembranous bones that develop in tendons. The patella is an example of a sesamoid bone.

chondroblast: Gk. *chondros*, cartilage; *blastos*, offspring or germ

DEVELOPMENT OF THE SKULL

The formation of the skull is a complex process that begins during the fourth week of embryonic development and continues well beyond the birth of the baby. Three aspects of the embryonic skull are involved in this process: the chondrocranium, the neurocranium, and the viscerocranium (exhibit II). The **chondrocranium** is the portion of the skull that undergoes endochondral ossification to form the bones supporting the brain. The **neurocranium** is the portion of the skull that develops through membranous ossification to form the bones covering the brain and facial region. The **viscerocranium** (splanchnocranium) is the portion that develops from the embryonic visceral arches to form the mandible, auditory ossicles, the hyoid bone, and specific processes of the skull.

chondrocranium: Gk. *chondros*, cartilage; *kranion*, skull
viscerocranium: L. *viscera*, soft parts; Gk. *kranion*, skull

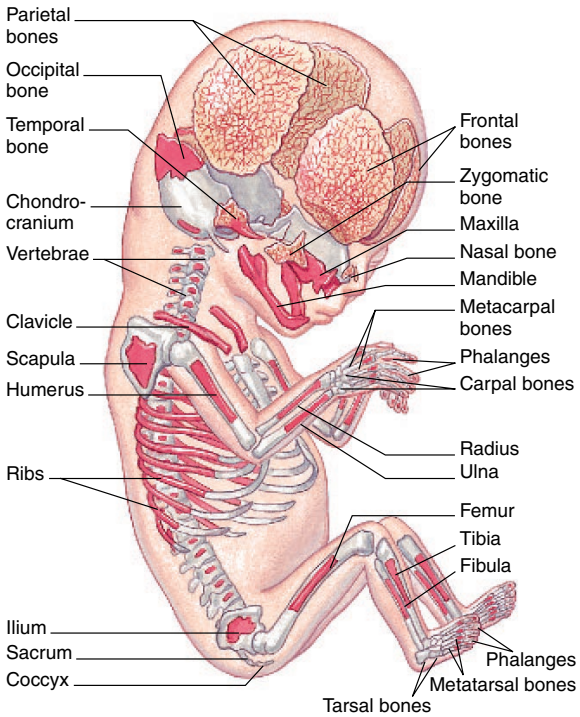

(a)

(b)

EXHIBIT I Ossification centers of the skeleton of a 10-week-old fetus. (*a*) The diagram depicts endochondrial ossification in red and intramembranous ossification in a stippled pattern. The cartilaginous portions of the skeleton are shown in gray. (*b*) The photograph shows the ossification centers stained with a red indicator dye.

(continued)

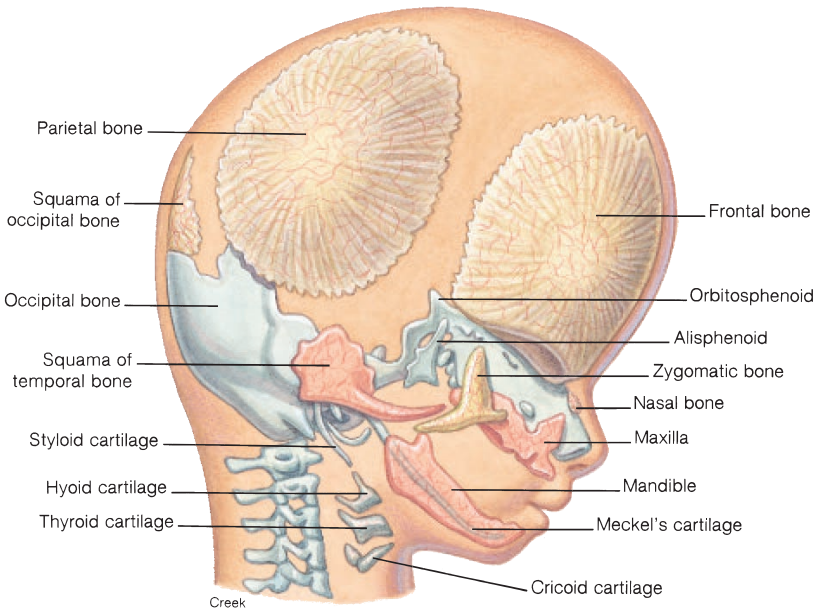

EXHIBIT II The embryonic skull at 12 weeks is composed of bony elements from three developmental sources: the chondrocranium (colored blue-gray), the neurocranium (colored light yellow), and the viscerocranium (colored salmon).

component of bone. As the perichondrium calcifies, it gives rise to a thin plate of compact bone called the **periosteal bone collar.** The periosteal bone collar is surrounded by the periosteum.

A **periosteal bud,** consisting of osteoblasts and blood vessels, invades the disintegrating center of the cartilage model from the periosteum. Once in the center, the osteoblasts secrete osteoid, and a **primary ossification center** is established. Ossification then expands into the deteriorating cartilage. This process is repeated in both the proximal and distal epiphyses, forming **secondary ossification centers** where spongy bone develops.

Once the secondary ossification centers have been formed, bone tissue totally replaces cartilage tissue, except at the articular ends of the bone and at the epiphyseal plates. An **epiphyseal plate** contains five histological zones (fig. 6.10). The *reserve zone* (zone of resting cartilage) borders the epiphysis and consists of small chondrocytes irregularly dispersed throughout the intercellular matrix. The chondrocytes in this zone anchor the epiphyseal plate to the bony epiphysis. The *proliferation zone* (zone of proliferating cartilage) consists of larger, regularly arranged chondrocytes that are constantly dividing. The *hypertrophic zone* (zone

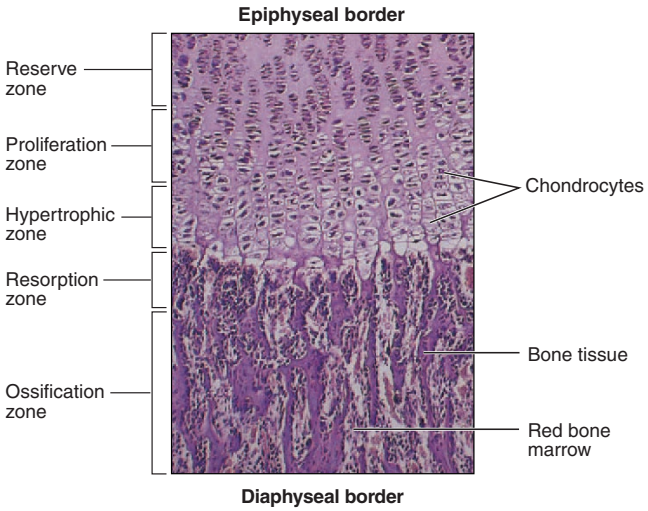

FIGURE 6.10 A photomicrograph from an epiphyseal plate (63×).

TABLE 6.3 Average Age of Completion of Bone Ossification

Bone	Chronological Age of Fusion
Scapula	18–20
Clavicle	23–31
Bones of upper extremity	17–20
Os coxae	18–23
Bones of lower extremity	18–22
Vertebra	25
Sacrum	23–25
Sternum (body)	23
Sternum (manubrium, xiphoid)	30+

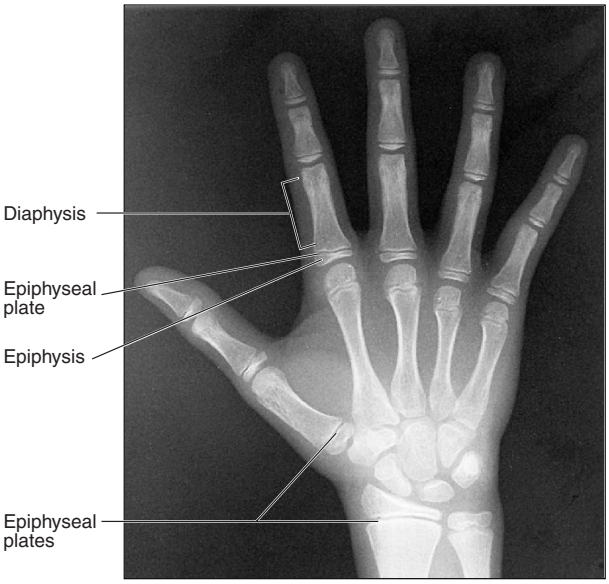

FIGURE 6.11 The presence of epiphyseal plates as seen in a radiograph of a child's hand. The plates indicate that the bones are still growing in length.

of hypertrophic cartilage) consists of very large chondrocytes that are arranged in columns. The linear growth of long bones is due to the cellular proliferation at the proliferation zone and the growth and maturation of these new cells within the hypertrophic zone. The *resorption zone* (zone of dechondrification) is the area where a change in mineral content is occurring. The *ossification zone* (zone of calcified cartilage) is a region of transformation from cartilage tissue to bone tissue. The chondrocytes within this zone die because the intercellular matrix surrounding them becomes calcified. Osteoclasts then break down the calcified matrix and the area is invaded by osteoblasts and capillaries from the bone tissue of the diaphysis. As the osteoblasts mature, osteoid is secreted and bone tissue is formed. The result of this process is a gradual increase in the length of the bone at the epiphyseal plates.

The time at which epiphyseal plates ossify varies greatly from bone to bone, but it usually occurs between the ages of 18 and 20 within the long bones (table 6.3). Because ossification of the epiphyseal cartilages within each bone occurs at predictable times, radiologists can determine the ages of people who are still growing by examining radiographs of their bones (fig. 6.11). Large discrepancies between bone age and chronological age may indicate a genetic or endocrine abnormality.

Bone is continually being remodeled over the course of a person's life. Bony prominences develop as stress is applied to the periosteum, causing the osteoblasts to secrete osteoid and form new bone tissue. The greater trochanter of the femur, for example, develops in response to forces of stress applied to the periosteum where the tendons of muscles attach (fig. 6.12). Even though a person has stopped growing in height, bony processes may continue to enlarge somewhat if he or she remains physically active.

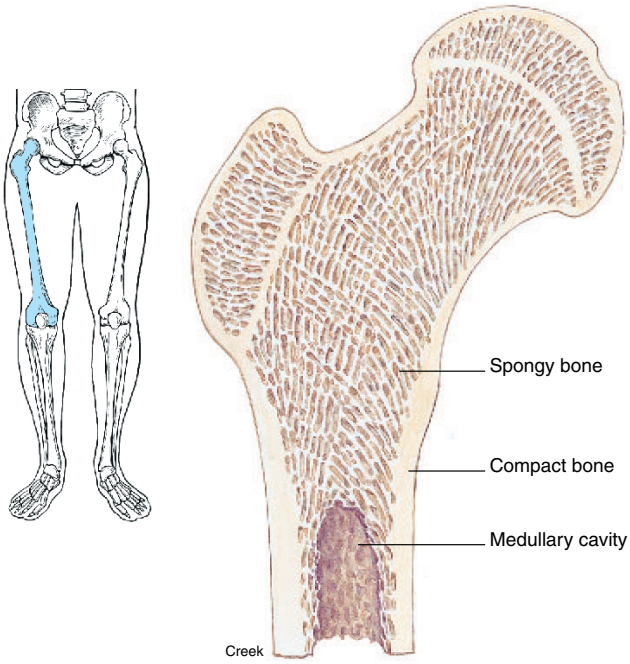

FIGURE 6.12 A longitudinal section of the proximal end of a femur showing stress lines within spongy bone.

As new bone layers are deposited on the outside surface of the bone, osteoclasts dissolve bone tissue adjacent to the medullary cavity. In this way, the size of the cavity keeps pace with the increased growth of the bone.

Even the absence of stress causes a remodeling of bones. This effect can best be seen in the bones of bedridden or paralyzed individuals. Radiographs of their bones reveal a marked loss of bone tissue. The absence of gravity that accompanies space flight may result in mineral loss from bones if an exercise regimen is not followed.

The movement of teeth in orthodontics involves bone remodeling. The dental alveoli (tooth sockets) are reshaped through the activity of osteoclast and osteoblast cells as stress is applied with braces. The use of traction in treating certain skeletal disorders has a similar effect.

Knowledge Check

11. List the zones of an epiphyseal plate and briefly describe the characteristics of each.
12. Explain the function of osteoblasts and osteoclasts in endochondral ossification and bone growth.

SKULL

The human skull, consisting of 8 cranial and 14 facial bones, contains several cavities that house the brain and sensory organs. Each bone of the skull articulates with the adjacent bones and has diagnostic and functional processes, surface features, and foramina.

Objective 9 List the fontanels and discuss their functions.

Objective 10 Identify the cranial and facial bones of the skull and describe their structural characteristics.

Objective 11 Describe the location of each of the bones of the skull and identify the articulations that affix one to the other.

The skull consists of *cranial bones* and *facial bones*. The eight bones of the cranium articulate firmly with one another to enclose and protect the brain and sensory organs. The 14 facial bones form the framework for the facial region and support the teeth. Variation in size, shape, and density of the facial bones is a major contributor to the individuality of each human face. The facial bones, with the exception of the mandible ("jawbone"), are also firmly interlocked with one another and the cranial bones.

The skull has several cavities. The **cranial cavity** is the largest, with an approximate capacity of 1,300 to 1,350 cc. The **nasal cavity** is formed by both cranial and facial bones and is partitioned into two chambers, or **nasal fossae,** by a **nasal septum** of bone and cartilage. Four sets of **paranasal sinuses,** located within the bones surrounding the nasal area, communicate via ducts into the nasal cavity. **Middle-** and **inner-ear cavities** are positioned inferior to the cranial cavity and house the organs of hearing and balance. The two **orbits** for the eyeballs are formed by facial and cranial bones. The **oral,** or **buccal** (*buk'al*) **cavity** (mouth), which is only partially formed by bone, is completely within the facial region (see fig. 2.23).

During fetal development and infancy, the bones of the cranium are separated by fibrous unions. There are also six large areas of connective tissue membrane that cover the gaps between the developing bones. These membranous sheets are called **fontanels** (*fon''tă-nelz'*), meaning "little fountains." The name derives from the fact that a baby's pulse can be felt surging in these "soft spots" on the skull. The fontanels permit the skull to undergo changes in shape, called *molding*, during parturition (childbirth), and they accommodate the rapid growth of the brain during infancy. Ossification of the fontanels is normally complete by 20 to 24 months of age. The fontanels are illustrated in figure 6.13 and briefly described below.

1. **Anterior** (frontal) **fontanel.** The anterior fontanel is diamond-shaped and is the most prominent. It is located on the anteromedian portion of the skull.
2. **Posterior** (occipital) **fontanel.** The posterior fontanel is positioned at the back of the skull on the median line. It is also diamond-shaped, but smaller than the anterior fontanel.
3. **Anterolateral** (sphenoid) **fontanels.** The paired anterolateral fontanels are found on both sides of the skull, directly lateral to the anterior fontanel. They are relatively small and irregularly shaped.
4. **Posterolateral** (mastoid) **fontanels.** The paired posterolateral fontanels, also irregularly shaped, are located on the posterolateral sides of the skull.

During normal childbirth, the fetal skull comes under tremendous pressure. Bones may even shift, altering the shape of the skull. A common occurrence during molding of the fetal skull is for the occipital bone to be repositioned under the two parietal bones. In addition, one parietal bone may shift so as to overlap the other. This makes delivery easier for the mother. If a baby is born breech (buttocks first), these shifts do not occur. Delivery becomes much more difficult, often requiring the use of forceps.

A prominent **sagittal suture** extends the anteroposterior median length of the skull between the anterior and posterior fontanels. A **coronal suture** extends from the anterior fontanel to the anterolateral fontanel. A **lambdoid suture** extends from the posterior fontanel to the posterolateral fontanel. A **squamous suture** connects the posterolateral fontanel to the anterolateral fontanel.

The bones of the skull contain numerous foramina (see table 6.2) to accommodate nerves, vessels, and other structures. The foramina of the skull are summarized in table 6.4. Various

fontanel: Fr. *fontaine*, little fountain
lambdoid: Gk. *lambda*, letter λ in Greek alphabet

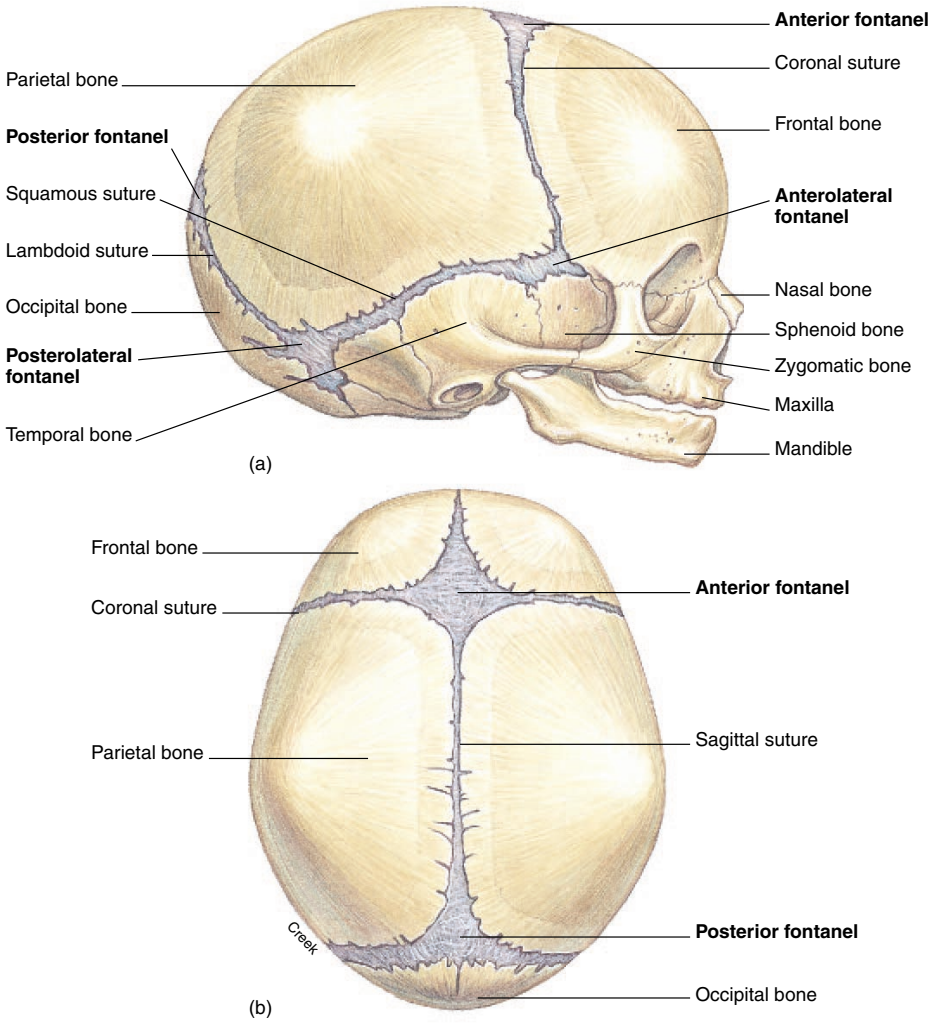

FIGURE 6.13 The fetal skull showing the six fontanels and the sutures. (*a*) A right lateral view and (*b*) a superior view.

views of the skull are shown in figures 6.14 through 6.21; radiographs are shown in figure 6.22.

Although the hyoid bone and the three paired auditory ossicles are not considered part of the skull, they are associated with it. These bones are described in this section, immediately following the discussion of the facial bones.

Cranial Bones

The cranial bones enclose and protect the brain and associated sensory organs. They consist of one *frontal*, two *parietals*, two *temporals*, one *occipital*, one *sphenoid*, and one *ethmoid*.

Frontal Bone

The frontal bone forms the anterior roof of the cranium, the forehead, the roof of the nasal cavity, and the superior arches of the *orbits*, which contain the eyeballs. The bones of the orbit are summarized in table 6.5. The frontal bone develops in two halves that grow together. Generally, they are completely fused by age 5 or 6. A suture sometimes persists between these two portions beyond age 6 and is referred to as a *metopic* (*mĕ-top′ik*) *suture*. The **supraorbital margin** is a

cranium: Gk. *kranion*, skull

metopic suture: Gk. *metopon*, forehead; L. *sutura*, sew

TABLE 6.4 Major Foramina of the Skull

Foramen	Location	Structures Transmitted
Carotid canal	Petrous part of temporal bone	Internal carotid artery and sympathetic nerves
Greater palatine foramen	Palatine bone of hard palate	Greater palatine nerve and descending palatine vessels
Hypoglossal canal	Anterolateral edge of occipital condyle	Hypoglossal nerve and branch of ascending pharyngeal artery
Incisive foramen	Anterior region of hard palate, posterior to incisors	Branches of descending palatine vessels and nasopalatine nerve
Inferior orbital fissure	Between maxilla and greater wing of sphenoid bone	Maxillary nerve of trigeminal cranial nerve, zygomatic nerve, and infraorbital vessels
Infraorbital foramen	Inferior to orbit in maxilla	Infraorbital nerve and artery
Jugular foramen	Between petrous part of temporal and occipital bones, posterior to carotid canal	Internal jugular vein; vagus, glossopharyngeal, and accessory nerves
Foramen lacerum	Between petrous part of temporal and sphenoid bones	Branch of ascending pharyngeal artery and internal carotid artery
Lesser palatine foramen	Posterior to greater palatine foramen in hard palate	Lesser palatine nerves
Foramen magnum	Occipital bone	Union of medulla oblongata and spinal cord, meningeal membranes, and accessory nerves; vertebral and spinal arteries
Mandibular foramen	Medial surface of ramus of mandible	Inferior alveolar nerve and vessels
Mental foramen	Below second premolar on lateral side of mandible	Mental nerve and vessels
Nasolacrimal canal	Lacrimal bone	Nasolacrimal (tear) duct
Cribriform foramina	Cribriform plate of ethmoid bone	Olfactory nerves
Optic foramen	Back of orbit in lesser wing of sphenoid bone	Optic nerve and ophthalmic artery
Foramen ovale	Greater wing of sphenoid bone	Mandibular nerve (branch) of trigeminal nerve
Foramen rotundum	Within body of sphenoid bone	Maxillary nerve (branch) of trigeminal nerve
Foramen spinosum	Posterior angle of sphenoid bone	Middle meningeal vessels
Stylomastoid foramen	Between styloid and mastoid processes of temporal bone	Facial nerve and stylomastoid artery
Superior orbital fissure	Between greater and lesser wings of sphenoid bone	Four cranial nerves (oculomotor, trochlear, ophthalmic nerve of trigeminal, and abducens)
Supraorbital foramen	Supraorbital ridge of orbit	Supraorbital nerve and artery
Zygomaticofacial foramen	Anterolateral surface of zygomatic bone	Zygomaticofacial nerve and vessels

prominent bony ridge over the orbit. Slightly medial to its midpoint is an opening called the **supraorbital foramen,** which provides passage for a nerve, artery, and veins.

The frontal bone also contains **frontal sinuses,** which are connected to the nasal cavity (fig 6.22). These sinuses, along with the other paranasal sinuses, lessen the weight of the skull and act as resonance chambers for voice production.

Parietal Bone

The two parietal bones form the upper sides and roof of the cranium (figs. 6.15 and 6.17). The **coronal suture** separates the frontal bone from the parietal bones, and the **sagittal suture** along the superior midline separates the right and left parietals from each other. The inner concave surface of each parietal bone, as well as the inner concave surfaces of other cranial bones, is marked by shallow impressions from convolutions of the brain and vessels serving the brain.

Temporal Bone

The two temporal bones form the lower sides of the cranium (figs. 6.15, 6.16, 6.17, and 6.23). Each temporal bone is joined to its adjacent parietal bone by the **squamous suture.** Structurally, each temporal bone has four parts.

1. **Squamous part.** The squamous part is the flattened plate of bone at the sides of the skull. Projecting forward is a **zygomatic** (*zi''go-mat'ik*) **process** that forms the posterior portion of the **zygomatic arch.** On the inferior surface of the squamous part is the cuplike **mandibular fossa,** which forms a joint with the condyle of the mandible. This articulation is the *temporomandibular joint*.

zygomatic: Gk. *zygoma,* yolk

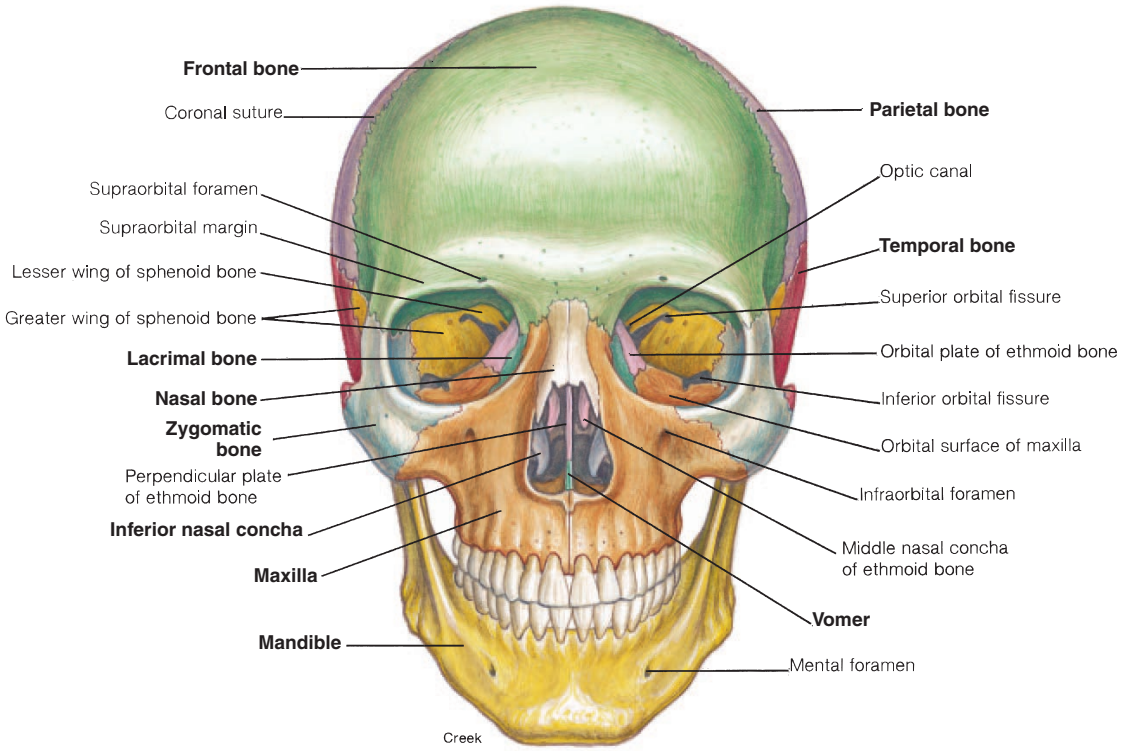

FIGURE 6.14 An anterior view of the skull.

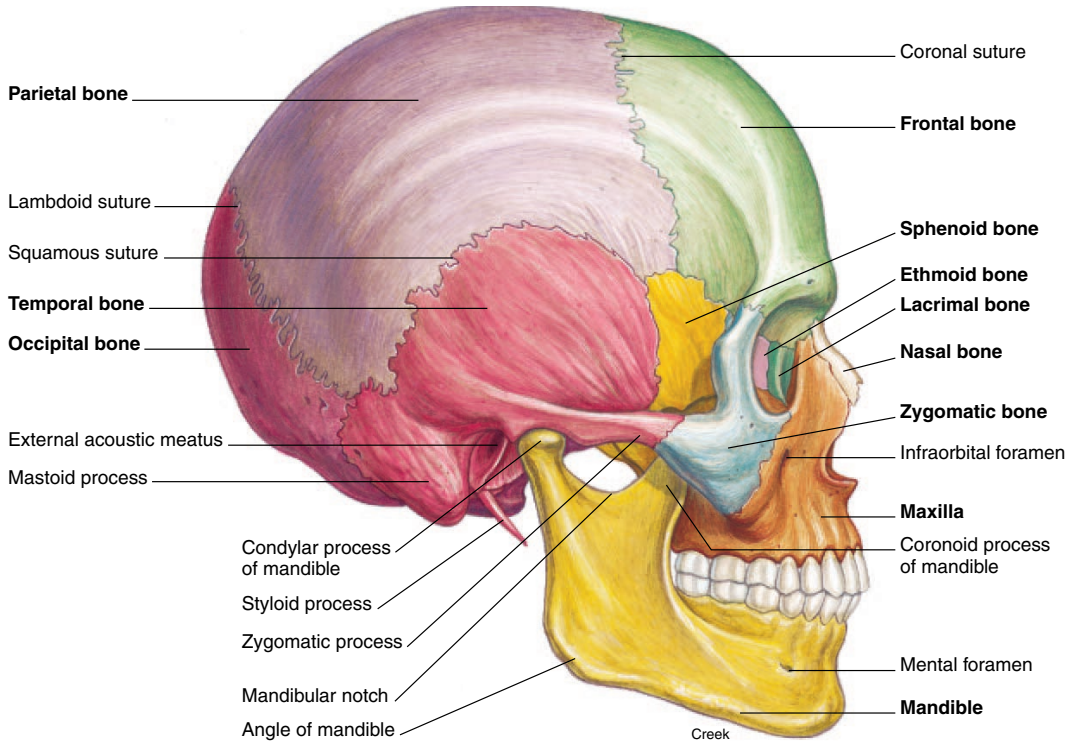

FIGURE 6.15 A lateral view of the skull.

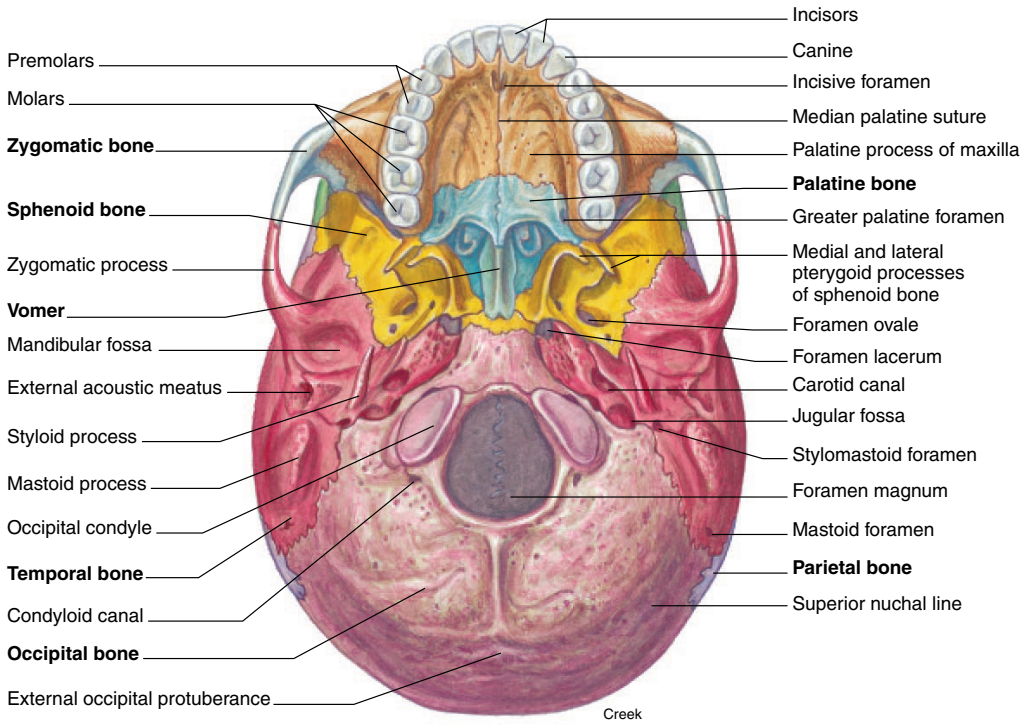

FIGURE 6.16 An inferior view of the skull.

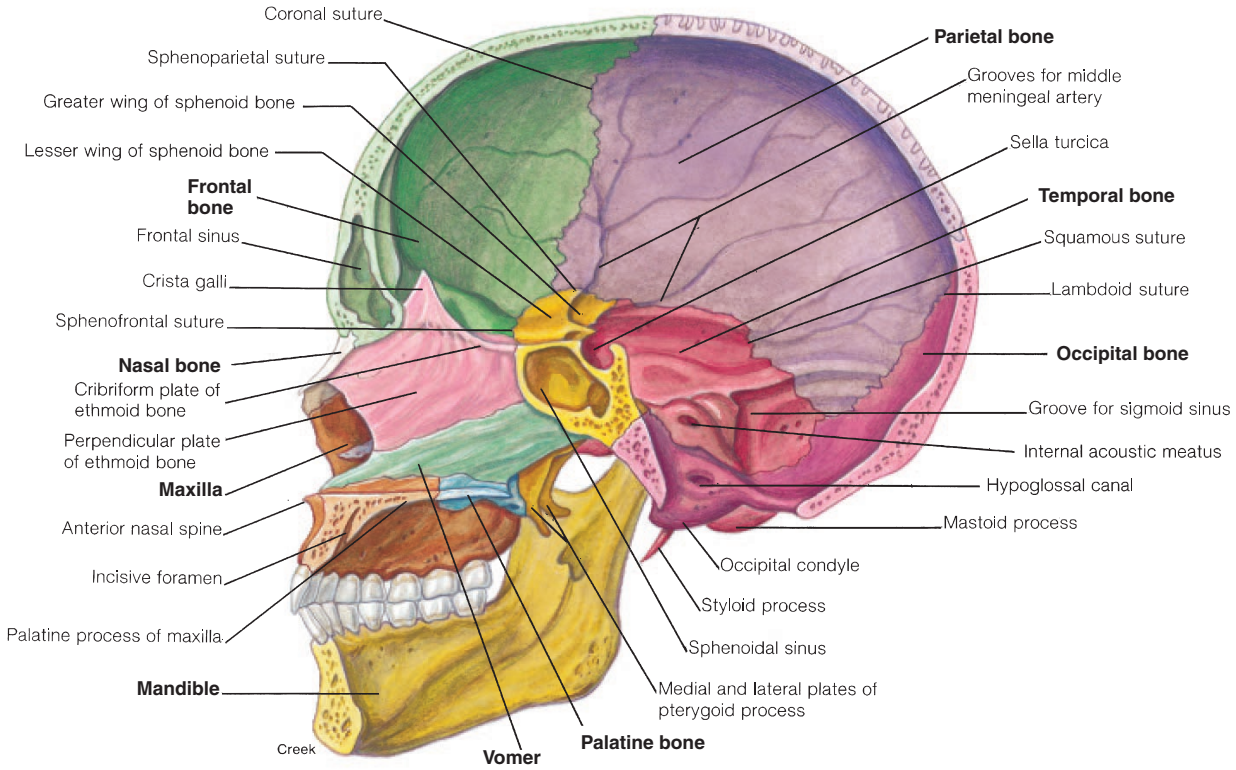

FIGURE 6.17 A sagittal view of the skull.

CHAPTER 6

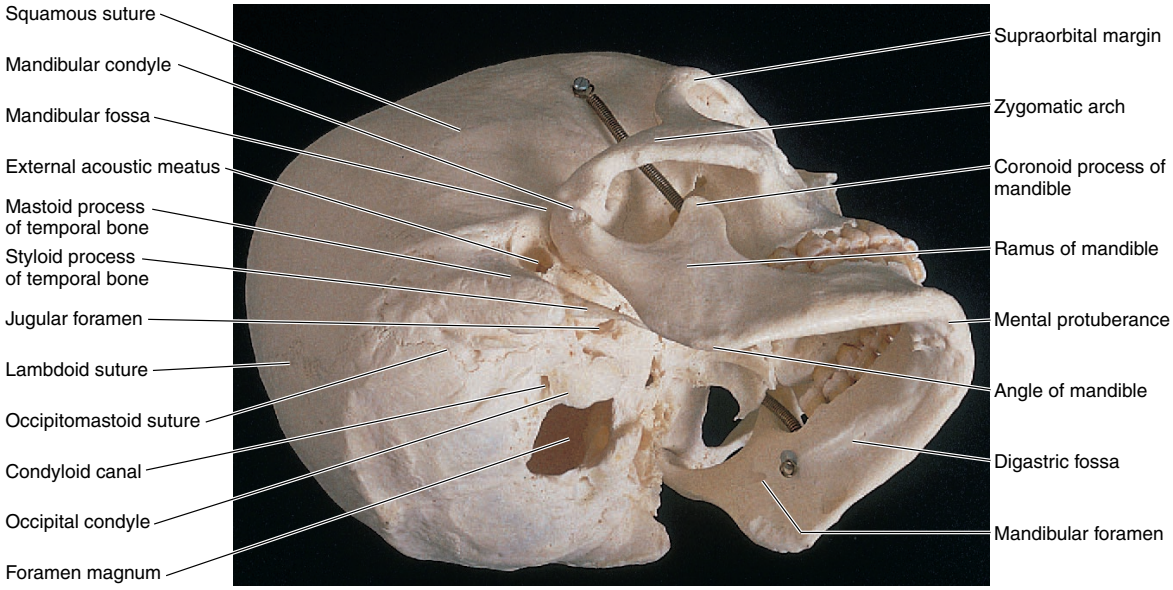

FIGURE 6.18 An inferolateral view of the skull.

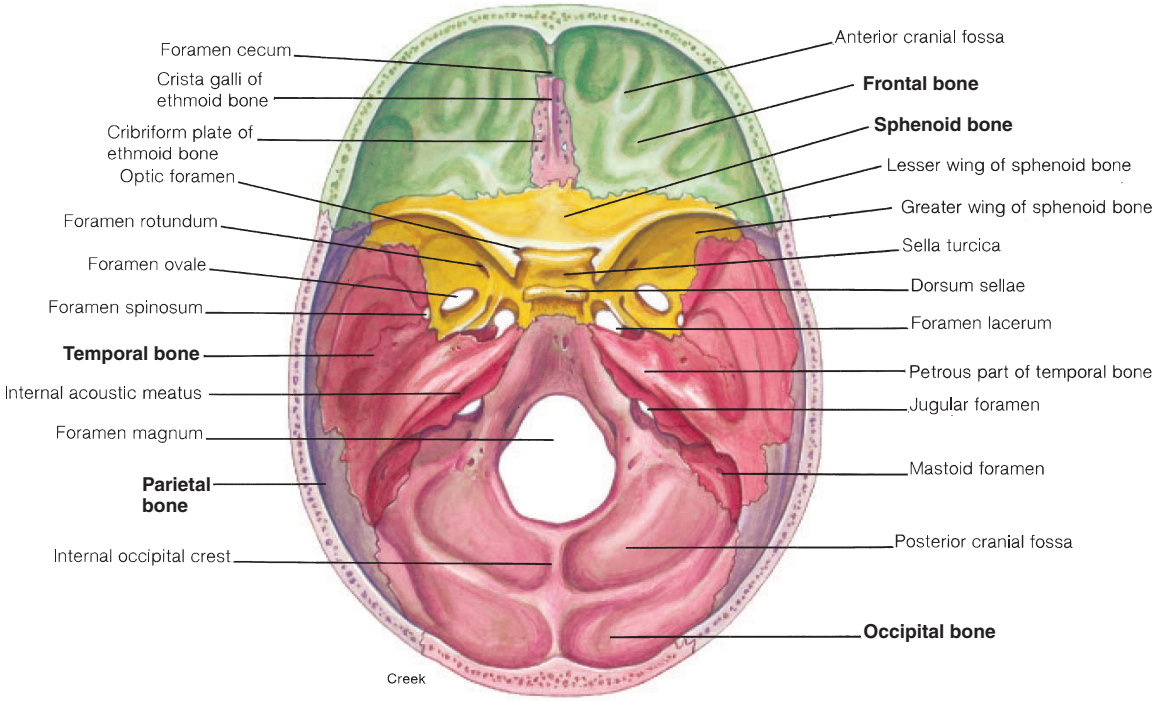

FIGURE 6.19 The floor of the cranial cavity.

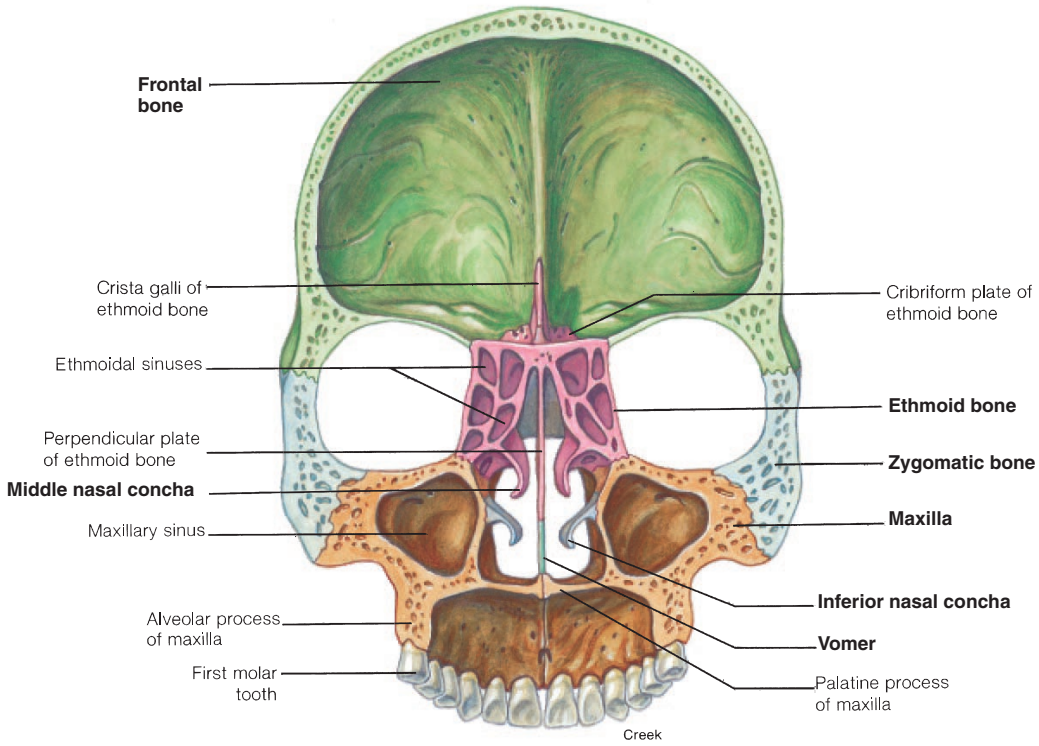

FIGURE 6.20 A posterior view of a frontal (coronal) section of the skull.

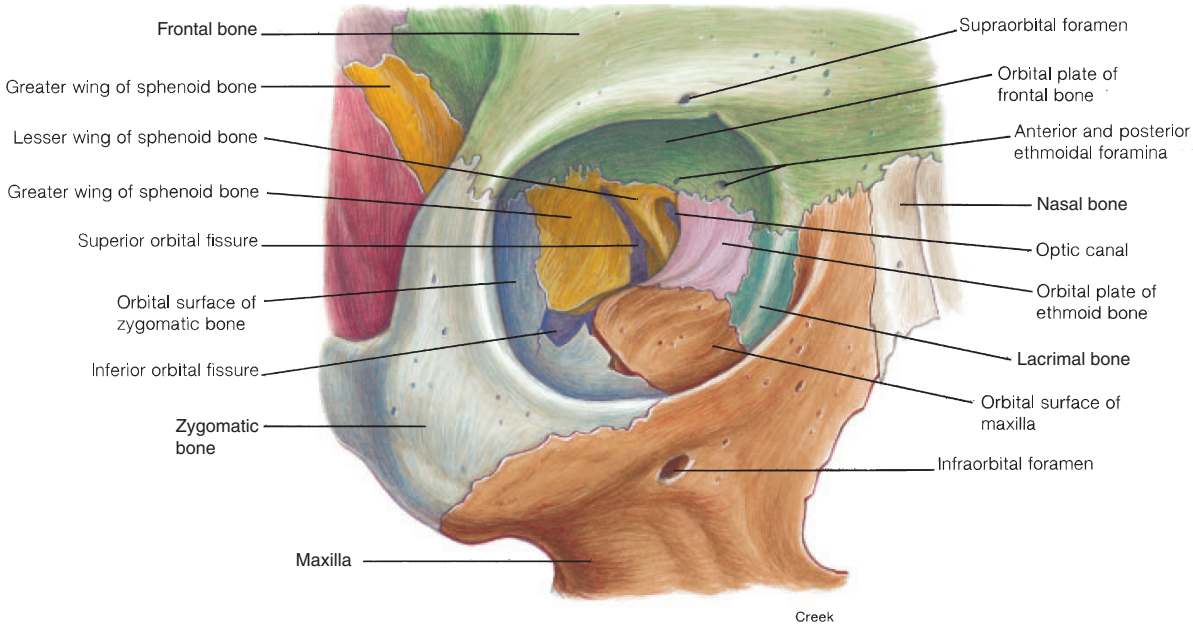

FIGURE 6.21 Bones of the orbit.

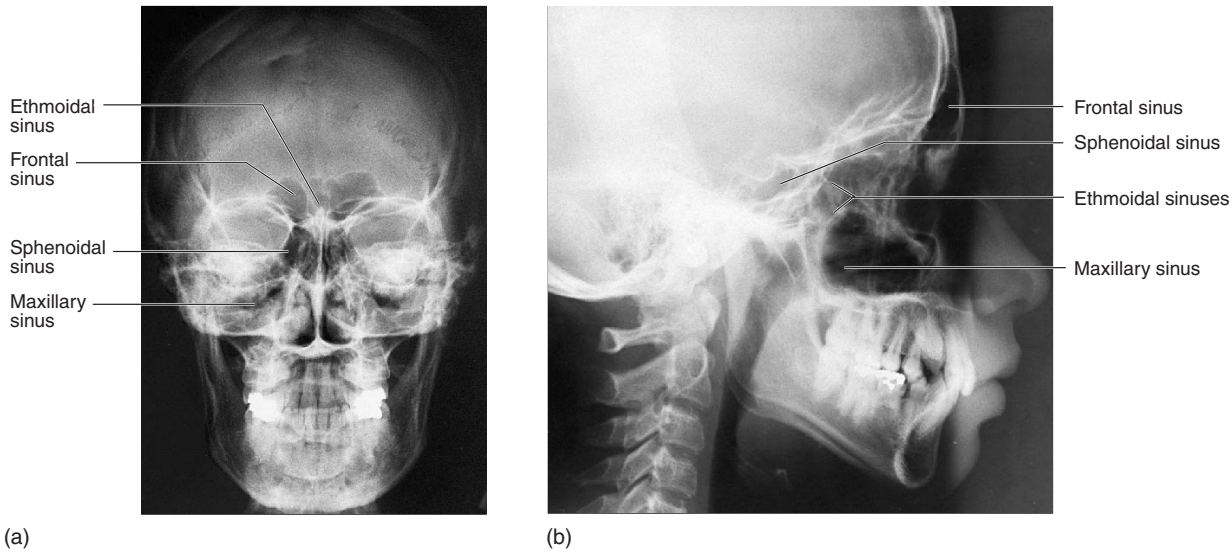

FIGURE 6.22 Radiographs of the skull showing the paranasal sinuses. (*a*) An anteroposterior view and (*b*) a right lateral view.

TABLE 6.5 Bones Forming the Orbit

Region of the Orbit	Contributing Bones
Roof (superior)	Frontal bone; lesser wing of sphenoid bone
Floor (inferior)	Maxilla; zygomatic bone; palatine bone
Lateral wall	Zygomatic bone
Posterior wall	Greater wing of sphenoid bone
Medial wall	Maxilla; lacrimal bone; ethmoid bone
Superior margin	Frontal bone
Lateral margin	Zygomatic bone
Medial margin	Maxilla

2. **Tympanic part.** The tympanic part of the temporal bone contains the **external acoustic meatus** *(me-a′tus)*, or ear canal, which is posterior to the mandibular fossa. A thin, pointed **styloid process** (figs. 6.16, 6.17, and 6.18) projects inferiorly from the tympanic part.
3. **Mastoid part.** The **mastoid process,** a rounded projection posterior to the external acoustic meatus, accounts for the mass of the mastoid part. The **mastoid foramen** (fig. 6.16) is directly posterior to the mastoid process. The **stylomastoid foramen,** located between the mastoid and styloid processes (fig. 6.16), provides the passage for part of the facial nerve.
4. **Petrous part.** The petrous *(pet′rus)* part can be seen in the floor of the cranium (figs. 6.19 and 6.23). The structures of the middle ear and inner ear are housed in this dense part of the temporal bone. The **carotid** *(kă-rot′id)* **canal** and the **jugular foramen** border on the medial side of the petrous part at the junction of the temporal and occipital bones. The carotid canal allows blood into the brain via the internal carotid artery, and the jugular foramen lets blood drain from the brain via the internal jugular vein. Three cranial nerves also pass through the jugular foramen (see table 6.4).

The mastoid process of the temporal bone can be easily palpated as a bony knob immediately behind the earlobe. This process contains a number of small air-filled spaces called *mastoid cells* that can become infected in *mastoiditis,* as a result, for example, of a prolonged middle-ear infection.

Occipital Bone

The occipital bone forms the posterior and most of the base of the skull. It articulates with the parietal bones at the **lambdoid suture.** The **foramen magnum** is the large hole in the occipital bone through which the spinal cord passes to attach to the brain stem. On each side of the foramen magnum are the **occipital condyles** (fig. 6.16), which articulate with the first vertebra (the atlas) of the vertebral column. At the anterolateral edge of the occipital condyle is the **hypoglossal canal** (fig. 6.17), through which the hypoglossal nerve passes. A **condyloid** *(kon′dĭ-loid)* **canal** lies posterior to the occipital condyle (fig. 6.16). The

styloid: Gk. *stylos*, pillar
mastoid: Gk. *mastos*, breast

petrous: Gk. *petra*, rock
magnum: L. *magnum*, great

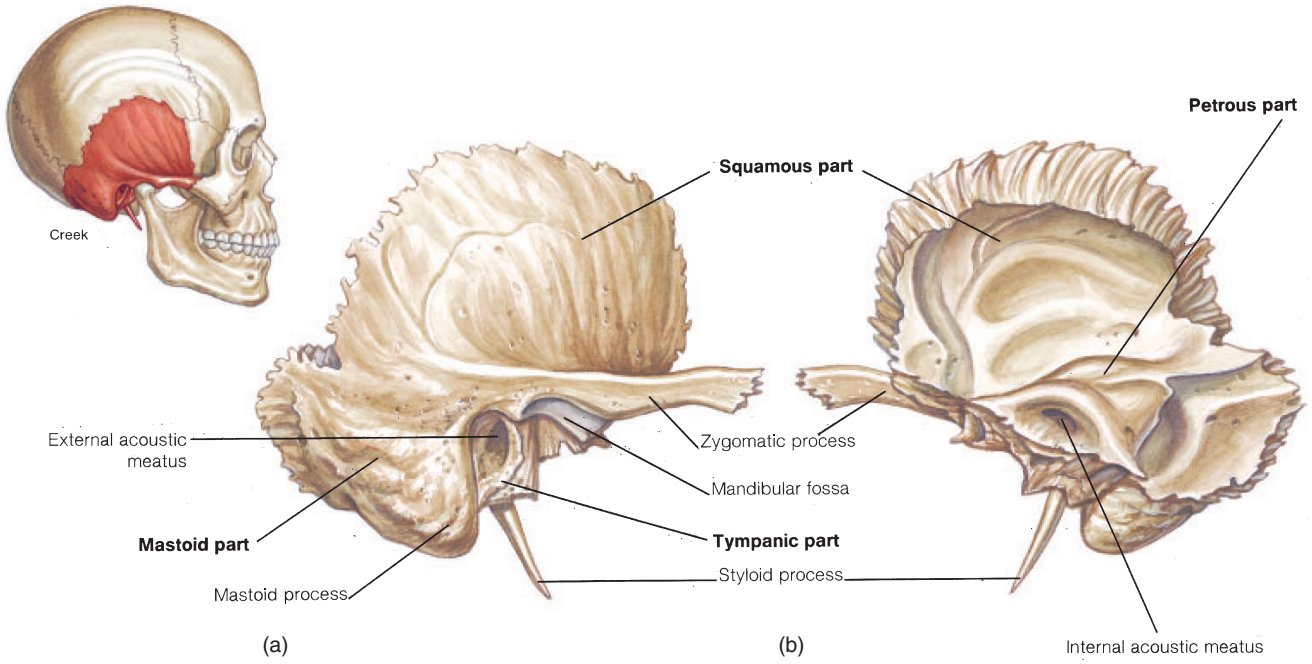

FIGURE 6.23 The temporal bone. (*a*) A lateral view and (*b*) a medial view.

external occipital protuberance is a prominent posterior projection on the occipital bone that can be felt as a definite bump just under the skin. The **superior nuchal** *(noo'kal)* **line** is a ridge of bone extending laterally from the occipital protuberance to the mastoid part of the temporal bone. **Sutural bones** are small clusters of irregularly shaped bones that frequently occur along the lambdoid suture.

Sphenoid Bone

The sphenoid *(sfe'noid)* bone forms part of the anterior base of the cranium and can be viewed laterally and inferiorly (figs. 6.15 and 6.16). This bone has a somewhat mothlike shape (fig. 6.24). It consists of a **body** and laterally projecting **greater** and **lesser wings** that form part of the orbit. The wedgelike body contains the **sphenoidal sinuses** and a prominent saddle-like depression, the **sella turcica** (*sel'ă tur'sĭ-kă*). Commonly called "Turk's saddle," the sella turcica houses the pituitary gland. A pair of **pterygoid** *(ter'ĭ-goid)* **processes** project inferiorly from the sphenoid bone and help form the lateral walls of the nasal cavity.

Several foramina (figs. 6.16, 6.19, and 6.24) are associated with the sphenoid bone.

1. The **optic canal** is a large opening through the lesser wing into the back of the orbit that provides passage for the optic nerve and the ophthalmic artery.
2. The **superior orbital fissure** is a triangular opening between the wings of the sphenoid bone that provides passage for the ophthalmic nerve, a branch of the trigeminal nerve, and for the oculomotor, trochlear, and abducens nerves.
3. The **foramen ovale** is an opening at the base of the lateral pterygoid plate, through which the mandibular nerve passes.
4. The **foramen spinosum** is a small opening at the posterior angle of the sphenoid bone that provides passage for the middle meningeal vessels.
5. The **foramen lacerum** (*las'er-um*) is an opening between the sphenoid and the petrous part of the temporal bone, through which the internal carotid artery and the meningeal branch of the ascending pharyngeal artery pass.
6. The **foramen rotundum** is an opening just posterior to the superior orbital fissure, at the junction of the anterior and medial portions of the sphenoid bone. The maxillary nerve passes through this foramen.

Located on the inferior side of the cranium, the sphenoid bone would seem to be well protected from trauma. Actually, just the opposite is true—and in fact the sphenoid is the most frequently fractured bone of the cranium. It has several broad, thin, platelike extensions that are perforated by numerous foramina. A blow to almost any portion of the skull causes the buoyed, fluid-filled brain to rebound against the vulnerable sphenoid bone, often causing it to fracture.

nuchal: Fr. *nuque*, nape of neck
sphenoid: Gk. *sphenoeides*, wedgelike

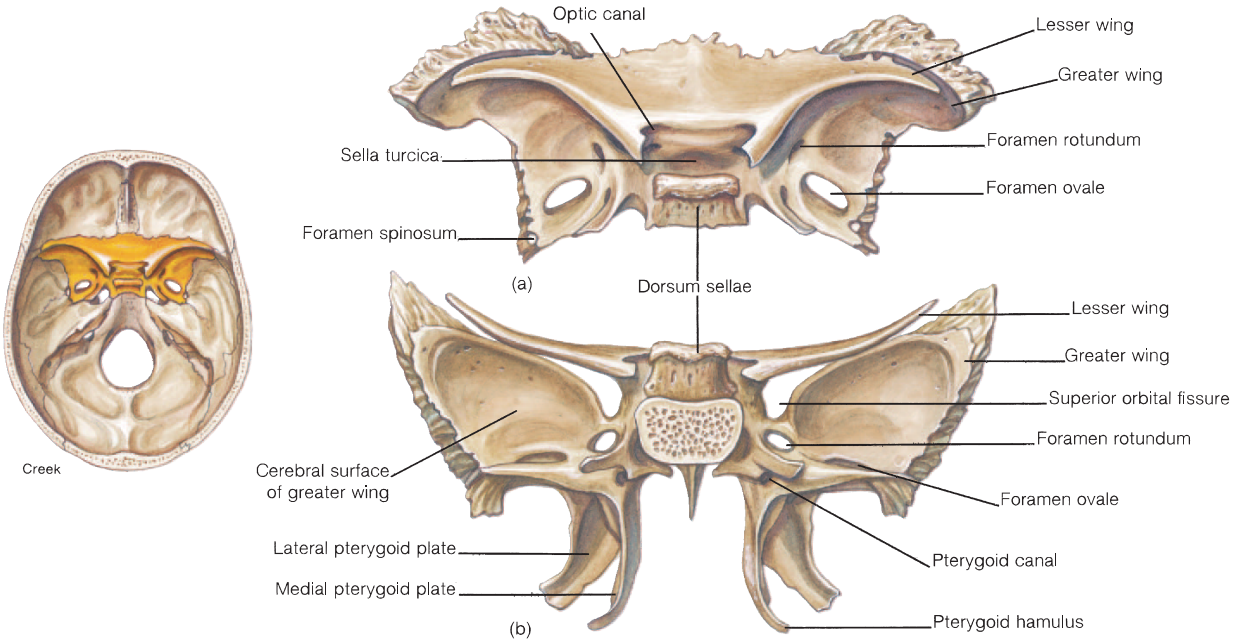

FIGURE 6.24 The sphenoid bone. (*a*) A superior view and (*b*) a posterior view.

Ethmoid Bone

The ethmoid bone is located in the anterior portion of the floor of the cranium between the orbits, where it forms the roof of the nasal cavity (figs. 6.17, 6.20, and 6.25). An inferior projection of the ethmoid bone, called the **perpendicular plate,** forms the superior part of the nasal septum that separates the nasal cavity into two chambers. Each chamber of the nasal cavity is referred to as a **nasal fossa.** Flanking the perpendicular plate on each side is a large but delicate mass of bone riddled with ethmoidal air cells, collectively constituting the **ethmoid sinus.** A spine of the perpendicular plate, the **crista galli** (*kris′tă gal′e*), projects superiorly into the cranial cavity and serves as an attachment for the meninges covering the brain. On both lateral walls of the nasal cavity are two scroll-shaped plates of the ethmoid bone, the **superior** and **middle nasal conchae** (*kong′ke*—singular, *concha*) (fig. 6.26), also known as *turbinates*. At right angles to the perpendicular plate, within the floor of the cranium, is the **cribriform** *(krib′rĭ-form)* **plate,** which has numerous **cribriform foramina** for the passage of olfactory nerves from the epithelial lining of the nasal cavity. The bones of the nasal cavity are summarized in table 6.6.

ethmoid: Gk. *ethmos*, sieve
crista galli: L. *crista*, crest; *galli*, cock's comb
conchae: L. *conchae*, shells
cribriform: L. *cribrum*, sieve; *forma*, like

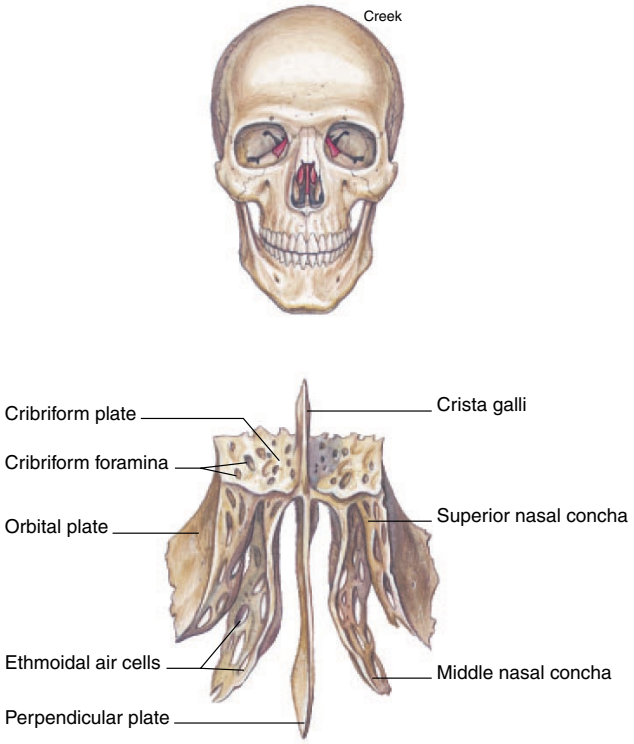

FIGURE 6.25 An anterior view of the ethmoid bone.

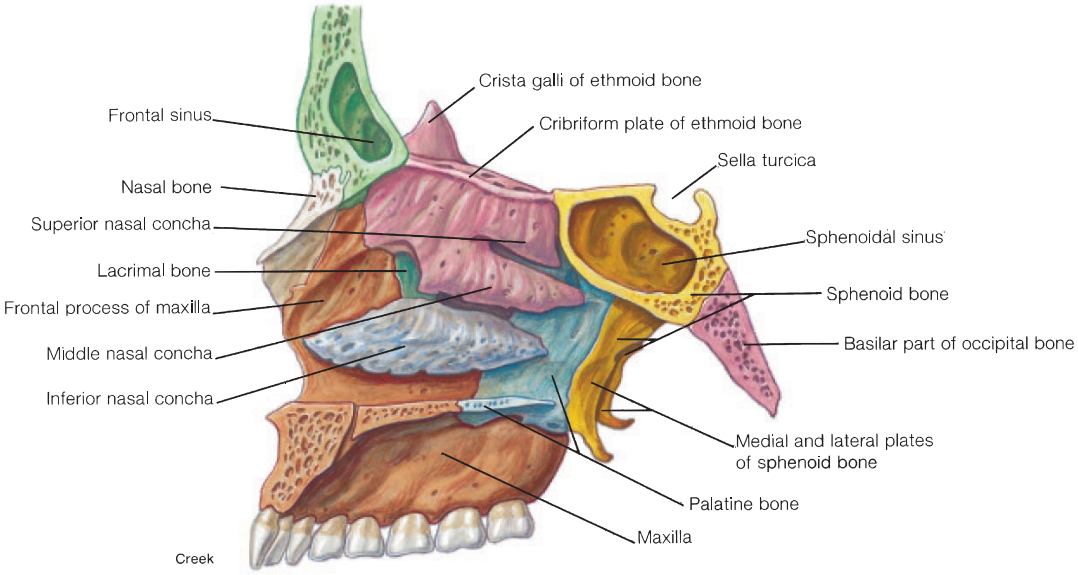

FIGURE 6.26 The lateral wall of the nasal cavity.

TABLE 6.6 Bones That Enclose the Nasal Cavity

Region of Nasal Cavity	Contributing Bones
Roof (superior)	Ethmoid bone (cribriform plate); frontal bone
Floor (inferior)	Maxilla; palatine bone
Lateral wall	Maxilla; palatine bone
Nasal septum (medial)	Ethmoid bone (perpendicular plate); vomer; nasal bone
Bridge	Nasal bone
Conchae	Ethmoid bone (superior and middle conchae); inferior nasal concha

The moist, warm vascular lining within the nasal cavity is susceptible to infections, particularly if a person is not in good health. Infections of the nasal cavity can spread to several surrounding areas. The paranasal sinuses connect to the nasal cavity and are especially prone to infection. The eyes may become reddened and swollen during a nasal infection because of the connection of the nasolacrimal duct, through which tears drain from the anterior surface of the eye to the nasal cavity. Organisms may spread via the auditory tube from the nasopharynx to the middle ear. With prolonged nasal infections, organisms may even ascend to the meninges covering the brain via the sheaths of the olfactory nerves and pass through the cribriform plate to cause *meningitis*.

Facial Bones

The 14 bones of the skull not in contact with the brain are called **facial bones.** These bones, together with certain cranial bones (frontal bone and portions of the ethmoid and temporal bones), give shape and individuality to the face. Facial bones also support the teeth and provide attachments for various muscles that move the jaw and cause facial expressions. With the exceptions of the vomer and mandible, all of the facial bones are paired. The articulated facial bones are illustrated in figures 6.14 through 6.21.

Maxilla

The two maxillae (*mak-sil′e*) unite at the midline to form the upper jaw, which supports the upper teeth. **Incisors, canines** (cuspids), **premolars,** and **molars** are anchored in **dental alveoli,** (tooth sockets), within the **alveolar** (*al-ve′ŏ-lar*) **process** of the maxilla (fig. 6.27). The **palatine** (*pal′ă-tīn*) **process,** a horizontal plate of the maxilla, forms the greater portion of the **hard palate** (*pal′it*), or roof of the mouth. The **incisive foramen** (fig. 6.16) is located in the anterior region of the hard palate, behind the in-

incisor: L. *incidere*, to cut
canine: L. *canis*, dog
molar: L. *mola*, millstone
alveolus: L. *alveus*, little cavity

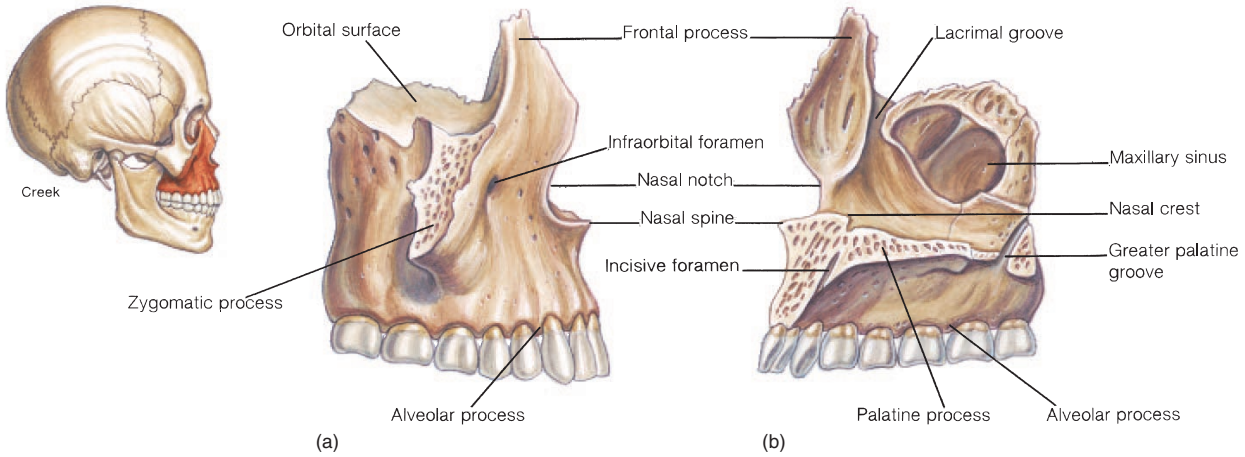

FIGURE 6.27 The maxilla. (*a*) A lateral view and (*b*) a medial view.

cisors. An **infraorbital foramen** is located under each orbit and serves as a passageway for the infraorbital nerve and artery to the nose (figs. 6.14, 6.15, 6.21, and 6.27). A final opening within the maxilla is the **inferior orbital fissure.** It is located between the maxilla and the greater wing of the sphenoid (fig. 6.14) and is the external opening for the maxillary nerve of the trigeminal nerve and infraorbital vessels. The large **maxillary sinus** located within the maxilla is one of the four paranasal sinuses (figs. 6.20 and 6.22).

If the two palatine processes fail to join during early prenatal development (about 12 weeks), a *cleft palate* results. A cleft palate may be accompanied by a *cleft lip* lateral to the midline. These conditions can be surgically treated with excellent cosmetic results. An immediate problem, however, is that a baby with a cleft palate may have a difficult time nursing because it is unable to create the necessary suction within the oral cavity to swallow effectively.

Palatine Bone

The L-shaped palatine bones form the posterior third of the hard palate, a part of the orbits, and a part of the nasal cavity. The **horizontal plates** of the palatines contribute to the formation of the hard palate (fig. 6.28). At the posterior angle of the hard palate is the large **greater palatine foramen** that provides passage for the greater palatine nerve and descending palatine vessels (fig. 6.16). Two or more smaller **lesser palatine foramina** are positioned posterior to the greater palatine foramen. Branches of the lesser palatine nerve pass through these openings.

Zygomatic Bone

The two zygomatic bones ("cheekbones") form the lateral contours of the face. A posteriorly extending *temporal process* of this bone unites with the *zygomatic process* of the temporal bone to form the **zygomatic arch** (fig. 6.16). The zygomatic bone also forms the lateral margin of the orbit. A small **zygomaticofacial** (*zī''gō-mat''ĭ-kōfa'shal*) **foramen,** located on the anterolateral surface of this bone, allows passage of the zygomatic nerves and vessels.

Lacrimal Bone

The thin lacrimal bones form the anterior part of the medial wall of each orbit (fig. 6.21). These are the smallest of the facial bones. Each one has a **lacrimal sulcus**—a groove that helps form the **nasolacrimal canal.** This opening permits the tears of the eye to drain into the nasal cavity.

Nasal Bone

The small, rectangular nasal bones (fig. 6.14) join at the midline to form the bridge of the nose. The nasal bones support the flexible cartilaginous plates, which are a part of the framework of the nose. Fractures of the nasal bones or fragmentation of the associated cartilages are common facial injuries.

Inferior Nasal Concha

The two inferior nasal conchae are fragile, scroll-like bones that project horizontally and medially from the lateral walls of the nasal cavity (figs. 6.14 and 6.20). They extend into the nasal cavity just below the superior and middle nasal conchae, which are part of the ethmoid bone (see fig. 6.25). The inferior nasal conchae are the largest of the three paired conchae, and, like the other two, are covered with a mucous membrane to warm, moisten, and cleanse inhaled air.

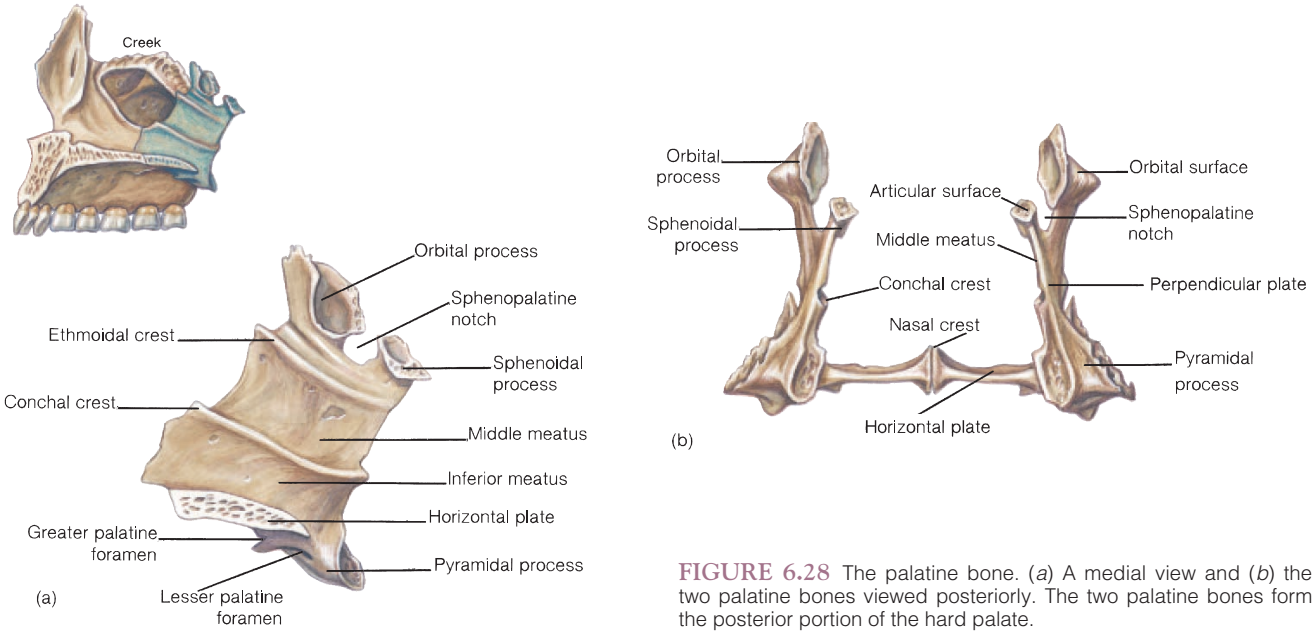

FIGURE 6.28 The palatine bone. (*a*) A medial view and (*b*) the two palatine bones viewed posteriorly. The two palatine bones form the posterior portion of the hard palate.

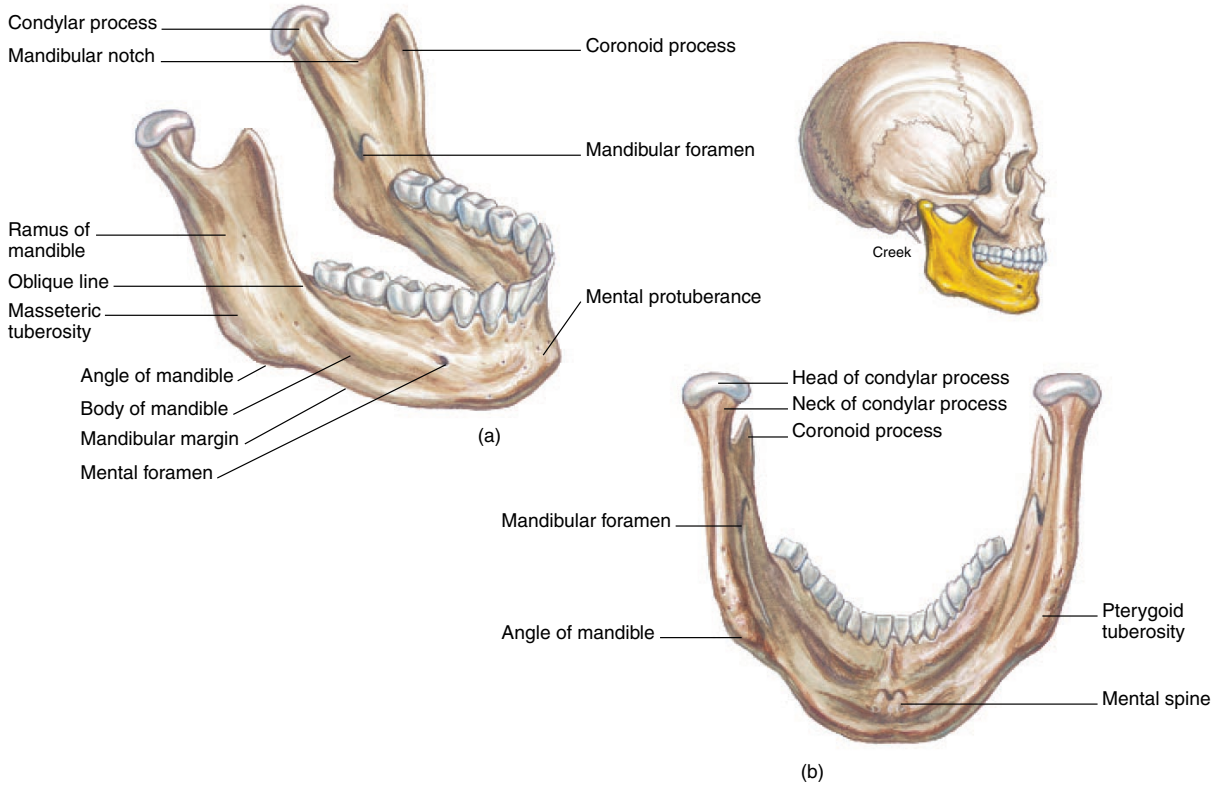

FIGURE 6.29 The mandible. (*a*) A lateral view and (*b*) a posterior view.

Vomer

The vomer (*vo'mer*) is a thin, flattened bone that forms the lower part of the nasal septum (figs. 6.16, 6.17, and 6.20). Along with the perpendicular plate of the ethmoid bone, it supports the layer of septal cartilage that forms most of the anterior and inferior parts of the nasal septum.

Mandible

The mandible ("jawbone") is the largest, strongest bone in the face. It is attached to the skull by paired temporomandibular joints (see fig. 8.23), and is the only movable bone of the skull. The horseshoe-shaped front and horizontal lateral sides of the mandible are referred to as the **body** (fig. 6.29). Extending vertically from the posterior part of the body are two **rami** (*ra'mi*—singular, *ramus*). At the superior margin of each ramus is a knoblike **condylar process,** which articulates with the mandibular fossa of the temporal bone, and a pointed **coronoid process** for the attachment of the temporalis muscle. The depressed area between these two processes is called the **mandibular notch.** The **angle of the mandible** is where the horizontal body and vertical ramus meet at the corner of the jaw.

Two sets of foramina are associated with the mandible: the **mental foramen,** on the anterolateral aspect of the body of the mandible below the first molar, and the **mandibular foramen,** on the medial surface of the ramus. The mental nerve and vessels pass through the mental foramen, and the inferior alveolar nerve and vessels are transmitted through the mandibular foramen. Several muscles that close the jaw extend from the skull to the mandible (see chapter 9). The mandible of an adult supports 16 teeth within dental alveoli, which occlude with the 16 teeth of the maxilla.

Dentists use bony landmarks of the facial region to locate the nerves that traverse the foramina in order to inject anesthetics. For example, the trigeminal nerve is composed of three large nerves, the lower two of which convey sensations from the teeth, gums, and jaws. The mandibular teeth can be desensitized by an injection near the mandibular foramen called a *third-division,* or *lower, nerve block.* An injection near the foramen rotundum of the skull, called a *second-division nerve block,* desensitizes all of the upper teeth on one side of the maxilla.

Hyoid Bone

The single **hyoid bone** is a unique part of the skeleton in that it does not attach directly to any other bone. It is located in the neck region, below the mandible, where it is suspended from the styloid process of the temporal bone by the stylohyoid muscles and ligaments. The hyoid bone has a **body,** two **lesser cornua** (*kor'nyoo-ă*—singular, *cornu*) extending anteriorly, and two **greater cornua** (fig. 6.30), which project posteriorly to the stylohyoid ligaments.

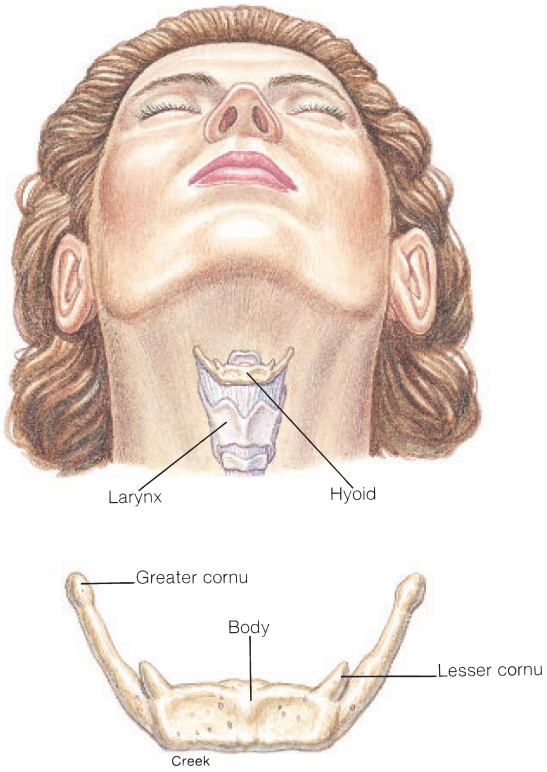

FIGURE 6.30 An anterior view of the hyoid bone.

The hyoid bone supports the tongue and provides attachment for some of its muscles (see fig. 9.18). It may be palpated by placing a thumb and a finger on either side of the upper neck under the lateral portions of the mandible and firmly squeezing medially. This bone is carefully examined in an autopsy when strangulation is suspected, because it is frequently fractured during strangulation.

Auditory Ossicles

Three small paired bones, called **auditory ossicles,** are located within the middle-ear cavities in the petrous part of the temporal bones (fig. 6.31). From outer to inner, these bones are the **malleus** ("hammer"), **incus** ("anvil"), and **stapes** ("stirrup"). As described in chapter 15, their movements transmit sound impulses through the middle-ear cavity (see p. 518).

vomer: L. *vomer*, plowshare
mandible: L. *mandere*, to chew
ramus: L. *ramus*, branch
condylar: L. *condylus*, knucklelike
coronoid: Gk. *korone*, like a crow's beak
cornu: L. *cornu*, horn

malleus: L. *malleus*, hammer
incus: L. *incus*, anvil
stapes: L. *stapes*, stirrup

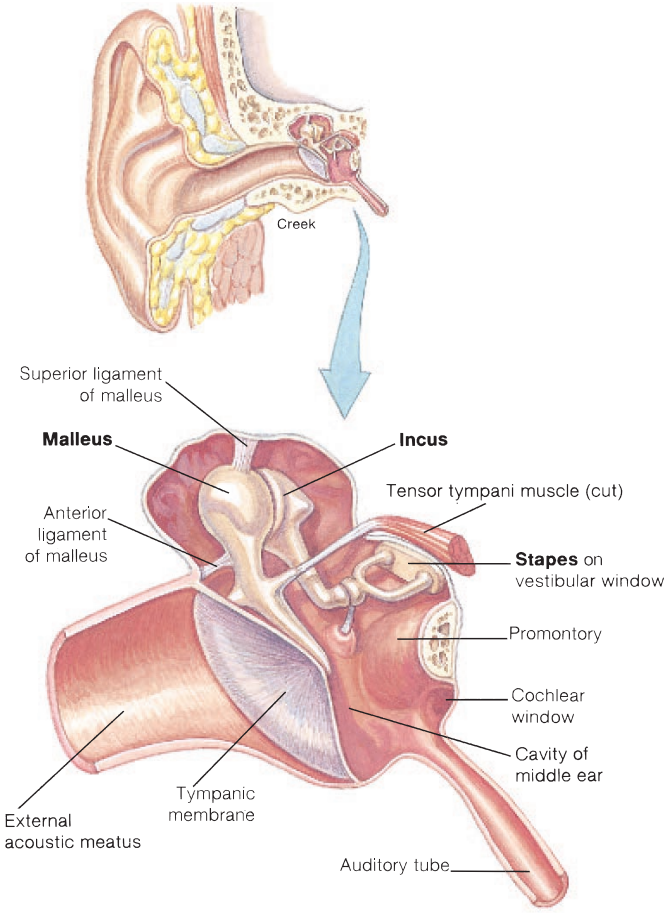

FIGURE 6.31 The three auditory ossicles within the middle-ear cavity.

Knowledge Check

13. State which facial and cranial bones of the skull are paired and which are unpaired. Also, indicate at least two structural features associated with each bone of the skull.
14. Describe the location of each bone of the skull and indicate the sutures that join these bones.
15. What is the function of each of the following: sella turcica, foramen magnum, petrous part of the temporal bone, crista galli, and nasal conchae?
16. Which facial bones support the teeth?

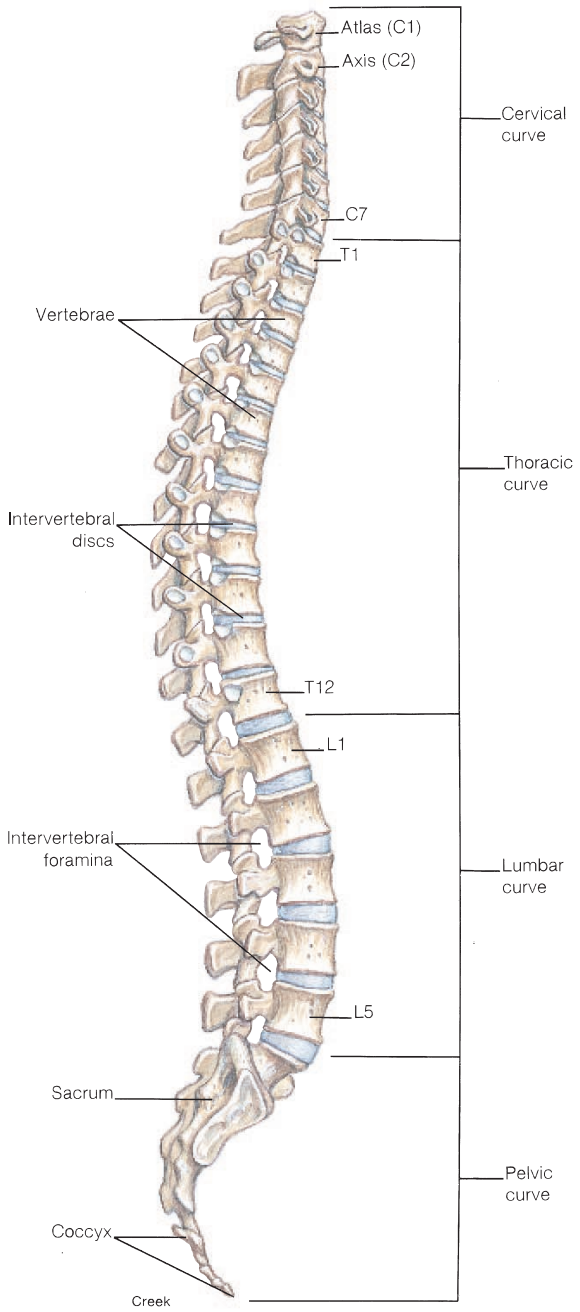

FIGURE 6.32 The vertebral column of an adult has four curves named according to the region in which they occur. The bodies of the vertebrae are separated by intervertebral discs, which allow flexibility.

VERTEBRAL COLUMN

The vertebral column consists of a series of irregular bones called vertebrae, separated from each other by fibrocartilaginous intervertebral discs. Vertebrae enclose and protect the spinal cord, support the skull and allow for its movement, articulate with the rib cage, and provide for the attachment of trunk muscles. The intervertebral discs lend flexibility to the vertebral column and absorb vertical shock.

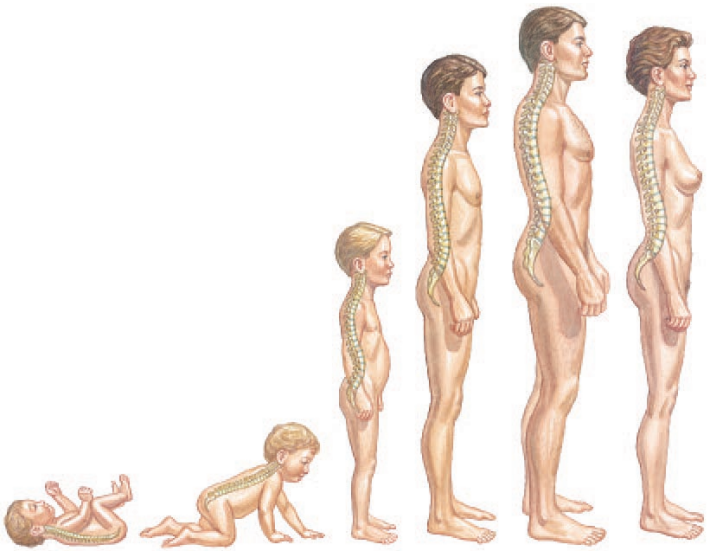

FIGURE 6.33 The development of the vertebral curves. An infant is born with the two primary curves but does not develop the secondary curves until it begins sitting upright and walking. (Note the differences in the curves between the sexes.)

Objective 12 Identify the bones of the five regions of the vertebral column and describe the characteristic curves of each region.

Objective 13 Describe the structure of a typical vertebra.

The **vertebral column** ("backbone") and the *spinal cord* of the nervous system constitute the *spinal column*. The vertebral column has four functions:

1. to support the head and upper extremities while permitting freedom of movement;
2. to enable bipedalism;
3. to provide attachment for various muscles, ribs, and visceral organs; and
4. to protect the spinal cord and permit passage of the spinal nerves.

The vertebral column is typically composed of 33 individual vertebrae, some of which are fused. There are 7 **cervical,** 12 **thoracic,** 5 **lumbar,** 3 to 5 fused **sacral,** and 4 or 5 fused **coccygeal** (*kok-sij′e-al*) **vertebrae;** thus, the adult vertebral column is composed of a total of 26 movable parts. Vertebrae are separated by fibrocartilaginous intervertebral discs and are secured to each other by interlocking processes and binding ligaments. This structural arrangement permits only limited movement between adjacent vertebrae but extensive movement for the vertebral column as a whole. Between the vertebrae are openings called **intervertebral foramina** that allow passage of spinal nerves.

When viewed from the side, four curvatures of the vertebral column can be identified (fig. 6.32). The **cervical, thoracic,** and **lumbar curves** are identified by the type of vertebrae they include. The **pelvic curve** (sacral curve) is formed by the shape of the sacrum and coccyx (*kok′siks*). The curves of the vertebral column play an important functional role in increasing the strength and maintaining the balance of the upper part of the body; they also make possible a bipedal stance.

The four vertebral curves are not present in an infant. The cervical curve begins to develop at about 3 months as the baby begins holding up its head, and it becomes more pronounced as the baby learns to sit up (fig. 6.33). The lumbar curve develops as a child begins to walk. The thoracic and pelvic curves are called *primary curves* because they retain the shape of the fetus. The cervical and lumbar curves are called *secondary curves* because they are modifications of the fetal shape.

General Structure of Vertebrae

Vertebrae are similar in their general structure from one region to another. A typical vertebra consists of an anterior drum-shaped **body,** which is in contact with intervertebral discs above and below (fig. 6.34). The **vertebral arch** is attached to the posterior surface of the body and is composed of two supporting **pedicles** (*ped′ĭ-kulz*) and two arched **laminae** (*lam′ĭ-ne*). The space formed by the vertebral arch and body is the **vertebral foramen,** through which the spinal cord passes. Between the pedicles of adjacent vertebrae are the **intervertebral foramina,** through which spinal nerves emerge as they branch off the spinal cord.

pedicle: L. *pediculus*, small foot
lamina: L. *lamina*, thin layer

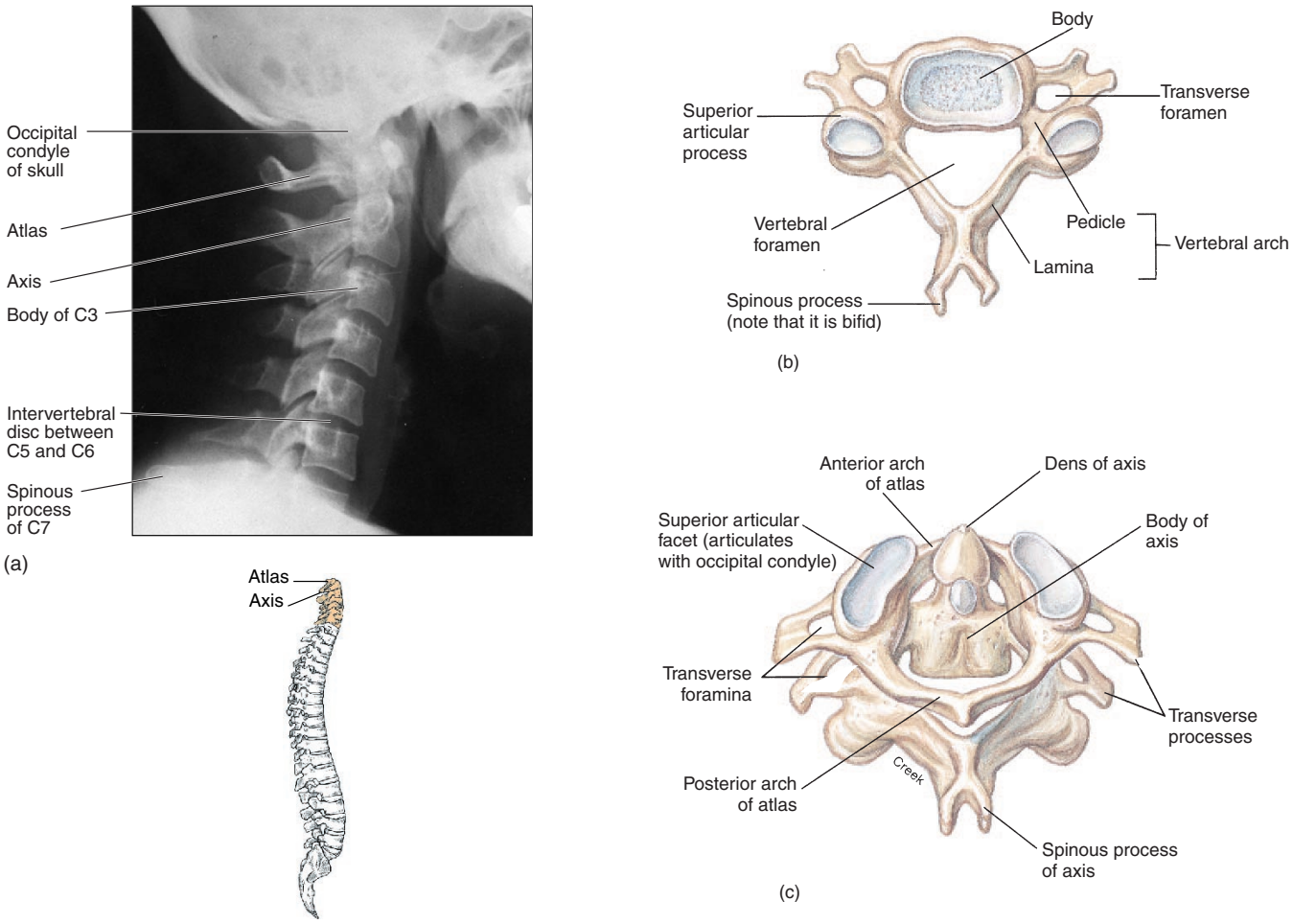

FIGURE 6.34 Cervical vertebrae. (*a*) A radiograph of the cervical region, (*b*) a superior view of a typical cervical vertebra, and (c) the articulated atlas and axis.

Seven processes arise from the vertebral arch of a typical vertebrae: the **spinous process,** two **transverse processes,** two **superior articular processes,** and two **inferior articular processes** (fig. 6.35). The spinous process and transverse processes serve for muscle attachment and the superior and inferior articular processes limit twisting of the vertebral column. The spinous process protrudes posteriorly and inferiorly from the vertebral arch. The transverse processes extend laterally from each side of a vertebra at the point where the lamina and pedicle join. The superior articular processes of a vertebra interlock with the inferior articular processes of the bone above.

A *laminectomy* is the surgical removal of the spinous processes and their supporting vertebral laminae in a particular region of the vertebral column. A laminectomy may be performed to relieve pressure on the spinal cord or nerve root caused by a blood clot, a tumor, or a herniated (ruptured) disc. It may also be performed on a cadaver to expose the spinal cord and its surrounding meninges.

Regional Characteristics of Vertebrae

Cervical Vertebrae

The seven cervical vertebrae form a flexible framework for the neck and support the head. The bone tissue of cervical vertebrae is more dense than that found in the other vertebral regions, and, except for those in the coccygeal region, the cervical vertebrae are smallest. Cervical vertebrae are distinguished by the presence of a **transverse foramen** in each transverse process (fig. 6.34). The vertebral arteries and veins pass through this opening as they contribute to the blood flow associated with the brain. Cervical vertebrae C2–C6 generally have a *bifid*, or notched, spinous process. The bifid spinous processes increase the surface area for attachment of the strong *nuchal ligament* that attaches to the back of the skull. The first cervical vertebra has no spinous process, and the process of C7 is not bifid and is larger than those of the other cervical vertebrae.

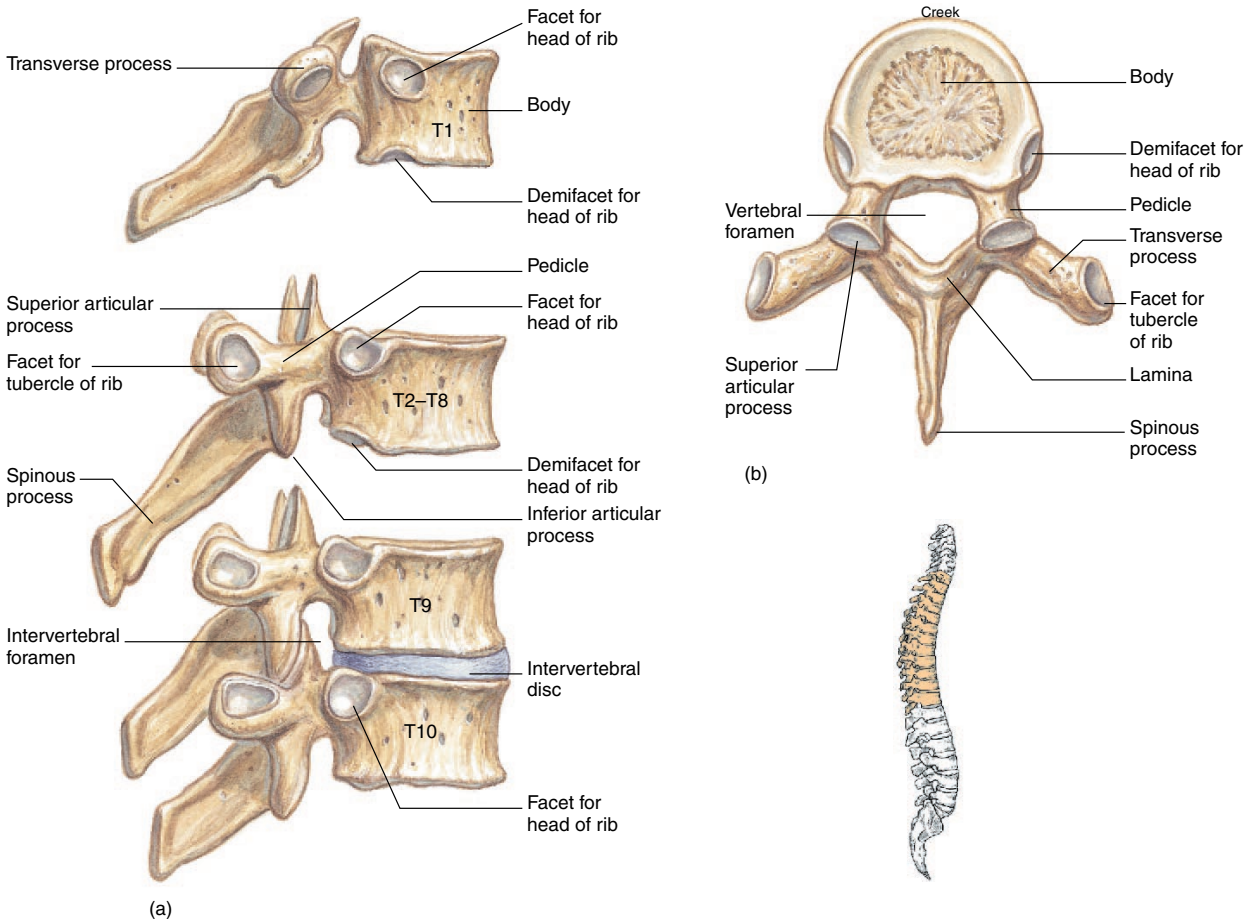

FIGURE 6.35 Thoracic vertebrae. Representative vertebrae in (*a*) a lateral view and (*b*) a superior view.

The **atlas** is the first cervical vertebra (sometimes called cervical 1 or C1). The atlas lacks a body, but it does have a short, rounded spinous process called the **posterior tubercle.** It also has cupped **superior articular surfaces** that articulate with the oval occipital condyles of the skull. This *atlanto-occipital joint* supports the skull and permits the nodding of the head in a "yes" movement.

The **axis** is the second cervical vertebra (C2). It has a peg-like **dens** (*odontoid process*) for rotation with the atlas in turning the head from side to side, as in a "no" movement.

Whiplash is a common term for any injury to the neck. Muscle, bone, or ligament injury in this portion of the spinal column is relatively common in individuals involved in automobile accidents and sports injuries. Joint dislocation occurs commonly between the fourth and fifth or fifth and sixth cervical vertebrae, where neck movement is greatest. Bilateral dislocations are particularly dangerous because of the probability of spinal cord injury. Compression fractures of the first three cervical vertebrae are common and follow abrupt forced flexion of the neck. Fractures of this type may be extremely painful because of pinched spinal nerves.

atlas: from Gk. mythology, Atlas—the Titan who supported the heavens

axis: L. *axis*, axle

odontoid: Gk. *odontos*, tooth

Thoracic Vertebrae

Twelve thoracic vertebrae articulate with the ribs to form the posterior anchor of the rib cage. Thoracic vertebrae are larger than cervical vertebrae and increase in size from superior (T1) to inferior (T12). Each thoracic vertebra has a long spinous process, which slopes obliquely downward, and facets (*fovea*) for articulation with the ribs (fig. 6.35).

Lumbar Vertebrae

The five lumbar vertebrae are easily identified by their heavy bodies and thick, blunt spinous processes (fig. 6.36) for attachment of powerful back muscles. They are the largest vertebrae of

lumbar: L. *lumbus*, loin

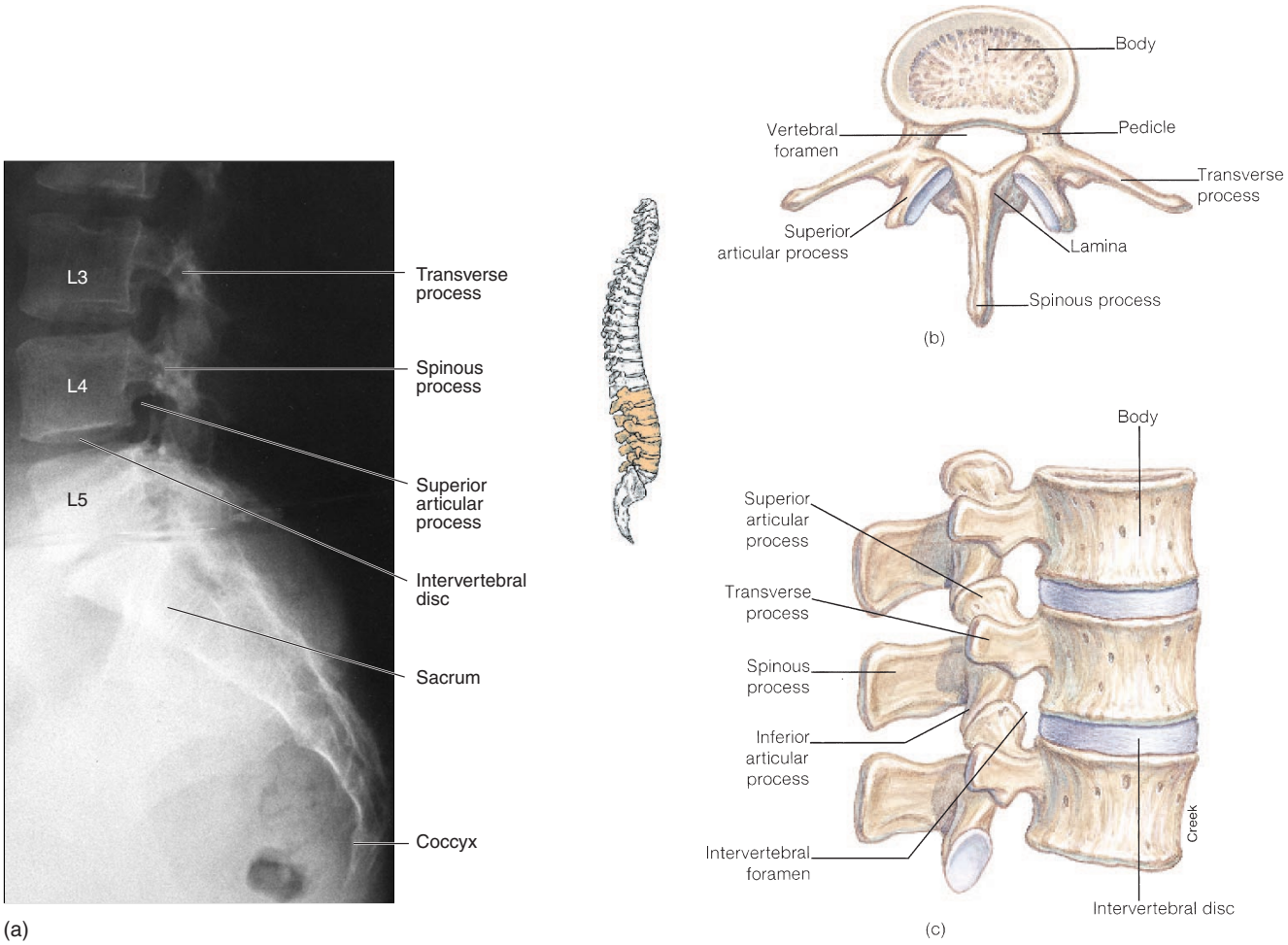

FIGURE 6.36 Lumbar vertebrae. (*a*) A radiograph, (*b*) a superior view, and (*c*) a lateral view.

the vertebral column. Their articular processes are also distinctive in that the facets of the superior pair are directed medially instead of posteriorly and the facets of the inferior pair are directed laterally instead of anteriorly.

Sacrum

The wedge-shaped sacrum provides a strong foundation for the pelvic girdle. It consists of four or five sacral vertebrae (fig. 6.37) that become fused after age 26. The sacrum has an extensive **auricular surface** on each lateral side for the formation of a slightly movable **sacroiliac** (*sak''ro-il'e-ak*) **joint** with the ilium of the hip. A **median sacral crest** is formed along the posterior surface by the fusion of the spinous processes. **Posterior sacral foramina** on either side of the crest allow for the passage of nerves from the spinal cord. The **sacral canal** is the tubular cavity within the sacrum that is continuous with the vertebral canal. Paired **superior articular processes,** which articulate with the fifth lumbar vertebra, arise from the roughened **sacral tuberosity** along the posterior surface.

The smooth anterior surface of the sacrum forms the posterior surface of the pelvic cavity. It has four **transverse lines** denoting the fusion of the vertebral bodies. At the ends of these lines are the paired **pelvic foramina (anterior sacral foramina).** The superior border of the anterior surface of the sacrum, called the **sacral promontory** (*prom'on-tor''e*), is an important obstetric landmark for pelvic measurements.

Coccyx

The triangular coccyx ("tailbone") is composed of three to five fused coccygeal vertebrae. The first vertebra of the fused coccyx has two

sacrum: L. *sacris*, sacred

coccyx: Gk. *kokkyx*, like a cuckoo's beak

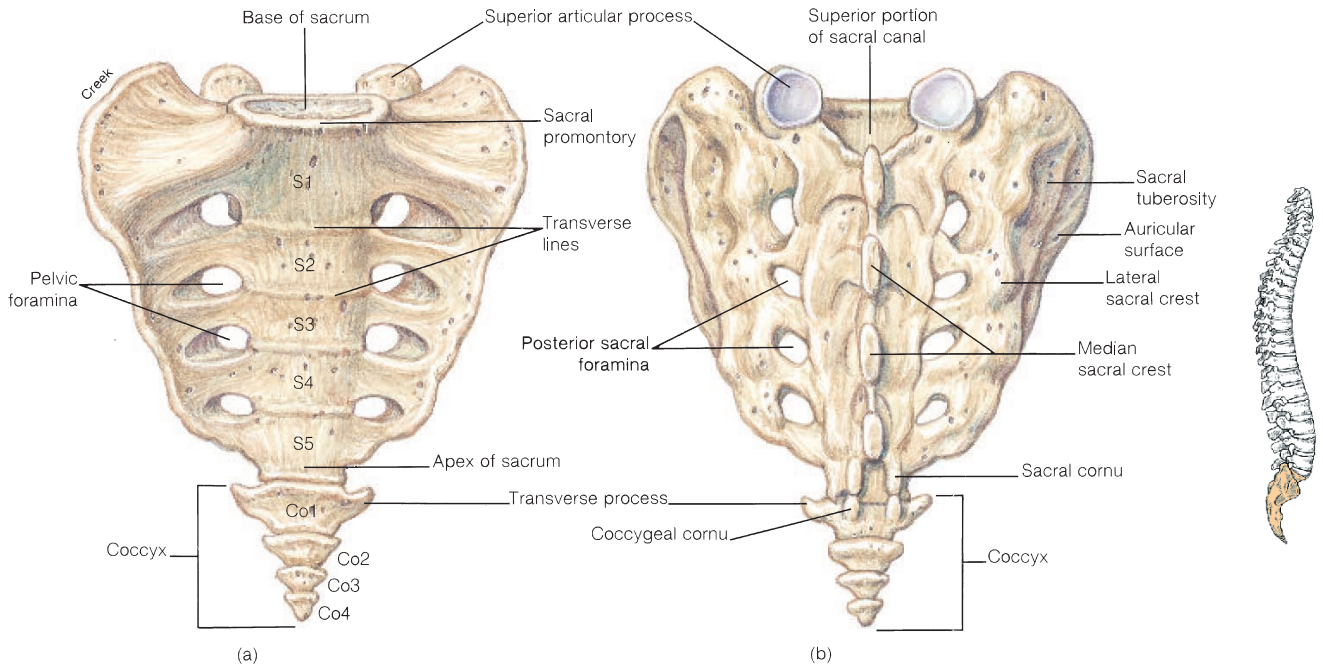

FIGURE 6.37 The sacrum and coccyx. (*a*) An anterior view and (*b*) a posterior view.

long **coccygeal cornua,** which are attached by ligaments to the sacrum (fig. 6.37). Lateral to the cornua are the transverse processes.

Distinct losses in height occur during middle and old age. Between the ages of 50 and 55, there is a decrease of 0.5 to 2.0 cm (0.25 to 0.75 in.) because of compression and shrinkage of the intervertebral discs. Elderly individuals may suffer a further loss of height because of osteoporosis (see Clinical Considerations at the end of this chapter).

The regions of the vertebral column are summarized in table 6.7.

When a person sits, the coccyx flexes anteriorly, acting as a shock absorber. An abrupt fall on the coccyx, however, may cause a painful subperiosteal bruising, fracture, or fracture-dislocation of the sacrococcygeal joint. An especially difficult childbirth can even injure the coccyx of the mother. Coccygeal trauma is painful and may require months to heal.

Knowledge Check

17. Which are the primary curves of the vertebral column and which are the secondary curves? Describe the characteristic curves of each region.
18. What is the function of the transverse foramina of the cervical vertebrae?
19. Describe the diagnostic differences between a thoracic and a lumbar vertebra. Which structures are similar and could therefore be characteristic of a typical vertebra?

TABLE 6.7 Regions of the Vertebral Column

Region	Number of Bones	Diagnostic Features
Cervical	7	Transverse foramina; superior facets of atlas articulate with occipital condyle; dens of axis; spinous processes of third through sixth vertebrae are generally bifid
Thoracic	12	Long spinous processes that slope obliquely downward; facets for articulation with ribs
Lumbar	5	Large bodies; prominent transverse processes; short, thick spinous processes
Sacrum	4 or 5 fused vertebrae	Extensive auricular surface; median sacral crest; posterior sacral foramina; sacral promontory; sacral canal
Coccyx	3 to 5 fused vertebrae	Small and triangular; coccygeal cornua

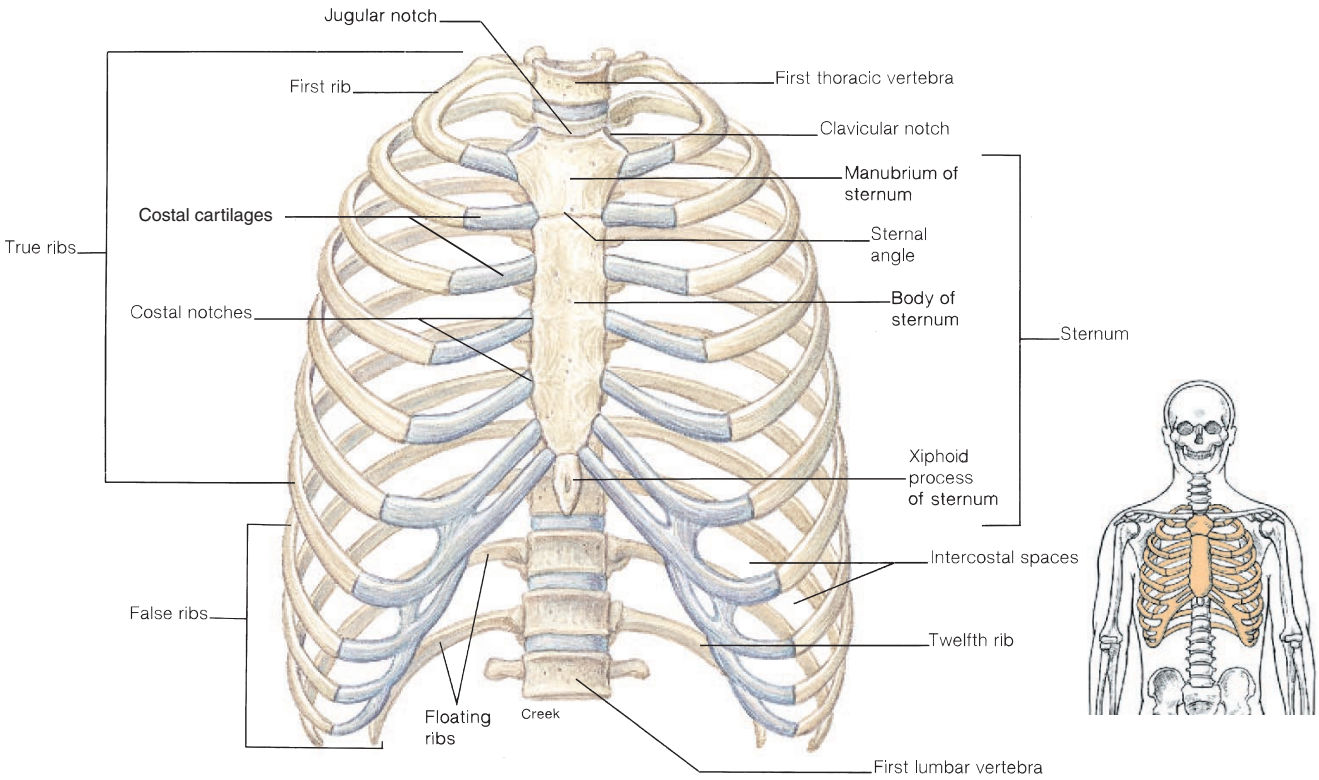

FIGURE 6.38 The rib cage.

RIB CAGE

The cone-shaped, flexible rib cage consists of the thoracic vertebrae, 12 paired ribs, costal cartilages, and the sternum. It encloses and protects the thoracic viscera and is directly involved in the mechanics of breathing.

Objective 14 Identify the parts of the rib cage and compare and contrast the various types of ribs.

The *sternum* ("breastbone"), *ribs*, *costal cartilages*, and the previously described thoracic vertebrae form the **rib cage** (fig. 6.38). The rib cage is anteroposteriorly compressed and more narrow superiorly than inferiorly. It supports the pectoral girdle and upper extremities, protects and supports the thoracic and upper abdominal viscera, and plays a major role in breathing (see fig. 9.21). Certain bones of the rib cage contain active sites in the bone marrow for the production of red blood cells.

Sternum

The **sternum** is an elongated, flattened bony plate consisting of three separate bones: the upper **manubrium,** (*mă-noo'bre-um*), the central **body,** and the lower **xiphoid** (*zif'oid; zi'foid*) **process.** The xiphoid process is often cartilaginous. On the lateral sides of the sternum are **costal notches** where the costal cartilages attach. A **jugular notch** is formed at the superior end of the manubrium, and a **clavicular notch** for articulation with the clavicle is present on both sides of the sternal notch. The manubrium articulates with the costal cartilages of the first and second ribs. The body of the sternum attaches to the costal cartilages of the sec-

sternum: Gk. *sternon*, chest
manubrium: L. *manubrium*, a handle
xiphoid: Gk. *xiphos*, sword
costal: L. *costa*, rib

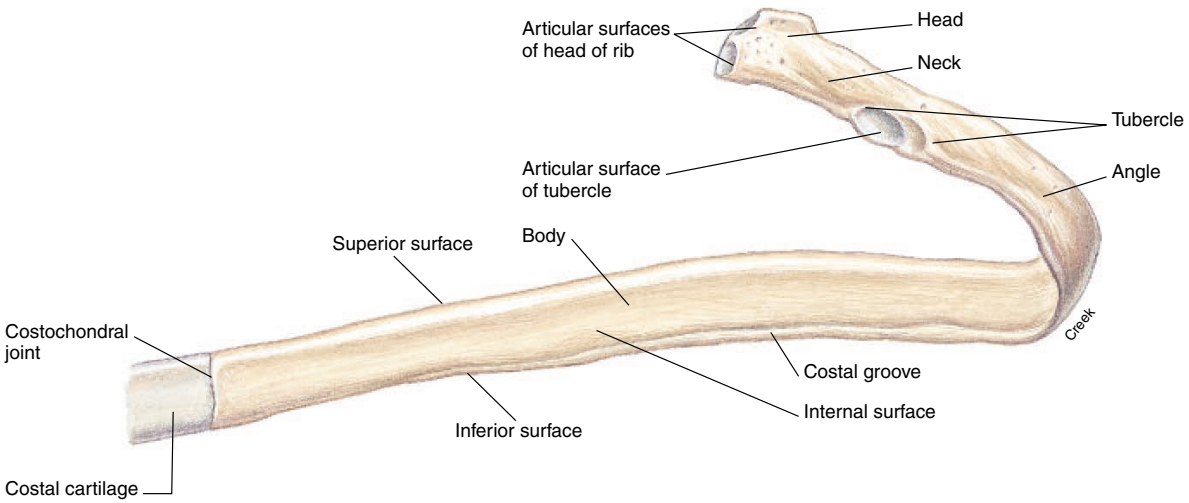

FIGURE 6.39 The structure of a rib.

ond through the tenth ribs. The xiphoid process does not attach to ribs but is an attachment for abdominal muscles. The costal cartilages of the eighth, ninth, and tenth ribs fuse to form the **costal margin** of the rib cage. A **costal angle** is formed where the two costal margins come together at the xiphoid process. The **sternal angle** (angle of Louis) may be palpated as an elevation between the manubrium and body of the sternum at the level of the second rib (fig. 6.38). The costal angle, costal margins, and sternal angle are important surface landmarks of the thorax and abdomen (see figs. 10.19 and 10.20).

Ribs

Embedded in the muscles of the body wall are 12 pairs of **ribs,** each pair attached posteriorly to a thoracic vertebra. Anteriorly, the first seven pairs are anchored to the sternum by individual *costal cartilages;* these ribs are called **true ribs.** The remaining five pairs (ribs 8, 9, 10, 11, and 12) are termed **false ribs.** Because the last two pairs of false ribs do not attach to the sternum at all, they are referred to as **floating ribs.**

Although the ribs vary structurally, each of the first 10 pairs has a **head** and a **tubercle** for articulation with a vertebra. The last two have a head but no tubercle. In addition, each of the 12 pairs has a **neck, angle,** and **body** (fig. 6.39). The head projects posteriorly and articulates with the body of a thoracic vertebra (fig. 6.40). The tubercle is a knoblike process, just lateral to the head. It articulates with the facet on the transverse process of a thoracic vertebra. The neck is the constricted area between the head and the tubercle. The body is the curved main part of the rib. Along the inner surface of the body is a depressed canal called the **costal groove** that protects the costal vessels and nerve. Spaces between the ribs are called **intercostal spaces** and are occupied by the intercostal muscles.

Fractures of the ribs are relatively common, and most frequently occur between ribs 3 and 10. The first two pairs of ribs are protected by the clavicles; the last two pairs move freely and will give with an impact. Little can be done to assist the healing of broken ribs other than binding them tightly to limit movement.

Knowledge Check

20. Describe the rib cage and list its functions. What determines whether a rib is true, false, or floating?
21. Distinguish between the costal margin and costal angle.

CLINICAL CONSIDERATIONS

Each bone is a dynamic living organ that is influenced by hormones, diet, aging, and disease. Because the development of bone is genetically controlled, congenital abnormalities may occur. The hardness of bones gives them strength, yet they lack the resiliency to avoid fracture when they undergo severe

angle of Louis: from Pierre C. A. Louis, French physician, 1787–1872

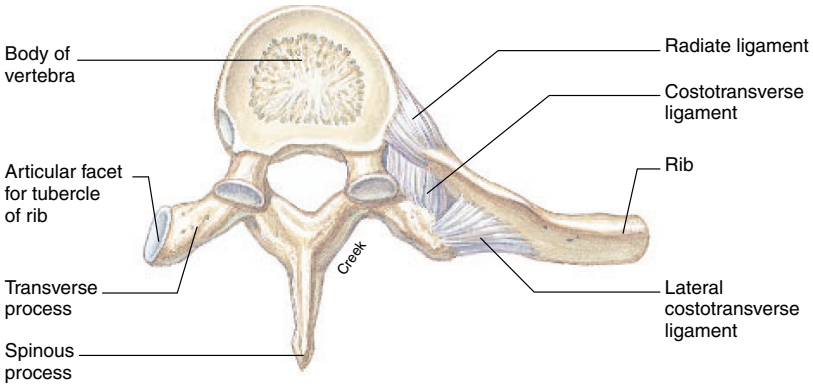

FIGURE 6.40 Articulation of a rib with a thoracic vertebra as seen in a superior view.

trauma. (Fractures are discussed in chapter 7 and joint injuries are discussed in chapter 8.) All of these aspects of bone make for some important and interesting clinical considerations.

Developmental Disorders

Congenital malformations account for several types of skeletal deformities. Certain bones may fail to form during osteogenesis, or they may form abnormally. **Cleft palate** and **cleft lip** are malformations of the palate and face. They vary in severity and seem to involve both genetic and environmental factors. **Spina bifida** (*spĭ′ nă bif′ĭ-dă*) is a congenital defect of the vertebral column resulting from a failure of the laminae of the vertebrae to fuse, leaving the spinal cord exposed (fig. 6.41). The lumbar area is most likely to be affected, and frequently only a single vertebra is involved.

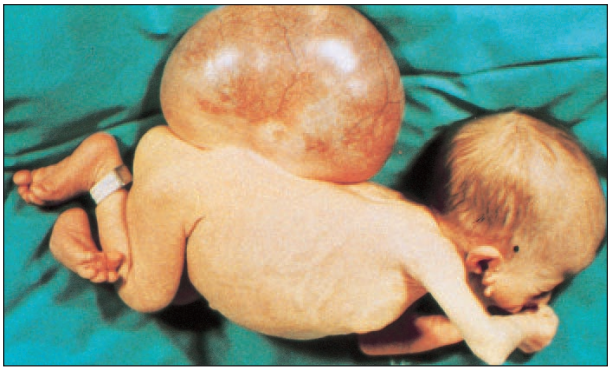

FIGURE 6.41 In spina bifida, failure of the vertebral arches to fuse permits a herniation of the meninges that cover the spinal cord through the vertebral column. This results in a condition called meningomyelocele.

Nutritional and Hormonal Disorders

Several bone disorders result from nutritional deficiencies or from excessive or deficient amounts of the hormones that regulate bone development and growth. Vitamin D has a tremendous influence on bone structure and function. When there is a deficiency of this vitamin, the body is unable to metabolize calcium and phosphorus. Vitamin D deficiency in children causes **rickets.** The bones of a child with rickets remain soft and structurally weak, and bend under the weight of the body (see fig. 5.11).

A vitamin D deficiency in the adult causes the bones to give up stored calcium and phosphorus. This demineralization results in a condition called **osteomalacia** (*os′′te-o-mă-la′sha*). Osteomalacia occurs most often in malnourished women who have repeated pregnancies and who experience relatively little exposure to sunlight. It is marked by increasing softness of the bones, so that they become flexible and thus cause deformities.

The consequences of endocrine disorders are described in chapter 14. Because hormones exert a strong influence on bone development, however, a few endocrine disorders will be briefly mentioned here. Hypersecretion of growth hormone from the pituitary gland leads to **gigantism** in young people if it begins before ossification of their epiphyseal plates. In adults, it leads to **acromegaly** (*ak′′ro-meg′ă-le*), which is characterized by hypertrophy of the bones of the face, hands, and feet. In a child, growth hormone deficiency results in slowed bone growth—a condition called **dwarfism.**

Paget's disease, a bone disorder that affects mainly older adults, occurs more frequently in males than in females. It is characterized by disorganized metabolic processes within bone

Paget's disease: from Sir James Paget, English surgeon, 1814–99

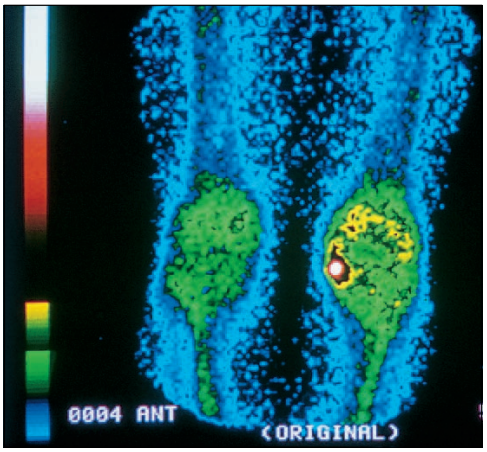

FIGURE 6.42 A bone scan of the legs of a patient suffering from arthritis in the left knee joint. In a bone scan, an image of an arthritic joint shows up lighter than most of a normal joint.

tissue. The activity of osteoblasts and osteoclasts becomes irregular, resulting in thick bony deposits in some areas of the skeleton and fragile, thin bones in other areas. The vertebral column, pelvis, femur, and skull are most often involved, and become increasingly painful and deformed. Bowed leg bones, abnormal curvature of the spine, and enlargement of the skull may develop. The cause of Paget's disease is currently not known.

Neoplasms of Bone

Malignant bone tumors are three times more common than benign tumors. Pain is the usual symptom of either type of osseous neoplasm, although benign tumors may not have accompanying pain.

Two types of benign bone tumors are **osteomas,** which are the more frequent and which often involve the skull, and **osteoid osteomas,** which are painful neoplasms of the long bones, usually in children.

Osteogenic sarcoma (*sar-ko′mā*) is the most virulent type of bone cancer. It frequently metastasizes through the blood to the lungs. This disease usually originates in the long bones and is accompanied by aching and persistent pain.

A **bone scan** (fig. 6.42) is a diagnostic procedure frequently done on a person who has had a malignancy elsewhere in the body that may have metastasized to the bone. The patient receiving a bone scan may be injected with a radioactive substance that accumulates more rapidly in malignant tissue than in normal tissue. Entire body radiographs show malignant bone areas as intensely dark dots.

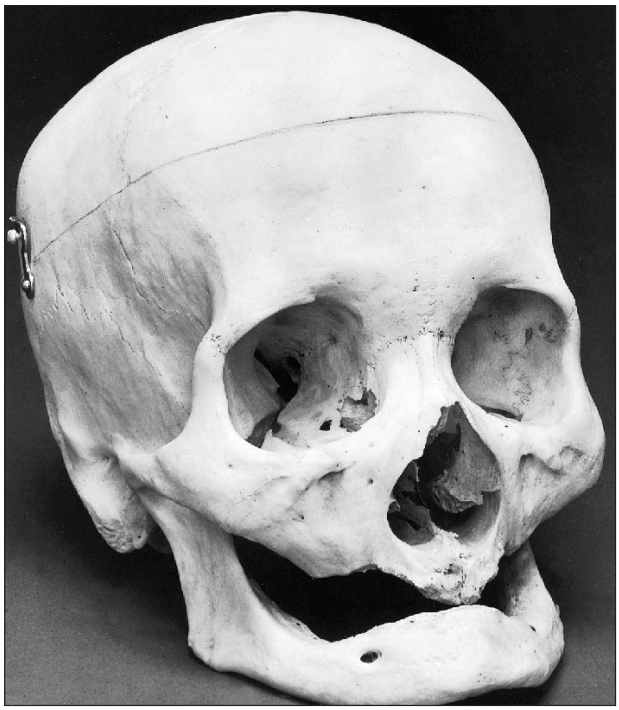

FIGURE 6.43 A geriatric skull. Note the loss of teeth and the degeneration of bone, particularly in the facial region.

Aging of the Skeletal System

Senescence affects the skeletal system by decreasing skeletal mass and density and increasing porosity and erosion (fig. 6.43). Bones become more brittle and susceptible to fracture. Articulating surfaces also deteriorate, contributing to arthritic conditions. Arthritic diseases are second to heart disease as the most common debilitation in the elderly.

Osteoporosis (*os″te-o-pŏ-ro′sis*) is a weakening of the bones, primarily as a result of calcium loss. The causes of osteoporosis include aging, inactivity, poor diet, and an imbalance in hormones or other chemicals in the blood. It is most common in older women because low levels of estrogens after menopause lead to increased bone resorption, and the formation of new bone is not sufficient to keep pace. People with osteoporosis are prone to bone fracture, particularly at the pelvic girdle and vertebrae, as the bones become too brittle to support the weight of the body. Complications of hip fractures often lead to permanent disability, and vertebral compression fractures may produce a permanent curved deformity of the spine.

Although there is no known cure for osteoporosis, good eating habits and a regular program of exercise, established at an early age and continued throughout adulthood, can minimize its

effects. Treatment in women through dietary calcium, exercise, and estrogens has had limited positive results. In addition, a drug called *alendronate* (Fosamax), approved by the FDA in 1995, has been shown to be effective in managing osteoporosis. This drug works without hormones to block osteoclast activity, making it useful for women who choose not to be treated with estrogen replacement therapy.

Clinical Case Study Answer

The height (overall length) of the vertebral column is equal to the sum of the thicknesses of the vertebrae plus the sum of the thicknesses of the intervertebral discs. The body of a vertebra consists of outer compact bone and inner spongy bone. An intervertebral disc consists of a fibrocartilage sheath called the *anulus fibrosus* and a mucoid center portion called the *nucleus pulposus*. The intervertebral discs generally change their anatomical configuration as one ages. In early adulthood, the nucleus pulposus is spongy and moist. With advanced age, however, it desiccates, resulting in a flattening of the intervertebral disc. Collectively, the intervertebral discs account for 25% of the height of the vertebral column. As they flatten with age, there is a gradual decrease in a person's overall height. Height loss may also result from undetectable compression fractures of the vertebral bodies, which are common in elderly people. This phenomenon, however, is considered pathological and is not an aspect of the normal aging process. In a person with osteoporosis, there is often a marked decrease in height and perhaps more serious clinical problems as well, such as compression of spinal nerves.

CLINICAL PRACTICUM 6.1

A 50-year-old male is brought to the emergency room by his spouse because he is acting strangely. She states that he has been ill for several days, but in the past 24 to 48 hours, he has become forgetful, less communicative, and sleepy. He had been complaining of a headache, which was localized to the front of his head and face, and a fever for several days. His wife reports a history of sinus infections. Physical examination reveals a fever, frontal tenderness, and altered mental status. You order a head CT. Two representative images are shown here.

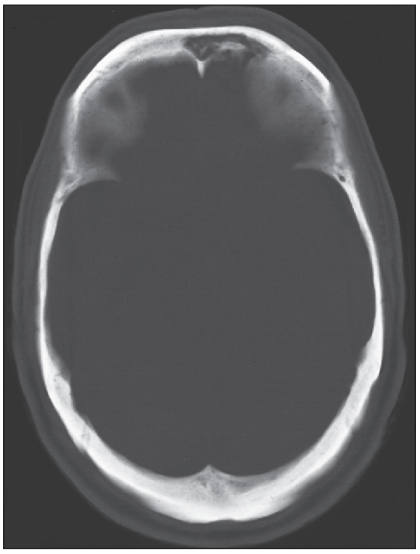

QUESTIONS

1. What abnormalities do you observe in the CT?
2. Where is the fluid in the right subdural space (see arrow) coming from?
3. What is the diagnosis?
4. What is your suggested course of treatment?

CLINICAL PRACTICUM 6.2

A 53-year-old male is injured in an automobile accident. He was wearing his seat belt when the accident occurred. The paramedics stabilize his spine and bring him to the emergency room. He is complaining of low back pain. You examine the patient and note that he has decreased strength and sensation in both legs, as well as tenderness in the small of his back. A radiograph of the lumbar spine as well as a CT scan are obtained.

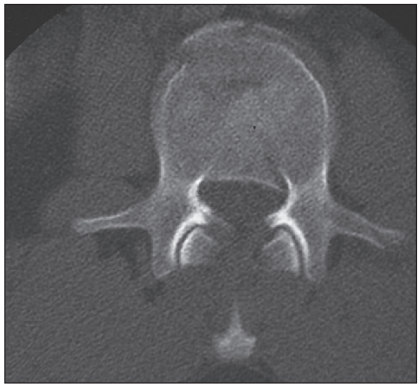

QUESTIONS

1. What is the patient's injury?
2. Why does the patient have neurological symptoms in his legs?
3. How does the seat belt contribute to this injury?

Important Clinical Terminology

achondroplasia (*ă-kon''dro-pla'ze-ă*) A genetic defect that inhibits formation of cartilaginous bone during fetal development.

craniotomy Surgical cutting into the cranium to provide access to the brain.

epiphysiolysis (*ep''ĭ-fiz''e-ol'ĭ-sis*) A separation of the epiphysis from the diaphysis of a growing long bone.

laminectomy The surgical removal of the posterior arch of a vertebra, usually to repair a herniated intervertebral disc.

orthopedics The branch of medicine concerned with the diagnosis and treatment of trauma, diseases, and abnormalities involving the skeletal and muscular systems.

osteitis (*os-te-ĭ tis*) An inflammation of bone tissue.

osteoblastoma (*os''te-o-blas-to'mā*) A benign tumor produced from bone-forming cells, most frequently in the vertebrae of young children.
osteochondritis (*os''te-o-kon-dri'tis*) An inflammation of bone and cartilage tissues.
osteomyelitis (*os''te-o-mi''ĕ-lĭtis*) An inflammation of bone marrow caused by bacteria or fungi.
osteonecrosis (*os''te-o-nĕkro'sis*) The death of bone tissue, usually caused by obstructed arteries.
osteopathology The study of bone diseases.
osteosarcoma A malignant tumor of bone tissue.
osteotomy (*os''te-ot'ŏ-me*) The cutting of a bone, usually by means of a saw or a chisel.

Chapter Summary

Organization of the Skeletal System (pp. 132–134)

1. The axial skeleton consists of the skull, auditory ossicles, hyoid bone, vertebral column, and rib cage.
2. The appendicular skeleton consists of the bones within the pectoral girdle, upper extremities, pelvic girdle, and lower extremities.

Functions of the Skeletal System (pp. 134–135)

1. The mechanical functions of bones include the support and protection of softer body tissues and organs. In addition, certain bones function as levers during body movement.
2. The metabolic functions of bones include hemopoiesis and storage of fat and minerals.

Bone Structure (pp. 135–138)

1. Bone structure includes the shape and surface features of each bone, along with gross internal components.
2. Bones may be structurally classified as long, short, flat, or irregular.
3. The surface features of bones are classified as articulating surfaces, nonarticulating prominences, and depressions and openings.
4. A typical long bone has a diaphysis, or shaft, filled with marrow in the medullary cavity; epiphyses; epiphyseal plates for linear growth; and a covering of periosteum for appositional growth and the attachments of ligaments and tendons.

Bone Tissue (pp. 138–140)

1. Compact bone is the dense outer portion; spongy bone is the porous, vascular inner portion.
2. The five types of bone cells are osteogenic cells, in contact with the endosteum and periosteum; osteoblasts (bone-forming cells); osteocytes (mature bone cells); osteoclasts (bone-destroying cells); and bone-lining cells, along the surface of most bones.
3. In compact bone, the lamellae of osteons are the layers of inorganic matrix surrounding a central canal. Osteocytes are mature bone cells, located within capsules called lacunae.

Bone Growth (pp. 140–144)

1. Bone growth is an orderly process determined by genetics, diet, and hormones.
2. Most bones develop through endochondral ossification.
3. Bone remodeling is a continual process that involves osteoclasts in bone resorption and osteoblasts in the formation of new bone tissue.

Skull (pp. 144–158)

1. The eight cranial bones include the frontal (1), parietals (2), temporals (2), occipital (1), sphenoid (1), and ethmoid (1).
   (a) The cranium encloses and protects the brain and provides for the attachment of muscles.
   (b) Sutures are fibrous joints between cranial bones.
2. The 14 facial bones include the nasals (2), maxillae (2), zygomatics (2), mandible (1), lacrimals (2), palatines (2), inferior nasal conchae (2), and vomer (1).
   (a) The facial bones form the basic shape of the face, support the teeth, and provide for the attachment of the facial muscles.
   (b) The hyoid bone is located in the neck, between the mandible and the larynx.
   (c) The auditory ossicles (malleus, incus, and stapes) are located within each middle-ear chamber of the petrous part of the temporal bone.
3. The paranasal sinuses include the sphenoidal and ethmoidal sinuses in the sphenoid and ethmoid bones respectively in the cranial region and the frontal and maxillary sinuses in the frontal and maxillary bones respectively in the facial region.

Vertebral Column (pp. 158–163)

1. The vertebral column consists of 7 cervical, 12 thoracic, 5 lumbar, 4 or 5 fused sacral, and 3 to 5 fused coccygeal vertebrae.
2. Cervical vertebrae have transverse foramina; thoracic vertebrae have facets and demifacets for articulation with ribs; lumbar vertebrae have large bodies; sacral vertebrae are triangularly fused and contribute to the pelvic girdle; and the coccygeal vertebrae form a small triangular bone.

Rib Cage (pp. 164–165)

1. The sternum consists of a manubrium, body, and xiphoid process.
2. There are seven pairs of true ribs and five pairs of false ribs. The inferior two pairs of false ribs (pairs 11 and 12) are called floating ribs.

Review Activities

Objective Questions

1. A bone is considered to be
   (a) a tissue. (b) a cell.
   (c) an organ. (d) a system.
2. Which of the following statements is *false?*
   (a) Bones are important in the synthesis of vitamin D.
   (b) Bones and teeth contain about 99% of the body's calcium.
   (c) Red bone marrow is the primary site for hemopoiesis.
   (d) Most bones develop through endochondral ossification.

CHAPTER 6

3. Match each of the following foramina with the bone in which it occurs.
   1. foramen rotundum
   2. mental foramen
   3. carotid canal
   4. cribriform foramina
   5. foramen magnum
      (a) ethmoid bone
      (b) occipital bone
      (c) sphenoid bone
      (d) mandible
      (e) temporal bone
4. With respect to the hard palate, which of the following statements is *false?*
   (a) It is composed of two maxillae and two palatine bones.
   (b) It separates the oral cavity from the nasal cavity.
   (c) The mandible articulates with the posterolateral angles of the hard palate.
   (d) The median palatine suture, incisive foramen, and greater palatine foramina are three of its structural features.
5. The location of the sella turcica is immediately
   (a) superior to the sphenoidal sinus.
   (b) inferior to the frontal sinus.
   (c) medial to the petrous parts of the temporal bones.
   (d) superior to the perpendicular plate of the ethmoid bone.
6. Specialized bone cells that enzymatically reabsorb bone tissue are
   (a) osteoblasts. (b) osteocytes.
   (c) osteons. (d) osteoclasts.
7. The mandibular fossa is located in which structural part of the temporal bone?
   (a) the squamous part
   (b) the tympanic part
   (c) the mastoid part
   (d) the petrous part
8. The crista galli is a structural feature of which bone?
   (a) the sphenoid bone
   (b) the ethmoid bone
   (c) the palatine bone
   (d) the temporal bone
9. Transverse foramina are characteristic of
   (a) lumbar vertebrae.
   (b) sacral vertebrae.
   (c) thoracic vertebrae.
   (d) cervical vertebrae.
10. The bone disorder that frequently develops in elderly people, particularly if they experience prolonged inactivity, malnutrition, or a hormone imbalance is
    (a) osteitis. (b) osteonecrosis.
    (c) osteoporosis. (d) osteomalacia.

Essay Questions

1. What are the functions of the skeletal system? Do the individual bones of the skeleton carry out these functions equally? Explain.
2. Explain why there are approximately 270 bones in an infant but 206 bones in a mature adult.
3. List the bones of the skull that are paired. Which are unpaired? Identify the bones of the skull that can be palpated.
4. Describe the development of the skull. What are the fontanels, where are they located, and what are their functions?
5. Which facial bones contain foramina? What structures pass through these openings?
6. Distinguish between the axial and appendicular skeletons. Describe where these two components articulate.
7. List four types of bones based on shape and give an example of each type.
8. Diagram a typical long bone. Label the epiphyses, diaphysis, epiphyseal plates, medullary cavity, nutrient foramina, periosteum, and articular cartilages.
9. List the bones that form the cranial cavity, the orbit, and the nasal cavity. Describe the location of the paranasal sinuses, the mastoidal sinus, and the inner-ear cavity.
10. Describe how bones grow in length and width. How are these processes similar, and how do they differ? Explain how radiographs can be used to determine normal bone growth.
11. Explain the process of endochondral ossification of a long bone. Why is it important that a balance be maintained between osteoblast activity and osteoclast activity?
12. Describe the curvature of the vertebral column. What do the terms *primary curves* and *secondary curves* refer to?
13. List two or more characteristics by which vertebrae from each of the five regions of the vertebral column can be identified.
14. Identify the bones that form the rib cage. What functional role do the bones and the costal cartilages have in respiration?
15. Describe the nature of bones in each of the following age periods: newborn, teenager, adult, and elderly.

Critical-Thinking Questions

1. Many people think that the bones in our bodies are dead—understandable considering that we associate bones with graveyards, Halloween, and leftover turkey from a Thanksgiving dinner. Your kid brother is convinced of this. What information could you use to try to get him to change his mind?
2. The sensory organs involved with sight, smell, and hearing are protected by bone. Describe the locations of each of these sensory organs and list the associated bones that provide protection.
3. Explain why a proper balance of vitamins, hormones, and minerals is essential in maintaining healthy bone tissue. Give examples of diseases or skeletal conditions that may occur in the event of an imbalance of any of these three essential substances.
4. The most common surgical approach to a pituitary gland tumor is through the nasal cavity. With the knowledge that the pituitary gland is supported by the sella turcica of the braincase, list the bones that would be involved in the removal of the tumor.
5. The contour of a child's head is distinctly different from that of an adult. Which skull bones exhibit the greatest amount of change as a child grows to adulthood?
6. You read in *National Geographic* that a team of archaeologists recently completed an examination of 18 skeletons from people buried under tons of volcanic ash 1,200 years ago. By analyzing the bones, the scientists were able to determine the sex, physical health (including a partial medical history), approximate age, and even the general profession of each of the 18 individuals. How could the examination of a preserved skeleton yield such a vast array of information?

Visit our **Online Learning Center** at http://www.mhhe.com/vdg
for chapter-by-chapter quizzing, additional study resources, and related web links.