

# 10

## Surface and Regional Anatomy

Introduction to Surface  
Anatomy 297

Surface Anatomy  
of the Newborn 298

Head 300

Neck 306

Trunk 309

Pelvis and Perineum 318

Shoulder and Upper Extremity 319

Buttock and Lower Extremity 326

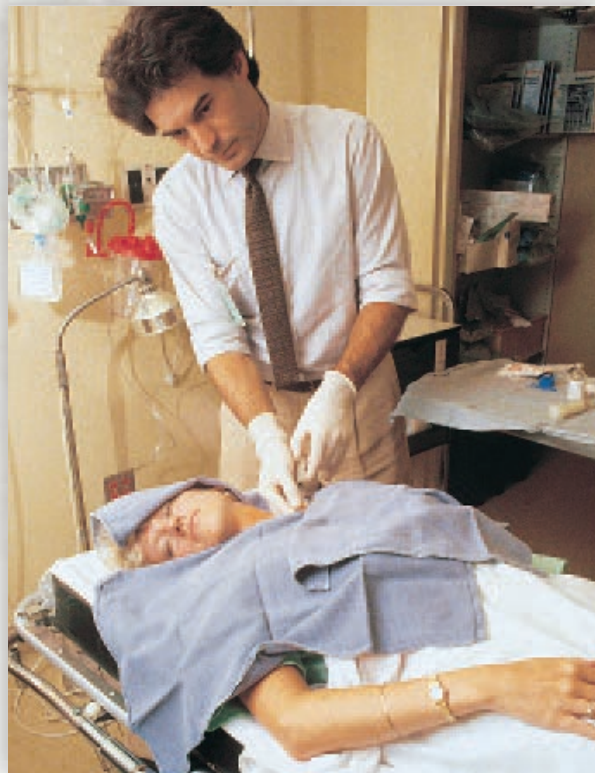---

CLINICAL CONSIDERATIONS 330

Clinical Case Study Answer 339

Chapter Summary 340

Review Activities 341



### Clinical Case Study

A 27-year-old female is brought to the emergency room following a motor vehicle accident. You examine the patient and find her to be alert but pale and sweaty, with breathing that is rapid and shallow. You see that she has distension of her right internal jugular vein visible to the jaw and neck. Her trachea is deviated 3 cm to the right of midline. She has tender contusions on her left anterior chest wall with minimal active bleeding over one of the ribs. During the brief period of your examination, the patient exhibits more respiratory distress, and her blood pressure begins to drop. You urgently insert a large-gauge needle into her left hemithorax and withdraw 20 cc of air. This results in immediate improvement in the patient's breathing and blood pressure.

Why does the patient have a distended internal jugular vein on the right side of her neck? Could this be related to a rapid drop in blood pressure? What is the clinical situation of this patient?

**Hint:** As you read this chapter, note that knowledge of normal surface anatomy is vital to the recognition of abnormal surface anatomy, and that the latter may be an easy clue to the pathology lying deep within the body.

**FIGURE:** In order to effectively administer medical treatment, it is imperative for a physician to know the surface anatomy of each body region and the functional interaction of the organs contained in each region.

## INTRODUCTION TO SURFACE ANATOMY

Surface anatomy, a branch of gross anatomy, is the study of the form and markings of the surface of the body as they relate to deeper structures. Knowledge of surface anatomy is essential in performing a physical examination, treating diseases or dysfunctions of the body, and maintaining physical fitness.

**Objective 1** Discuss the value of surface anatomy in learning about internal anatomical structures.

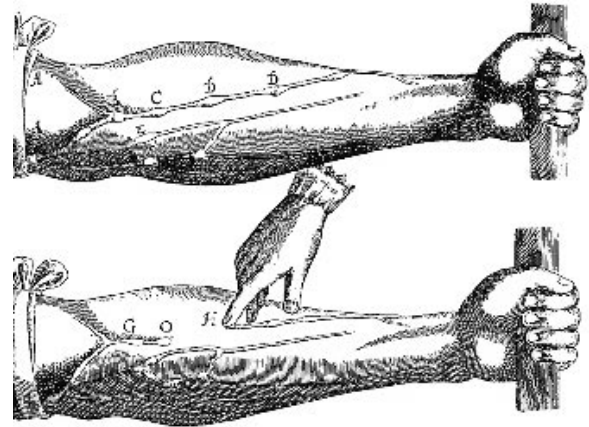
**Objective 2** Explain why surface anatomy is important in the diagnosis and treatment of diseases or dysfunctions of the body.

**Objective 3** Explain why individual differences in body physique may have a bearing on the effectiveness of observation and palpation.

It is amazing how much anatomical information you can acquire by examining the surface anatomy of your own body. Surface anatomy is the study of the structure and markings of the surface of the body through visual inspection or palpation. Surface features can be readily identified through *visual inspection*, and anatomical features beneath the skin can be located by *palpation* (feeling with firm pressure or perceiving by the sense of touch). Knowledge of surface anatomy is clinically important in locating precise sites for *percussion* (tapping sharply to detect resonating vibrations) and *auscultation* (listening to sounds emitted from organs).

With the exception of certain cranial bones, the bones of the entire skeleton can be palpated. Once the position, shape, and processes of these bones are identified, these skeletal features can serve as landmarks for locating other anatomical structures. Many of the skeletal muscles and their tendinous attachments are clearly visible as they are contracted and caused to move. The location and range of movement of the joints of the body can be determined as the articulating bones are moved by muscle contractions. On some individuals, the positions of superficial veins can be located and their courses traced. Even the location and function of the valves within the veins can be demonstrated on the surface of the skin (fig. 10.1). Some of the arteries also can be seen as they pulse beneath the skin. Knowing where the arterial pressure points are is an important clinical aspect of surface anatomy (see fig. 16.33). Other structures can be identified from the body surface, including certain nerves, lymph nodes, glands, and other internal organs.

Surface anatomy is an essential aspect of the study of internal gross anatomy. Knowing where muscles and muscle groups are located can be extremely important in maintaining physical fitness. In many medical and paramedical professions, the surface anatomy of a patient is of immeasurable value in diagnosis and treatment. Knowing where to record a pulse, insert needles and tubes, listen to the functioning of internal organs, take radiographs, and perform physical therapy requires a knowledge of surface landmarks.



**FIGURE 10.1** A demonstration of the presence and function of valves within the veins of the forearm, conducted by the great English anatomist William Harvey. In order to understand the concept of a closed circulatory system (e.g., blood contained within vessels), a knowledge of surface anatomy was essential.  
After William Harvey, *On the Motion of the Heart and Blood in Animals*, 1628.

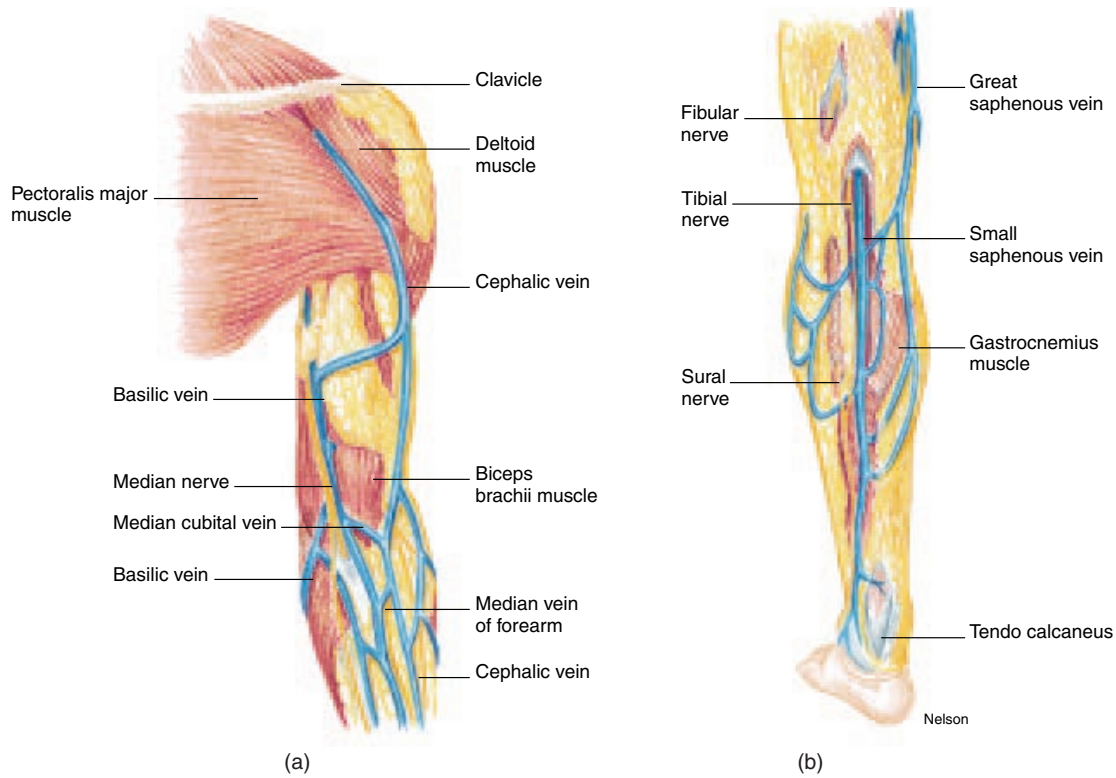
The effectiveness of observation and palpation in studying a person's surface anatomy is related to the amount of subcutaneous adipose tissue present (fig. 10.2). In examining an obese person, it may be extremely difficult to observe or palpate certain internal structures that are readily discernible in a thin person. The hypodermis of females is normally thicker than that of males (fig. 10.3). This tends to smooth the surface contours of females and obscure the muscles, veins, and bony prominences that are apparent in males.

This chapter will be of great value in reviewing the bones, articulations, and muscles you have already studied. In the photographs of dissected cadavers, you will be able to see the relationships between the various body organs and systems in specific regions. Refer back to this chapter as you study the anatomy of the remaining body systems. Reviewing in this way will broaden your perspective in locating various organs and structures.

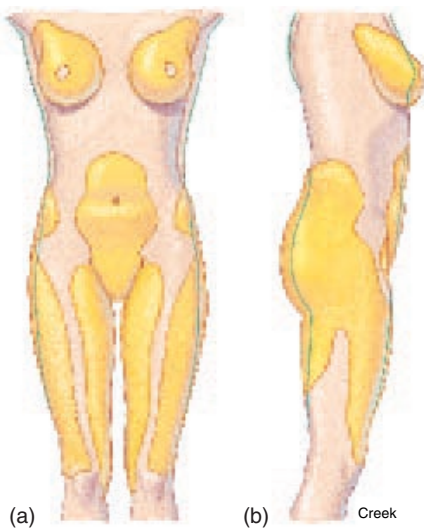
➤ If you use yourself as a model from which to learn and review, anatomy as a science will take on new meaning. As you learn about a bone or a process on a bone, palpate that part of your body. Contract the muscles you are studying so that you better understand their locations, attachments, and actions. In this way, you will become better acquainted with your body, and anatomy will become more enjoyable and easier to learn. Your body is one crib sheet you can take with you to exams.

## ✓ Knowledge Check

1. Explain what is meant by visual inspection and palpation, and discuss the value of surface anatomy in locating internal structures.
2. Why is a knowledge of surface anatomy important in a clinical setting?
3. How does the hypodermis of the skin differ in males and females? What are the clinical implications of this difference?



**FIGURE 10.2** Subcutaneous adipose tissue. (a) An anterior view of the left brachial region and (b) a posterior view of the left leg.



**FIGURE 10.3** Principal areas of adipose deposition of a female. (a) An anterior view and (b) a lateral view. The outline of a male is superposed in both views. There is significantly more adipose tissue interlaced in the fascia covering the muscles, vessels, and nerves in a female than in a male. The hypodermis layer of the skin is also approximately 8% thicker in a female than in a male.

## SURFACE ANATOMY OF THE NEWBORN

The surface anatomy of a newborn infant represents an early stage of human development; therefore, it differs from that of an adult. Certain aspects of the surface anatomy of a neonate are of clinical importance in ascertaining the degree of physical development, general health, and possible congenital abnormalities.

**Objective 4** Describe the surface anatomy of a normal, full-term neonate.

**Objective 5** List some of the internal structures that can be palpated in a neonate.

The birth of a baby is the dramatic culmination of a 9-month gestation, during which the miraculous development of the fetus prepares it for extrauterine life. Although the normal, full-term neonate is physiologically prepared for life, it is totally dependent on the care of others. The physical assessment of the neonate is extremely important to ensure its survival. Much of the assess-



**TABLE 10.1** Surface Anatomy of the Neonate

| Body Structure  | Normal Conditions                                                                                                | Common Variations                                                                                                                                   |
|-----------------|------------------------------------------------------------------------------------------------------------------|-----------------------------------------------------------------------------------------------------------------------------------------------------|
| General posture | Joints of vertebral column and extremities flexed                                                                | Extended legs and neck; abducted and rotated thighs (breech birth)                                                                                  |
| Skin            | Red or pink, with vernix caseosa and lanugo; edematous face, extremities, and genitalia                          | Neonatal jaundice; integumentary blisters; Mongolian spots                                                                                          |
| Skull           | Fontanels large, flat, and firm, but soft to the touch                                                           | Molded skull, bulging fontanels; cephalhematoma                                                                                                     |
| Eyes            | Lids edematous; color—gray, dark blue, or brown; absence of tears; corneal, pupillary, and blink reflexes        | Conjunctivitis, subconjunctival hemorrhage                                                                                                          |
| Ears            | Auricle flexible, with cartilage present; top of auricle positioned on horizontal line with outer canthus of eye | Auricle flat against head                                                                                                                           |
| Neck            | Short and thick, surrounded by neck folds                                                                        | Torticollis                                                                                                                                         |
| Chest           | Equal anteroposterior and lateral dimensions; xiphoid process evident; breast enlargement                        | Funnel or pigeon chest; additional nipples (polythelia); secretions from breast (witch's milk)                                                      |
| Abdomen         | Cylindric in shape; liver and kidneys palpable                                                                   | Umbilical hernia                                                                                                                                    |
| Genitalia       | (♂ and ♀) Edematous and darkly pigmented; (♂) testes palpable in scrotum; periodic erection of penis             | (♀) Blood-ringed discharge (pseudomenstruation); hymenal tag; (♂) testes palpable in inguinal canals; inability to retract prepuce; inguinal hernia |
| Extremities     | Symmetrical; 10 fingers and toes; soles flat with moderate to deep creases                                       | Partial syndactyly; asymmetric length of toes                                                                                                       |

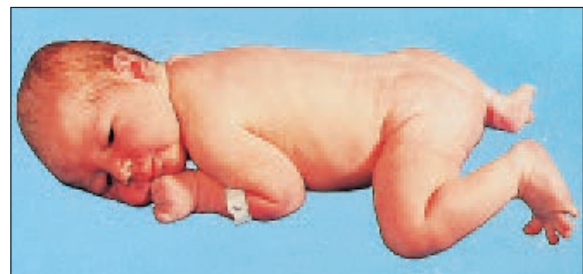
ment is performed through inspection and palpation of its surface anatomy. The surface anatomy of a neonate obviously differs from that of an adult because of the transitional stage of development from fetus to infant.

Although the surface anatomy of a neonate is discussed at this point in the text, prenatal development and body growth with its accompanying physiological changes are discussed in detail in chapter 22. A summary of the surface anatomy of the neonate is presented in table 10.1.

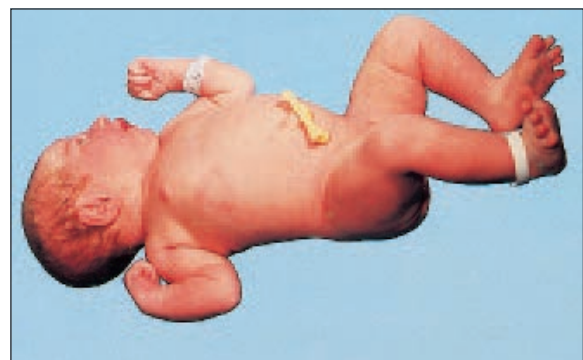## General Appearance

As a result of in utero position, the posture of the full-term neonate is one of flexion (fig. 10.4). The neonate born vertex (head first) keeps the neck and vertebral column flexed, with the chin resting on the upper chest. The hands are clenched into fists, the elbow joints are flexed, and the arms are held to the chest. The knee and hip joints are flexed, drawing the thighs toward the abdomen. The ankle joints are dorsiflexed.

The skin is the one organ of the neonate that is completely visible and is therefore a source of considerable information concerning its state of development and clinical condition. At birth, the skin is covered with a grayish, cheeselike substance called **vernix caseosa** (*ver'niks ka'se-o'sā*). If it is not washed away dur-

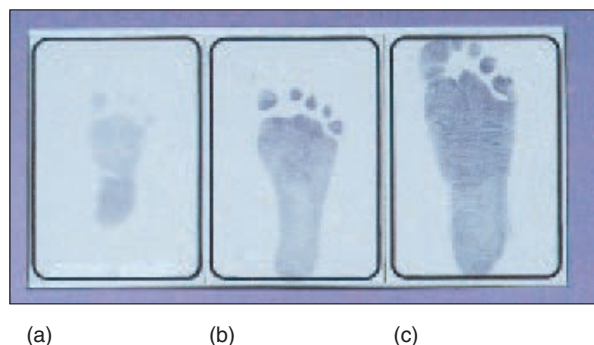


(a)




(b)

**FIGURE 10.4** The flexion position of a neonate (a, b) is an indication of a healthy gestation and a normal delivery.



**FIGURE 10.5** Sole creases at different ages of gestation as seen from footprints of two premature babies (a, b) and a full-term baby (c). (a) At 26 weeks of gestation, only an anterior transverse crease is present. (b) By 33 weeks, creases have developed along the medial instep. (c) The entire sole has developed creases by 38 weeks.

ing bathing, the vernix will dry and disappear within a couple of days. Fine, silklike hair called **lanugo** (*lă-noo'go*) may be present on the forehead, cheeks, shoulders, and back. Distended sebaceous glands called **milia** (*mil'e-ă*) may appear as tiny white papules on the nose, cheeks, and chin. Skin color depends on genetic background, although certain areas, such as the genitalia, areola, and linea alba may appear darker than the rest of skin because of a response to maternal and placental hormones that enter the fetal circulation. **Mongolian spots** occur in about 90% of newborn Blacks, Asians, and American Indians. These blue-gray pigmented areas vary in size and are usually located in the lumbosacral region. Mongolian spots generally fade within the first year or two.

 Abnormal skin color is clinically important in the physical assessment of the neonate. **Cyanosis** (*si'ă-no'sis*) (bluish discoloration) is usually due to a pulmonary disease (for example, atelectasis or pneumonia) or to congenital heart disease. Although **jaundice** (yellowish discoloration) is common in infants and is usually of no concern, it may indicate liver or bone marrow problems. **Pallor** (paleness) may indicate anemia, edema, or shock.

The appearance of the nails and nail beds is especially valuable in determining body dysfunctions, certain genetic conditions, and even normal gestations. Cyanosis, pallor, and capillary pulsations are best observed at the nails. Jaundice is common in postmature neonates and can be visibly detected by yellow nails.

Local edema (swelling) is not uncommon in the neonate, particularly in the skin of the face, legs, hands, feet, and genitalia. Creases on the palms of the hands and soles of the feet should be prominent; the absence of creases accompanies prematurity (fig. 10.5). The nose is usually flattened after birth and there may be bruises there, or on other areas of the face. The auricle of the ear is flexible, with the top edge positioned on a horizontal line with the outer canthus (corner) of the eye.

milia: *L. miliaris*, relating to millet

The neck of a neonate is short, thick, and surrounded by neck folds. The chest is rounded in cross section, and the abdomen is cylindrical. The abdomen may bulge in the upper right quadrant because of the large liver.

If the newborn is thin, peristaltic intestinal waves may be observed. At birth, the **umbilical cord** appears bluish white and moist. After clamping, it begins to dry and appears yellowish brown. It progressively shrivels and becomes greenish black prior to its falling off by the second week.

The genitalia of both sexes may appear darkly pigmented because of maternal hormonal influences. In a female neonate, a **hymenal** (*hi'men-al*) **tag** is frequently present and is visible at the back of the vaginal opening. It is composed of tissue from the hymen and labia minora. The hymenal tag usually disappears by the end of the first month.

## Palpable Structures

The six **fontanels** (see fig. 6.13) can be lightly palpated as the “soft spots” on the infant’s head. The liver is palpable 2–3 cm (1 in.) below the right costal margin. During a physical examination of a neonate, the physician will palpate both kidneys soon after delivery, before the intestines fill with air. The suprapubic area is also palpated for an abnormally distended urinary bladder. The newborn should void urine within the first 24 hours after birth.

The testes of the male neonate should always be palpated in the scrotum. If the neonate is small or premature, the testes may be palpable in the inguinal canals. An examination for inguinal hernias is facilitated by the crying of an infant, which creates abdominal pressure.

## ✓ Knowledge Check

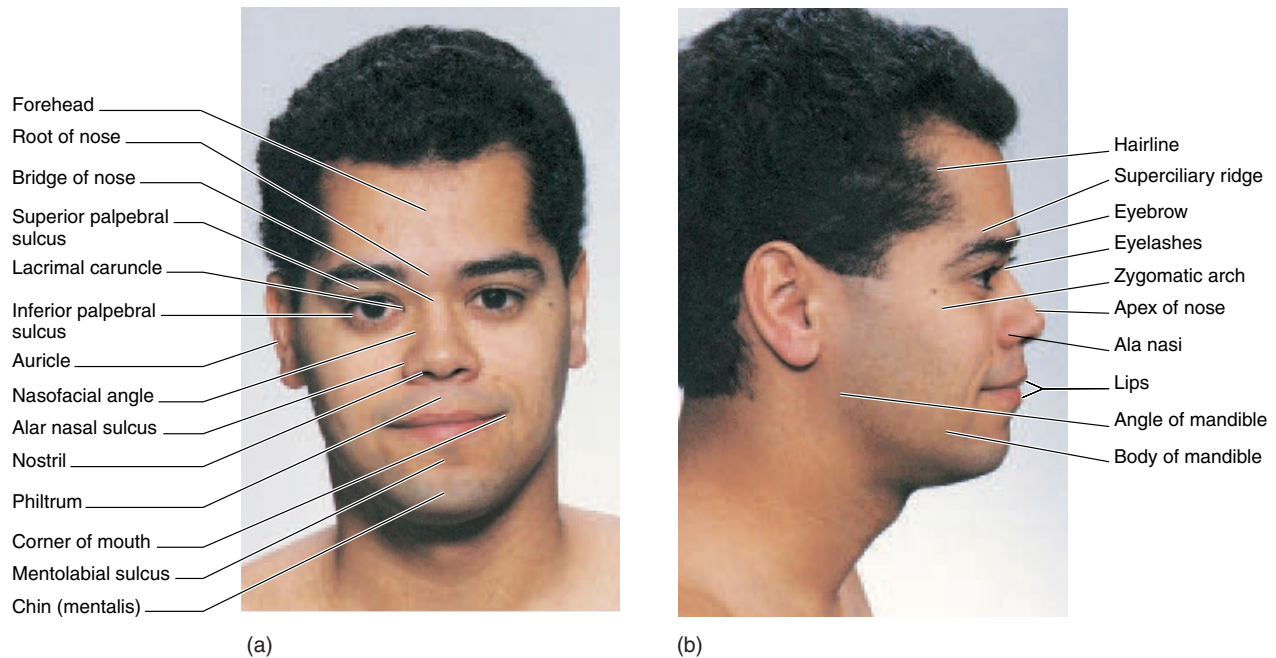
- Describe the appearance of each of the following in a normal neonate: skin, head, thorax, abdomen, genitalia, and extremities. What is meant by the normal flexion position of a neonate?
- Which internal body organs are palpable in a neonate?

## HEAD

The head is the most highly integrated region of the body, because it communicates with and controls all of the body systems. The head is of clinical concern because it contains important sense organs and provides openings into the respiratory and digestive systems. Of social importance is the aesthetics (pleasing appearance) of the head, which in some cases is also of clinical concern.

**Objective 6** Identify various surface features of the cranial and facial regions by observation or palpation.

**Objective 7** Describe the basic internal anatomy of the head.



**FIGURE 10.6** The surface anatomy of the facial region. (a) An anterior view and (b) a lateral view.

## Surface Anatomy

The head contains the brain and the special sense organs—the eyes, ears, nose, and taste buds. It also provides openings into the respiratory and digestive systems. The head is structurally and developmentally divided into the cranium and the face.

### Cranium

The **cranium**, also known as the **braincase**, is covered by the **scalp**. The scalp is attached anteriorly, at the level of the eyebrows, to the **supraorbital ridges**. It extends posteriorly over the area commonly called the forehead and across the crown (vertex) of the head to the **superior nuchal** (*noo'kal*) **line**, a ridge on the back of the skull. Both the supraorbital ridge above the **orbit**, or socket of the eye, and the superior nuchal line at the back of the skull can be easily palpated. Laterally, the scalp covers the **temporal region** and terminates at the fleshy portion of the ear called the **auricle** (*or'i-kul*), or **pinna**. The temporal region is the attachment for the **temporalis** muscle, which can be palpated when the jaw is repeatedly clenched. This region is clinically important because it is a point of entrance to the cranial cavity in many surgical procedures.

Only a portion of the scalp is covered with hair, and the variable **hairline** is genetically determined. The scalp is clinically important because of the dense connective tissue layer that supports nerves and vessels beneath the skin. When the scalp is cut, the wound is held together by the connective tissue, but at the same time the vessels are held open, resulting in profuse bleeding.

### Face

The **face** (fig. 10.6) is divided into four regions: the **ocular region**, which includes the eye and associated structures; the **auricular region**, which includes the ear; the **nasal region**, which includes the external and internal structures of the nose; and the **oral region**, which includes the mouth and associated structures.

The skin of the face is relatively thin and contains many sensory receptors, particularly in the oral region. Certain facial regions also have numerous **sweat glands** and **sebaceous** (*sē-ba'shus*) (oil-secreting) **glands**. Facial acne is a serious dermatological problem for many teenagers. Facial hair appears over most of the facial region in males after they go through puberty; unwanted facial hair may occur sparsely on some females and can be a social problem.

The muscles of facial expression are important in their effect on surface features. As they are contracted, various emotions are conveyed. These muscles originate on the facial bones and

cranium: Gk. *kranion*, skull

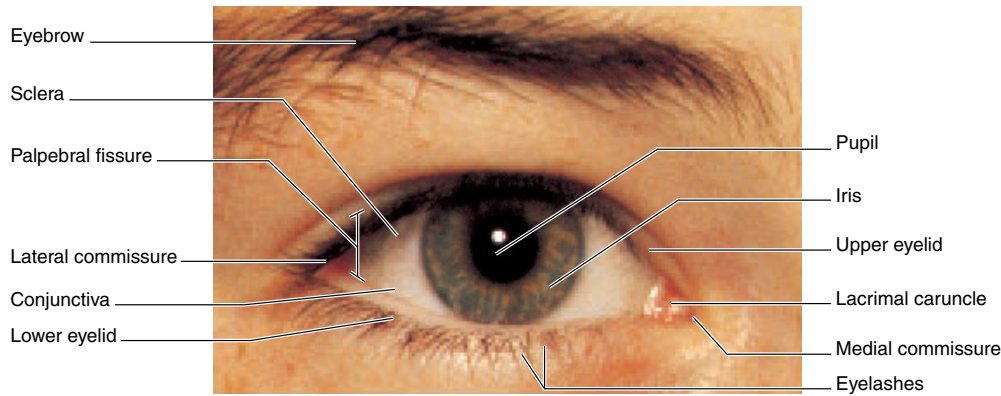


FIGURE 10.7 The surface anatomy of the ocular region.

TABLE 10.2 Surface Anatomy of the Ocular Region

| Structure   | Comments                                                                                                                                                                      | Structure          | Comments                                                                                                                         |
|-------------|-------------------------------------------------------------------------------------------------------------------------------------------------------------------------------|--------------------|----------------------------------------------------------------------------------------------------------------------------------|
| Eyebrow     | Ridge of hair that superiorly arches the eye. It protects the eye against sunlight and is important in facial expression.                                                     | Cornea             | Transparent anterior portion of the eyeball. It is slightly convex to refract incoming light waves.                              |
| Eyelids     | Movable folds of skin and muscle that cover the eyeball anteriorly. They assist in lubricating the anterior surface of the eyeball and reflexly close to protect the eyeball. | Iris               | Circular, colored, muscular portion of the eyeball that surrounds the pupil. It reflexly regulates the amount of incoming light. |
| Eyelashes   | Rows of hairs on the margins of the eyelids. They prevent airborne particles from contacting the eyeball.                                                                     | Pupil              | Opening in the center of the iris through which light enters the eyeball                                                         |
| Conjunctiva | Thin mucous membrane that covers the anterior surface of the eyeball and lines the undersurface of the eyelids. It aids in reducing friction during blinking.                 | Palpebral fissure  | Space between the eyelids when they are open                                                                                     |
| Sclera      | Outer fibrous layer of the eyeball; the “white” of the eye that gives form to the eyeball                                                                                     | Subtarsal sulcus   | Groove beneath the eyelid that parallels the margin of the lid. It traps small foreign particles that contact the conjunctiva.   |
|             |                                                                                                                                                                               | Medial commissure  | Medial junction of the upper and lower eyelids                                                                                   |
|             |                                                                                                                                                                               | Lateral commissure | Lateral junction of the upper and lower eyelids                                                                                  |
|             |                                                                                                                                                                               | Lacrimal caruncle  | Fleshy, pinkish elevation at the medial commissure. It contains sebaceous and sweat glands.                                      |

insert into the dermis (second major layer) of the skin. Repeated contraction of these muscles may eventually cause permanent crease lines in the skin.

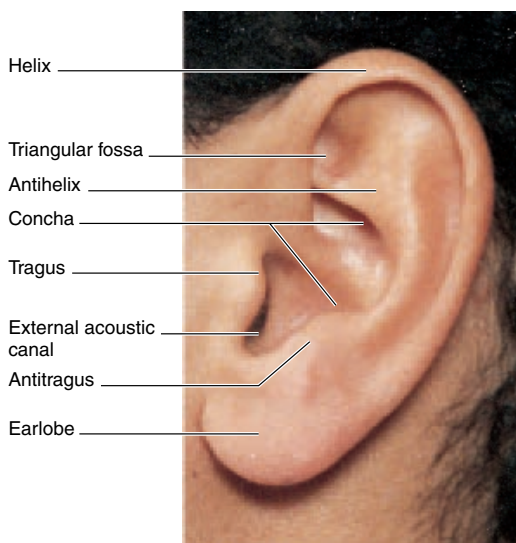
Because the organs of the facial region are so complex and specialized, there are professional fields of specialty associated with the various regions. *Optometry* and *ophthalmology* are concerned with the structure and function of the eye. *Dentistry* is entirely devoted to the health and functional and cosmetic problems of the oral region, particularly the teeth. An *otorhinolaryngologist* (o'to-ri'no-lar'ing-gol'ō-jist) is an ear, nose, and throat specialist.

The *ocular region* includes the eyeball and associated structures. Most of the surface features of the ocular region protect the

eye. **Eyebrows** protect against potentially damaging sunlight and mechanical blows; **eyelids** reflexly close to protect against objects moving toward the eye or visual stimuli; **eyelashes** prevent airborne particles from contacting the eyeball; and *lacrimal* (lak'rīmal) *secretions* (tears) wash away chemicals or foreign materials and prevent the surface of the eyeball from drying. Many of the surface features of the ocular region are shown in figure 10.7 and described in table 10.2.

The *auricular region* includes the visible surface structures and internal organs that function in hearing and maintaining equilibrium. The fleshy **auricle** and the tubular opening into the middle ear, called the **external acoustic canal**, are the only





**FIGURE 10.8** The surface anatomy of the auricular region.

observable surface features of the auricular region. The rim of the auricle, shaped and supported by elastic cartilage, is called the **helix**; the inferior portion is referred to as the **earlobe**. The earlobe is composed primarily of connective and fatty tissue, and therefore can be easily pierced. For this reason, it is sometimes used when obtaining blood for a blood count. The **tragus** (*tra'gus*) is a small, posteriorly directed projection partially covering and protecting the external acoustic canal. Further protection is provided by the many fine hairs that surround the opening into this canal. The condyle of the mandible can be palpated at the opening of the external acoustic canal by placing the little finger in the opening, and then vigorously moving the jaw. Refer to figure 10.8 and table 10.3 for an illustration and description of other surface features of the auricular region.

The inspection of some of the internal structures of the ear is part of a routine physical examination and is performed using an otoscope. *Cerumen* (*să-roo'men*) (earwax) may accumulate in the canal, but this is a protective substance. It waterproofs the tympanic membrane (eardrum) and because of its bitter taste is thought to be an insect repellent. In some cases, it may become impacted and require physical removal.

A few structural features of the **nasal region** are apparent from its surface anatomy (fig. 10.9 and table 10.4). The principal function of the nose is associated with the respiratory system, and the need for a permanent body opening to permit gaseous ventilation accounts for its surface features. The **root** (*nasion*) of the nose is the point in the skull where the nasal and frontal

**TABLE 10.3** Surface Anatomy  
of the Auricular Region

| Structure               | Comments                                                                                                                   |
|-------------------------|----------------------------------------------------------------------------------------------------------------------------|
| Auricle (pinna)         | Expanded portion of the ear projecting from the side of the head. It funnels sound waves into the external acoustic canal. |
| Helix                   | Outer rim of the auricle. It gives form and shape to the auricle.                                                          |
| Earlobe                 | Fleshy inferior portion of the auricle                                                                                     |
| Tragus                  | Small projection of the auricle, just anterior to the external acoustic canal.                                             |
| Antitragus              | Small, cartilaginous anterior projection opposite the tragus                                                               |
| Antihelix               | Semicircular ridge anterior to the greater portion of the helix                                                            |
| Concha                  | Depressed hollow of the auricle. It funnels sound waves.                                                                   |
| External acoustic canal | Slightly S-shaped tube extending inward to the tympanic membrane. It contains glands that secrete earwax for protection.   |
| Triangular fossa        | Triangular depression in the superior part of the antihelix                                                                |

bones unite. It is located at about the level of the eyebrows. The firm, narrow part between the eyes is the **bridge** (*dorsum nasi*) of the nose and is formed by the union of the nasal bones. The nose below this level has a pliable cartilaginous framework that maintains an opening. The tip of the nose is called the **apex**. The **nostrils**, or **external nares**, (*na'rēz*) are the paired openings into the nose. The **wing** (*ala*) of the nose forms the flaired outer margin of each nostril.

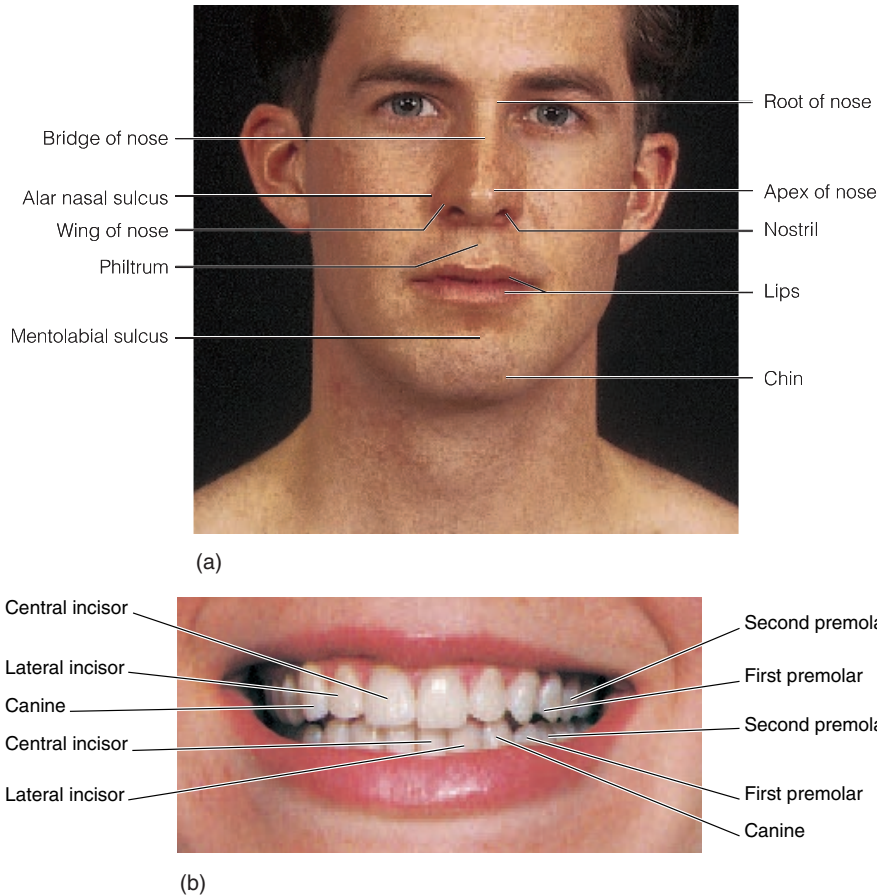
Structures of the **oral region** that are important in surface anatomy include the fleshy upper and lower **lips** (*labia*), the **chin** (*mentum*), and the structures of the **oral cavity** that can be observed when the mouth is open. The lips and chin are shown in figure 10.9 and the structures of the oral cavity, in figure 10.10.

The color of the lips and other mucous membranes of the oral cavity are diagnostic of certain body dysfunctions. The lips may appear pale in people with severe anemia, or bluish in those with abnormal amounts of reduced hemoglobin in the blood. A lemon yellow tint to the lips may indicate pernicious anemia or jaundice.

## Internal Anatomy

The internal anatomy of the head from cadaver dissections is shown in figures 10.11 through 10.13. Figure 10.13 depicts the





**FIGURE 10.9** The surface anatomy of the nasal and oral regions. (a) The nose and lips and (b) the teeth.

**TABLE 10.4 Surface Anatomy of the Nasal and Oral Regions**

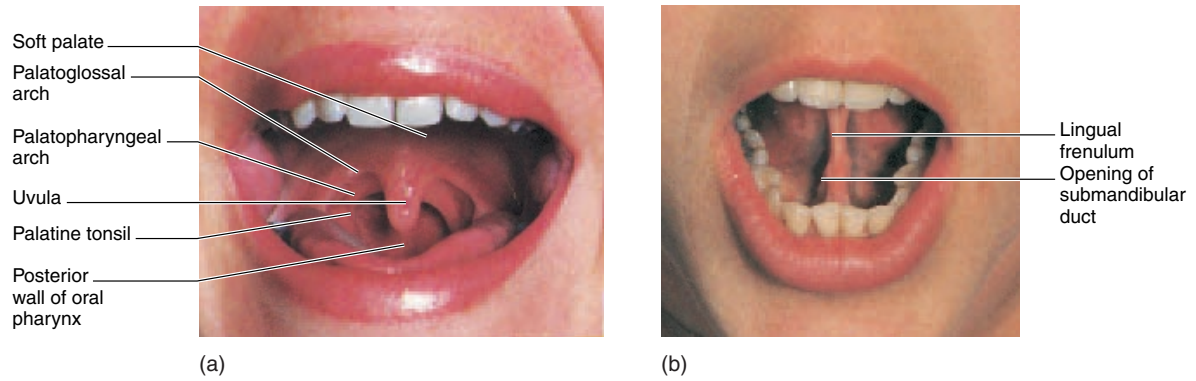
| Structure                    | Comments                                                                      |
|------------------------------|-------------------------------------------------------------------------------|
| Root of nose (nasion)        | Superior attachment of the nose to the cranium                                |
| Bridge of nose (dorsum nasi) | Bony upper framework of the nose formed by the union of nasal bones           |
| Alar nasal sulcus            | Lateral depression where the ala of the nose contacts the tissues of the face |
| Apex of nose                 | Tip of the nose                                                               |
| Nostril (external nare)      | External opening into the nasal cavity                                        |
| Wing of nose (ala)           | Laterally expanded border of the nostril                                      |
| Philtrum                     | Vertical depression in the medial part of the upper lip                       |
| Lip (labium)                 | Upper and lower anterior borders of the mouth                                 |
| Chin (mentum)                | Anterior portion of the lower jaw                                             |

brain in sagittal section within the cranium. A detailed discussion of the brain, with accompanying illustrations, is presented in chapter 11. The sensory organs of the head (eyes, ears, taste buds, and olfactory receptors) are discussed and illustrated in chapter 15.

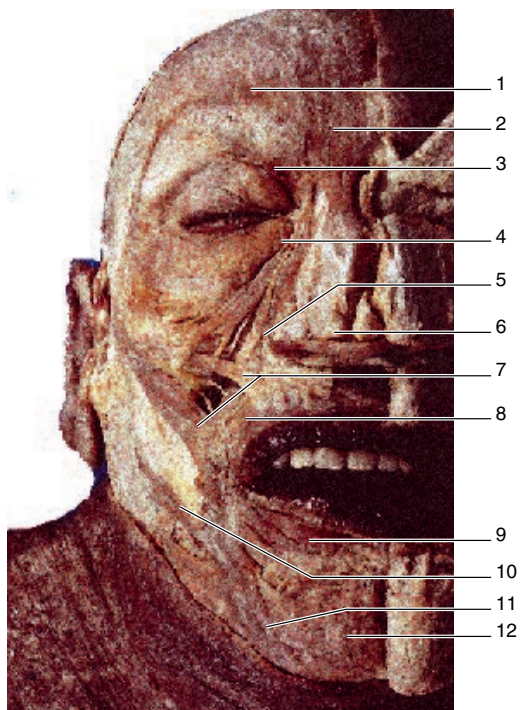
### ✓ Knowledge Check

- What are the boundaries of the cranial region and why is this region clinically important?
- Why do scalp wounds bleed so freely? How might this relate to infections?
- What are the subdivisions of the facial region?

Chapter 10 Surface and Regional Anatomy 305

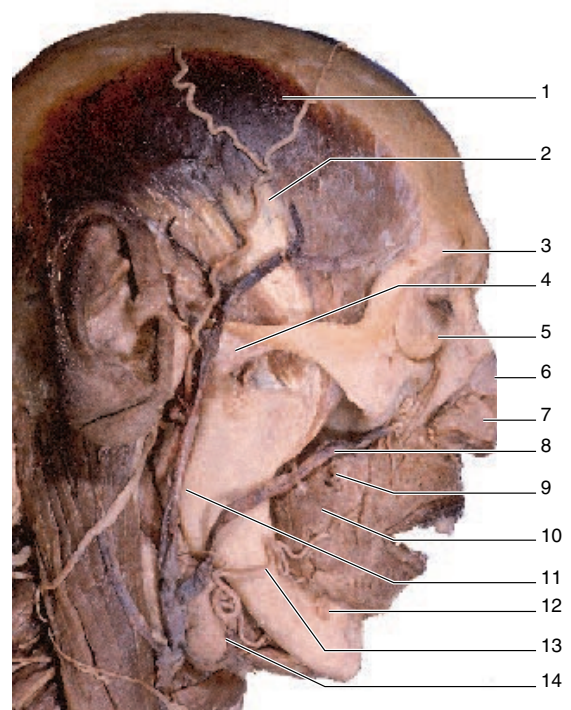


**FIGURE 10.10** Surface structures of the oral cavity (a) with the mouth open and (b) with the mouth open and the tongue elevated.



- |                               |                                |
|-------------------------------|--------------------------------|
| 1 Frontalis m.                | 7 Zygomaticus mm.              |
| 2 Supratrochlear a.           | 8 Facial a.                    |
| 3 Corrugator supercilli m.    | 9 Orbicularis oris m.          |
| 4 Orbicularis oculi m.        | 10 Risorius m.                 |
| 5 Levator labii superioris m. | 11 Depressor angularis oris m. |
| 6 Alar cartilage              | 12 Mentalis m.                 |

**FIGURE 10.11** An anterior view of the muscles of the head (m. = muscle, mm. = muscles, a. = artery).



- |                           |                        |
|---------------------------|------------------------|
| 1 Temporalis m.           | 8 Facial v.            |
| 2 Superficial temporal a. | 9 Parotid duct         |
| 3 Supraorbital margin     | 10 Buccinator m.       |
| 4 Temporomandibular joint | 11 Retromandibular v.  |
| 5 Orbital fat body        | 12 Mental a., v., n.   |
| 6 Greater alar cartilage  | 13 Facial a.           |
| 7 Lateral alar cartilage  | 14 Submandibular gland |

**FIGURE 10.12** A lateral view of the deep muscles of the head (m. = muscle, a. = artery, v. = vein, n. = nerve).

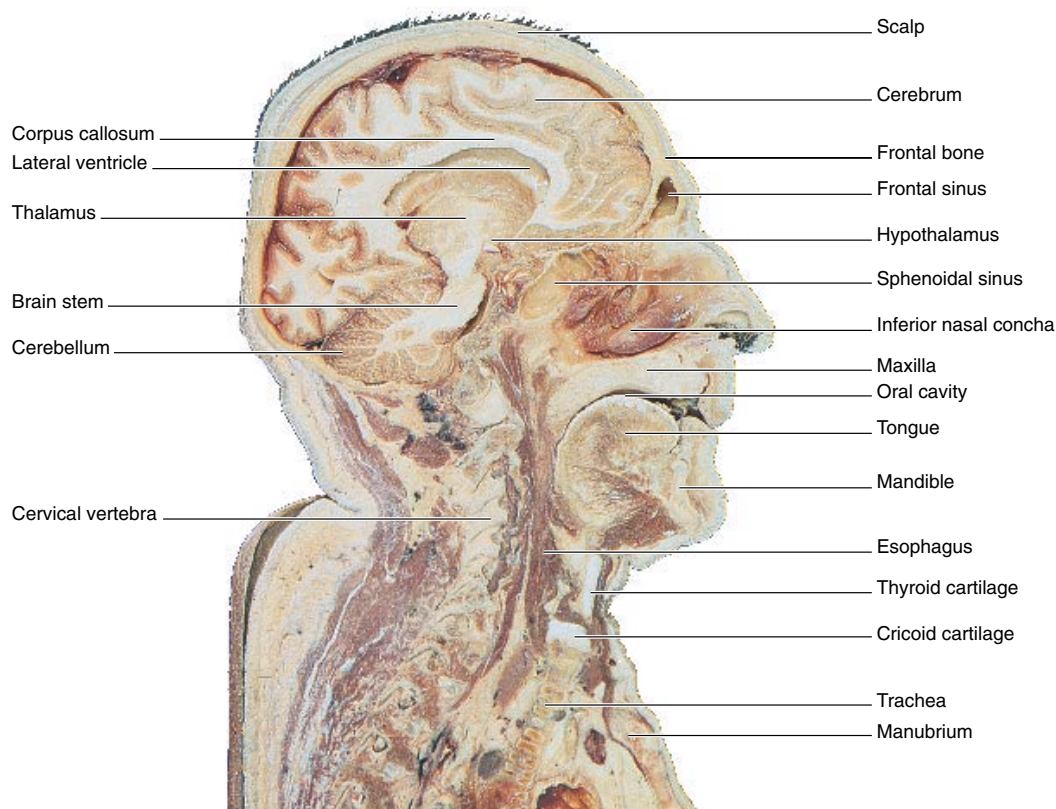


FIGURE 10.13 A sagittal section of the head and neck.

## NECK

The flexible neck has a number of important external features. In addition, several major organs are contained within the neck, and other vital structures pass through it.

**Objective 8** Discuss the functions of the neck.

**Objective 9** Name and locate the triangles of the neck and list the structures contained within these triangles.

The **neck** is a complex region of the body that connects the head to the thorax. The spinal cord, nerves, trachea, esophagus, and major vessels traverse this highly flexible area. In addition, other organs are contained entirely within the neck, as are several important glands. Remarkable musculature in the neck produces an array of movements. Because of this complexity, the neck is a clinically important area. Its surface features provide landmarks for locating internal structures.

## Surface Anatomy

The neck is divided into four regions: (1) an *anterior region* called the **cervix** (*ser'viks*) that contains portions of the digestive and

respiratory tracts, the **larynx** (*lar'ingks*) (voice box), vessels passing to and from the head, nerves, and the **thyroid** and **parathyroid glands**; (2) right and (3) left *lateral regions*, each composed of major neck muscles and **cervical lymph nodes**; and (4) a *posterior region*, referred to as the **nucha** (*noo'ka*) which includes the spinal cord, cervical vertebrae, and associated structures.

The most prominent structure of the cervix of the neck is the **thyroid cartilage** of the larynx (fig. 10.14). The **laryngeal prominence** of the thyroid cartilage, commonly called the “Adam’s apple,” can be palpated on the midline of the neck. The thyroid cartilage supports the vocal folds (cords). It is larger in males than in females because male sex hormones stimulate its growth during puberty. The **hyoid bone** can be palpated just above the larynx. Both of these structures are elevated during swallowing, which is one of the actions that directs food and fluid into the esophagus. Note this action on yourself by gently cupping your fingers on the larynx, and then swallowing. Directly below the thyroid cartilage is the **cricoid** (*kri'coid*) **cartilage**, followed by the **trachea** (*tra'ke-ě*) (“windpipe”). Both of these structures can be palpated. The cricoid cartilage serves as a landmark for locating the rings of cartilage of the trachea when creating an emergency airway (*tracheostomy*). The thyroid gland can be palpated on



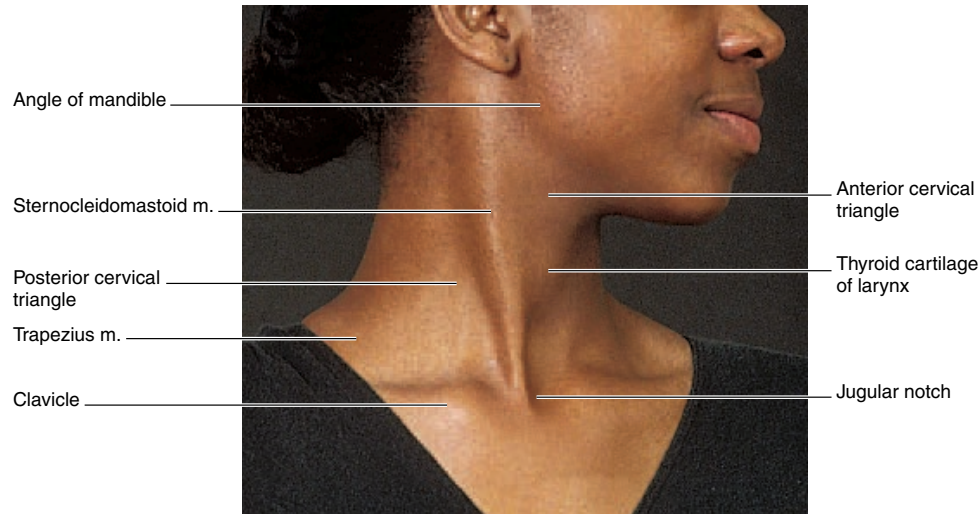



FIGURE 10.14 An anterolateral view of the neck.

either side of the neck, just below the level of the larynx. In addition, pulsations of the **common carotid** (*kă-rot'id*) **artery** can be observed on either side of the neck, just lateral and a bit superior to the level of the larynx.

 The arteries of the head and neck are rarely damaged because of their elasticity. In a severe lateral blow to the head, however, the internal carotid artery may rupture, resulting in the perception of a roaring sound as blood rushes into the cavernous sinuses of the temporal bone. Containment of carotid hemorrhage within the sinuses may actually be lifesaving.

The **jugular notch** is a V-shaped groove in the manubrium of the sternum, which creates a depression on the inferior midline of the cervix. The two **clavicles** are obvious in all people because they lie just under the skin.


The **sternocleidomastoid** (*ster''no-kli''do-mas'toid*) and **trapezius** muscles are the prominent structures of each lateral region (figs. 10.14 and 10.15). The sternocleidomastoid muscle can be palpated along its entire length when the head is turned to the side. The tendon of this muscle is especially prominent to the side of the jugular notch. The trapezius muscle can be felt when the shoulders are shrugged. An inflammation of the trapezius causes a “stiff neck.” If a person is angry or if a shirt collar is too tight, the **external jugular vein** can be seen as it courses obliquely across the sternocleidomastoid muscle. **Cervical lymph nodes** of the lateral neck region may become swollen and painful from infectious diseases of the oral or pharyngeal regions.

Most of the structures of the nucha are too deep to be of importance in surface anatomy. The spines of the lower cervical vertebrae (especially C7), however, can be observed and palpated when the neck is flexed. In this same position, the **ligamentum nuchae** (*noo'ke*) (not shown) is raised, forming a firm ridge that extends superiorly from vertebra C7 to the external occipital protuberance of the skull. Clinically, the ligamentum

nuchae is extremely important because of the debilitating damage it sustains from whiplash injury or a broken neck.

### Triangles of the Neck

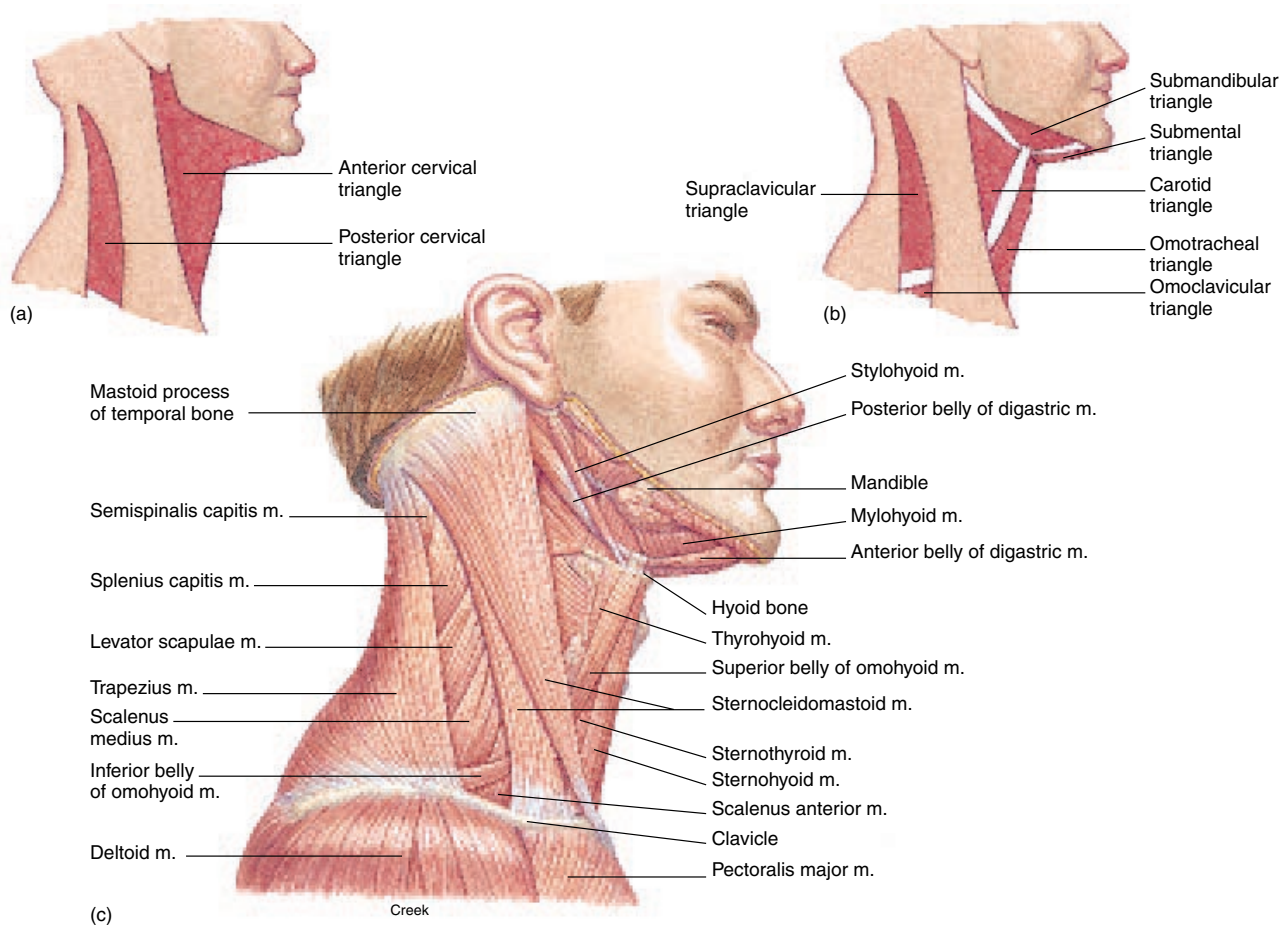
The triangles of the neck, created by the arrangement of specific muscles and bones, are clinically important because of the specific structures included in each. The structures of the neck that are important in surface anatomy have already been described, however. Thus, the two major and six minor triangles are depicted in figure 10.15 and presented in table 10.5 in summary form. The sternocleidomastoid muscle obliquely transects the neck, dividing it into an **anterior cervical triangle** and a **posterior cervical triangle**. The apex of the anterior cervical triangle is directed inferiorly. The median line of the neck forms the anterior boundary of the anterior cervical triangle; the inferior border of the mandible forms its superior boundary; and the sternocleidomastoid muscle forms its posterior boundary. The posterior cervical triangle is formed by the sternocleidomastoid muscle anteriorly and the trapezius muscle posteriorly; the clavicle forms its base inferiorly.

 Three structures traversing the neck are extremely important and potentially vulnerable. These structures are the common carotid artery, which carries blood to the head; the internal jugular vein, which drains blood from the head; and the vagus nerve, which conducts nerve impulses to visceral organs. These structures are protected in the neck by their deep position behind the sternocleidomastoid muscle and by their enclosure in a tough connective tissue called the *carotid sheath*.

### Internal Anatomy

The internal anatomy of the neck from cadaver dissections is shown in figures 10.16 and 10.17. The organs of the neck are highly integrated and packed into a relatively small area. The neck has to support the head, at the same time permitting flexibility.

308 Unit 4 Support and Movement



**FIGURE 10.15** Triangles of the neck. (a) The two large triangular divisions, (b) the six lesser triangular subdivisions, and (c) the detailed muscular anatomy of the neck.

**TABLE 10.5** Boundaries and Internal Structures of the Triangles of the Neck

| Triangle               | Boundaries                                                                     | Internal Structures                                                                                            |
|------------------------|--------------------------------------------------------------------------------|----------------------------------------------------------------------------------------------------------------|
| Anterior cervical      | Sternocleidomastoid muscle; median line of neck; inferior border of mandible   | Four lesser triangles contain salivary glands, larynx, trachea, thyroid glands, and various vessels and nerves |
| Carotid                | Sternocleidomastoid, posterior digastric, and omohyoid muscles                 | Common carotid artery, internal jugular vein, and vagus nerve                                                  |
| Submandibular          | Digastric muscle (both heads); inferior border of mandible                     | Salivary glands                                                                                                |
| Submental              | Digastric muscle; hyoid bone (This is the only unpaired triangle of the neck.) | Muscles of the floor of the mouth and salivary glands and ducts                                                |
| Omotracheal (muscular) | Sternocleidomastoid and omohyoid muscles; midline of neck                      | Larynx, trachea, thyroid gland, and carotid sheath                                                             |
| Posterior cervical     | Sternocleidomastoid and trapezius muscles; clavicle                            | Nerves and vessels                                                                                             |
| Supraclavicular        | Sternocleidomastoid, trapezius, and omohyoid muscles                           | Cervical plexus and accessory nerve                                                                            |
| Omoclavicular          | Sternocleidomastoid and omohyoid muscles; clavicle                             | Brachial plexus and subclavian artery                                                                          |

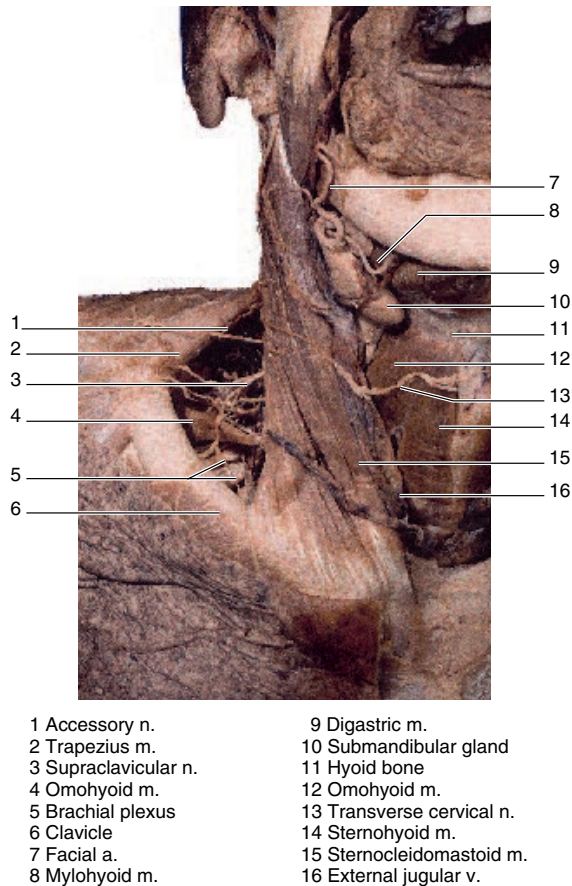


FIGURE 10.16 An anterior view of the right cervical region.

## ✓ Knowledge Check

- List four functions of the neck. Which body systems are located, in part, within the neck.
- What are the structural regions of the neck? Identify the structures included in each region?
- With reference to the triangles of the neck, where would you palpate to feel (a) a pulse, (b) the trachea, (c) cervical lymph nodes, and (d) the thyroid gland?

## TRUNK

The locations of vital visceral organs in the cavities of the trunk make the surface anatomy of this body region especially important.

**Objective 10** Identify various surface features of the trunk by observation or palpation.

**Objective 11** List the auscultation sites of the thorax and abdomen.

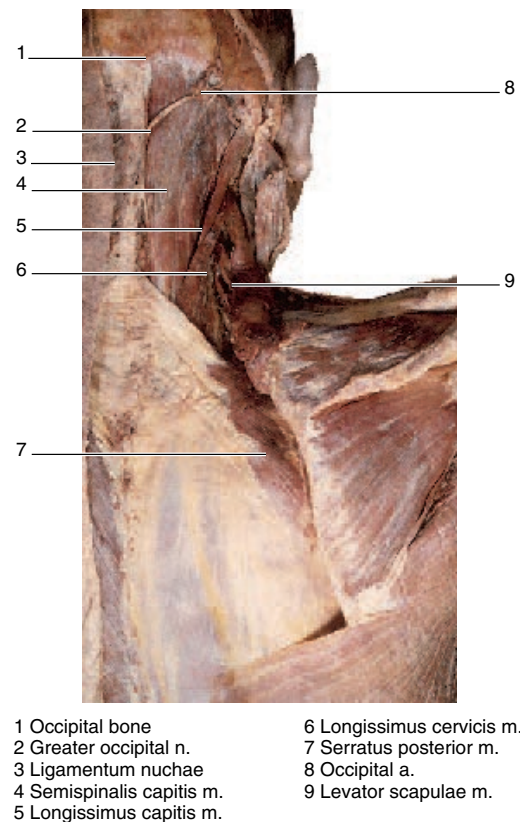


FIGURE 10.17 A posterior view of the deep cervical muscles.

## Surface Anatomy

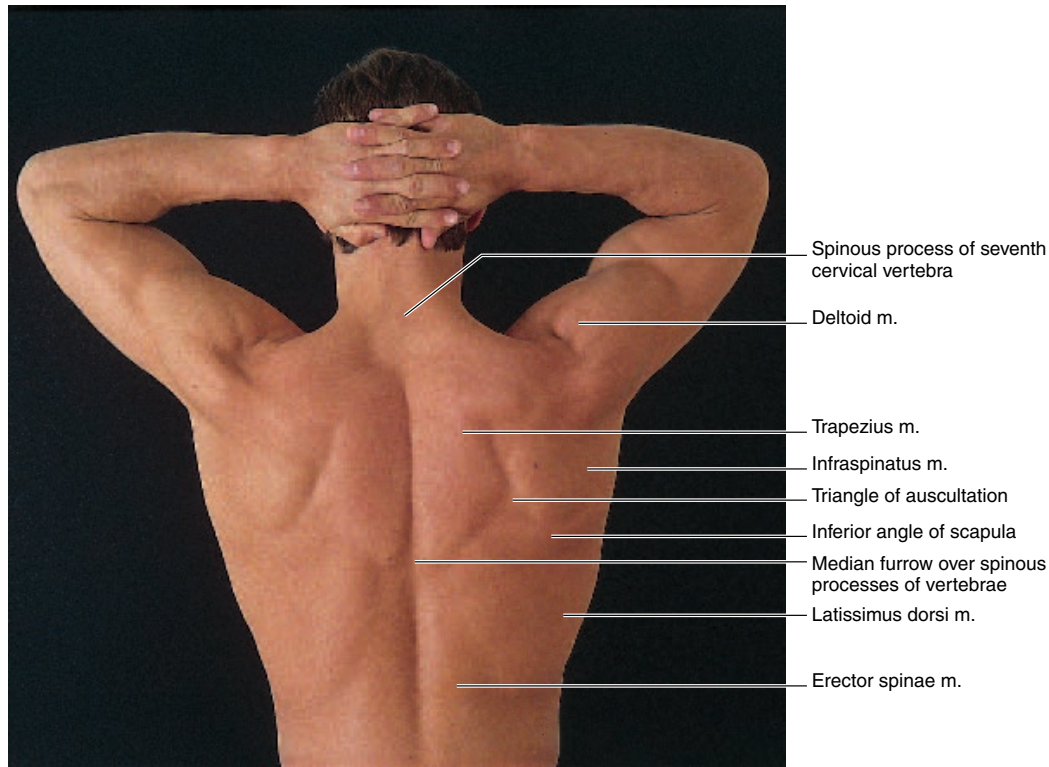
The **trunk**, or *torso*, is divided into the **back**, **thorax** (chest), **abdomen** (venter), and **pelvis**. A region called the *perineum* forms the floor of the pelvis and includes the external genitalia. The pelvis and perineum are discussed in the following section.

The surface anatomy of the trunk is particularly important in determining the location and condition of the visceral organs. Some of the surface features may be obscured, however, because of age, sex, or body weight.

### Back

No matter how obese a person may be, a **median furrow** can be seen on the back, along with some of the spinous process of the vertebrae (fig. 10.18). The entire series of vertebral spines can be observed when the vertebral column is flexed. This position is important in determining defects of the vertebral column (see Clinical Considerations in chapters 8 and 11). The back of the **scapula** presents other important surface landmarks. The base of the spine of the scapula is level with the third thoracic vertebra, and the inferior angle of the scapula is even with the seventh





**FIGURE 10.18** The surface anatomy of the back during abduction of the shoulder joints and flexion of the elbow joints.

thoracic vertebra. Several muscles of the scapula can be observed on a lean, muscular person and are identified in figure 10.18. Many of the ribs and muscles that attach to the ribs can be seen in a lateral view (fig. 10.19).

The **triangle of auscultation** (fig. 10.18) is bounded by the trapezius muscle, the latissimus dorsi muscle, and the medial border of the scapula (see fig. 10.27). Because there is a space between the superficial back muscles in this area, heart and respiratory sounds are not muffled by the muscles when a stethoscope is placed here.

## Thorax

The leading causes of death in the United States are associated with disease or dysfunction of the thoracic organs. With the exception of the breasts and surrounding lymph nodes, the organs of the thorax are located within the rib cage. The paired clavicles and the jugular notch have already been identified as important surface features of the neck, with regard to the thoracic region (fig. 10.20), these structures serve as reference points for counting the ribs. Many of the ribs can be seen on a thin person. All but the first, and at times the twelfth, can be palpated. The sternum is composed of three separate bones (manubrium, body, and xiphoid process), each of which can be palpated. The **sternal**

**angle** is felt as an elevation between the manubrium and body of the sternum. The sternal angle is important because it is located at the level of the second rib. The articulation between the body of the sternum and the xiphoid process, called the **xiphisternal** (zif'i-ster'nal) **joint**, is positioned over the lower border of the heart and the diaphragm. The **costal margin** of the rib cage is the lower oblique boundary and can be easily identified when a person inhales and holds his or her breath (see fig. 10.19). The **costal angle** (costal arch) is where the costal margins come together as an inverted V of the position of the xiphoid process of the sternum.

The nipples in the male (fig. 10.20) are located at the fourth intercostal spaces (the area between the fourth and fifth ribs), about 10 cm (4 in.) from the midline. In sexually mature women, their position varies according to age and the size and pendulousness of the breasts (fig. 10.21). The position of the left nipple in males is an important landmark for knowing where to listen to various heart sounds and for determining whether the heart is enlarged. For diagnostic purposes, an imaginary line, the **midclavicular line**, can be extended vertically from the middle of the clavicle through the nipple. Several superficial chest muscles can be observed or palpated and are therefore important surface features. These muscles are depicted in figures 10.20 and 10.21.

- Deltoid m. \_\_\_\_\_  
 Axilla \_\_\_\_\_  
 Pectoralis major m. \_\_\_\_\_  
 Latissimus dorsi m. \_\_\_\_\_  
 Nipple \_\_\_\_\_  
 Serratus anterior m. \_\_\_\_\_  
 Costal angle \_\_\_\_\_  
 External intercostal m. \_\_\_\_\_  
 Costal margin \_\_\_\_\_  
 Tendinous inscription \_\_\_\_\_  
 Rectus abdominis m. \_\_\_\_\_

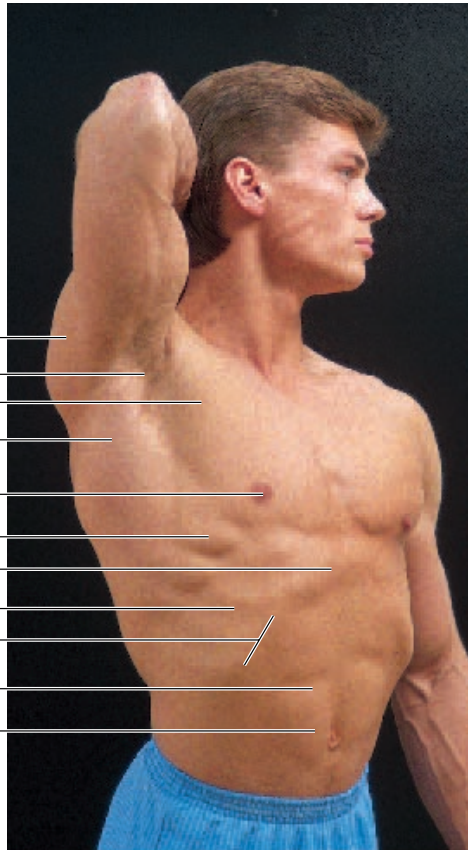


FIGURE 10.19 An anterolateral view of the trunk and axilla.

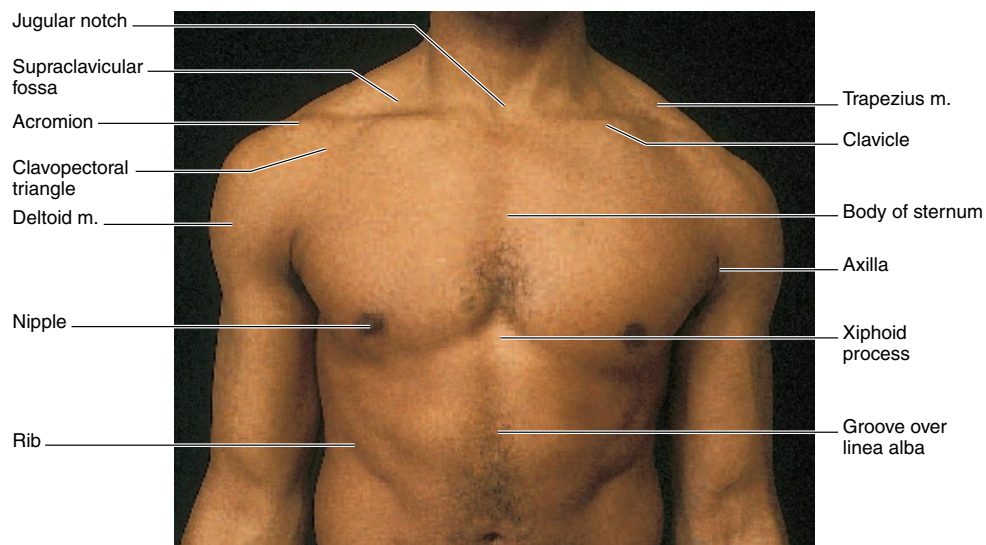


FIGURE 10.20 The surface anatomy of the anterior thoracic region of the male.

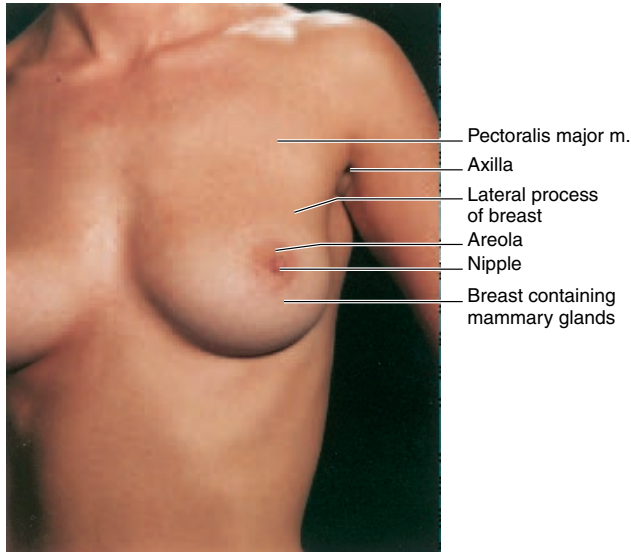


FIGURE 10.21 The surface anatomy of the female breast.

In addition to helping one know where to listen with a stethoscope to heart sounds, surface features of the thorax are important for auscultations of the lungs, radiographs, tissue biopsies, sternal taps for bone marrow studies, and thoracic surgery. Although the anatomical features of the rib cage are quite consistent, some people exhibit slight deformities and asymmetries. They are generally not disabling and require no treatment. Most of the abnormalities are congenital and include such conditions as a projecting sternum (pigeon breast) or a receding sternum (funnel chest).

### Abdomen

The abdomen is the portion of the body between the diaphragm and the pelvis. Because it does not have a bony framework like that of the thorax the surface anatomy is not as well defined. Bony landmarks of both the thorax and pelvis are used when referring to abdominal structures (fig. 10.22). The **right costal margin** of the rib cage is located over the liver and gallbladder on the right side, and the **left costal margin** is positioned over the stomach and spleen on the left. The xiphoid process is important because from this point a tendinous, midventral raphe, the **linea alba** (*lin'e'ă al'bī*), extends the length of the abdomen to attach to the **symphysis pubis**. The symphysis pubis can be palpated at the anterior union of the two halves of the pelvic girdle. The **navel**, or **umbilicus**, is

linea alba: L. *linea*, line; *alba*, white  
navel: O.E. *nafela*, umbilicus  
umbilicus: L. *umbilicus*, navel

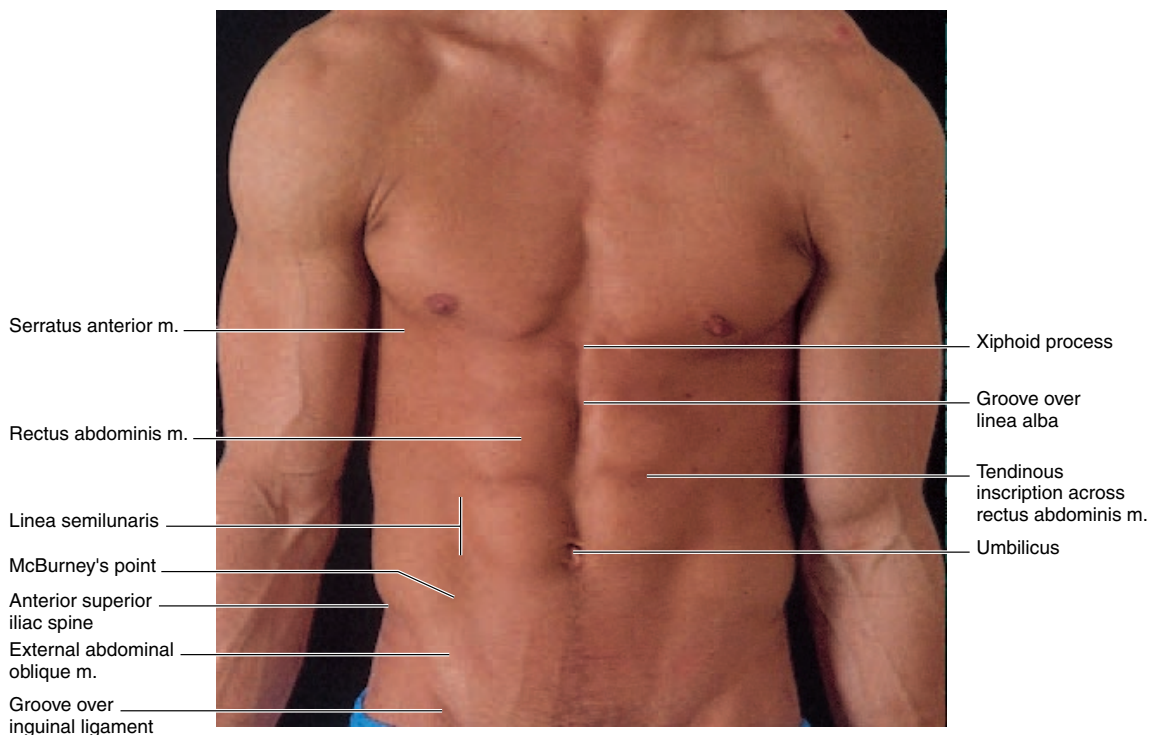
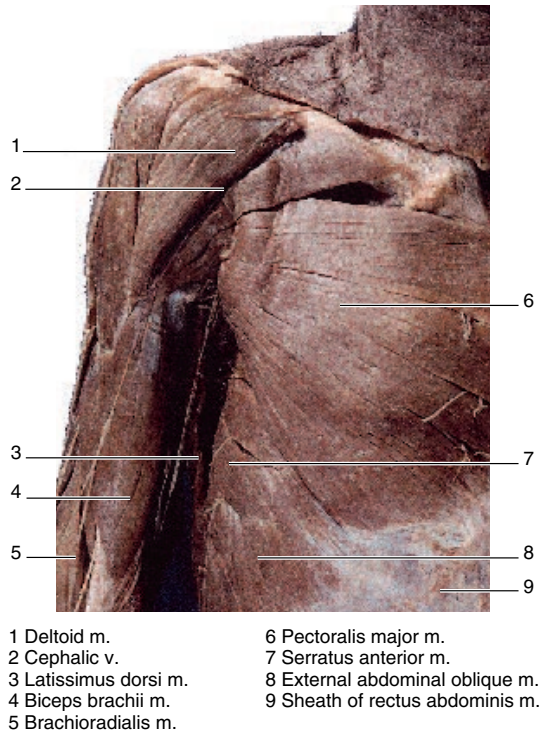



FIGURE 10.22 The surface anatomy of the anterior abdominal region.





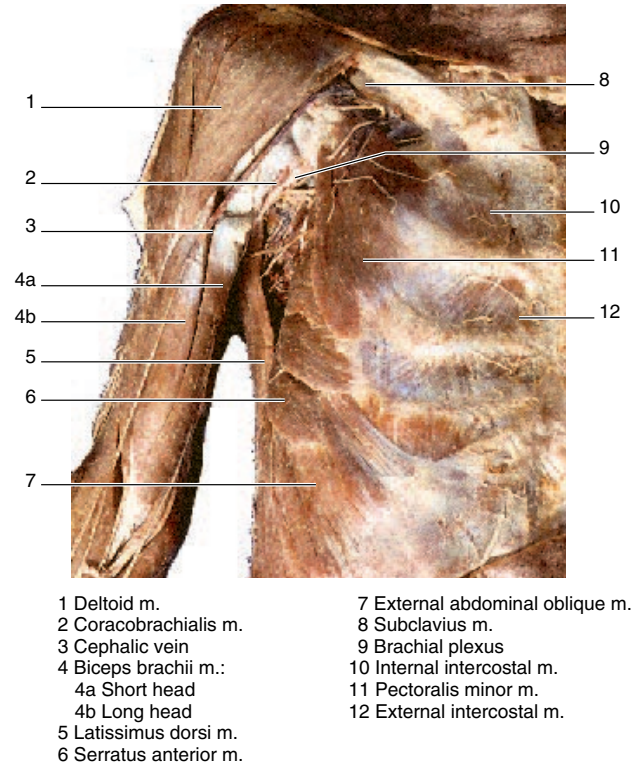
**FIGURE 10.23** An anterior view of the superficial muscles of the right thorax, shoulder, and brachium.

the site of attachment of the fetal umbilical cord and is located along the linea alba. The linea alba separates the paired, straplike **rectus abdominis** muscles, which can be seen when a person flexes the abdomen (as when doing sit-ups).

 Clinically, the linea alba is a favored site for abdominal surgery because an incision made along this line severs no muscles and few vessels or nerves. Moreover, the linea alba heals readily. It has been said that only a zipper would provide a more convenient entry to the abdominal cavity.


The lateral margin of the rectus abdominis muscle can be observed on some individuals, and the surface line it produces is called the **linea semilunaris**. The **external abdominal oblique** muscle is the superficial layer of the muscular abdominal wall. The **iliac crest** is subcutaneous and can be palpated along its entire length. The highest point of the crest lies opposite the body of the fourth lumbar vertebra, an important level in spinal anesthesia. Another important landmark is **McBurney's point**, located about one-third of the distance from the right anterior superior iliac spine on a line between that spine and the umbilicus (fig. 10.22). This point overlies the appendix of the GI tract. In surgical removal of the appendix (*appendectomy*), an oblique incision is made through McBurney's point.

McBurney's point: from Charles McBurney, American surgeon, 1845–1914



**FIGURE 10.24** An anterior view of the deep muscles of the right thorax, shoulder, and brachium.

The abdominal region is frequently divided into nine regions or four quadrants in order to describe the location of internal organs and to clinically identify the sites of various pains or conditions. These regions have been adequately described in chapter 2 (see figs. 2.15 and 2.16).

 Although the position of the umbilicus is relatively consistent in all people, its shape and health is not. For example, there may be an opening to the outside, called a *fistula*, or herniation of some of the abdominal contents. Acquired umbilical hernias may develop in children who have a weak abdominal wall in this area, or they may develop in pregnant women because of the extra pressure exerted at this time.

The umbilicus is a common site for an incision into the abdominal cavity in a procedure called *laparotomy*. Laparotomy is frequently done to examine or perform surgery on the internal female reproductive organs. A depressed umbilicus on an obese person is difficult to keep clean, and so various types of infections may occur there.

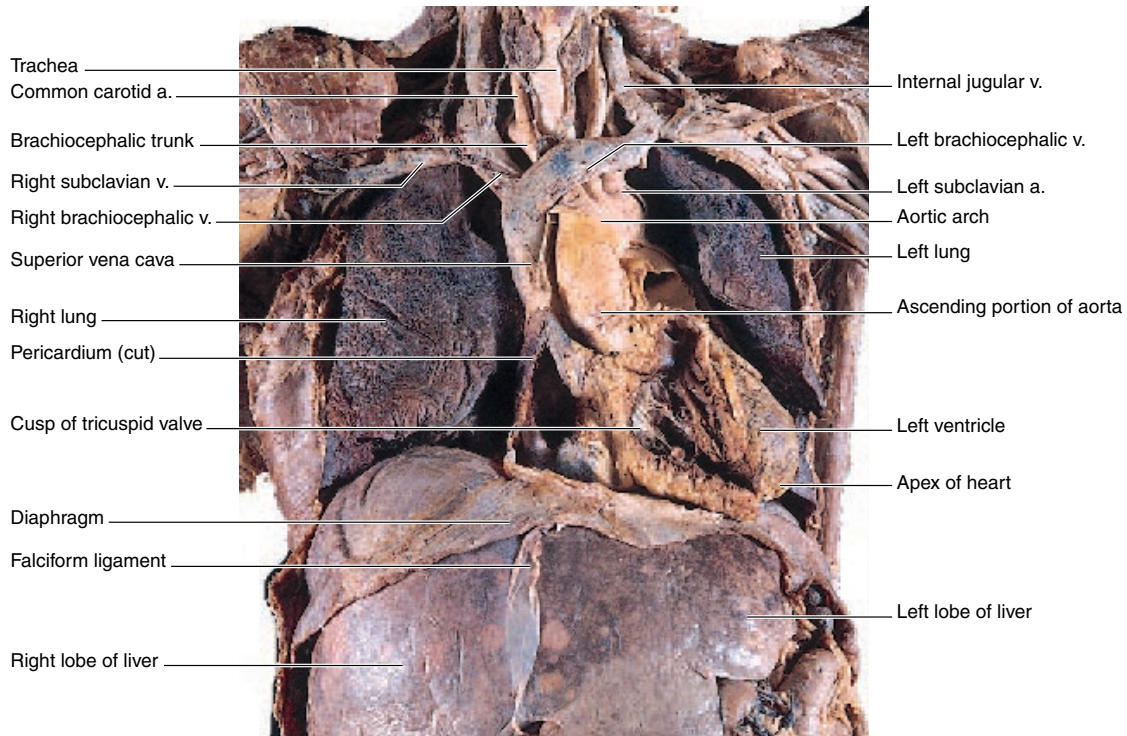
## Internal Anatomy

### Thorax

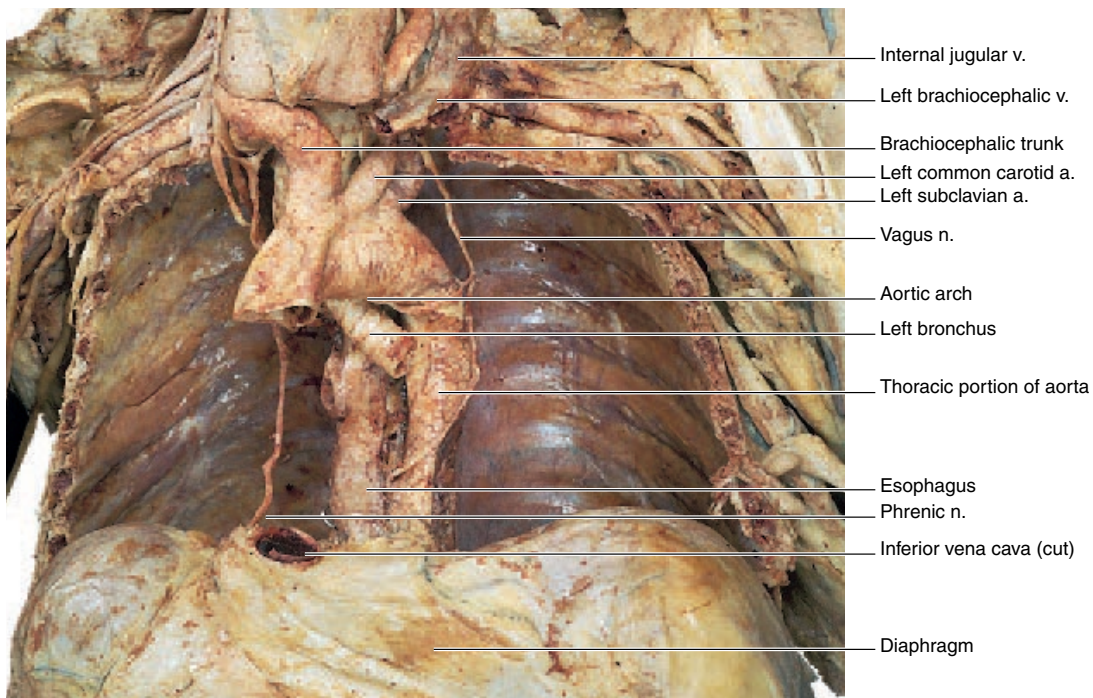
Included in the internal anatomy of the thorax (figs. 10.23 through 10.29) are the rib cage and its contents, the thoracic musculature, and the mammary glands and breasts of a female.

laparotomy: Gk. *lapara*, flank; *tome*, incision

314 Unit 4 Support and Movement

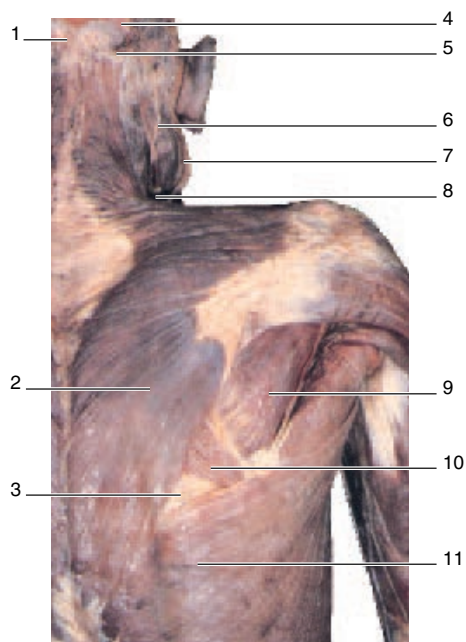


**FIGURE 10.25** Viscera of the thorax. The heart has been coronally sectioned to expose the chambers.



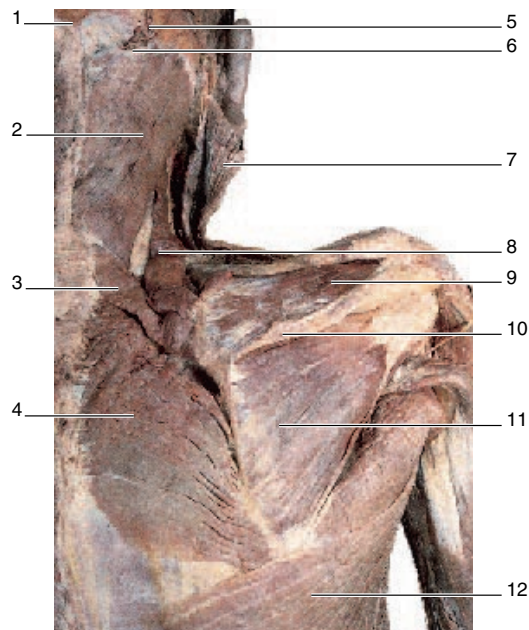
**FIGURE 10.26** The thoracic cavity with the heart and lungs removed.





- |                                   |                          |
|-----------------------------------|--------------------------|
| 1 External occipital protuberance | 6 Lesser occipital n.    |
| 2 Trapezius m.                    | 7 Sternocleidomastoid m. |
| 3 Triangle of auscultation        | 8 Great auricular n.     |
| 4 Occipital a.                    | 9 Infrapinatus m.        |
| 5 Greater occipital n.            | 10 Rhomboideus major m.  |
|                                   | 11 Latissimus dorsi m.   |

**FIGURE 10.27** A posterior view of the superficial muscles of the right thorax and neck.



- |                                   |                                |
|-----------------------------------|--------------------------------|
| 1 External occipital protuberance | 7 Sternocleidomastoid m. (cut) |
| 2 Splenius capitis m.             | 8 Levator scapulae m.          |
| 3 Rhomboideus minor m.            | 9 Supraspinatus m.             |
| 4 Rhomboideus major m.            | 10 Spine of scapula            |
| 5 Occipital a.                    | 11 Infrapinatus m.             |
| 6 Great occipital n.              | 12 Latissimus dorsi m.         |

**FIGURE 10.28** A posterior view of the deep structures of the right thorax and neck.

The rib cage is formed by the sternum, the costal cartilages, and the ribs attached to the thoracic vertebrae. It protects the lungs, several large vessels, and the heart. It also affords a site of attachment for the muscles of the thorax, upper extremities, back, and diaphragm. The principal organs of the respiratory and circulatory systems are located within the thorax, and the esophagus of the digestive system passes through the thorax. Because the viscera of the thoracic cavity are vital organs, the thorax is of immense clinical importance.

### Abdomen

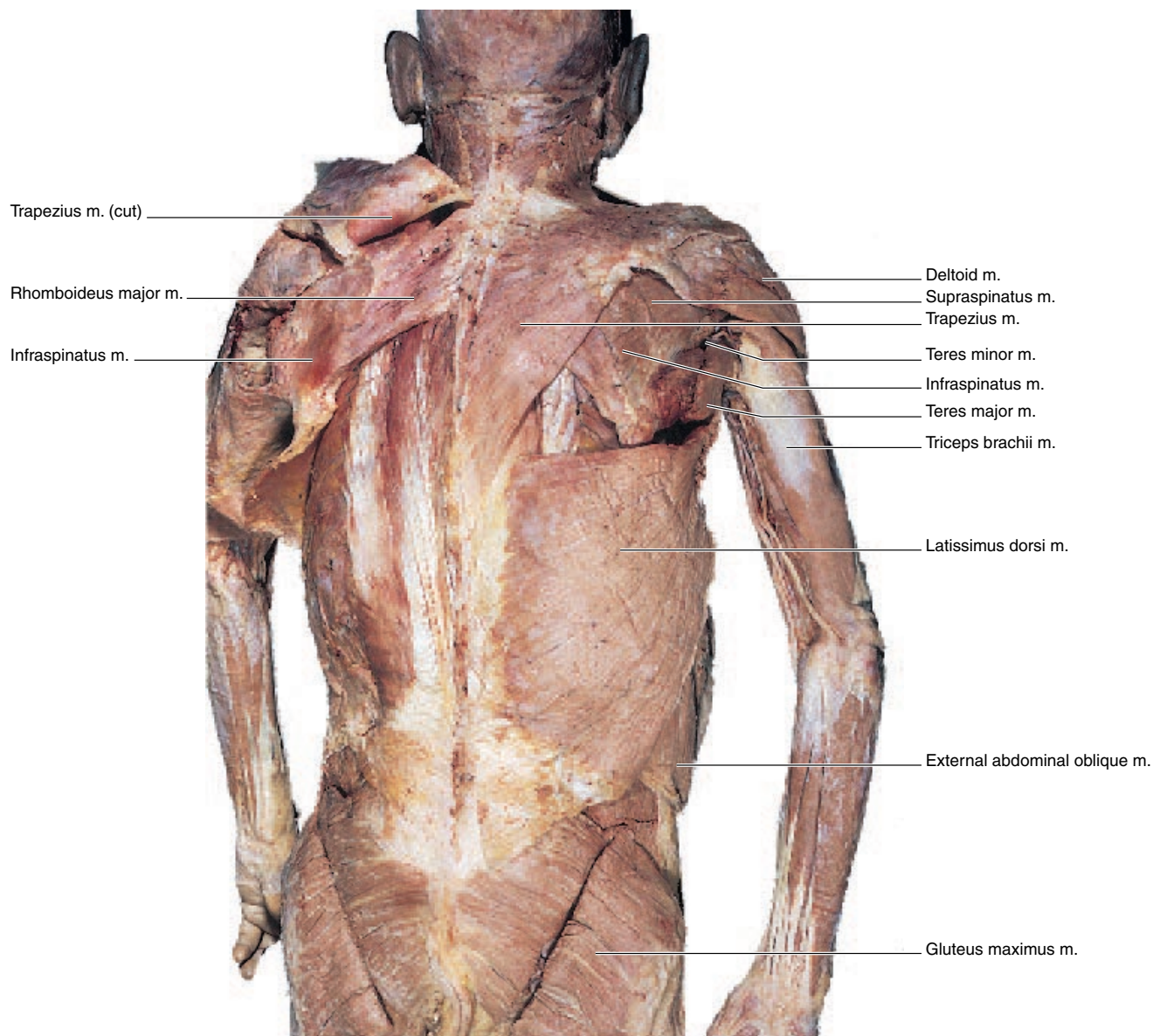
The cavity of the abdomen contains the stomach and intestines, the liver and gallbladder, the kidneys and adrenal glands, the spleen, the internal genitalia, and major vessels and

nerves. Because of the domed shape of the diaphragm, some of the abdominal viscera are protected by the rib cage. The abdominal region is shown in photographs of cadavers in figures 10.30, 10.31, and 10.32.

### ✓ Knowledge Check

- Which structures of the trunk can be readily observed? Which can be palpated?
- Where are the common auscultation sites of the trunk located?
- Why are the linea alba, costal margins, linea semilunaris, and McBurney's point important landmarks?





**FIGURE 10.29** A posterior view of the trunk with deep muscles exposed on the left.

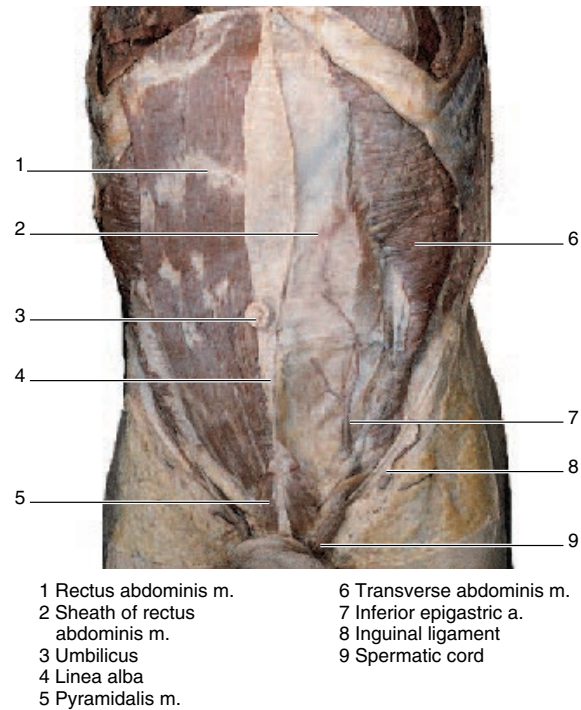


FIGURE 10.30 An anterior view of the structures of the abdominal wall.

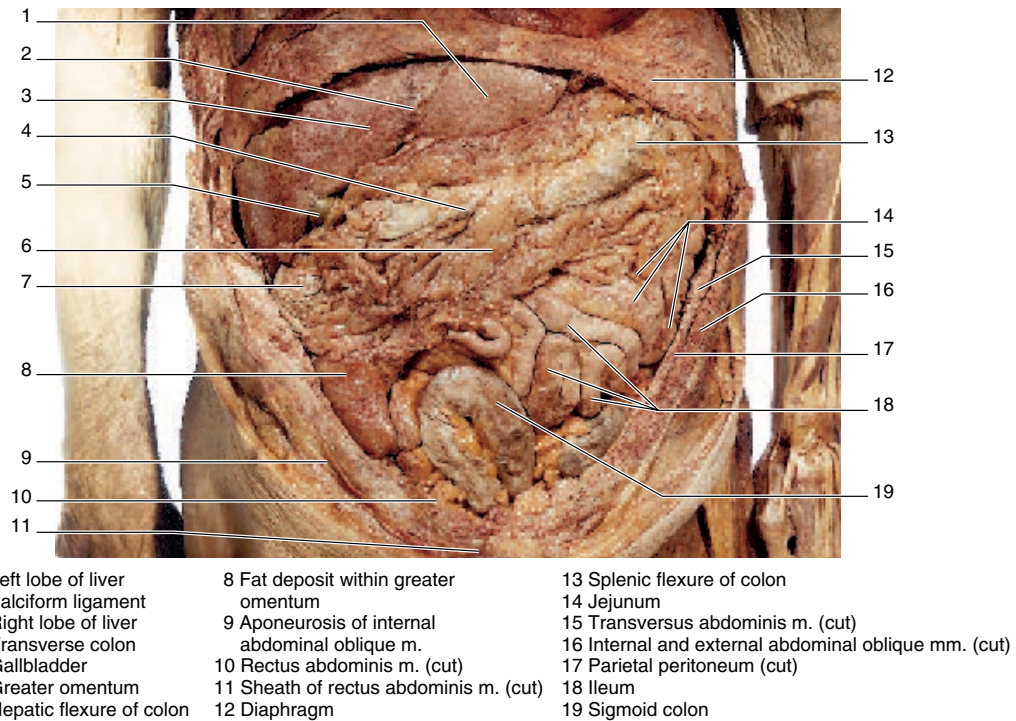
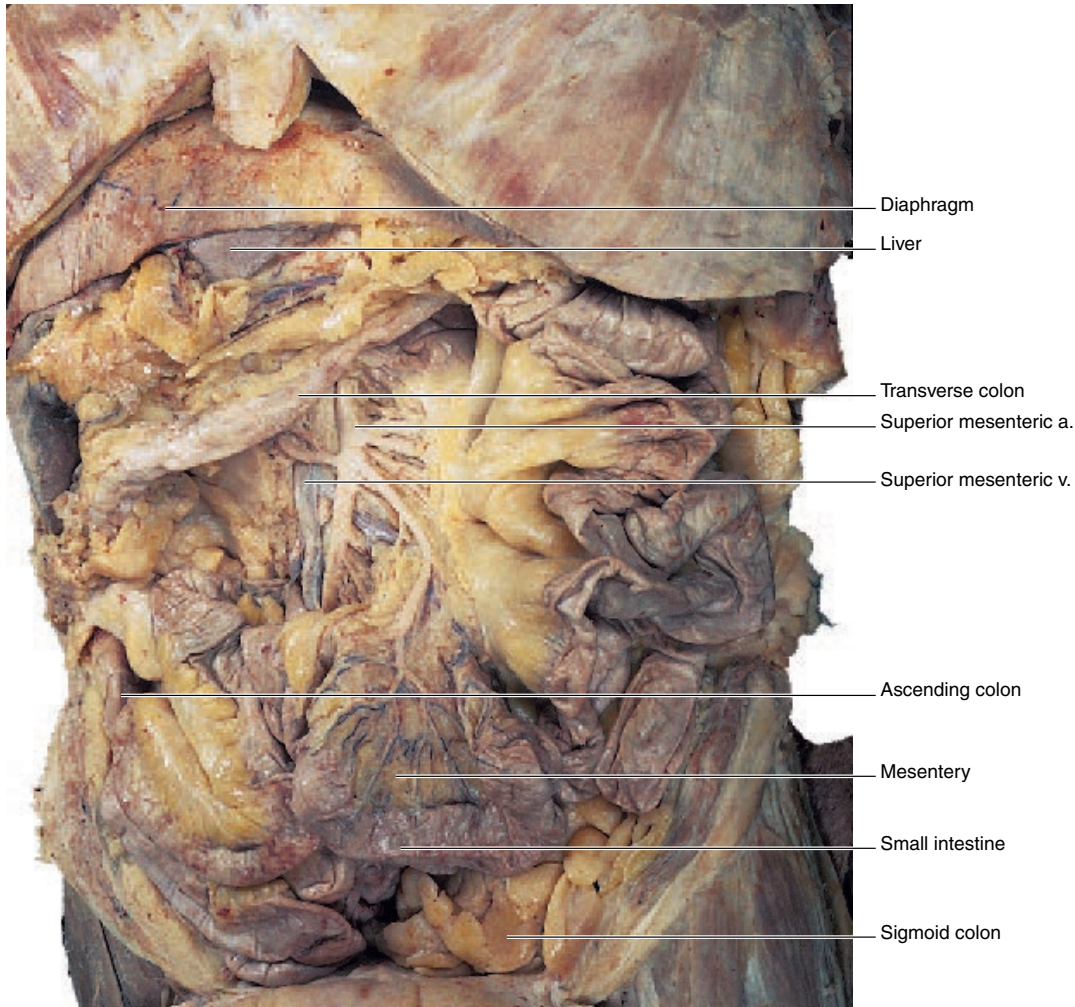


FIGURE 10.31 An anterior view of the abdominal viscera.



**FIGURE 10.32** An anterior view of the abdominal viscera with the greater omentum removed and the small intestine displaced to the left.

## PELVIS AND PERINEUM

The surface features of the pelvic region are important primarily to identify reproductive organs and clinical problems of these organs.

**Objective 12** Describe the location of the perineum and list the organs of the pelvic and perineal regions.

The important bony structures of the **pelvis** include the crest of the ilium and the symphysis pubis, located anteriorly, and the ischium and coccyx, which are palpable posteriorly. An **inguinal** (*ing'wī-nal*) **ligament** extends from the anterior superior iliac spine to the symphysis pubis and is clinically important because

inguinal: L. *inguinalis*, groin

hernias may occur along it. Although the inguinal ligament cannot be seen, an oblique groove overlying the ligament is an apparent surface feature.

The **perineum** (*per'ī-ne'um*) (see fig. 2.17) is the region that contains the external sex organs and the anal opening. The surface features of this region are further discussed in chapters 20 and 21. The surface anatomy of the perineum of a female becomes particularly important during parturition.

## ✓ Knowledge Check

15. Define the term *perineum*. What structures are located within the perineum?
16. List three body systems that have openings within the pelvic region.



## SHOULDER AND UPPER EXTREMITY

The anatomy of the shoulder and upper extremity is of clinical importance because of frequent trauma to these body regions. In addition, vessels of the upper extremity are used as pressure points and as sites for venipuncture for drawing blood, providing nutrients and fluids, and administering medicine.

**Objective 13** Identify various surface features of the shoulder and upper extremity by observation or palpation.

**Objective 14** Discuss the clinical importance of the axilla, cubital fossa, and wrist.

### Surface Anatomy


#### Shoulder

The scapula, clavicle, and proximal portion of the humerus are the bones of shoulder, and portions of each of them are important surface landmarks in this region. Posteriorly, the spine of the scapula and acromion are subcutaneous and easily located.

The acromion and clavicle, as well as several large shoulder muscles, can be seen anteriorly (fig. 10.33). The rounded curve of the shoulder is formed by the thick deltoid muscle that covers the greater tubercle of the humerus. The deltoid muscle frequently serves as a site for intramuscular injections. The large pectoralis major muscle is prominent as it crosses the shoulder joint and attaches to the humerus. A small depression, the **clavipectoral triangle** (fig. 10.33), is situated below the clavicle and is bounded on either side by the deltoid and pectoralis major muscles.

#### Axilla

The axilla is commonly called the armpit. This depressed region of the shoulder supports axillary hair in sexually mature individuals. The axilla is clinically important because of the subcutaneous position of vessels, nerves, and lymph nodes in this region. Two muscles form the anterior and posterior borders (fig. 10.34). The anterior axillary fold is formed by the pectoralis major muscle, and the posterior axillary fold consists primarily of the latissimus dorsi muscle as it extends from the lumbar vertebrae to the humerus. Axillary lymph nodes are palpable in some individuals.

 In sexually mature females, the lateral process of the mammary gland, which is positioned on the pectoralis major muscle (see figs. 9.22 and 10.21), extends partially into the axilla. In doing a *breast self-examination* (see fig. 21.22), a woman should palpate the axillary area as well as the entire breast because the lymphatic drainage pathway is toward the axilla (see fig. 21.18).

Supraclavicular  
fossa

Trapezius m.

Acromion of scapula

Deltoid m.

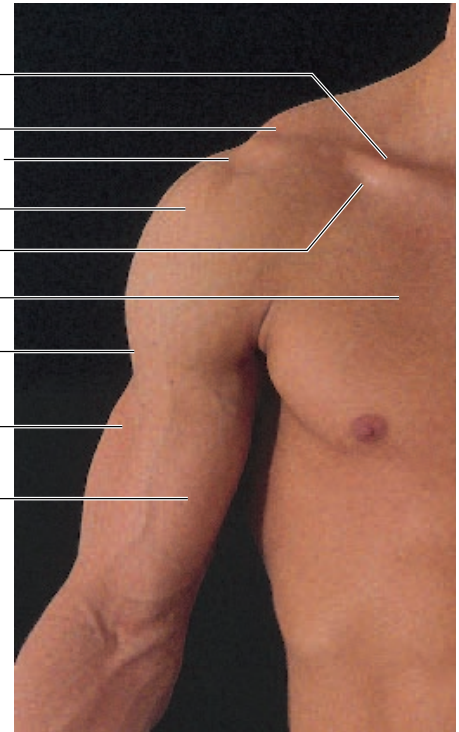
Clavipectoral  
triangle

Pectoralis major m.

Insertion of  
deltoid m.

Triceps brachii m.

Biceps brachii m.



**FIGURE 10.33** An anterior view of the right shoulder region.

#### Brachium

Several muscles are clearly visible in the brachium (figs. 10.34 and 10.35). The belly of the biceps brachii muscle becomes prominent when the elbow is flexed. While the arm is in this position, the deltoid muscle can be traced as it inserts on the humerus. The triceps brachii muscle forms the bulk of the posterior surface of the brachium. A groove forms on the medial side of the brachium between the biceps brachii and triceps brachii muscles, where pulsations of the brachial artery may be felt as it carries blood toward the forearm (see fig. 10.37). This region is clinically important because it is where arterial blood pressure is taken with a sphygmomanometer. It is also the place to apply pressure in case of severe arterial hemorrhage in the forearm or hand.

Three bony prominences can be located in the region of the elbow (fig. 10.36). The medial and lateral epicondyles are processes on the humerus, whereas the olecranon is a proximal process of the ulna. When the elbow is extended, these prominences lie on the same transverse plane; when the elbow is flexed, they form a triangle. The ulnar nerve can be palpated in the **ulnar sulcus** (groove) posterior to the medial epicondyle (see fig. 7.5). This sulcus and the accompanying ulnar nerve is commonly known as the “funny bone,” or “crazy bone.”

320 Unit 4 Support and Movement

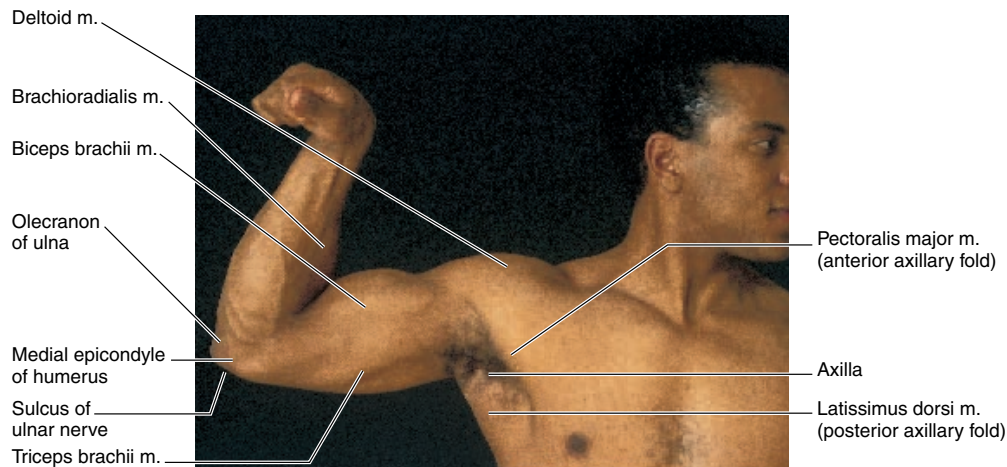


FIGURE 10.34 An anterior view of the right shoulder region and upper extremity.

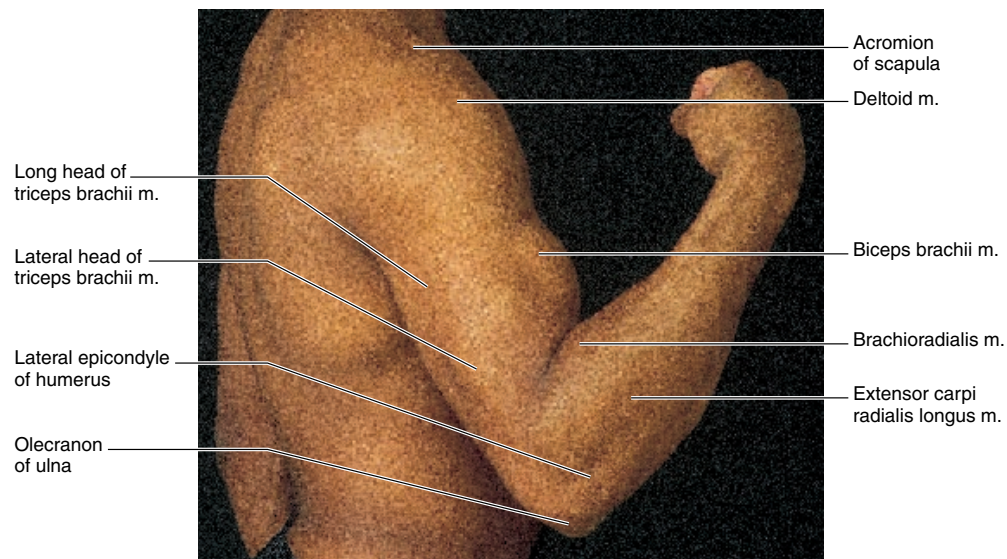


FIGURE 10.35 A lateral view of the upper extremity.

The **cubital fossa** is the depression on the anterior surface of the elbow region, where the median cubital vein links the cephalic and basilic veins. These veins are subcutaneous and become more conspicuous when a proximal compression is applied. For this reason, they are an important location (particularly the median cubital) for the removal of venous blood for analyses and transfusions or for intravenous therapy (fig. 10.37).

### Antebrachium

Contained within the antebrachium (forearm) are two parallel bones (the ulna and radius) and the muscles that control the movements of the hand. The muscles of the forearm taper distally over the wrist, where their tendons attach to various bones of the hand. Several muscles of the forearm can be identified as surface features and are depicted in figures 10.37 and 10.38.

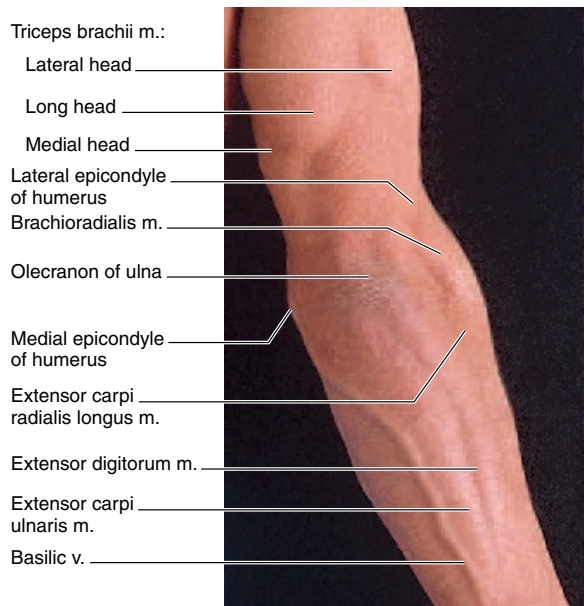


FIGURE 10.36 A posterior view of the elbow.

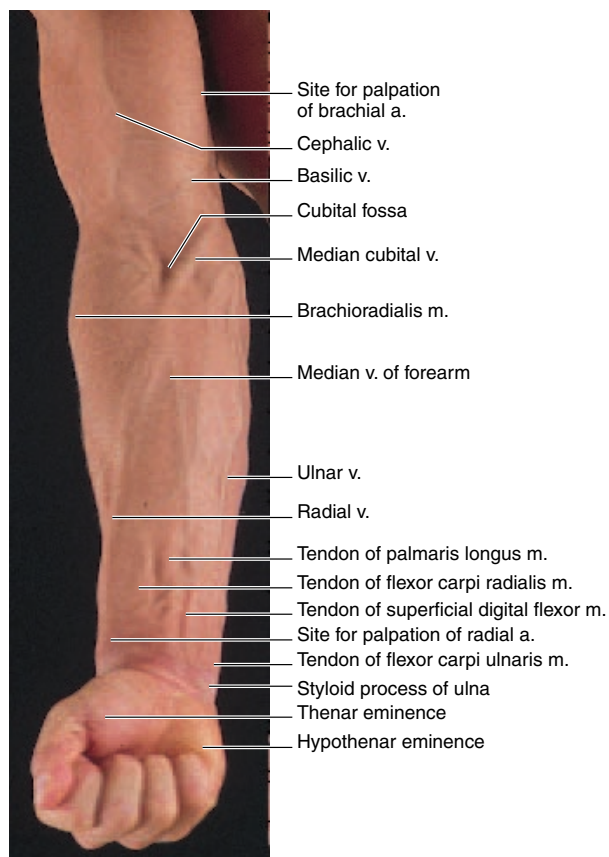


FIGURE 10.37 An anterior view of the forearm and hand.

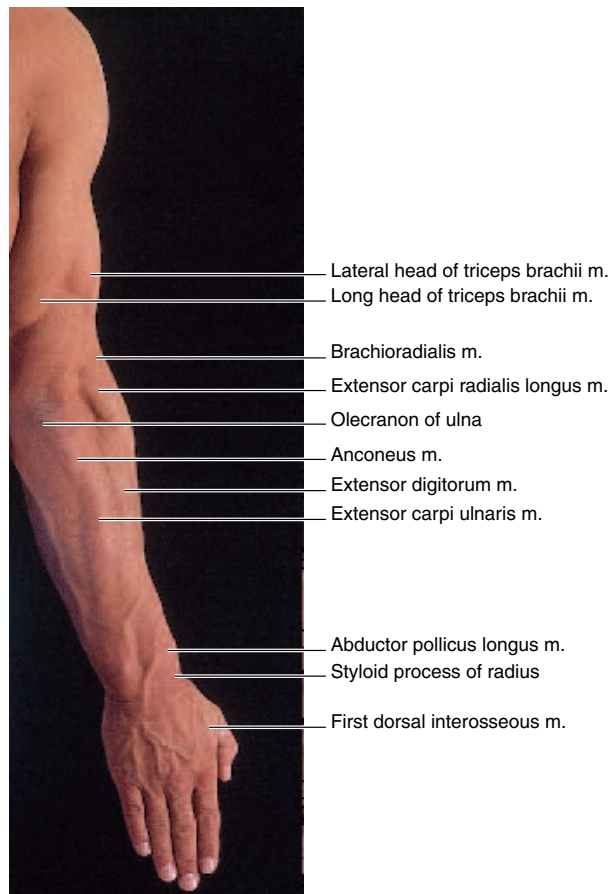
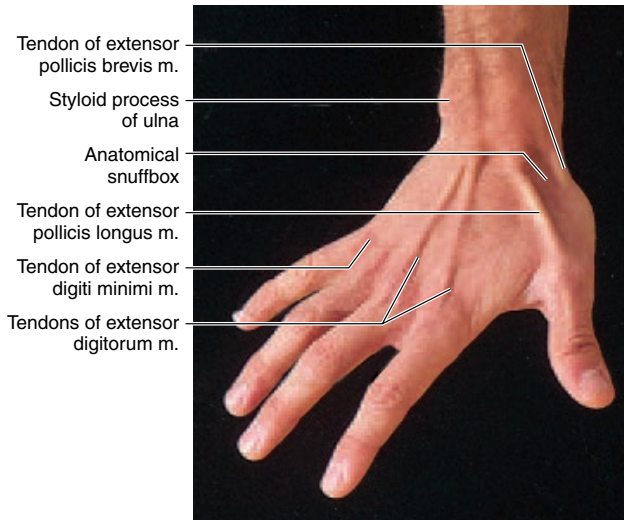


FIGURE 10.38 A posterior view of the forearm and hand.

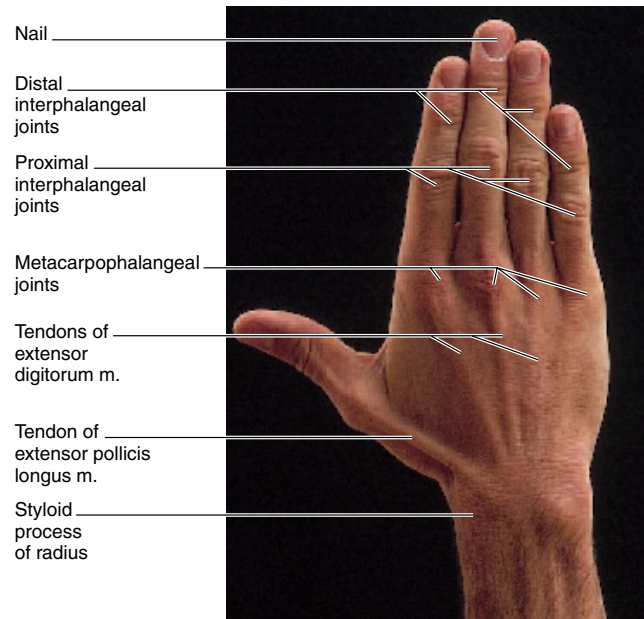
Because of the frequency of fractures involving the forearm, bony landmarks are clinically important when setting broken bones. The ulna can be palpated along its entire length from the olecranon to the styloid process. The distal half of the radius is palpable as the forearm is rotated, and its styloid process can be located.

Nerves, tendons, and vessels are close to the surface at the wrist, making cuts to this area potentially dangerous. Tendons from four flexor muscles can be observed as surface features if the anterior forearm muscles are strongly contracted while making a fist. The tendons that can be observed along this surface, from lateral to medial, are from the following muscles: flexor carpi radialis, palmaris longus, superficial digital flexor, and flexor carpi ulnaris. The median nerve going to the hand is located under the tendon of the palmaris longus muscle (see fig. 10.37), and the ulnar nerve is lateral to the tendon of





**FIGURE 10.39** An posteromedial view of the right hand showing the anatomical snuffbox.



**FIGURE 10.40** A posterior view of the hand.

the flexor carpi ulnaris muscle. The radial artery lies along the surface of the radius, immediately lateral to the tendon of the flexor carpi radialis muscle. This is the artery commonly used when monitoring the pulse. By careful palpation, pulsations can also be detected in the ulnar artery, lateral to the tendon of the flexor carpi ulnaris.

Two tendons that attach to the thumb can be seen on the posterior surface of the wrist as the thumb is extended backward. The tendon of the extensor pollicis brevis muscle is positioned anterolaterally along the thumb, and the tendon of the extensor pollicis longus muscle lies posteromedially (fig. 10.39). The depression created between these two tendons as they are pulled taut is referred to as the *anatomical snuffbox*. Pulsations of the radial artery can be detected in this depression.

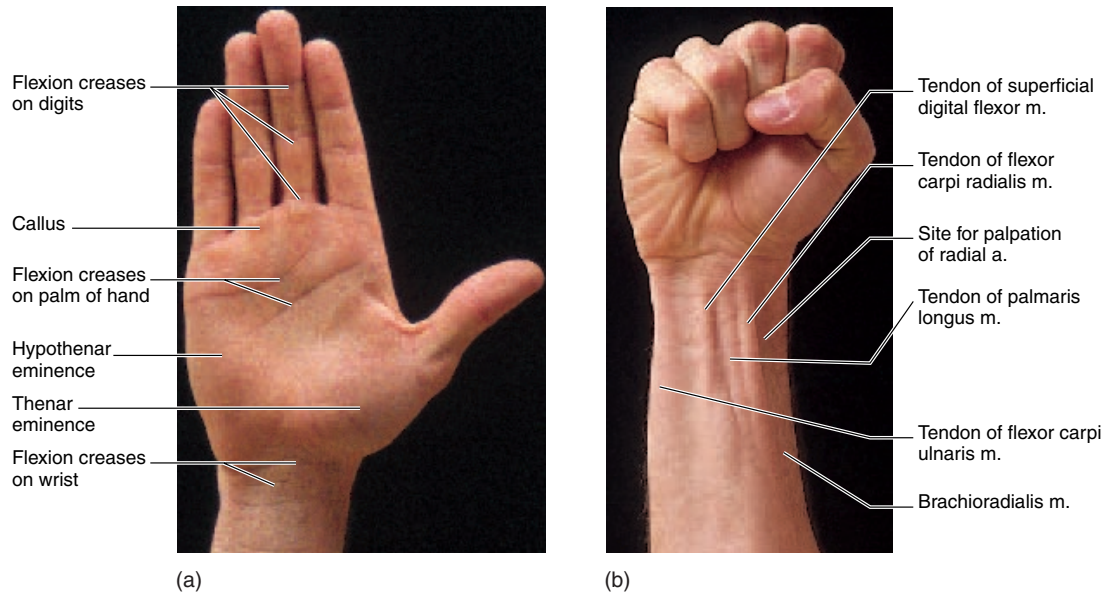
The median nerve, which serves the opponens pollicis muscle of the thumb, is the nerve most commonly injured by stab wounds or the penetration of glass into the wrist or hand. Severing of this nerve paralyzes a major muscle of the thumb; it wastes away, resulting in an inability to oppose the thumb in grasping.

## Hand

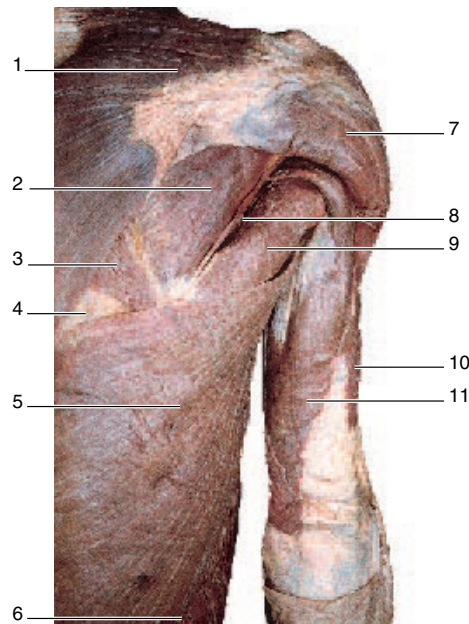
Much of the surface anatomy of the hand, such as flexion creases, fingerprints, and fingernails, involves features of the skin discussed in chapter 5. Other surface features are the extensor tendons from the extensor digitorum muscle, which can be seen going to each of the fingers on the back side of the hand as the digital joints are extended (fig. 10.40). The knuckles of the hand are the distal ends of the second through the fifth metacarpal bones. Each of the joints of the fingers and the individual phalanges can be palpated. The **thenar** (*the'nar*) **eminence** is the thickened, muscular portion of the hand that forms the base of the thumb (fig. 10.41).

## Internal Anatomy

The internal anatomy of the shoulder and upper extremity includes the structures of the shoulder, brachium, cubitus (elbow), antebrachium, and hand. The principal structures of these regions are shown in the cadaver dissections in figures 10.42 through 10.46.

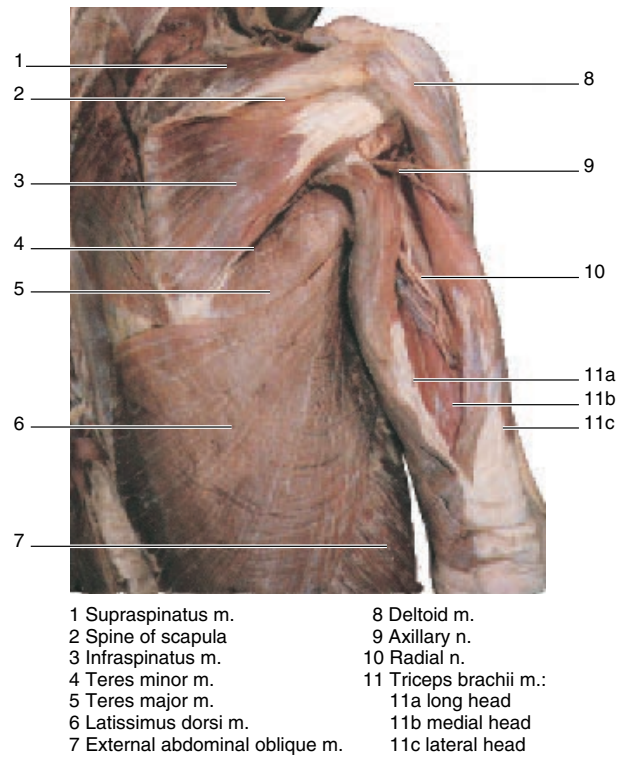


**FIGURE 10.41** An anterior view of the wrist and hand (a) with the hand open and (b) with a clenched fist.

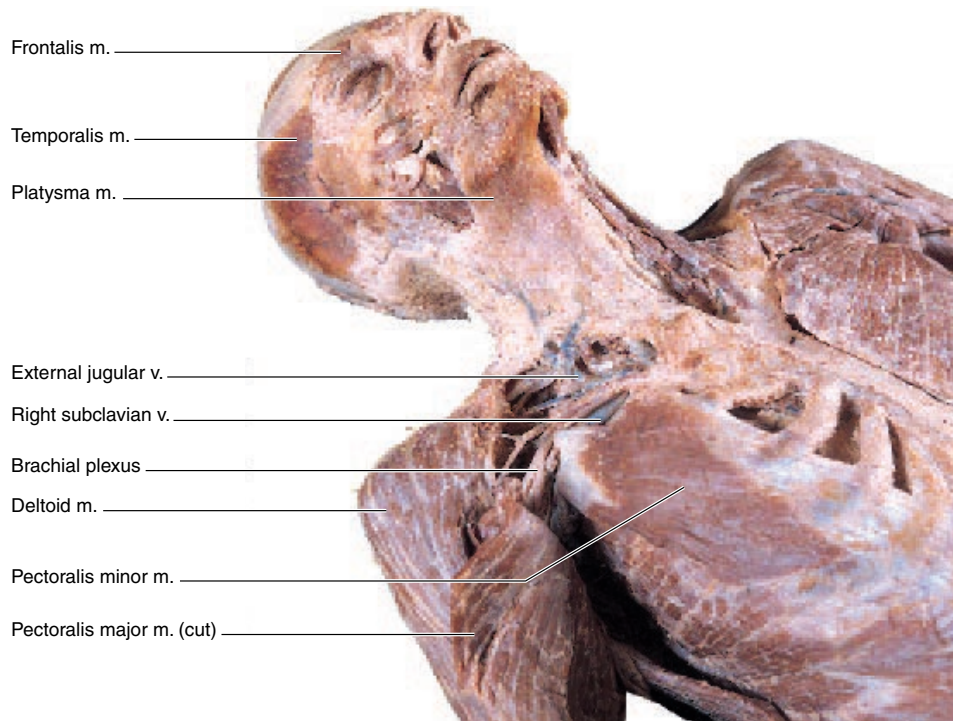


- 1 Trapezius m.
- 2 Infraspinatus m.
- 3 Rhomboideus major m.
- 4 Triangle of auscultation
- 5 Latissimus dorsi m.
- 6 External abdominal oblique m.
- 7 Deltoid m.
- 8 Teres minor m.
- 9 Teres major m.
- 10 Lateral head of triceps brachii m.
- 11 Long head of triceps brachii m.

**FIGURE 10.42** A posterior view of the superficial muscles of the right shoulder and brachium.

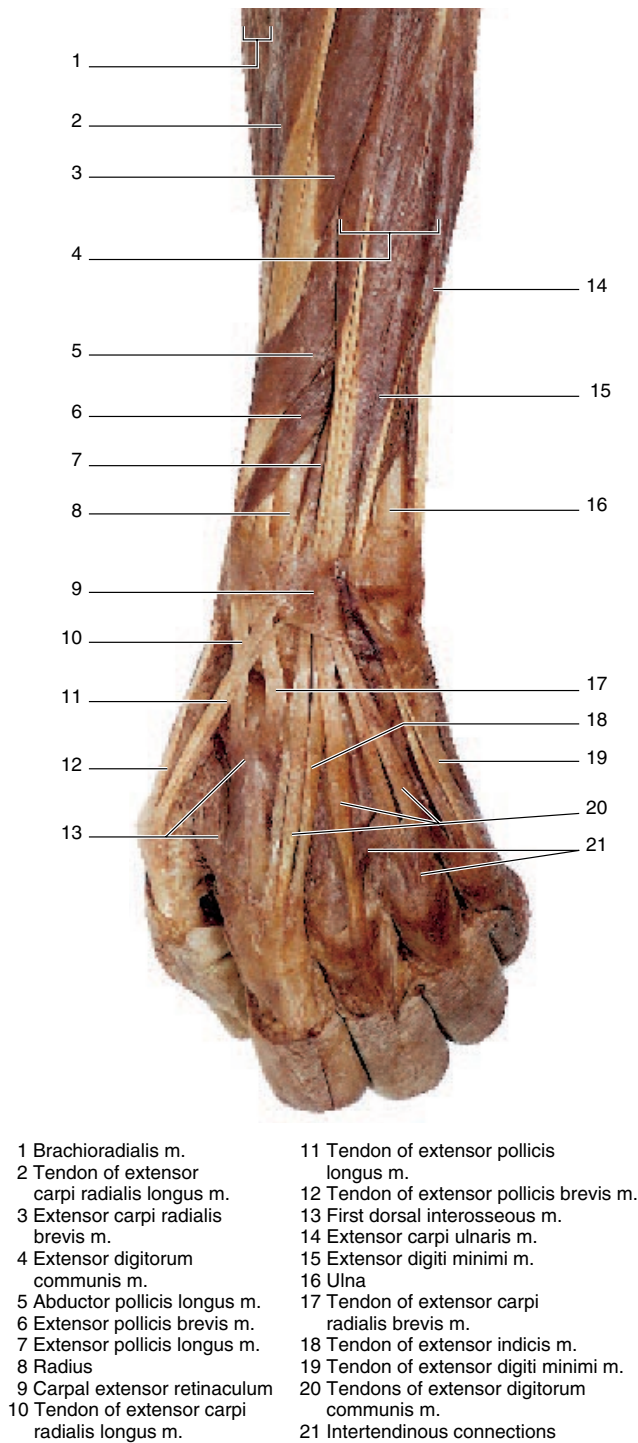


**FIGURE 10.43** An anterior view of the right shoulder and brachial regions.

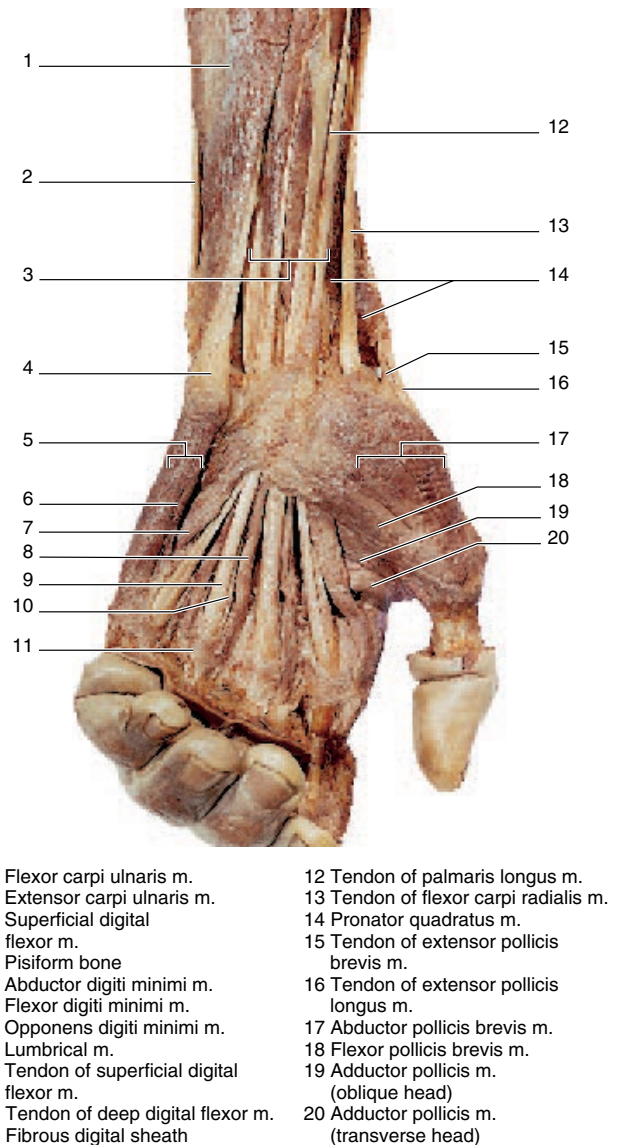


**FIGURE 10.44** An anterolateral view of the head, neck, and thorax.





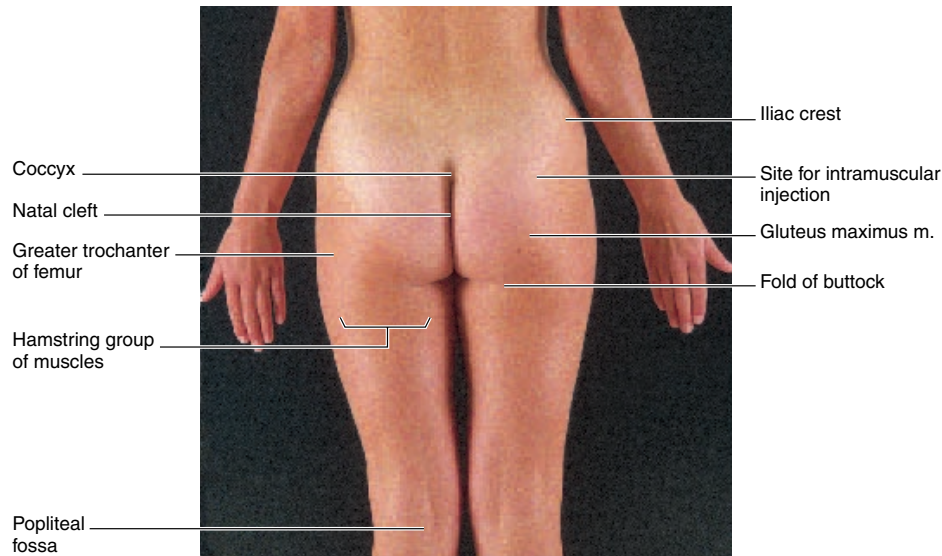
**FIGURE 10.45** An posterior view of the left forearm and hand.



**FIGURE 10.46** An anterior view of the left forearm and hand.

## ✓ Knowledge Check

- List the clinically important structures that can be observed or palpated in the shoulder and upper extremity.
- Describe the locations of the axilla, brachium, cubital fossa, and wrist.
- Bumping the ulnar nerve causes a tingling sensation along the medial part of the forearm and into the little finger of the hand. What does this tell you about its distribution?
- Which of the two bones of the forearm is the more stationary as the arm is rotated?



**FIGURE 10.47** The buttocks and the posterior aspect of the thigh. (Note the relation of the angle of the elbow joint to the pelvic region, which is characteristic of females.)

## BUTTOCK AND LOWER EXTREMITY

The massive bones and muscles of the buttock and lower extremity are important as weight-bearers and locomotors. Many of the surface features of these regions are important with respect to locomotion or locomotor dysfunction.

**Objective 15** Identify various surface features of the buttock and lower extremity by observation or palpation.

**Objective 16** Discuss the clinical importance of the buttock, femoral triangle, popliteal fossa, ankle, and arches of the foot.

### Surface Anatomy

#### Buttock

The superior borders of the buttocks, or *gluteal region*, are formed by the iliac crests (fig. 10.47). Each crest can be palpated medially to the level of the second sacral vertebra. From this point, the **natal cleft** (*gluteal cleft*) extends vertically to separate the buttocks into two prominences, each formed by pads of fat and by the massive gluteal muscles. An ischial tuberosity can be palpated in the lower portion of each buttock. In a sitting position, the ischial tuberosities support the weight of the body. When standing, these processes are covered by the gluteal muscles. The sciatic nerve, which is the major nerve to the lower extremity, lies deep to the gluteus maximus muscle. The inferior border of the gluteus maximus muscle forms the **fold of the buttock**.

Because of the thickness of the gluteal muscles and the rich blood supply, the buttock is a preferred site for intramuscular injections. Care must be taken, however, not to inject into the sciatic nerve. For this reason, the surface landmark of the iliac crest is important. The injection is usually administered 5–7 cm (2–3 in.) below the iliac crest, in what is known as the upper lateral quadrant of the buttock.

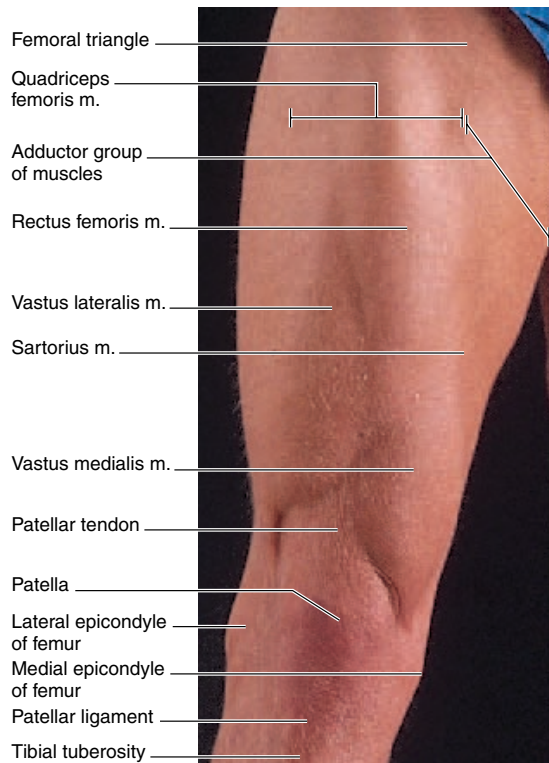
#### Thigh

The femur is the only bone of the thigh, but there are three groups of thigh muscles. The anterior group of muscles, referred to as the *quadriceps femoris*, extends the knee joint when it is contracted (fig. 10.48). The medial muscles are the adductors, and when contracted they draw the thigh medially. The “hamstrings” are positioned on the posterior aspect of the thigh (see fig. 10.47) and serve to extend the hip joint, as well as flex the knee joint, when they are contracted. The tendinous attachments of the hamstrings can be palpated along the posterior aspect of the knee joint when it is flexed. The hamstrings or their attachments are often injured in athletic competition.

The **femoral** (*fem’or-al*) **triangle** is an extremely important element of the surface anatomy of the thigh. It can be seen as a depression inferior to the location of the inguinal ligament on the anteromedial surface in the upper part of the thigh (see fig. 16.32). The major vessels of the lower extremity, as well as the femoral nerve, traverse this region. Hernias are frequent in this area. More important; the femoral triangle serves as an arterial pressure point (see fig. 16.33) in the case of uncontrolled hemorrhage of the lower extremity.

The greater trochanter of the femur can be palpated on the upper lateral surface of the thigh (see fig. 10.47). At the knee, the lateral and medial condyles of the femur and tibia can be identified (fig. 10.48). The patella (“kneecap”) can be easily lo-

## Chapter 10 Surface and Regional Anatomy 327



**FIGURE 10.48** An anterior view of the right thigh and knee.

cated within the patellar tendon, anterior to the knee joint. Stress or injury to this joint may cause swelling, commonly called “water on the knee.”

The depression on the posterior aspect of the knee joint is referred to as the **popliteal** (*pop’lĭ-te’al*) **fossa** (fig. 10.49). This area becomes clinically important in elderly people who suffer degenerative conditions. Aneurysms of the popliteal artery are common, as are popliteal abscesses resulting from infected lymph nodes. The small saphenous vein as it traverses the popliteal fossa may become varicose in the elderly.


## Leg

Portions of the tibia and fibula, the bones of the leg, can be observed as surface features. The medial surface and anterior border (commonly called “shin”) of the tibia are subcutaneous and are palpable throughout their length. At the ankle, the medial malleolus of the tibia and the lateral malleolus of the fibula are easy to observe as prominent eminences (fig. 10.50). Of clinical

importance in setting fractures of the leg is knowing that the top of the medial malleolus lies about 1.3 cm (0.6 in.) proximal to the level of the tip of the lateral malleolus.


The heel is not part of the leg; rather, it is the posterior part of the calcaneus. It warrants mention with the leg, however, because of its functional relationship to it. The **tendo calcaneus** (tendon of Achilles) is the strong, cordlike tendon that attaches to the calcaneus from the calf of the leg. The muscles forming the belly of the calf are the gastrocnemius and soleus. Pulsations from the posterior tibial artery can be detected by palpating between the medial malleolus and the calcaneus.

The superficial veins of the leg can be observed on many individuals (see fig. 10.2). The great saphenous vein can be seen subcutaneously along the medial aspect of the leg. The less conspicuous small saphenous vein drains the lateral surface of the leg. If these veins become excessively enlarged, they are called *varicose veins*.

 Leg injuries are common among athletes. *Shinsplints*, probably the result of a stress fracture or periosteum damage of the tibia, is a common condition in runners. A fracture of one or both malleoli is caused by a severe twisting of the ankle region. Skiing fractures are generally caused by strong torsion forces on the body of the tibia or fibula.

## Foot

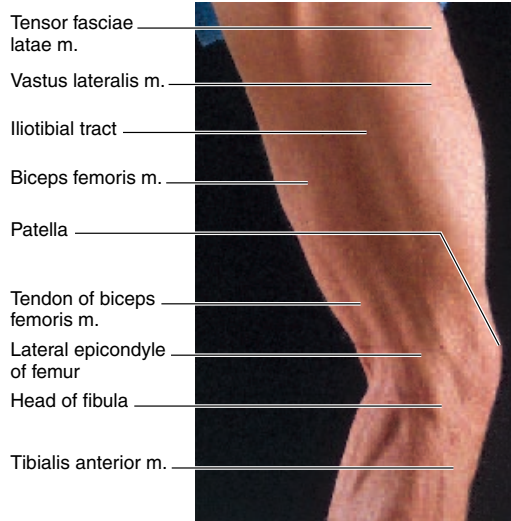
The feet are adapted to support the weight of the body, to maintain balance, and to function mechanically during locomotion. The structural features and surface anatomy of the foot are indicative of these functions. The **longitudinal arch** of the foot, located on the medial portion of the plantar surface (see figs. 7.20 and 10.50b), provides a spring effect when locomoting. The head of the first metatarsal bone forms the medial ball of the foot, just proximal to the hallux (great toe).

 The feet and toes are adapted to endure tremendous compression forces during locomotion. Although appropriate shoes help to minimize trauma to the feet and toes, there is still an array of common clinical conditions (fig. 10.51) that may impede walking or running. An *ingrown toenail* occurs as the sharp edge of a toenail becomes embedded in the skin fold, causing inflammation and pain. *Hammertoe* is a condition resulting from a forceful hyperextension at the metatarsophalangeal joint with flexion at the proximal interphalangeal joint. A *corn* is a cone-shaped horny mass of thickened skin resulting from recurrent pressure on the skin over a bony prominence. Most often it occurs on the outside of the little toe or the upper surfaces of the other toes. *Soft corns* occur between the toes and are kept soft by moisture.

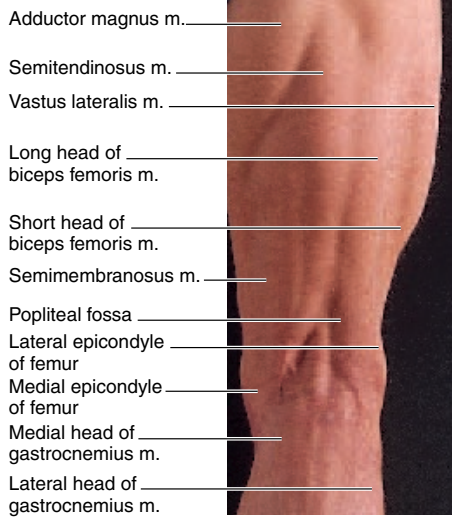
The fifth metatarsal bone forms much of the lateral border of the plantar surface of the foot. The tendons of the extensor digitorum longus muscle can be seen along the superior surface of the foot, especially if the toes are elevated. Pulsations of the dorsal pedal artery can be palpated on the superior surface of the foot between the first and second metatarsal bones. The individual phalanges of the toes, the joints between these bones, and the toenails are obvious surface landmarks.



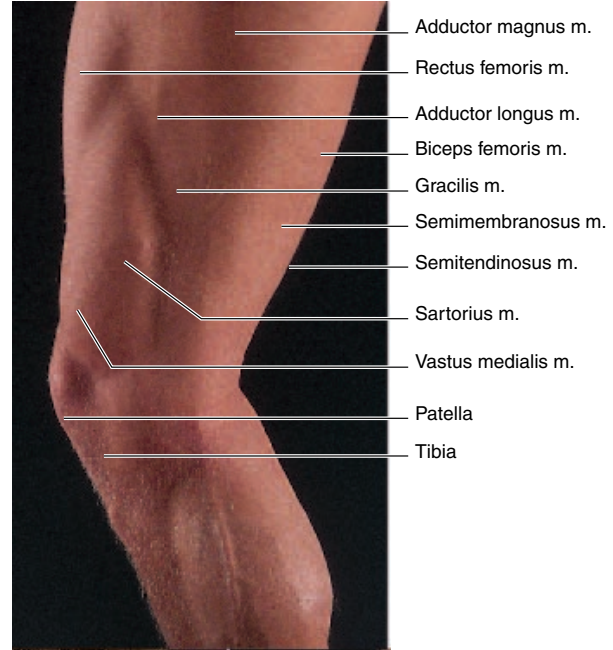
328 Unit 4 Support and Movement



(a)

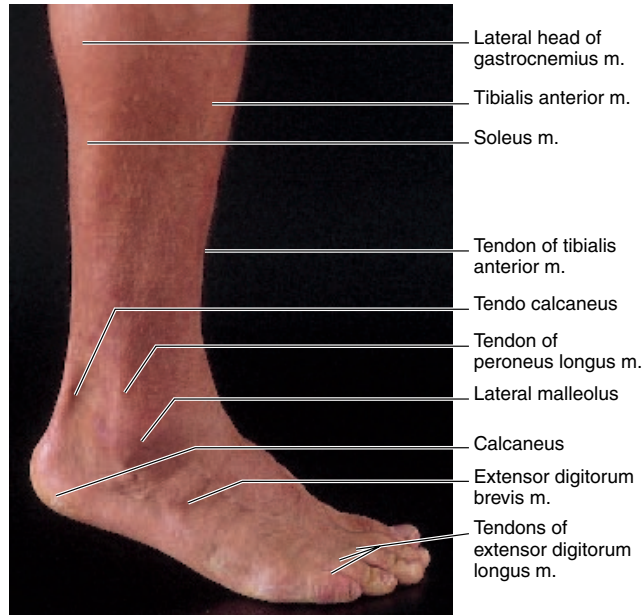


(b)

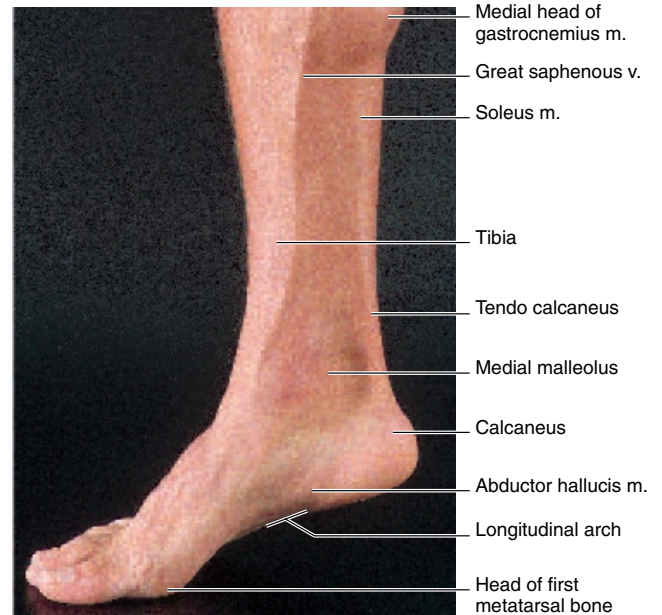


(c)

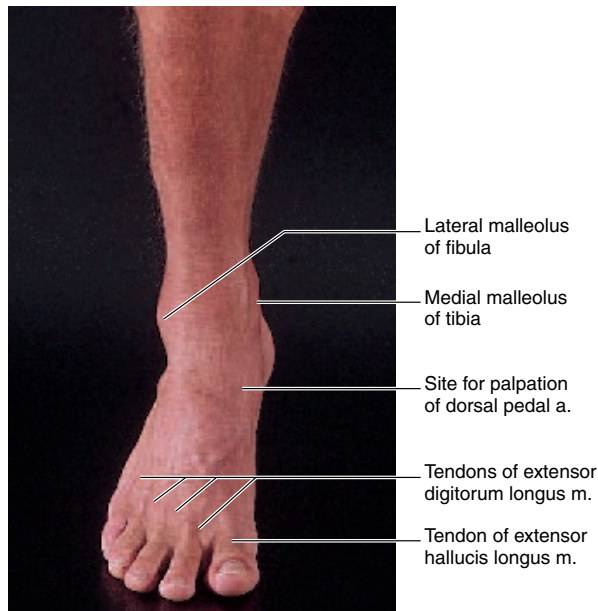
**FIGURE 10.49** The right thigh and knee. (a) A lateral view, (b) a posterior view, and (c) a medial view.



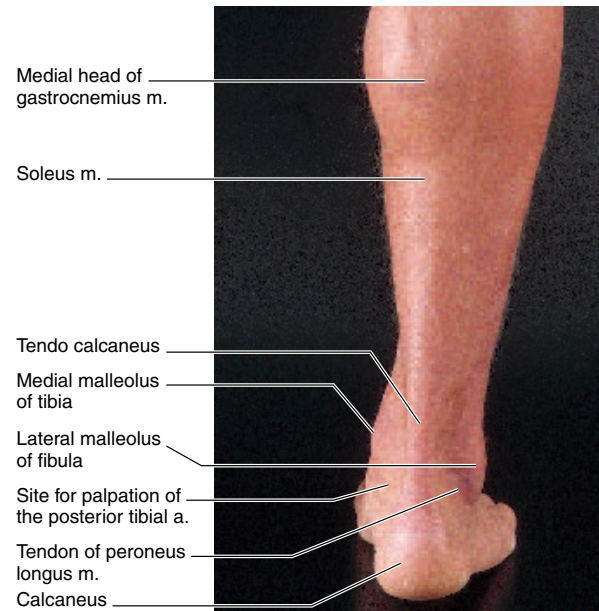
(a)



(b)

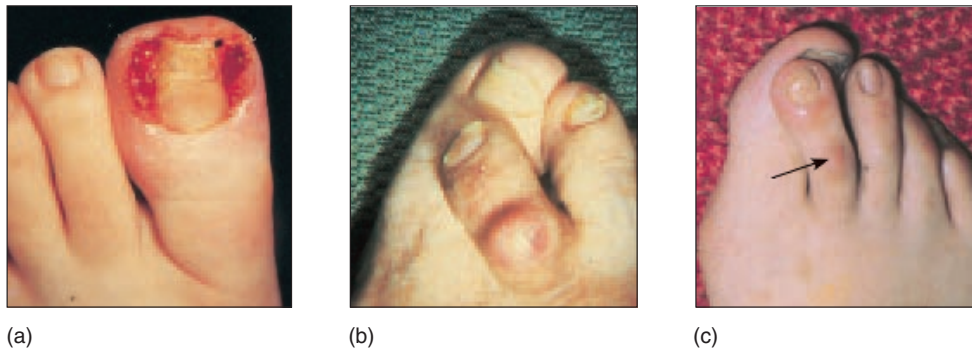


(c)

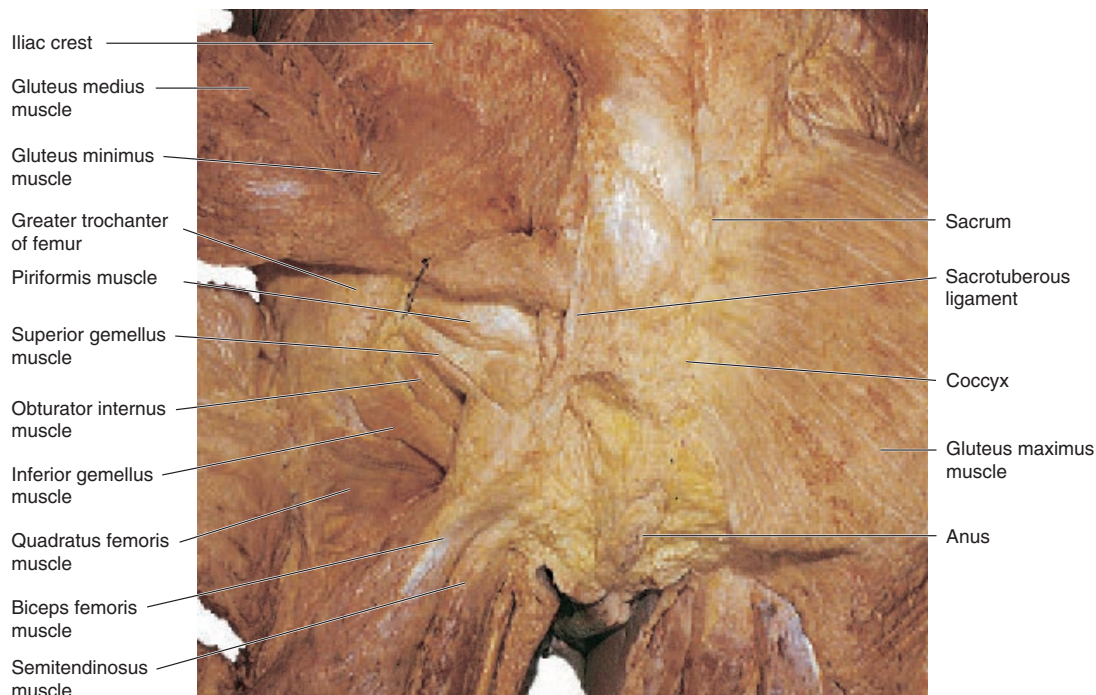

(d)

**FIGURE 10.50** The right leg and foot. (a) A lateral view, (b) a medial view, (c) an anterior view, and (d) a posterior view.



**FIGURE 10.51** Common clinical conditions of the foot and toes. (a) Ingrown toenail, (b) hammertoe, and (c) corn.



**FIGURE 10.52** The gluteal regions; the superficial muscles are shown on the left, and the deep muscles are shown on the right.

## Internal Anatomy

The internal anatomy of the buttock and lower extremity include the structures of the hip, thigh, knee, leg, and foot. The principal structures of these regions are shown in the cadaver dissections in figures 10.52 through 10.57.

### ✓ Knowledge Check

21. What are the surface features that form the boundaries of a buttock?
22. List the clinically important structures that can be observed or palpated in the buttock and lower extremity.

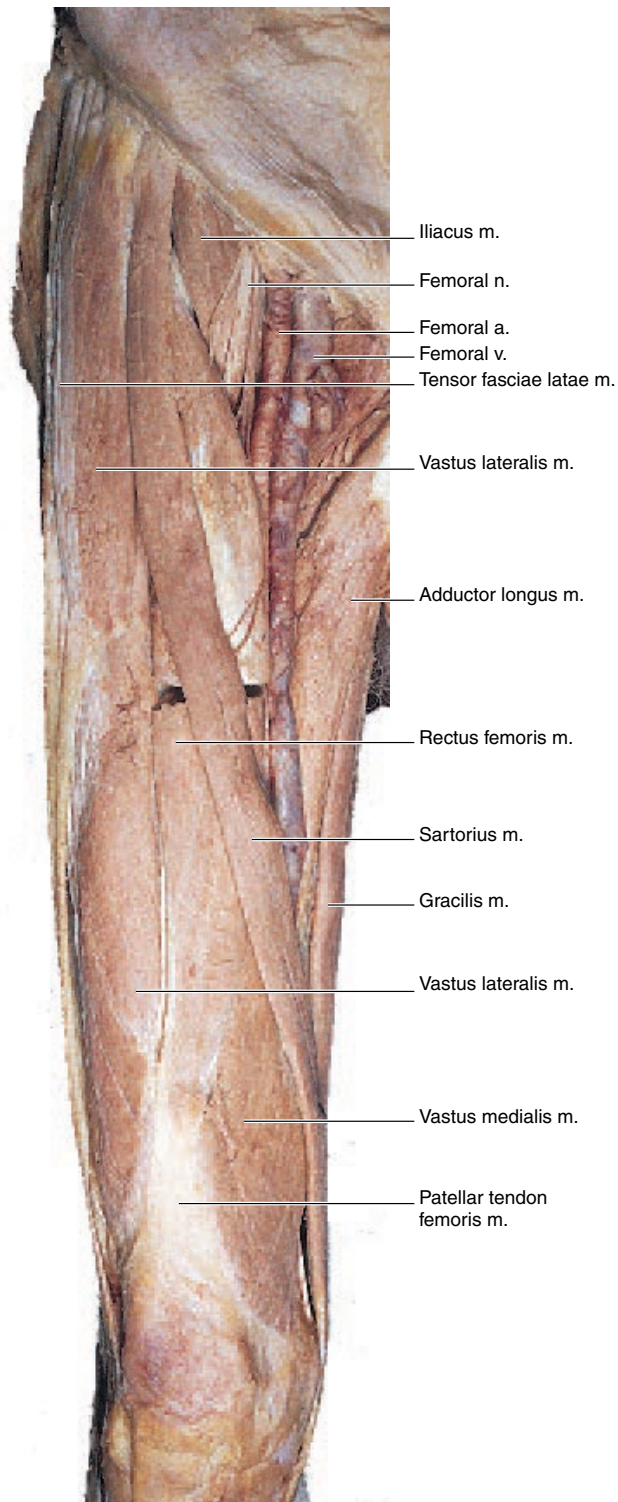
## CLINICAL CONSIDERATIONS

### Head and Neck Regions

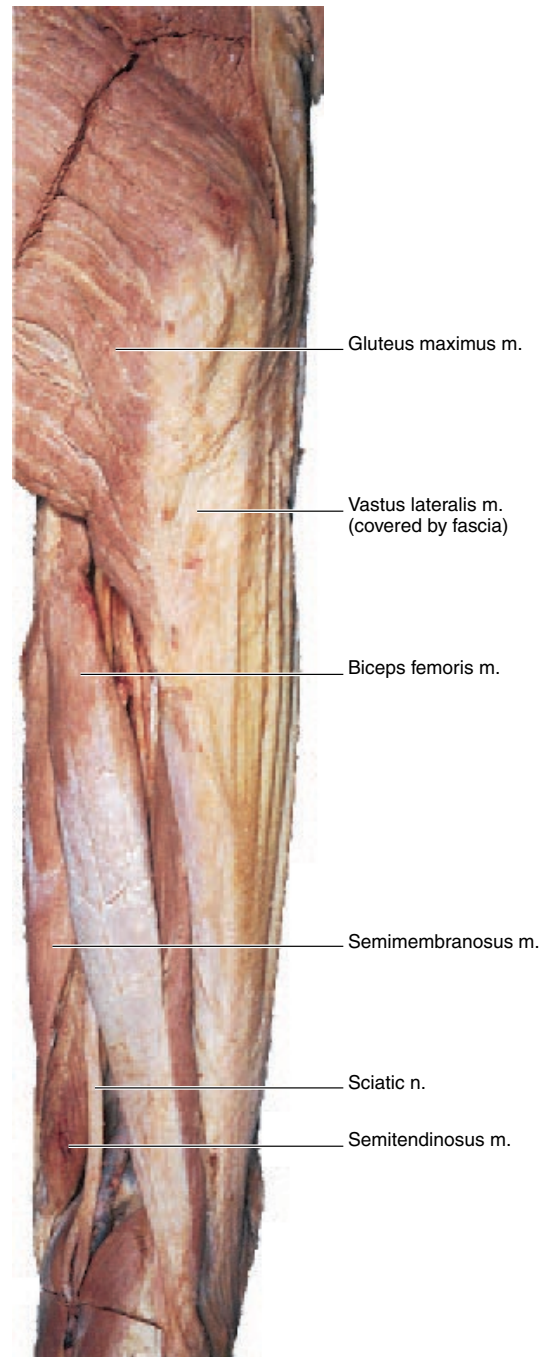
The highly specialized head and neck regions are extremely vulnerable to trauma and disease. Furthermore, because of the incredible complexity of these body regions, they are susceptible to numerous congenital conditions that occur during prenatal development.

The aggressive nature of humans, reflected in part by a penchant for contact sports and fast-moving vehicles, puts the human head and neck in constant danger of injury. Pathogens

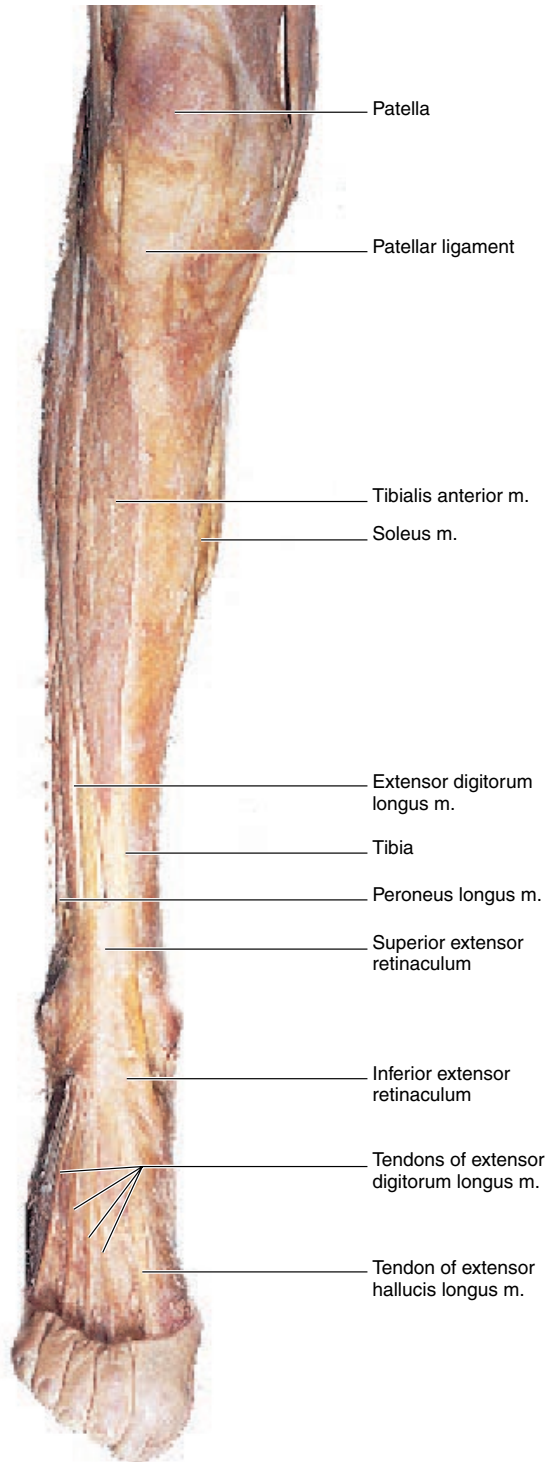




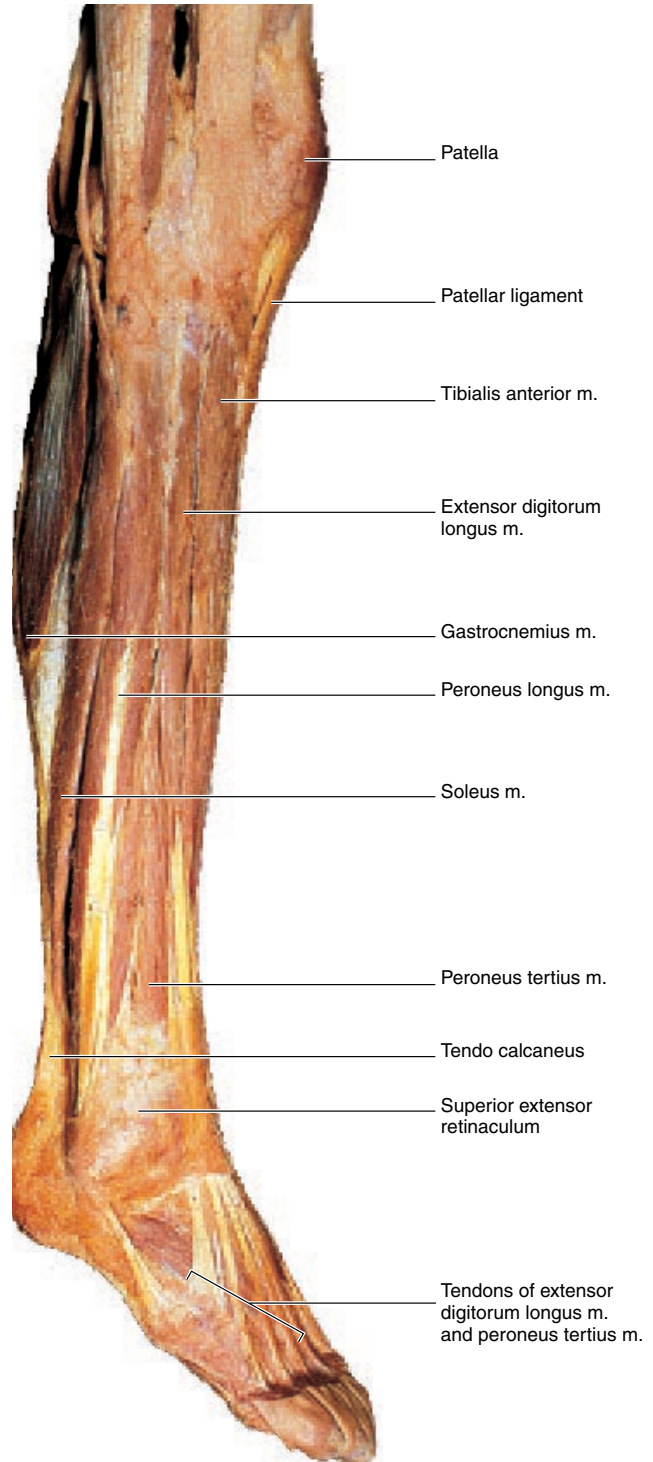
**FIGURE 10.53** An anterior view of the superficial muscles of the right thigh.



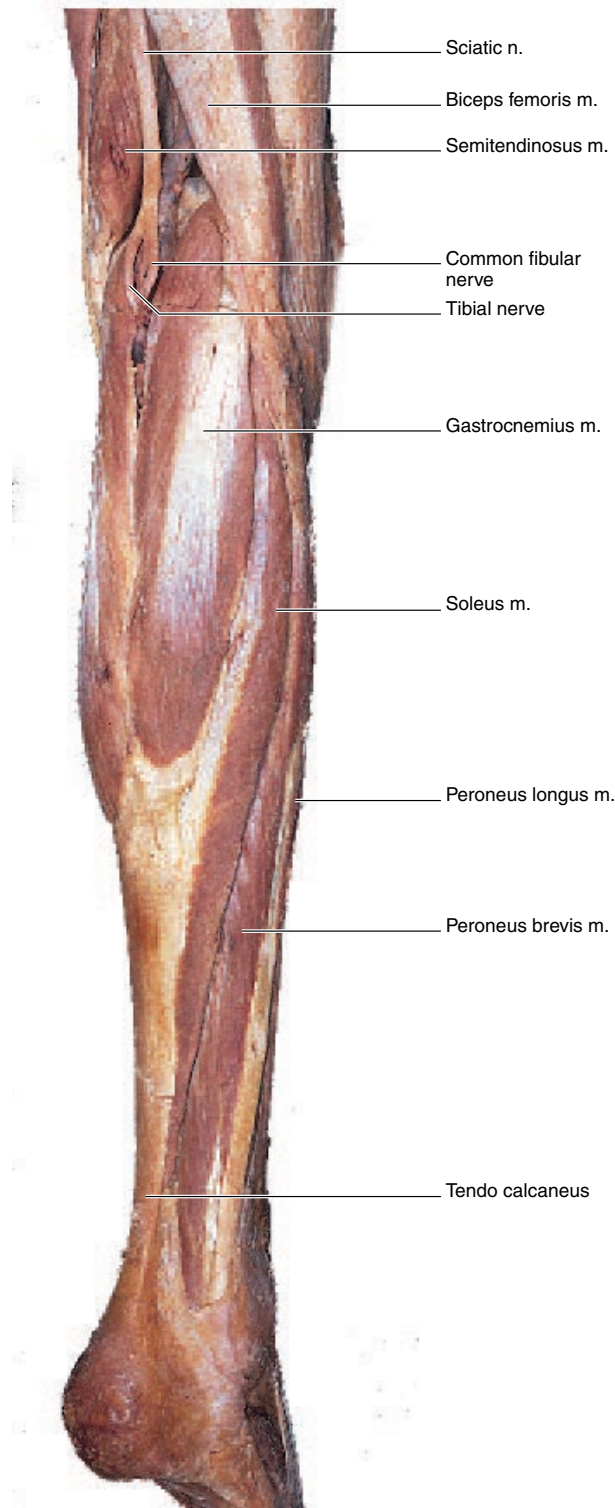
**FIGURE 10.54** A posterior view of the superficial muscles of the right hip and thigh.



**FIGURE 10.55** An anterior view of the superficial muscles of the right leg.



**FIGURE 10.56** A lateral view of the superficial muscles of the right leg.



**FIGURE 10.57** A posterior view of the superficial muscles of the right leg.

readily gain access to the internal structures of the head and neck through the several openings into the head. Also, the risk for contracting certain diseases is greatly increased by the social nature of humans.

### Developmental Conditions

Congenital malformations of the head and neck regions result from genetic or environmental causes and are generally very serious. The less severe malformations may result in functional disability, whereas the more severe malformations usually make life impossible.

**Anencephaly** (*an''en-sef''ă-le*), a severe underdevelopment of the brain and surrounding cranial bones, is always fatal. The cause of anencephaly is unknown, but genetic and geographic factors are believed to be involved. South Wales, for example, reports incidences of anencephaly as high as 1 in every 105 births. It occurs more frequently in females than males, and the damage to the developing embryo occurs between day 16 and day 26 following conception.

Altered cranial bones and sutures, resulting in pressure on the brain, accompany several kinds of congenital conditions. **Microcephaly** is characterized by premature closure of the sutures of the skull. If the child is untreated, underdevelopment of the brain and mental retardation will result. **Cranial encephalocele** (*en-sef''ă-to-sel*) is a condition in which the skull does not develop properly, and portions of the brain often protrude through it. In **hydrocephalus** (*hi''dro-sef''ă-lus*), an excessive accumulation of cerebrospinal fluid dilates the ventricles of the brain and causes a separation of the cranial bones.

A **cleft palate** and **cleft lip** is a common congenital condition of varying degrees of severity. A vertical split on one side, where the maxillary and median nasal processes fail to unite, is referred to as a unilateral cleft. A bilateral, or double, cleft occurs when the maxillary and median nasal process on both sides fail to unite.

By the age of 30, the sutures of the skull normally synostose and cranial bone growth ceases. **Premature synostosis (microcephaly)** is an early union of the cranial sutures before the brain has reached its normal size. **Scaphocephaly** is a malformation in which the sagittal suture prematurely closes. The skull will be noticeably crooked in a condition called **plagiocephaly** (*pla''je-o-sef''ă-le*).

### Trauma to the Head and Neck

The head and neck are extremely susceptible to trauma and blows, which are frequently physically debilitating if not fatal. Striking the head from the front or back often causes **subdural hemorrhage**, resulting from the tearing of the superior cerebral veins at their points of entrance to the superior sagittal sinuses. Blows to the side of the head tend to be less severe because the

synostose: Gk. *syn*, together; *osteon*, bone  
scaphocephalus: Gk. *skaphe*, boat; *kephale*, head  
plagiocephaly: Gk. *plagios*, oblique; *kephale*, head



## 334 Unit 4 Support and Movement

falx cerebelli and tentorium cerebelli (see table 11.6) restrict the displacement of the brain sideways. With a sudden violent lateral movement of the head, such as in a serious automobile accident, the serrated edge of the lesser wing of the sphenoid bone may severely damage the brain and tear cranial nerves.

The arteries of the head and neck are rarely damaged because of their elasticity. In a severe lateral blow to the head, however, the internal carotid artery may rupture, and a roaring sound will be perceived by the injured person as blood quickly fills the cavernous sinuses of the temporal bone.

Skull fractures are fairly common in adults but much less common in children. The cranial bones of a child are resilient, and sutures are not yet ossified. The cranium of an adult, however, has limited resilience and tends to splinter. A hard blow to the head frequently breaks the bone on the opposite side of the skull in what is called a **contrecoup fracture**. The sphenoid bone, with its numerous foramina, is the weakest bone of the cranium. It frequently sustains a contrecoup fracture as a result of a hard blow to the top of the head.

The most frequently fractured bones of the face are the nasal bones and the mandible. Trauma to these bones generally results in a simple fracture, which is not usually serious. If the nasal septum or cribriform plate of the ethmoid bone is fractured, however, careful treatment is required. If the cribriform plate is severely fractured, a tear in the meninges may result, causing a sudden loss of cerebrospinal fluid and death.

**Whiplash** is a common injury to the neck due to a sudden and forceful displacement of the head (see fig. 11.48). The muscle, bone, or ligaments may be injured, in addition to the spinal cord and cervical nerves. A whiplash is usually extremely painful and difficult to treat because of the difficulty in diagnosing the extent of the injury.

The sensory organs within the head are also very prone to trauma. The eyes may be injured by sudden bright light, and loud noise can rupture the tympanic membrane of the middle ear. A nonpenetrating blow to the eye may result in a herniation of the orbital contents through a fracture created in the floor of the orbit. The nerves that control the eye may also be damaged.

### Diseases of the Head and Neck

The head and neck are extremely susceptible to infection, especially along the mucous membranes lining body openings. Sinusitis, tonsillitis, laryngitis, pharyngitis, esophagitis, and colds are common, periodically recurring ailments of the mucous-lined digestive and respiratory tracts of the head and neck.

The cutaneous area of the head most susceptible to infections extends from the upper lip to the midportion of the scalp. An infection of the scalp may spread via the circulatory system to the bones of the skull, causing **osteomyelitis** (os''te-o-mi''li'tis). The infection may even spread into the sagittal venous sinus, causing **venous sinus thrombosis**. A **boil** in the facial region may secondarily cause thrombosis of the facial vein or the spread of the infection to the sinuses of the skull. Before antibiotics, such sinus infections had a mortality rate of 90%.

Close observation of the head by a physician can be helpful in diagnosing several diseases and body conditions. The nose becomes greatly enlarged in a person with **acromegaly** (ak''ro-meg''ā-le) and very wide in a person with **hypothyroidism**. The bridge of the nose is depressed in a person with **congenital syphilis**.

The color of the mucous membranes of the mouth may be important in diagnosing illness. Pale lips generally indicate **anemia**, yellow lips indicate **pernicious anemia**, and blue lips are characteristic of **cyanosis**, or cardiovascular problems. In *Addison's disease*, the normally pinkish mucous membranes of the cheeks have brownish areas of pigmentation.

## Thoracic Region

### Developmental Conditions

When serious deformities of the chest do occur, they are almost always due to an overgrowth of the ribs. In **pigeon breast** (*pectus carinatum*), the sternum is pushed forward and downward like the keel of a boat. In **funnel chest** (*pectus excavatum*), the sternum is pushed posteriorly, causing an anterior concavity in the thorax. Rarely, there may be a congenital absence of a pair, or pairs, of ribs. The absence of ribs is due to incomplete development of the thoracic vertebrae, a condition termed **hemivertebrae**, and may result in impaired respiratory function. There is a 0.5% occurrence of **cervical rib**, and half the time it is bilateral. A cervical rib is attached to the transverse process of the seventh cervical vertebra, and it either has a free anterior portion or is attached to the first (thoracic) rib. Pressure of a cervical rib on the brachial plexus may produce a burning, prickling sensation (*paresthesia*) along the ulnar border of the forearm and atrophy of the medial (hypothener) muscles of the hand.

The pectoralis major muscle may be congenitally absent, either partially or wholly. A person with this anomaly appears to have a sunken chest and must rely on the contractions of muscles that are synergistic to the pectoralis major for flexion at the shoulder joint.

The rapid and complex development of the heart and major thoracic vessels accounts for the numerous congenital abnormalities that may affect these organs (see chapter 16). Congenital heart problems occur in approximately 3 of every 100 births and account for about 50% of early childhood deaths. Cardiac malformations usually arise from developmental defects in the heart valves, septa (atrial and/or ventricular), or both. A **patent foramen ovale** (fōra'men o-val'e) is an example of a septal defect. Such a malformation may permit venous blood from the right atrium to mix freely with the oxygenated blood in the left atrium. A **ventricular septal defect** usually occurs in the upper portion of the interventricular septum and is generally more serious than an atrial septal defect because of the greater fluid pressures in the ventricles and the greater chance of heart failure.

Congenital valvular problems are classified as either an **incompetence** (leakage) or a **stenosis** (constriction) of valves. Improper closure of a valve permits some backflow of blood, causing an abnormal sound referred to as a **murmur**. Murmurs are common and generally have no adverse affect on a person's health.

The **tetralogy of Fallot** is a combination of four defects within the heart of a newborn: (1) a ventricular septal defect, (2) an overriding aorta, (3) pulmonary stenosis, and (4) right ventricular hypertrophy. It immediately causes a cyanotic condition (blue baby). Although tetralogy of Fallot is one of the most common cardiac defects, it is also one of the simplest to correct surgically.

Abnormal development of the primitive aortic arches occasionally results in both a left and a right aortic arch. In this case, there are generally anomalies of other vessels as well.

### Trauma to the Thorax

Because of its resilience, the rib cage generally provides considerable protection for the thoracic viscera. The ribs of children are highly elastic and fractures are rare. By contrast, the ribs of adults, are frequently fractured by direct trauma or, indirectly, by crushing injuries. Ribs 3 through 8 are the ones most commonly fractured. The first and second ribs are somewhat protected by the clavicle and the last four ribs are more flexible to blows. The costal cartilages in elderly people may undergo some ossification, reducing the flexibility of the rib cage and causing some confusion when examining a chest radiograph.

A possible complication of a rib fracture is a puncture of the lung or the protrusion of a bone fragment through the skin. In either case, pleural membranes will likely be ruptured resulting in a **pneumothorax** (*noo''mo-thor'aks*) (accumulation of air in the pleural cavity) or a **hemothorax** (blood in the pleural cavity).

Any puncture wound to the thorax—from a bullet or a knife, for example—may cause a pneumothorax. **Atelectasis** (*at'lek'tă-sis*) the collapse of a lung or part of it, generally results from a pneumothorax, and makes respiration extremely difficult. Because each lung is surrounded by its own pleural cavity, trauma to one lung does not usually directly affect the other lung.

The heart, the ascending aorta, and the pulmonary trunk are enclosed by the fibrous pericardium. A severe blow to the chest, such as hitting the steering wheel in an automobile accident, may cause a sudden surge of blood from the ventricles sufficient to rupture the ascending aorta. Such an injury will flood the pericardial sac with blood, causing **cardiac tamponade** (fluid compression) and almost immediate death.

### Diseases of the Thorax

The leading causes of death in the United States are due to disease or dysfunction of the thoracic organs. Consequently, the surface features of the thorax are extremely important to a physi-

cian as reference locations for *palpation* (feeling with firm pressure, *percussion* tapping with the fingertips), and *auscultation* (listening with a stethoscope). As mentioned earlier, many of the ribs are evident on a thin person, and all but the first, and at times the twelfth, can be palpated. The sternum, clavicles, and scapulae also provide important bony landmarks in conducting a physical examination. The nipples in the male and prepubescent female are located at the fourth intercostal spaces. The position of the left nipple in males provides a guide for where to listen for various heart sounds.

The clinical importance of the female breasts lies in their periodic phases of activity (during pregnancy and lactation) and their susceptibility to neoplastic change. The breasts and mammary glands are highly susceptible to infections, cysts, and tumors. The superficial position of the breasts allows for effective treatment by way of surgery and radiotherapy if tumors are detected early. The importance of *breast self-examination* (BSE) (see chapter 21) cannot be overemphasized. Breast cancer, or **carcinoma of the breast**, is surpassed only by lung cancer as the most common malignancy in women. Untreated, breast cancer is eventually fatal. One in nine women will develop breast cancer, and one-third of these will die from the disease.

The lungs can be examined through percussion, auscultation, or observation. *Bronchoscopy* enables a physician to examine the trachea, carina, primary bronchi, and secondary bronchi. A bronchoscope also enables a physician to remove foreign objects from these passageways. Swallowed objects that are aspirated beyond the glottis lodge in the right primary bronchus 90% of the time because of its near vertical alignment with the trachea.

The lungs are a common site for cancer. Fortunately, each lung is divided into distinct lobes, which allows a surgeon to remove a diseased portion and leave the rest of the lung intact. Pneumonia, tuberculosis, asthma, pleurisy, and emphysema are other common diseases that directly or indirectly afflict the lungs.

Cardiovascular diseases are the leading cause of death in the United States. Included among these diseases are heart attacks, which are caused by an insufficient blood supply to the myocardium (**myocardial ischemia** [*is-ke'mēd*]). Poor cardiac circulation is due to an accumulation of atherosclerotic plaques or the presence of a thrombus (clot). A heart attack is generally accompanied by severe chest pains (**angina pectoris**) and usually by referred pain, perceived as arising from the left arm and shoulder. If the coronary deficiency is continuous, local tissue necrosis results, causing a permanent loss of cardiac muscle fibers (**myocardial infarction**). Extensive cardiac necrosis results in cardiac arrest.

**Ventricular fibrillation** is random, disorganized electrical activity within the ventricular wall of the heart. The consequent loss of coordinated ventricular contraction impairs coronary circulation, resulting in low blood pressure, or **hypotension**. If untreated, continuous ventricular fibrillation results in death.

Various other heart diseases include infections of the serous membrane (**pericarditis**), infection of the lining of the heart chambers (**endocarditis**), infection of the valves (**bacterial**

tetralogy of Fallot: from Etienne L.A. Fallot, French physician, 1850–1911

## 336 Unit 4 Support and Movement

*endocarditis*), and immune-mediated damage to the valves, as occurs in *rheumatic fever*. Valvular disease may cause the cusps to function poorly and may result in an enlarged heart.

## Abdominal Region

### Developmental Conditions

The development of the abdominal viscera from endoderm and mesoderm is a highly integrated, complex, and rapidly occurring process; the viscera are therefore susceptible to a wide range of congenital malformations.

The diaphragm develops in four directions simultaneously as skeletal muscle tissues coalesce toward the posterior center. Failure of the muscle tissues to fuse results in a **congenital diaphragmatic (hiatal) hernia**. This abnormal opening in the diaphragm may permit certain abdominal viscera to project into the thoracic cavity.

The role of the umbilicus in the development of the fetal urinary, circulatory, and digestive systems may present some interesting congenital defects. A **patent urachus** (*yoor'ă-kus*) is an opening from the urinary bladder to the outside through the umbilicus. For a short time during development, this opening is normal. Closure of the urachus occurs in most fetuses with progressive development of the urinary system. A patent urachus will generally go undetected unless there is extreme difficulty with urination, such as may be caused by an enlarged prostate. In such a case, some urine may be forced through the patent urachus and out the umbilicus.

**Meckel's diverticulum** is the most common anomaly of the small intestine. It is the result of failure of the embryonic yolk sac to atrophy completely. Present in about 3% of the population, a Meckel's diverticulum consists of a pouch, approximately 6.5 cm (2.5 in.) long, that resembles the appendix. It arises near the center of the ileum, and may terminate freely or be attached to the anterior abdominal wall near the umbilicus. Like the appendix, a Meckel's diverticulum is prone to infections; it may become inflamed, producing symptoms similar to appendicitis. For this reason, it is usually removed as a precautionary measure when discovered during abdominal surgery.

The connection from the ileum of the small intestine to the outside sometimes is patent at the time of birth; this condition is called a **fecal fistula**. It permits the passage of fecal material through the umbilicus and must be surgically corrected in a newborn.

Other parts of the GI tract are also common sites for congenital problems. In **pyloric stenosis**, there is a narrowing of the pyloric orifice of the stomach resulting from hypertrophy of the muscular layer of the pyloric sphincter. This condition is more common in males than in females, and the symptoms usually appear early in infancy. The constricted opening interferes with the

passage of food into the duodenum and therefore causes dilation of the stomach, vomiting, and weight loss. Treatment involves a surgical incision of the pyloric sphincter.

**Congenital megacolon** (Hirschsprung's disease) is a condition in which ganglia fail to develop in the submucosal and myenteric plexuses in a portion of the colon. The absence of these ganglia results in enlargement of the affected portion of the colon because of lack of innervation and muscle tone. In the absence of peristalsis, there is severe constipation. Treatment involves surgical resection of the affected portion of the colon.

Congenital malformations may occur in any of the abdominal viscera, but most of these conditions are inconsequential. Accessory spleens, for example, occur in about 10% of the population. Located near the hilum of the spleen, these anomalous organs are small (about 1 cm in diameter), number from two to five, and are only moderately functional. They usually atrophy within a few years after birth.

Tremendous variation can occur in the formation of the kidneys. They are frequently multilobed, fused, or malpositioned (see fig. 19.17). There also may be more than the normal two. In the case of an anomalous kidney, there is usually an accompanying variation in the vascular supply. It is common to have multiple renal arteries serving a kidney. Most renal anomalies do not pose serious problems.

An abnormal pattern of sex hormone production in the embryo may result in considerable malformation of the developing genitalia. These anomalies may be cosmetic concern only, or they may render the organ nonfunctional. Some may be so severe as to preclude determination of an individual's sex based on external appearance. Most of these conditions can be surgically corrected. Also of clinical concern and treatable are the various problems that may occur during descent of the testes into the scrotum. In the normal development of the male fetus, the testes will be in scrotal position by the twenty-eighth week of gestation. If they are undescended at birth, a condition called **cryptorchidism** (*krip-tor'kī-diz''em*), medical intervention may be necessary.

### Trauma to the Abdomen

The rib cage, the omentum (see fig. 18.3), and the pendant support of the abdominal viscera offer some protection from trauma. However, puncture wounds, compression, and severe blows to the abdomen may result in serious abdominal injury.

The large and dense liver, located in the upper right quadrant of the abdomen, is quite vulnerable to traumatic blows, stab wounds, or puncture wounds from fractured ribs. A lacerated liver is extremely serious because of the possibility of internal hemorrhage from such a vascular organ.

The spleen is another highly vascular organ that is frequently injured, especially from blunt abdominal trauma. A ruptured spleen causes severe internal hemorrhage and shock. Its



prompt removal (*splenectomy*) is necessary to keep the patient from bleeding to death. The spleen may also rupture spontaneously because of infectious diseases that cause it to hypertrophy.

Rupture of the pancreas is not nearly as common as rupture of the spleen, but it could occur if a strong compression of the upper abdomen were to force the pancreas against the vertebral column. The danger of a ruptured pancreas is the flow of pancreatic juice into the peritoneal cavity, the subsequent digestive action, and peritonitis.

The kidneys are vulnerable to trauma in the lumbar region, such as from a traumatic blow. Because the kidney is fluid-filled, a blow to one side propagates through the kidney and may possibly rupture the renal pelvis or the proximal portion of the ureter. Blood in the urine is symptomatic of kidney damage. Medical treatment of a traumatized kidney varies with the severity of the injury.

Trauma to the external genitalia of both males and females is a relatively common occurrence. The pendant position of the penis and scrotum makes them vulnerable to compression forces. For example, if a construction worker were to slip and land astride a steel beam, his external genitalia would be compressed between the beam and his pubic bone. In this type of accident, the penis (including the urethra) might split open, and one or both testes might be crushed.

Trauma to the female genitalia usually results from sexual abuse. Vaginal tearing and a displaced uterus are common in molested girls. The physical and mental consequences are generally severe.

### Diseases of the Abdomen

Any of the abdominal organs may be afflicted by an array of diseases. It is beyond the scope of this text to cover all of these diseases; instead, an overview of some general conditions will be presented.

Knowledge of the clinical regions of the abdomen (see figs. 2.15 and 2.16) and the organs within these regions (see table 2.4) is fundamental to the physician in performing a physical examination. Also important are the locations of the linea alba, extending from the xiphoid process to the symphysis pubis, the umbilicus, the inguinal ligament, the bones and processes that can be palpated on the rib cage, and the pelvic girdle.

**Peritonitis** is of major clinical concern. The peritoneum is the serous membrane of the abdominal cavity. It lines the abdominal wall as the parietal peritoneum, and it covers the visceral organs as the visceral peritoneum. The peritoneal cavity is the moistened space between the parietal and visceral portions of the peritoneum. Peritonitis results from any type of contamination of the peritoneal cavity, such as from a puncture wound, blood-borne diseases, or a ruptured visceral organ. In females, peritonitis is frequently a complication of infections of the reproductive tract that have entered the peritoneal cavity via the uterine tubes. Without medical treatment, peritonitis is generally fatal.

**Ulcers** may occur throughout the GI tract. *Peptic ulcers*—erosions of the mucous membranes of the stomach or duodenum—are produced by the action of hydrochloric acid (HCl) contained

in gastric juice. Agents that weaken the mucosal lining of the stomach, including alcohol and aspirin, and hypersecretion of gastric juice, as may accompany chronic stress, increase the likelihood of developing peptic ulcers. The bacterium *H. pylori*, which may be present in the GI tract, also may contribute to the weakening of mucosal barriers.

**Enteritis**, or inflammation of the intestinal mucosa, is frequently referred to as intestinal flu. Causes of enteritis include bacterial or viral infections, irritating foods or fluids, and emotional stress. The symptoms are abdominal pain, nausea, and diarrhea. *Diarrhea* is symptomatic of inflammation, stress, and other body dysfunctions. In children, it is of immense clinical importance because of the rapid loss of body fluids.

## Shoulder and Upper Extremity

### Developmental Conditions

Twenty-eight days after conception, a limb bud appears on the upper lateral side of the embryo, which eventually becomes a shoulder and an upper extremity. Three weeks later (7 weeks after conception) the shoulder and upper extremity are present in the form of mesenchymal primordium of bone and muscle. It is during this crucial 3 weeks of development that malformations of the extremities can occur.

If a pregnant woman uses certain teratogenic drugs or is exposed to certain diseases (*Rubella* virus, for example) during development of the embryo, there is a strong likelihood that the appendage will be incompletely developed. A large number of limb deformities occurred between 1957 and 1962 as a result of women ingesting the sedative thalidomide during early pregnancy to relieve morning sickness. It is estimated that 7,000 infants were malformed by this drug. The malformations ranged from *micromelia* (short limbs) to *amelia* (the absence of limbs).

Although genetic deformities of the shoulder and upper extremity are numerous, only a few are relatively common. **Sprengel's deformity** affects the development of one or both scapulae. In this condition, the scapula is smaller than normal and is positioned at an elevated level. As a result, abduction of the arm is not possible beyond a right angle to the plane of the body.

Minor defects of the extremities are relatively common malformations. Extra digits, a condition called **polydactyly** (pol''e-dak'tī-le) is the most common limb deformity. Usually an extra digit is incompletely formed and nonfunctional. **Syndactyly**, or webbed digits, is likewise a relatively common limb malformation. Polydactyly is inherited as a dominant trait, whereas syndactyly is a recessive trait.

## 338 Unit 4 Support and Movement

### Trauma to the Shoulder and Upper Extremity

The wide variety of injuries to the shoulder and upper extremity range from damaged bones and surrounding muscles, tendons, vessels, and nerves to damaged joints in the form of sprains or dislocations.

It is not uncommon to traumatize the shoulder and upper extremity of a newborn during a difficult delivery. **Upper arm birth palsy** (*Erb–Duchenne palsy*) is the most common type of birthing injury, caused by a forcible widening of the angle between the head and shoulder. Using forceps to rotate the fetus in utero, or pulling on the head during delivery, may cause this injury. The site of injury is at the junction of vertebrae C5 and C6 (*Erb's point*), as they form the upper trunk of the brachial plexus. The expression of the injury is paralysis of the abductors and lateral rotators of the shoulder and the flexors of the elbow. The arm will permanently hang at the side in medial rotation.

The stability of the shoulder is largely dependent on the support of the clavicle and acromion of the scapula superiorly and the tendons forming the rotator cuff anteriorly. Because support is weak along the inferior aspect of the shoulder joint, dislocations are frequent in this direction. Injuries of this sort are common in athletes engaging in contact sports. Sudden jerks of the arm are also likely to dislocate the shoulder, especially in children who have weak muscles spanning this area.

Fractures are common in any location of the shoulder and upper extremity. Many fractures result from extending the arm to break a fall. The clavicle is the most frequently broken bone in the body. Also common are fractures of the humerus, which are often serious because of injury to the nerves and vessels that parallel the bone. The surgical neck of the humerus is a common fracture site. At this point, the axillary nerve is often damaged, thus limiting abduction of the arm. A fracture in the middle third of the humerus may damage the radial nerve, causing paralysis of the extensor muscles of the hand (wristdrop). A fracture of the olecranon of the ulna often damages the ulnar nerve, resulting in paralysis of the flexor muscles of the hand and the adductor muscles of the thumb. The distal part of the radius is frequently fractured (*Colles' fracture*) by falling on an outstretched arm. In this fracture, the hand is displaced backward and upward.

Sports injuries frequently involve the upper extremity. Repeated extension of the wrist against a force, such as occurs during the backhand stroke in tennis, may cause **lateral epicondylitis** (*ep''i-ko-n''dī-li'tis*) (tennis elbow). Wearing an elbow brace or a compression band may help reduce the pain, but only if the cause is eliminated will the area be allowed to heal.

Athletes frequently jam a finger when a ball forcefully strikes a distal phalanx as the fingers are extended, causing a sharp flexion at the joint between the middle and distal pha-

langes. Splinting the finger for a period of time may be curative; however, surgery may be required to avoid a permanent crook in the finger.

### Diseases of the Shoulder and Upper Extremity

Inflammations in specific locations of the shoulder or upper extremity are the only common clinical conditions endemic to these regions. **Bursitis**, for example, may specifically afflict any of the numerous bursae of the shoulder, elbow, or wrist joints. There are several types of **arthritis**, but generally they involve synovial joints throughout the body rather than just those in the hands and fingers.

**Carpal tunnel syndrome** is caused by compression of the median nerve by the carpal flexor retinaculum that forms the palmar aspect of the carpal tunnel. The nerve compression results in a painful burning sensation or numbness of the first three fingers and some muscle atrophy. The compression is due to an inflammation of the transverse carpal ligament, which may be eased through surgery.

**Tenosynovitis** (*ten''o-sin''o-vi'tis*) is an inflammation of the synovial tendon sheath in the wrist or hand. Digital sheath infections are quite common following a puncture wound in which pathogens enter the closed synovial sheath. The increased pressure from the swollen, infected sheath may cause severe pain and eventually result in necrosis of the flexor tendons. The loss of hand function can be prevented by draining the synovial sheath and providing antibiotic treatment.

## Hip and Lower Extremity

### Developmental Conditions

The embryonic development of the hip and lower extremity follows the developmental pattern of the shoulder and upper extremity: the appearance of the limb bud is followed by the formation of the mesenchymal primordium of bone and muscle in the shape of an appendage. Development of the lower extremity, however, lags behind that of the upper extremity by 3 or 4 days.

The likelihood of congenital deformities of the hips and lower extremities in a newborn is slim if the pregnant mother has been healthy and well nourished, especially prior to and during embryonic development. The few congenital malformations that occur generally have a genetic basis.

In **congenital dislocation of the hip**, the acetabulum fails to develop adequately, and the head of the femur slides out of the acetabulum onto the gluteal surface of the ilium. If this condition goes untreated, the infant will never be able to walk normally.

Polydactyly and syndactyly occur in the feet as well as in the hands. Treatment of the feet is the same as treatment of the hands.

**Talipes**, (*tal'i-pēz*) or **clubfoot**, is a congenital malformation in which the sole of the foot is twisted medially. It is uncertain whether abnormal positioning or restricted movement in utero causes talipes, but both genetic and environmental factors are involved in most cases.

Erb–Duchenne palsy: from Wilhelm H. Erb, German neurologist, 1840–1921, and Guillaume G.A. Duchenne, French neurologist, 1806–75

Colles' fracture: from Abraham Colles, Irish surgeon, 1773–1843

### Trauma to the Hip and Lower Extremity

As with the shoulder and upper extremity, a variety of traumatic conditions are associated with the hip and lower extremity. These range from injury to the bones and surrounding muscles, tendons, vessels, and nerves to damage of the joints in the form of sprains or dislocations.

Dislocation of the hip is a common and severe result of an automobile accident when a seat belt is not worn. When the hip is in the flexed position, as in sitting in a seat, a sudden force applied at the distal end of the femur will drive the head of the femur out of the acetabular socket, fracturing the posterior acetabular hip. In this kind of injury, there is usually damage to the sciatic nerve.

Trauma to the nerve roots that form the sciatic nerve may also occur from a herniated disc or pressure from the uterus during pregnancy. An improperly administered injection into the buttock may damage the sciatic nerve itself. Sciatic nerve damage is usually very painful and is expressed throughout the posterior length of the lower extremity.

Fractures are common in any location of the hip and lower extremity. Athletes (such as skiers) and elderly people seem to be most vulnerable. *Osteoporosis* markedly weakens the bones of the hip and thigh regions, making them vulnerable to fracture. A common fracture site, especially in elderly women, is across the femoral neck. A fracture of this kind may be complicated by vascular and nerve interruption. A direct blow to the knee will frequently fracture the patella. A potentially more serious knee trauma, however, is a clipping injury, caused by a blow to the lateral side. In this type of injury, there is generally damage to the cruciate ligament and menisci. Serious complications arise if the common fibular (peroneal) nerve, traversing the popliteal fossa, is damaged. Damage to this nerve results in paralysis of the ankle and foot extensors (*footdrop*) and inversion of the foot.

**Stress fractures** of the long bones of the lower extremity are common to athletes. *Shinsplints*, a painful condition of the anterior muscles of the leg and their periosteal attachments, are often accompanied by tibial stress fractures. Stress fractures of the metatarsal bones may be very painful, even though they may

not show up on radiographs. Frequently, the only way to heal stress fractures is to abstain from exercise.

**Sprains** are common in the joints of the lower extremity. Ligaments and tendons are torn to varying degrees in sprains. Sprains are usually accompanied by *synovitis*, an inflammation of the joint capsule.

### Diseases of the Hip and Lower Extremity

As in the shoulder and upper extremity, infections in the hip and lower extremity—such as bursitis and tendinitis—can be localized in any part of the hip or lower extremity. Likewise, several types of arthritis may affect joints in these regions.

A variety of skin diseases afflict the foot, including athlete's foot, plantar warts, and dyshidrosis. Most of the diseases of the feet can be prevented, or if they do occur, they can be treated effectively.

Because arterial occlusive disease is common in elderly people, palpation of the posterior tibial artery is clinically important in general physical assessment. This can be accomplished by gently palpating between the medial malleolus and the tendo calcaneus.

Many neuromuscular diseases have a direct effect on the functional capabilities of the lower extremities. *Muscular dystrophy* and *poliomyelitis* are both serious immobilizing diseases because of muscle paralysis.

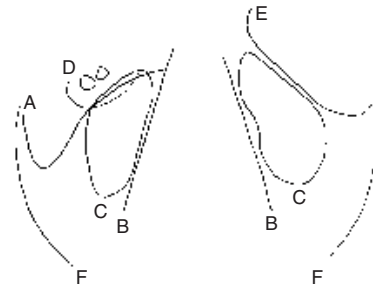
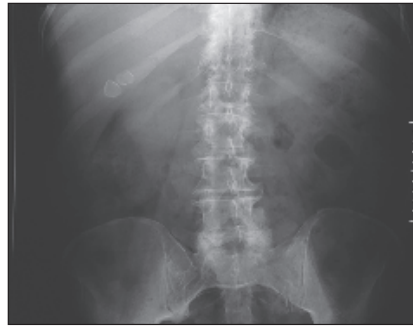
## Clinical Case Study Answer

The patient experienced a tension pneumothorax because a fractured rib opened an abnormal channel between the pleural cavity and the outside air. Every time she inspired, the relative drop in intrathoracic pressure sucked air into the pleural cavity, but no air escaped with expiration. In only a short time, her left hemithorax became distended and compressed the mediastinal contents into the right thorax, resulting in a drop in blood pressure. This condition is fatal unless air is removed from the affected pleural cavity. The internal jugular vein is medically referred to as the "dipstick" to the heart because its abnormal distension is diagnostic of heart dysfunction.



## CLINICAL PRACTICUM 10.1

Just as a knowledge of surface and regional anatomy are important to a physician performing a physical exam, physicians must also understand the relationships of internal organs to interpret radiographs. Images are produced on radiographs by the transmission of x-rays through tissues of different densities. At the interfaces of different tissues, there is often a difference in density resulting in a line on the radiograph. These lines show the edges of organs, allowing physicians to analyze the size and shape, and relationship to other organs. On this radiograph of the abdomen, identify the organs or structures indicated by the lines in the accompanying line drawing.



- A.
- B.
- C.
- D.
- E.
- F.

## Chapter Summary

**Introduction to Surface Anatomy**  
(pp. 297–298)

1. Surface anatomy is concerned with identifying body structures through visual inspection and palpation. It has tremendous application in the maintenance of physical fitness and in medical diagnosis and treatment.
2. Most of the bones of the skeleton are palpable and provide landmarks for locating other anatomical structures.
3. The effectiveness of visual inspection and palpation in studying a person's surface anatomy is influenced by the thickness of the hypodermis, which varies in accordance with the amount of subcutaneous adipose tissue present.

**Surface Anatomy of the Newborn**  
(pp. 298–300)

1. Certain aspects of the surface anatomy of a neonate are of clinical importance in ascertaining the degree of physical development, general health, and possible congenital abnormalities.
2. The posture of a full-term, normal neonate is one of flexion.

3. Portions of the skin and subcutaneous tissues of a neonate are typically edematous. Vernix caseosa covers the body, and lanugo may be present on the head, neck, and back.
4. The fontanels, liver, and kidneys should be palpable, as well as the testes of a male.

**Head (pp. 300–305)**

1. Surface features of the cranium include the forehead, crown, temporalis muscles, and the hair and hairline.
2. The face is composed of the ocular region that surrounds the eye, the auricular region of the ear, the nasal region serving the respiratory system, and the oral region serving the digestive and respiratory systems.

**Neck (pp. 306–309)**

1. Major organs are located within the flexible neck, and structures that are essential for body sustenance pass through the neck to the trunk.
2. The neck consists of an anterior cervix, right and left lateral regions, and a posterior nucha.

3. Two major and six minor triangles, each of which contains specific structures, are located on each side of the neck.
  - (a) The anterior cervical triangle encompasses the carotid, submandibular, submental, and omotracheal triangles.
  - (b) The posterior cervical triangle encompasses the supraclavicular and omoclavicular triangles.

**Trunk (pp. 309–318)**

1. Vital visceral organs in the trunk make the surface anatomy of this region especially important.
2. The median furrow is visible, and the vertebral spines and scapulae are palpable on the back.
3. Palpable structures of the thorax include the sternum, the ribs, and the costal angle.
4. The important surface anatomy features of the abdomen include the linea alba, umbilicus, costal margin, iliac crest, and the pubis.

## Chapter 10 Surface and Regional Anatomy 341

### Pelvis and Perineum (p. 318)

1. The crest of the ilium, the symphysis pubis, and the inguinal ligament are important pelvic landmarks.
2. The perineum is the region that contains the external genitalia and the anal opening.

### Shoulder and Upper Extremity (pp. 319–325)

1. The surface anatomy of the shoulder and upper extremity is important because of frequent trauma to these regions. Vessels of the upper extremity are also used as pressure points and for intravenous injections or blood withdrawal.
2. The scapula, clavicle, and humerus are palpable in the shoulder.
3. The axilla is clinically important because of the vessels, nerves, and lymph nodes located there.

4. The brachial artery is an important pressure point in the brachium. The median cubital vein is important for the removal of blood or for intravenous therapy.
5. The ulna, radius, and their processes are palpable landmarks of the forearm.
6. The knuckles, fingernails, and tendons for the extensor muscles of the forearm can be observed on the posterior aspect of the hand.
7. Flexion creases and the thenar eminence are important features on the anterior surface of the hand.

### Buttock and Lower Extremity (pp. 326–330)

1. The massive bones and muscles in the buttock and lower extremity serve as weight-bearers and locomotors. Many of

the surface features of these regions are important with respect to locomotion or locomotor dysfunctions.

2. The prominences of the buttocks are formed by the gluteal muscles and are separated by the natal cleft.
3. The thigh has three muscle groups: anterior (quadriceps), medial (adductors), and posterior (hamstrings).
4. The femoral triangle and popliteal fossa are clinically important surface landmarks.
5. The structures of the leg include the tibia and fibula, the muscles of the calf, and the saphenous veins.
6. The surface anatomy of the foot includes structures adapted to support the weight of the body, maintain balance, and function during locomotion.

## Review Activities

### Objective Questions

1. Eyebrows are located on
  - (a) the palpebral fissure.
  - (b) the subnasal sulcus.
  - (c) the scalp.
  - (d) the supraorbital ridges.
  - (e) both c and d.
2. Which of the following structures is *not* part of the auricle (pinna) of the ear?
  - (a) the tragus
  - (b) the ala
  - (c) the earlobe
  - (d) the helix
3. Which of the following clinical-structural word pairs is *incorrectly* matched?
  - (a) cleft lip/philtrum
  - (b) broken nose/nasion
  - (c) pierced ear/earlobe
  - (d) black eye/concha
4. The conjunctiva
  - (a) covers the entire eyeball.
  - (b) is a thick nonmucous membrane.
  - (c) secretes tears.
  - (d) none of the above apply.
5. Which of the following could *not* be palpated within the cervix of the neck?
  - (a) the larynx
  - (b) the hyoid bone
  - (c) the trachea
  - (d) the cervical vertebrae
6. Palpation of an arterial pulse in the neck is best accomplished at
  - (a) the carotid triangle.
  - (b) the supraclavicular triangle.
  - (c) the submental triangle.
  - (d) the submandibular triangle.
  - (e) the omotracheal triangle.
7. Which nerve lies posterior to the medial epicondyle of the humerus?
  - (a) the ulnar nerve
  - (b) the median nerve
  - (c) the radial nerve
  - (d) the brachial nerve
  - (e) the cephalic nerve
8. Which of the following surface features could *not* be observed on obese people?
  - (a) the jugular notch
  - (b) scapular muscles
  - (c) clavicles
  - (d) vertebral spines
  - (e) the natal cleft
9. Which pair of muscles forms the anterior and posterior borders of the axilla?
  - (a) deltoid/pectoralis minor
  - (b) biceps brachii/triceps brachii
  - (c) latissimus dorsi/pectoralis major
  - (d) triceps brachii/pectoralis major
  - (e) latissimus dorsi/deltoid
10. Varicose veins occur when which of the following become(s) excessively enlarged?
  - (a) saphenous veins
  - (b) tibial veins
  - (c) the external iliac vein
  - (d) the popliteal vein
  - (e) all of the above
3. Which surface features can be observed on the trunk of any person, regardless of how obese that person might be?
4. Identify the two major triangles of the neck and list the associated six minor triangles. Discuss the importance of knowing the boundaries of these triangles and the specific structures included in each.
5. Name four structures that are palpable along the anterior midline of the neck.
6. What three bones are found in the shoulder region? List the surface features that can be either observed or palpated on each of these bones.
7. Identify the tendons or vessels that can be observed or palpated along the anterior surface of the wrist. Which nerves pass through this region?
8. Describe the locations of the arteries that can be palpated as they pulsate in the following regions: (a) neck, (b) brachium, (c) antebrachium, (d) thigh, and (e) ankle. Which of these are considered clinical pressure points?
9. Describe the locations of the following regions: (a) cubital fossa, (b) femoral triangle, (c) axilla, (d) perineum, and (e) popliteal fossa. Comment on the clinical importance of each of these regions.
10. Describe the anatomical location where each of the following could be observed or palpated: (a) the distal tendinous attachments of the hamstring muscles; (b) the greater trochanter; (c) the great and small saphenous veins; (d) the femoral, posterior tibial, and dorsal pedal arteries; and (e) the medial malleolus

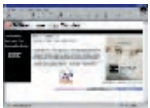### Essay Questions

1. List four surface features of the cranium and explain how the cranium relates to the scalp.
2. Identify the four regions of the face and list at least two surface features of each region.

342 Unit 4 Support and Movement

**Critical-Thinking Questions**

1. A Saturday afternoon athlete crashed while mountain biking without a helmet. He sustained deep cuts across the front of his knee, across the back of his elbow, horizontally through his scalp, and across the length of the cheek on his face. Which areas would be the most difficult to hold together with sutures, thus requiring more time to heal? Why the disparity in the various regions?
2. Knowledge of surface anatomy is crucial to the intensive care physician when vascular access to the large veins of the neck is required for the rapid administration of fluids and medications. Cannulation of the internal jugular and subclavian veins is frequently employed. Can you associate the position of these veins with surface landmarks on the neck? Refer to figures 16.34 and 16.35 for the location of these veins. What might be a possible complication of using the subclavian vein?
3. It is often necessary in the critical care setting for a physician to obtain vascular access to the femoral artery or vein. How do these structures lie in relation to each other and what other structures are in the vicinity? (Refer to fig. 10.52.)



Visit our **Online Learning Center** at <http://www.mhhe.com/vdg> for chapter-by-chapter quizzing, additional study resources, and related web links.