

# 8

## Articulations

Classification of Joints 197

Fibrous Joints 197

Cartilaginous Joints 199

Synovial Joints 200

**Developmental Exposition:**

The Synovial Joints 206

Movements at Synovial Joints 207

Specific Joints of the Body 214

---

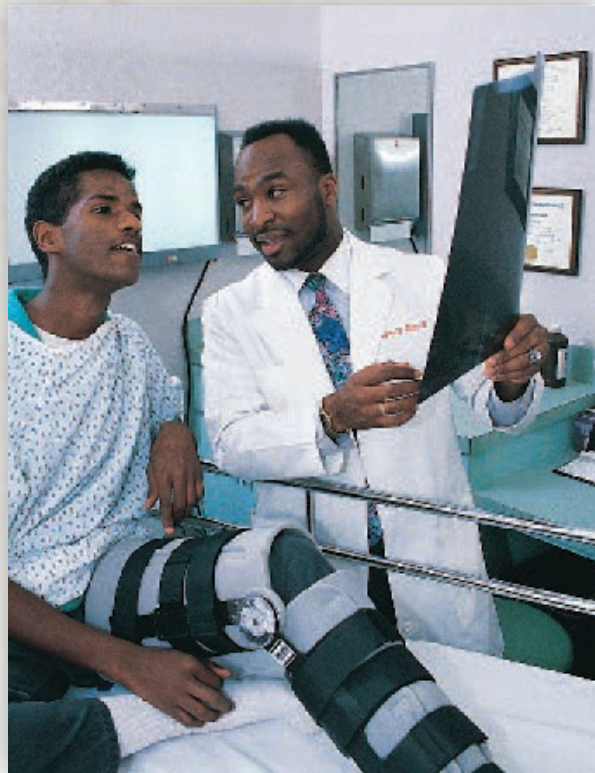CLINICAL CONSIDERATIONS 224

Clinical Case Study Answer 229

Important Clinical Terminology 230

Chapter Summary 230

Review Activities 231



## Clinical Case Study

A 20-year-old college football player sustained injury to his right knee during the opening game of the season. Because of rapid swelling and intense pain, he was taken to the emergency room of the local hospital. When the attending physician asked him to describe how the injury occurred, the athlete responded, “I was carrying the ball on an end run left on third down and two. As I planted my right foot just before I was going to make my cut, I was hit in the knee from the side. I felt my knee give way, and then I felt a stabbing pain on the inside of my knee.”

Close examination by the physician revealed marked swelling on the medial part of the knee. The doctor determined that *valgus stress* (an inward bowing stress on the knee) caused the medial aspect of the joint to “open.” Which stabilizing structure is most likely injured? Which cartilaginous structure is frequently injured in association with the previously mentioned structure? Is there an anatomical explanation? What are some other stabilizing structures within the knee that are frequently injured in sports?

**Hint:** An impact to one side of the knee generally results in greater trauma to the other side. Carefully read the sections in this chapter on the tibiofemoral (knee) joint and trauma to joints. In addition, examine figures 8.31 and 8.32.

**FIGURE:** In spite of being well suited for body support, walking, and running, the knee joint is particularly vulnerable to sport-related injuries.

## CLASSIFICATION OF JOINTS

On the basis of anatomical structure, the articulations between the bones of the skeleton are classified as fibrous joints, cartilaginous joints, or synovial joints. Fibrous joints firmly bind skeletal elements together with fibrous connective tissue. Cartilaginous joints firmly unite skeletal elements with cartilage. Synovial joints are freely movable joints; they are enclosed by joint capsules that contain synovial fluid.

**Objective 1** Define *arthrology* and *kinesiology*.

**Objective 2** Compare and contrast the three principal kinds of joints that are classified on the basis of structure.

One of the functions of the skeletal system is to permit body movement. It is not the bones themselves that allow movement, but rather the unions between the bones, called **articulations** or **joints**. Although the joints of the body are actually part of the skeletal system, this chapter is devoted entirely to them.

The structure of a joint determines the direction range of movement it permits. Not all joints are flexible, however, and as one part of the body moves, other joints remain rigid to stabilize the body and maintain balance. The coordinated activity of the joints permits the sinuous, elegant movements of a gymnast or ballet dancer, just as it permits all of the commonplace actions associated with walking, eating, writing, and speaking.

*Arthrology* is the science concerned with the study of joints. Generally speaking, an arthrologist is interested in the structure, classification, and function of joints, including any dysfunctions that may develop. *Kinesiology* (*kī-ne''se-ol'ō-je*), a more applied and dynamic science, is concerned with the mechanics of human motion—the functional relationship of the bones, muscles, and joints as they work together to produce coordinated movement. Kinesiology is a subdiscipline of *biomechanics*, which deals with a broad range of mechanical processes, including the forces that govern blood circulation and respiration.

In studying the joints, a kinetic approach allows for the greatest understanding. The student should be able to demonstrate the various movements permitted at each of the movable joints. Additionally, he or she should be able to explain the adaptive advantage, as well as the limitations, of each type of movement.

The articulations of the body are grouped by their structure into three principal categories.

1. **Fibrous joints.** In fibrous joints, the articulating bones are held together by fibrous connective tissue. These joints lack joint cavities.
2. **Cartilaginous joints.** In cartilaginous joints, the articulating bones are held together by cartilage. These joints also lack joint cavities.

3. **Synovial joints.** In synovial (*sī-no've-al*) joints, the articulating bones are capped with cartilage, and ligaments frequently help support them. These joints are distinguished by fluid-filled joint cavities.

A functional classification of joints is based on the degree of movement permitted within the joint. Using this type of classification, the three kinds of articulations are as follows:

1. **Synarthroses** (*sin'ar-thro'sēz*). Immovable joints.
2. **Amphiarthroses.** Slightly movable joints.
3. **Diarthroses** (*di''ar-thro'sēz*). Freely movable joints.

In accordance with the structural classification of the joints presented in the sixth edition of *Nomina Anatomica*, this chapter uses a structural classification of joints.

### ✓ Knowledge Check

1. Explain the statement that kinesiology is applied arthrology.
2. List the three categories of structural articulations and speculate as to which would be most supportive and which most vulnerable to trauma.

## FIBROUS JOINTS

As the name suggests, the articulating bones in fibrous joints are tightly bound by fibrous connective tissue. Fibrous joints range from rigid and relatively immovable joints to those that are slightly movable. The three kinds of fibrous joints are sutures, syndesmoses, and gomphoses.

**Objective 3** Describe the structure of a suture and indicate where sutures are located.

**Objective 4** Describe the structure of a syndesmosis and indicate where syndesmoses are located.

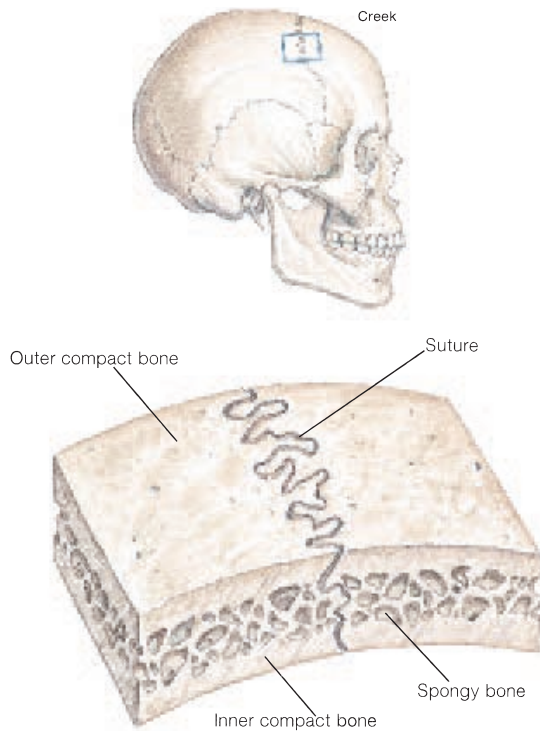
**Objective 5** Describe the structure of gomphoses and note their location. Also, discuss the importance of these joints in dentistry.

### Sutures

**Sutures** are found only within the skull. They are characterized by a thin layer of dense irregular connective tissue that binds the articulating bones (fig. 8.1). Sutures form at about 18 months of age and replace the pliable fontanels of an infant's skull (see fig. 6.13).


Different types of sutures can be distinguished by the appearance of the articulating edge of bone. A **serrate suture** is characterized by interlocking sawlike articulations. This is the most common type of suture, an example of which is the sagittal suture between the two parietal bones. In a **squamous (lap) suture**, the

## 198 Unit 4 Support and Movement




**FIGURE 8.1** A section of the skull showing a suture.

edge of one bone overlaps that of the articulating bone. The squamous suture formed between the temporal and parietal bones is an example. In a **plane** (butt) **suture**, the edges of the articulating bones are fairly smooth and do not overlap. An example is the median palatine suture, where the paired maxillary and palatine bones articulate to form the hard palate (see fig. 6.16).

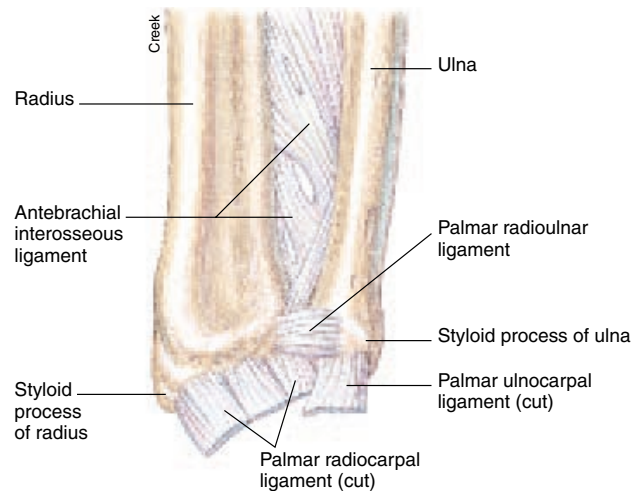
 The nomenclature in human anatomy is extensive and precise. There are over 30 named sutures in the skull, even though just a few of them are mentioned by name in figures 6.15, 6.16, and 6.17. Review these illustrations and make note of the bones that articulate to form the sutures identified.

A **synostosis** (*sin"os-to'sis*) is a sutural joint in that it is present during growth of the skull, but in the adult it generally becomes totally ossified. For example, the frontal bone forms as two separate components (see fig. 6.13b), but the suture becomes obscured in most individuals as the skull completes its growth.

 Fractures of the skull are fairly common in an adult but much less so in a child. The skull of a child is resilient to blows because of the nature of the bone and the layer of fibrous connective tissue within the sutures. The skull of an adult is much like an eggshell in its lack of resilience. It will frequently splinter on impact.

## Syndesmoses

**Syndesmoses** (*sin"des-mo'sēz*) are fibrous joints held together by collagenous fibers or sheets of fibrous tissue called *interosseous lig-*




**FIGURE 8.2** The side-to-side articulation of the ulna and radius forms a syndesmotic joint. An interosseous ligament tightly binds these bones and permits only slight movement between them.

*aments*. The articulating processes between adjacent vertebrae are syndesmoses. These types of joints also occur in the antebrachium (forearm) between the distal parts of the radius and ulna (fig. 8.2) and in the leg between the distal parts of the tibia and fibula. Slight movement is permitted at these joints as the antebrachium or leg is rotated.

## Gomphoses

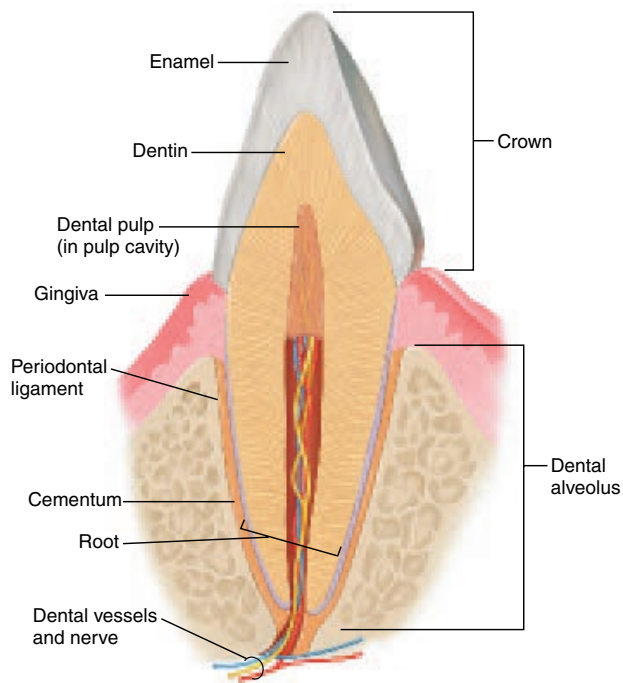
**Gomphoses** (*gom-fo'sēz*) are fibrous joints that occur between the teeth and the supporting bones of the jaws. More specifically, a gomphosis, or *dentoalveolar joint*, is where the root of a tooth is attached to the periodontal ligament of the dental alveolus (tooth socket) of the bone (fig. 8.3).

 **Periodontal disease** occurs at gomphoses. It refers to the inflammation and degeneration of the gum, periodontal ligaments, and alveolar bone tissue. With this condition, the teeth become loose and plaque accumulates on the roots. Periodontal disease may be caused by poor oral hygiene, compacted teeth (poor alignment), or local irritants, such as impacted food, chewing tobacco, or cigarette smoke.

## ✓ Knowledge Check

3. Compare and contrast the three kinds of sutures. Give an example of each and note its location.
4. In what way does the structure of a syndesmosis permit it to move slightly?
5. A gomphosis commonly is called a "peg-and-socket" joint. What do the "peg" and "socket" represent?





**FIGURE 8.3** A gomphosis is a fibrous joint in which a tooth is held in its socket (dental alveolus).

## CARTILAGINOUS JOINTS

Cartilaginous joints allow limited movement in response to twisting or compression. The two types of cartilaginous joints are symphyses and synchondroses.

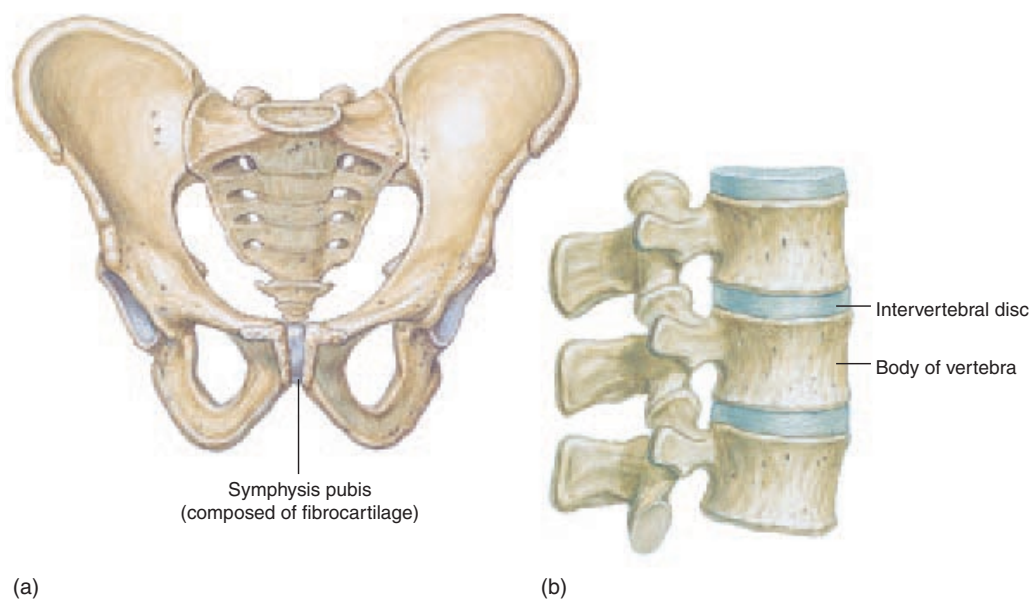
**Objective 6** Describe the structure of a symphysis and indicate where symphyses occur.

**Objective 7** Describe the structure of a synchondrosis and indicate where synchondroses occur.

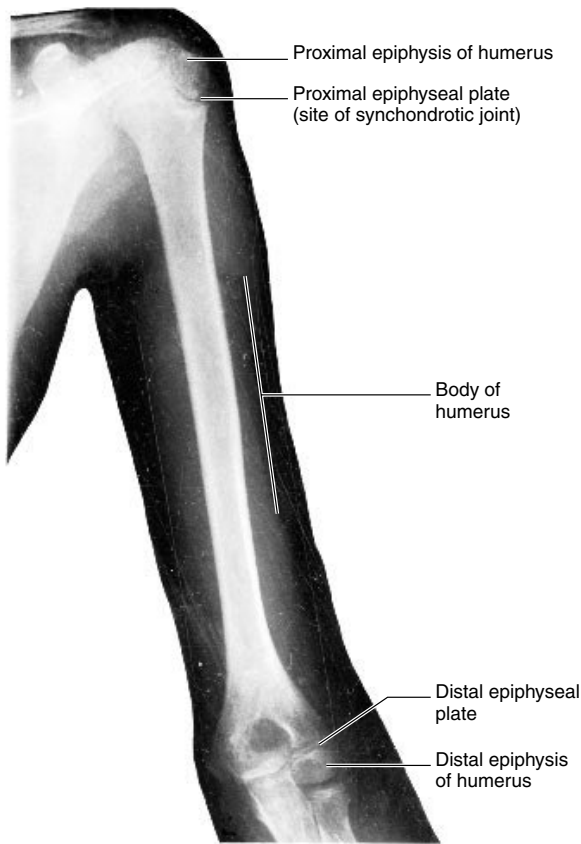
### Symphyses

The adjoining bones of a **symphysis** (*sim'fī-sis*) are covered with hyaline cartilage, which becomes infiltrated with collagenous fibers to form an intervening pad of fibrocartilage. This pad cushions the joint and allows limited movement. The symphysis pubis and the intervertebral joints formed by the intervertebral discs (fig. 8.4) are examples of symphyses. Although only limited motion is possible at each intervertebral joint, the combined movement of all of the joints of the vertebral column results in extensive spinal action.

symphysis: Gk. *symphysis*, growing together



**FIGURE 8.4** Examples of symphyses. (a) The symphysis pubis and (b) the intervertebral joints between vertebral bodies.



**FIGURE 8.5** A radiograph of the left humerus of a 10-year-old child showing a synchondrotic joint. In a long bone, this type of joint occurs at both the proximal and distal epiphyseal plates. The mitotic activity at synchondrotic joints is responsible for bone growth in length.

## Synchondroses

**Synchondroses** (*sin''kon-dro'sēz*) are cartilaginous joints that have hyaline cartilage between the articulating bones. Some of these joints are temporary, forming the epiphyseal plates (growth plates) between the diaphyses and epiphyses in the long bones of children (fig. 8.5). When growth is complete, these synchondrotic joints ossify. A totally ossified synchondrosis may also be referred to as a *synostosis*.



A fracture of a long bone in a child may be extremely serious if it involves the mitotically active epiphyseal plate of a synchondrotic joint. If such an injury is left untreated, bone growth is usually retarded or arrested, so that the appendage will be shorter than normal.

synchondrosis: Gk. *syn*, together; *chondros*, cartilage

synostosis: Gk. *syn*, together; *osteon*, bone

Synchondroses that do not ossify as a person ages are those that connect the bones of the floor and sides of the cranium and include the joints between the occipital, sphenoid, temporal, and ethmoid bones. In addition, the costochondral articulations between the ends of the ribs and the costal cartilages that attach to the sternum are examples of synchondroses. Elderly people often exhibit some ossification of the costal cartilages of the rib cage. This may restrict movement of the rib cage and obscure an image of the lungs in a thoracic radiograph.

## ✓ Knowledge Check

6. Discuss the function of the pad of fibrocartilage in a symphysis and give two examples of symphyses.
7. What structural feature is characteristic of all synchondroses? Give two examples of synchondroses.

## SYNOVIAL JOINTS

The freely movable synovial joints are enclosed by joint capsules containing synovial fluid. Based on the shape of the articular surfaces and the kinds of motion they permit, synovial joints are categorized as gliding, hinge, pivot, condyloid, saddle, or ball-and-socket.

**Objective 8** Describe the structure of a synovial joint.

**Objective 9** Discuss the various kinds of synovial joints, noting where they occur and the movements they permit.

The most obvious type of articulation in the body is the freely movable synovial joint. The function of synovial joints is to provide a wide range of precise, smooth movements, at the same time maintaining stability, strength, and, in certain aspects, rigidity in the body.

Synovial joints are the most complex and varied of the three major types of joints. A synovial joint's range of motion is determined by three factors:

1. the structure of the bones involved in the articulation (for example, the olecranon of the ulna limits hyperextension of the elbow joint);
2. the strength of the joint capsule and the strength and tautness of the associated ligaments and tendons; and
3. the size, arrangement, and action of the muscles that span the joint. Range of motion at synovial joints is characterized by tremendous individual variation, most of which is related to body conditioning (fig. 8.6). Excessive obesity may also limit the range of movement at synovial joints. Although some people can perform remarkable contortions and are said to be "double-jointed," they have no extra joints that help them do this. Rather, through conditioning, they are able to stretch the ligaments that normally inhibit movement.



**FIGURE 8.6** Although joint flexibility is structurally determined and limited, some individuals can achieve an extraordinary range of movement through extensive training.

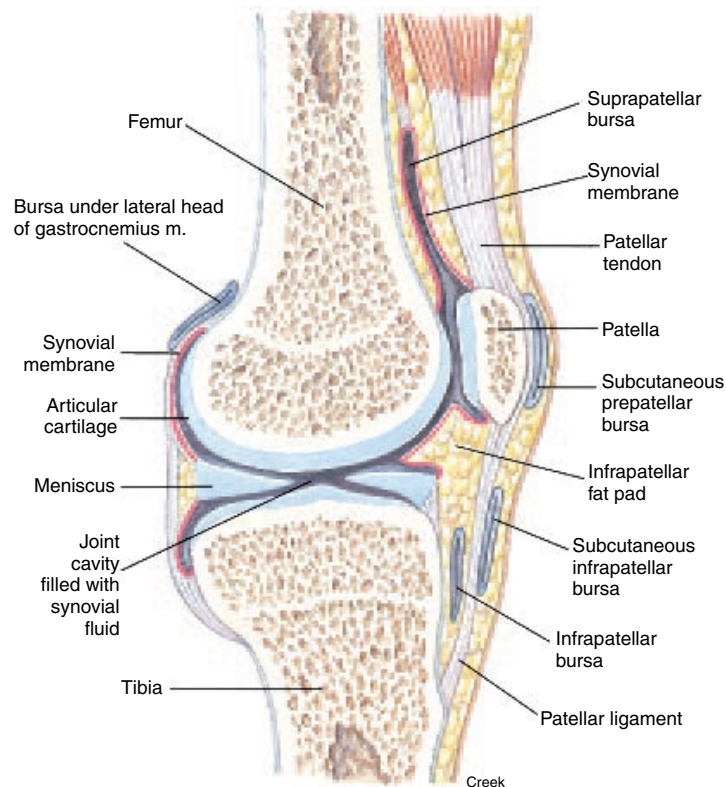


**Arthroplasty** is the surgical repair or replacement of joints. Advancements in this field continue as new devices are developed to restore lost joint function and permit movement that is free of pain. A recent advancement in the repair of soft tissues involves the use of *artificial ligaments*. A material consisting of carbon fibers coated with a plastic called polylactic acid is sewn in and around torn ligaments and tendons. This reinforces the traumatized structures and provides a scaffolding on which the body's collagenous fibers can grow. As healing progresses, the polylactic acid is absorbed and the carbon fibers break down.

## Structure of a Synovial Joint

Synovial joints are enclosed by a **joint capsule** (articular capsule) composed of dense regular connective tissue. Each joint capsule encloses lubricating **synovial fluid** contained within the **joint cavity** (fig. 8.7). The term *synovial* is derived from a Greek word meaning “egg white,” which this fluid resembles. It is secreted by

arthroplasty: Gk. *arthron*, joint; *plasso*, to form



**FIGURE 8.7** A synovial joint is represented by the knee joint, shown here in a sagittal view.

## 202 Unit 4 Support and Movement

a thin **synovial membrane** that lines the inside of the joint capsule. Synovial fluid is similar to interstitial fluid (fluid between the cells). It is rich in hyaluronic acid and albumin, and also contains phagocytic cells that clean up tissue debris resulting from wear on the joint cartilages. The bones that articulate in a synovial joint are capped with a smooth layer of hyaline cartilage called the **articular cartilage**. Articular cartilage is only about 2 mm thick. Because articular cartilage lacks blood vessels, it has to be nourished by the movement of synovial fluid during joint activity.

Composed of dense regular connective tissue, **ligaments** are flexible cords that connect from bone to bone as they help bind synovial joints. Ligaments may be located within the joint cavity or on the outside of the joint capsule. Tough, fibrous cartilaginous pads called **menisci** (*mĕ-nis'ki*—singular, *meniscus*) are unique to the knee joint, where they cushion and guide the articulating bones. A few other synovial joints, such as the temporomandibular joint (see fig. 8.23), have a fibrocartilaginous pad called an **articular disc** that provides functions similar to menisci.



Many people are concerned about the cracking sounds they hear as joints move, or the popping sounds that result from “popping” or “cracking” the knuckles by forcefully pulling on the fingers. These sounds are actually quite normal. When a synovial joint is pulled upon, its volume is suddenly expanded and the pressure of the joint fluid is lowered, causing a partial vacuum within the joint. As the joint fluid is displaced and hits against the articular cartilage, air bubbles burst and a popping or cracking sound is heard. Similarly, displaced water in a sealed vacuum tube makes this sound as it hits against the glass wall. Popping your knuckles does not cause arthritis, but it can lower your social standing.



The articular cartilage that caps the articular surface of each bone and the synovial fluid that circulates through the joint during movement are protective features of synovial joints. They serve to minimize friction and cushion the articulating bones. Should trauma or disease render either of them nonfunctional, the two articulating bones will come in contact. Bony deposits will then form, and a type of arthritis will develop within the joint.

Closely associated with some synovial joints are flattened, pouchlike sacs called **bursae** (*bur'se*—singular *bursa*) that are filled with synovial fluid (fig. 8.8a). These closed sacs are commonly located between muscles, or in areas where a tendon passes over a bone. They function to cushion certain muscles and assist the movement of tendons or muscles over bony or ligamentous surfaces. A **tendon sheath** (fig. 8.8b) is a modified bursa that surrounds and lubricates the tendons of certain muscles, particularly those that cross the wrist and ankle joints.



Improperly fitted shoes or inappropriate shoes can cause joint related problems. People who perpetually wear high-heeled shoes often have backaches and leg aches because their posture has to counteract the forward tilt of their bodies when standing or walking. Their knees are excessively flexed, and their spine is thrust forward at the lumbar curvature in order to maintain balance. Tightly fitted shoes, especially those with pointed toes, may result in the development of *hallux valgus*—a lateral deviation of the hallux (great toe)

in the direction of the other toes. *Hallux valgus* is generally accompanied by the formation of a *bunion* at the medial base of the proximal phalanx of the hallux. A bunion is an inflammation and accompanying callus that develops in response to pressure and rubbing of a shoe.

## Kinds of Synovial Joints

Synovial joints are classified into six main categories on the basis of their structure and the motion they permit. The six categories are *gliding*, *hinge*, *pivot*, *condyloid*, *saddle*, and *ball-and-socket*.

### Gliding

Gliding joints allow only side-to-side and back-and-forth movements, with some slight rotation. This is the simplest type of joint movement. The articulating surfaces are nearly flat, or one may be slightly concave and the other slightly convex (fig. 8.9). The intercarpal and intertarsal joints, the sternoclavicular joint, and the joint between the articular processes of adjacent vertebrae are examples.

### Hinge

Hinge joints are *monaxial*—like the hinge of a door, they permit movement in only one plane. In this type of articulation, the surface of one bone is always concave, and the other convex (fig. 8.10). Hinge joints are the most common type of synovial joints. Examples include the knee, the humeroulnar articulation within the elbow, and the joints between the phalanges.

### Pivot

The movement at a pivot joint is limited to rotation about a central axis. In this type of articulation, the articular surface on one bone is conical or rounded and fits into a depression on another bone (fig. 8.11). Examples are the proximal articulation of the radius and ulna for rotation of the forearm, as in turning a door-knob, and the articulation between the atlas and axis that allows rotational movement of the head.

### Condyloid

A condyloid articulation is structured so that an oval, convex articular surface of one bone fits into a concave depression on another bone (fig. 8.12). This permits angular movement in two directions, as in up-and-down and side-to-side motions. Condyloid joints are therefore said to be *biaxial* joints. The radiocarpal joint of the wrist and the metacarpophalangeal joints are examples.

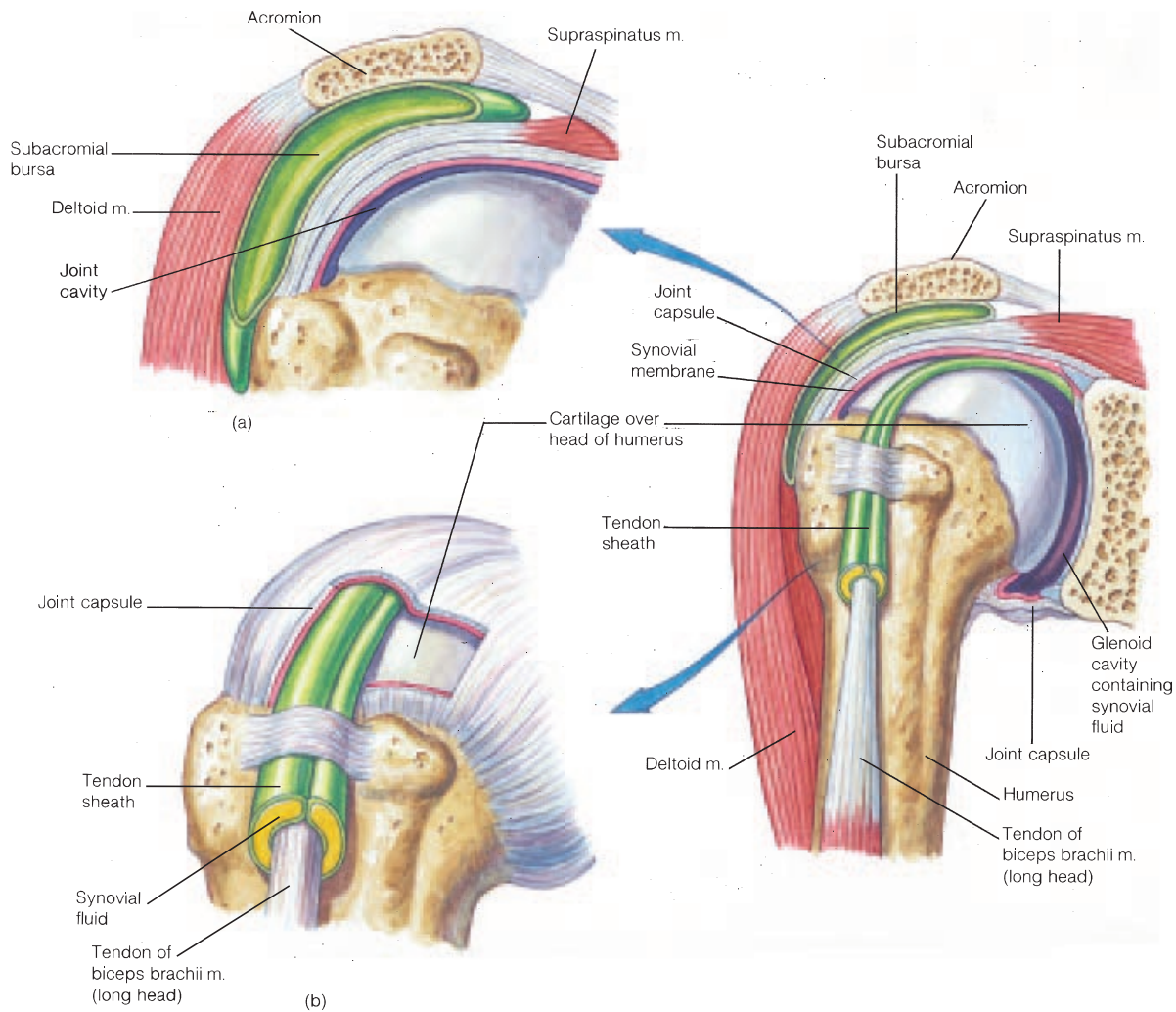
### Saddle

Each articular process of a saddle joint has a concave surface in one direction and a convex surface in another. This articulation is a modified condyloid joint that allows a wide range of movement. There are two places in the body where a saddle joint occurs. One is at the articulation of the trapezium of the carpus with the first metacarpal bone (fig. 8.13). This carpometacarpal joint is the one responsible for the opposable thumb—a hallmark of primate anatomy. The other is at the articulation between the

meniscus: Gk. *meniskos*, small moon

bursa: Gk. *byrsa*, bag or purse






**FIGURE 8.8** Bursae and tendon sheaths are friction-reducing structures found in conjunction with synovial joints. (a) A bursa is a closed sac filled with synovial fluid. Bursae are commonly located between muscles or between tendons and joint capsules. (b) A tendon sheath is a double-layered sac of synovial fluid that completely envelops a tendon.

malleus and incus, two of the auditory ossicles of the middle ear (see fig. 6.31).

### Ball-and-Socket

Ball-and-socket joints are formed by the articulation of a rounded convex surface with a cuplike cavity (fig. 8.14). This *multiaxial* type of articulation provides the greatest range of movement of all the synovial joints. Examples are the glenohumeral (shoulder) and coxal (hip) joints.

A summary of the various types of joints is presented in table 8.1.

 Trauma to a synovial joint causes the excessive production of synovial fluid in an attempt to cushion and immobilize the joint.

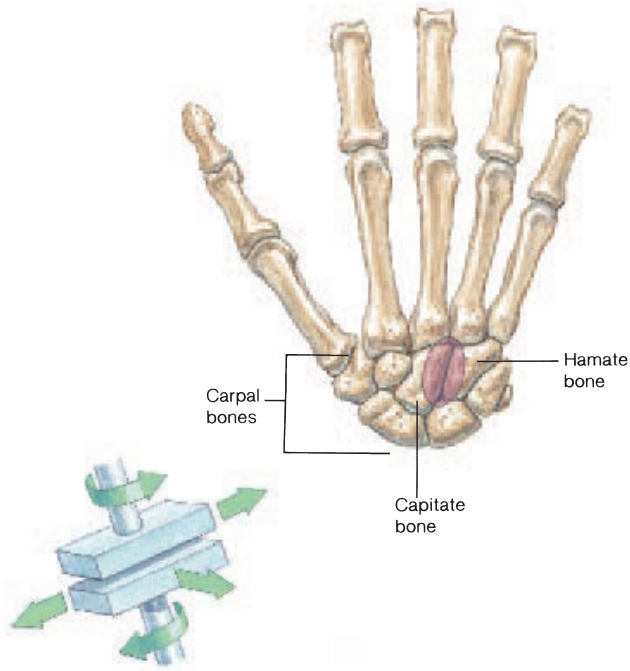
This leads to swelling of the joint and discomfort. In extreme cases, some of the synovial fluid may be drained by a needle punctured through the joint capsule. The most frequent type of joint injury is a *sprain*, in which the supporting ligaments or the joint capsule are damaged to varying degrees.

### ✓ Knowledge Check

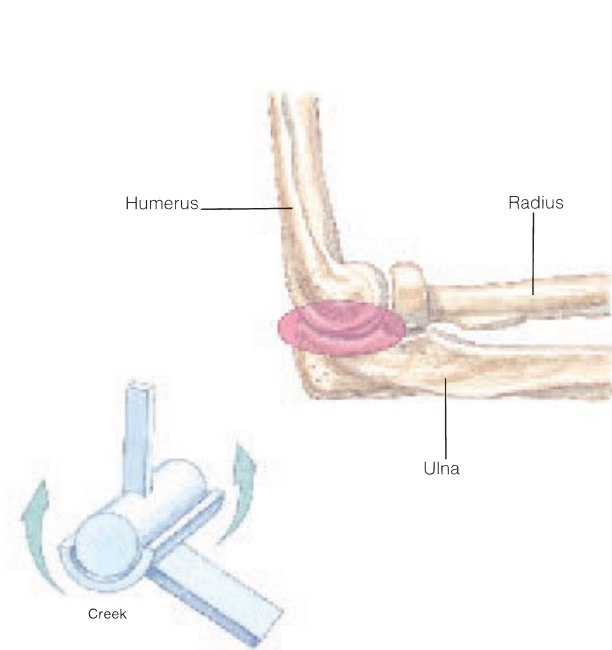
- List the structures of a synovial joint and explain the function of each.
- What three factors limit the range of movement in synovial joints?
- Give an example of each type of synovial joint and describe the range of movement allowed by each.



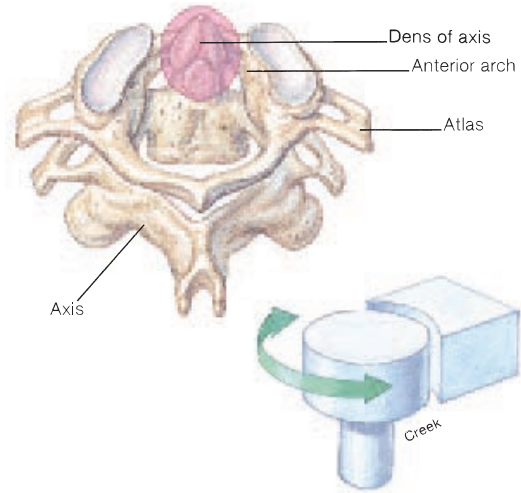
204 Unit 4 Support and Movement



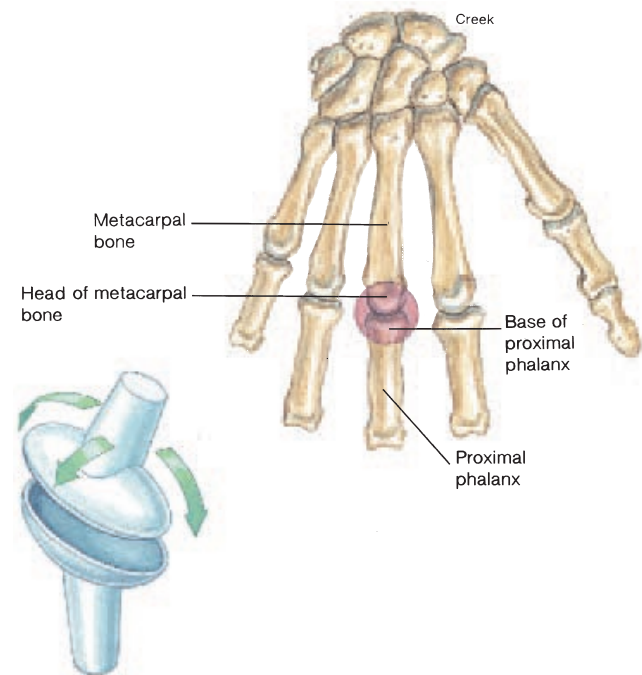
**FIGURE 8.9** The intercarpal articulations in the wrist are examples of gliding joints in which the articulating surfaces of the adjacent bones are flattened or slightly curved. Note the diagrammatic representation showing the direction of possible movement.



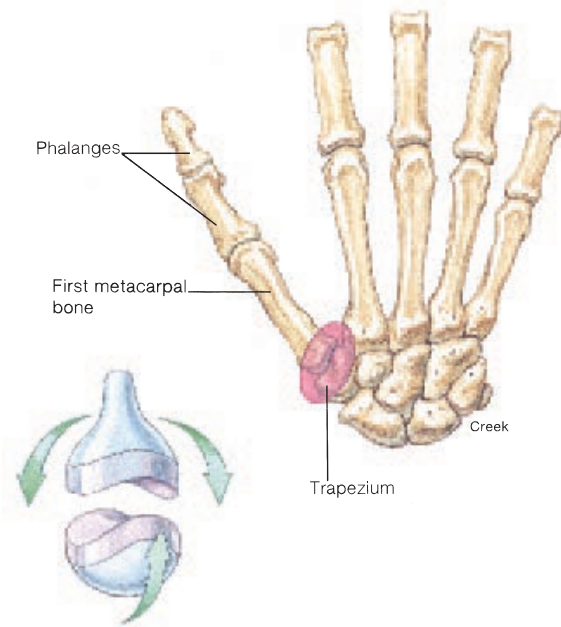
**FIGURE 8.10** A hinge joint permits only a bending movement (flexion and extension). The hinge joint of the elbow involves the articulation of the distal end of the humerus with the proximal end of the ulna. Note the diagrammatic representation showing the direction of possible movement.



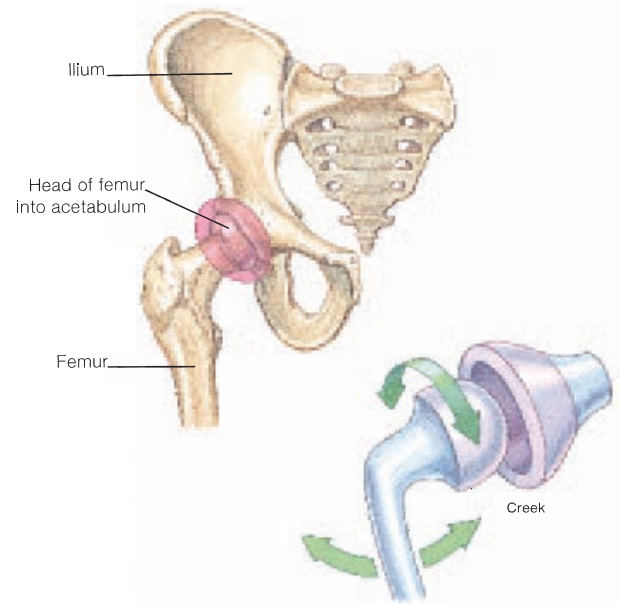
**FIGURE 8.11** The articulation of the atlas with the axis forms a pivot joint that permits a rotation. Note the diagrammatic representation showing the direction of possible movement. (Refer to figure 8.10 and determine which articulating bones of the elbow region form a pivot joint.)



**FIGURE 8.12** The metacarpophalangeal articulations of the hand are examples of condyloid joints in which the oval condyle of one bone articulates with the cavity of another. Note the diagrammatic representation showing the direction of possible movement.



**FIGURE 8.13** A saddle joint is formed as the trapezium articulates with the base of the first metacarpal bone. Note the diagrammatic representation showing the direction of possible movement.



**FIGURE 8.14** A ball-and-socket articulation illustrated by the hip joint. Note the diagrammatic representation showing the direction of possible movement.

**TABLE 8.1** Types of Articulations

Type	Structure	Movements	Example
<b>Fibrous Joints</b>	Skeletal elements joined by fibrous connective tissue		
1. Suture	Edges of articulating bones frequently jagged; separated by thin layer of fibrous tissue	None	Sutures between bones of the skull
2. Syndesmoses	Articulating bones bound by interosseous ligament	Slightly movable	Joints between tibia-fibula and radius-ulna
3. Gomphoses	Teeth bound into dental alveoli of bone by periodontal ligament	Slightly movable	Dentoalveolar joints (teeth secured in dental alveoli)
<b>Cartilaginous Joints</b>	Skeletal elements joined by fibrocartilage or hyaline cartilage		
1. Symphyses	Articulating bones separated by pad of fibrocartilage	Slightly movable	Intervertebral joints; symphysis pubis
2. Synchondroses	Mitotically active hyaline cartilage located between skeletal elements	None	Epiphyseal plates within long bones; costal cartilages of rib cage
<b>Synovial Joints</b>	Joint capsule containing synovial membrane and synovial fluid		
1. Gliding	Flattened or slightly curved articulating surfaces	Sliding	Intercarpal and intertarsal joints
2. Hinge	Concave surface of one bone articulates with convex surface of another	Bending motion in one plane	Knee; elbow; joints of phalanges
3. Pivot	Conical surface of one bone articulates with depression of another	Rotation about a central axis	Atlantoaxial joint; proximal radioulnar joint
4. Condyloid	Oval condyle of one bone articulates with elliptical cavity of another	Movement in two planes	Radiocarpal joint; metacarpophalangeal joint
5. Saddle	Concave and convex surface on each articulating bone	Wide range of movements	Carpometacarpal joint of thumb
6. Ball-and-socket	Rounded convex surface of one bone articulates with cuplike socket of another	Movement in all planes and rotation	Shoulder and hip joints

# Developmental Exposition

## The Synovial Joints

### EXPLANATION

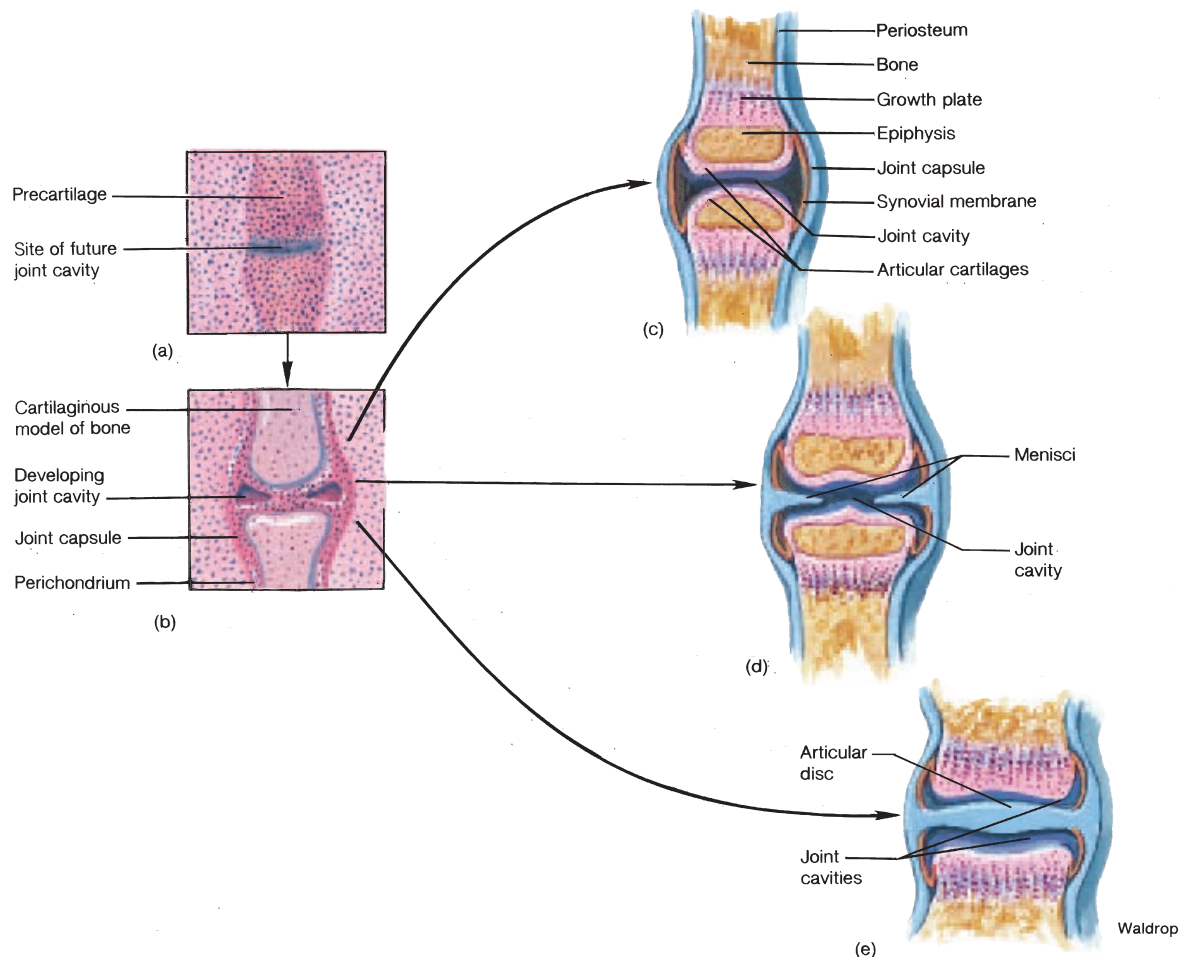
The sites of developing synovial joints (freely movable joints) are discernible at 6 weeks as mesenchyme becomes concentrated in the areas where precartilage cells differentiate (exhibit I). At this stage, the future joints appear as intervals of less concentrated mesenchymal cells. As cartilage cells develop within a forming bone, a thin flattened sheet of cells forms around the cartilaginous model to become the **perichondrium**. These same cells are continuous across the gap between the adjacent developing bone. Surrounding the gap, the flattened mesenchymal cells differentiate to become the **joint capsule**.

During the early part of the third month of development, the mesenchymal cells still remaining within the joint capsule begin to migrate toward the epiphyses of the adjacent developing bones. The

cleft eventually enlarges to become the **joint cavity**. Thin pads of hyaline cartilage develop on the surfaces of the epiphyses that contact the joint cavity. These pads become the **articular cartilages** of the functional joint. As the joint continues to develop, a highly vascular **synovial membrane** forms on the inside of the joint capsule and begins secreting a watery **synovial fluid** into the joint cavity.

In certain developing synovial joints, the mesenchymal cells do not migrate away from the center of the joint cavity. Rather, they give rise to cartilaginous wedges called **menisci**, as in the knee joint, or to complete cartilaginous pads called **articular discs**, as in the sternoclavicular joint.

Most synovial joints have formed completely by the end of the third month. Shortly thereafter, fetal muscle contractions, known as *quickening*, cause movement at these joints. Joint movement enhances the nutrition of the articular cartilage and prevents the fusion of connective tissues within the joint.



**EXHIBIT I** Development of synovial joints. (a) At 6 weeks, different densities of mesenchyme denote where the bones and joints will form. (b) At 9 weeks, a basic synovial model is present. At 12 weeks, the synovial joints are formed and have either (c) a free joint cavity (e.g., interphalangeal joint); (d) a cavity containing menisci (e.g., knee joint); or (e) a cavity with a complete articular disc (e.g., sternoclavicular joint).



## MOVEMENTS AT SYNOVIAL JOINTS

Movements at synovial joints are produced by the contraction of skeletal muscles that span the joints and attach to or near the bones forming the articulation. In these actions, the bones act as levers, the muscles provide the force, and the joints are the fulcra, or pivots.

**Objective 10** List and discuss the various kinds of movements that are possible at synovial joints.

**Objective 11** Describe the components of a lever and explain the role of synovial joints in lever systems.

**Objective 12** Compare the structures of first-, second-, and third-class levers.

As previously mentioned, the range of movement at a synovial joint is determined by the structure of the individual joint and the arrangement of the associated muscle and bone. The movement at a hinge joint, for example, occurs in only one plane, whereas the structure of a ball-and-socket joint permits movement around many axes. Joint movements are broadly classified as *angular* and *circular*. Each of these categories includes specific types of movements, and certain special movements may involve several of the specific types. The description of joint movements are in reference to anatomical position (see fig. 2.13).

### Angular Movements

**Angular movements** increase or decrease the joint angle produced by the articulating bones. The four types of angular movements are *flexion*, *extension*, *abduction*, and *adduction*.

#### Flexion

Flexion is movement that decreases the joint angle on an antero-posterior plane (fig. 8.15a). Examples of flexion are the bending of the elbow or knee. Flexion of the elbow joint is a forward movement, whereas flexion of the knee is a backward movement. Flexion of the ankle and shoulder joints is a bit more complicated. In the ankle joint, flexion occurs as the top surface (dorsum) of the foot is elevated. This movement is frequently called **dorsiflexion** (fig. 8.15b). Pressing the foot downward (as in rising on the toes) is called **plantar flexion**. Flexion of the shoulder joint consists of raising the arm anteriorly from anatomical position, as if to point forward.

flexion: L. *flectere*, to bend

#### Extension

In extension, which is the reverse of flexion, the joint angle is increased (fig. 8.15a). Extension returns a body part to anatomical position. In an extended joint, the angle between the articulating bones is 180°. An exception is the ankle joint, in which there is a 90° angle between the foot and leg in anatomical position. Examples of extension are straightening of the elbow or knee joints from flexion positions. **Hyperextension** occurs when a part of the body is extended beyond the anatomical position so that the joint angle is greater than 180°. An example of hyperextension is bending the neck to tilt the head backward, as in looking at the sky.



A common injury in runners is *patellofemoral stress syndrome*, commonly called “runner’s knee.” This condition is characterized by tenderness and aching pain around or under the patella. During normal knee movement, the patella glides up and down the patellar groove between the femoral condyles. In patellofemoral stress syndrome, the patella rubs laterally, causing irritation to the membranes and articular cartilage within the knee joint. Joggers frequently experience this condition from prolonged running on the slope of a road near the curb.

#### Abduction

Abduction is movement of a body part away from the main axis of the body, or away from the midsagittal plane, in a lateral direction (fig. 8.15c). This term usually applies to the upper and lower extremities but can also apply to the fingers or toes, in which case the line of reference is the longitudinal axis of the limb. An example of abduction is moving the arms sideward, away from the body. Spreading the fingers apart is another example.

#### Adduction

Adduction, the opposite of abduction, is movement of a body part toward the main axis of the body (fig. 8.15c). In anatomical position, the upper and lower extremities have been adducted toward the midplane of the body.

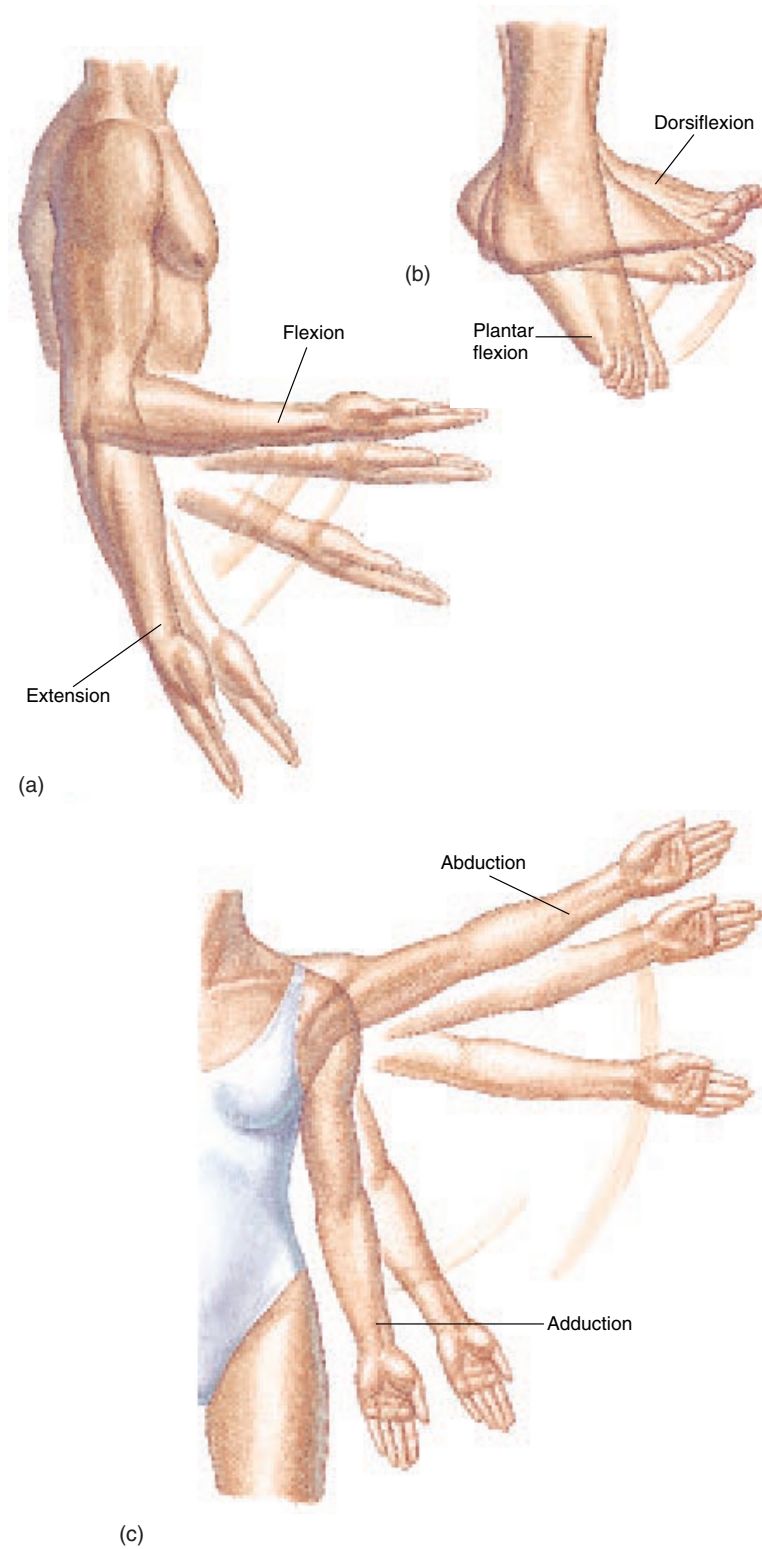
### Circular Movements

In joints that permit **circular movement**, a bone with a rounded or oval surface articulates with a corresponding depression on another bone. The two basic types of circular movements are *rotation* and *circumduction*.

extension: L. *ex*, out, away from; *tendere*, stretch

abduction: L. *abducere*, lead away

adduction: L. *adductus*, bring to



**FIGURE 8.15** Angular movements within synovial joints include (a) flexion and extension, (b) dorsiflexion and plantar flexion, and (c) abduction and adduction.

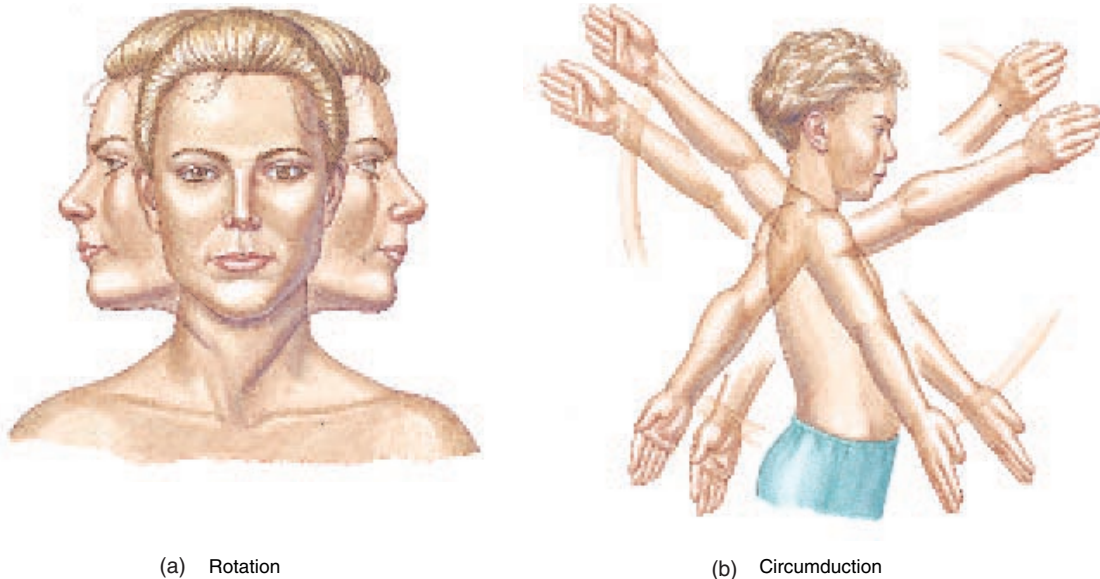


FIGURE 8.16 Circular movements within synovial joints include (a) rotation and (b) circumduction.

### Rotation

Rotation is movement of a body part around its own axis (see figs. 8.11 and 8.16a). There is no lateral displacement during this movement. Examples are turning the head from side to side, as if gesturing “no,” and twisting at the waist.

**Supination** (*soo’pi-na’shun*) is a specialized rotation of the forearm so that the palm of the hand faces forward (anteriorly) or upward (superiorly). In anatomical position, the forearm is already supine. **Pronation** (*pro-na’shun*) is the opposite of supination. It is a rotational movement of the forearm so that the palm is directed to the rear (posteriorly) or downward (inferiorly).

With respect to anatomical position, medial rotation of the shoulder joint occurs when an upper limb is moved across the body so that the palm of the hand could contact the abdomen. Lateral rotation is the opposite movement.


Medial rotation of the hip joint occurs as one lower limb is partially moved across the anterior surface of the other. Lateral rotation is the opposite movement.

### Circumduction

Circumduction is the circular movement of a body part so that a cone-shaped airspace is traced. The distal extremity performs the circular movement and the proximal attachment serves as the pivot (fig. 8.16b). This type of motion is possible at the trunk, shoulder, wrist, metacarpophalangeal, hip, ankle, and metatarsophalangeal joints.

### Special Movements

Because the terms used to describe generalized movements around axes do not apply to movement at certain joints or areas of the body, other terms must be used. **Inversion** is movement of the sole of the foot inward or medially (fig. 8.17a). **Eversion**, the opposite of inversion, is movement of the sole of the foot outward or laterally. The pivot axes for these movements are at the ankle and intertarsal joints. Both inversion and eversion are clinical terms that are usually used to describe developmental abnormalities.

 The condition of the heels of your shoes can tell you whether you invert or evert your foot as you walk. If the heel is worn down on the outer side, you tend to invert your foot as you walk. If the heel is worn down on the inside, you tend to evert your foot.

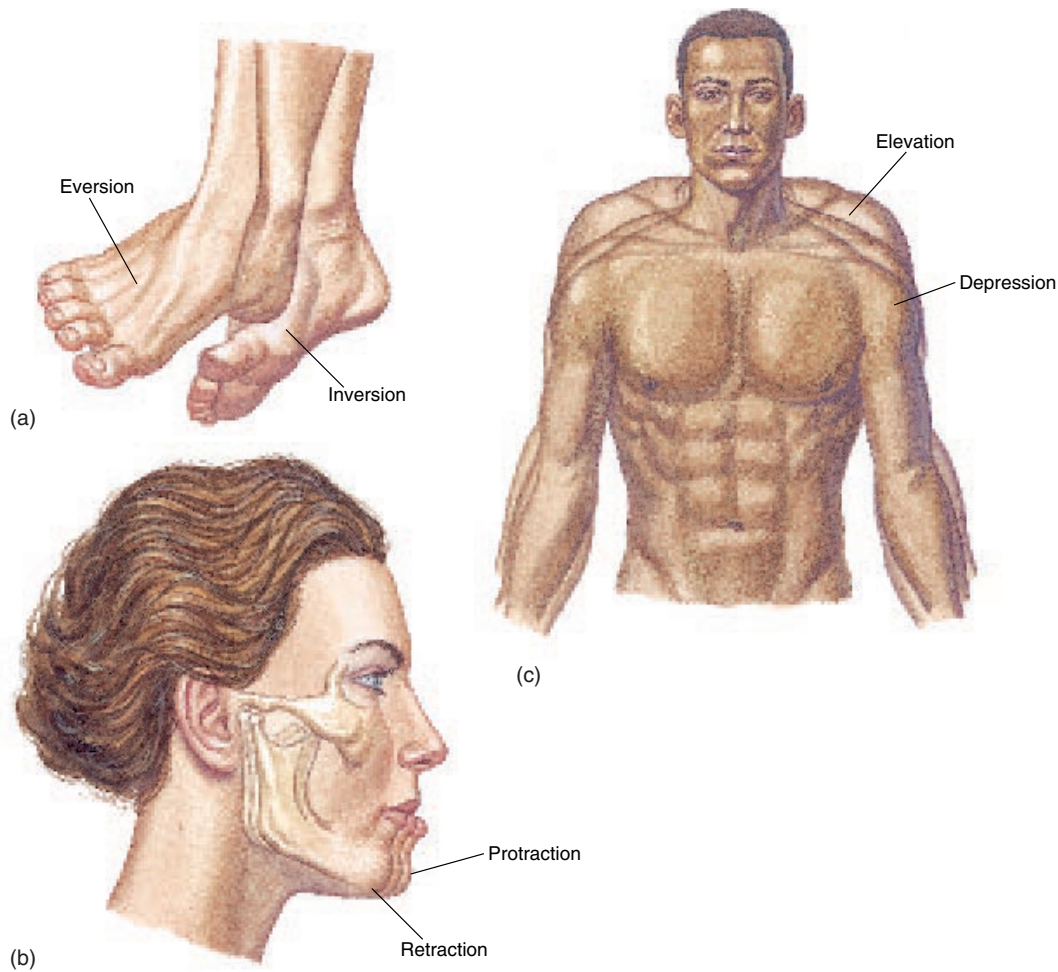
**Protraction** is movement of part of the body forward, on a plane parallel to the ground. The thrusting out of the lower jaw (fig. 8.17b) and the movement of the shoulder and upper extremity forward are examples. **Retraction**, the opposite of protraction, is the pulling back of a protracted part of the body on a plane parallel to the ground. Retraction of the mandible brings the lower jaw back in alignment with the upper jaw, so that the teeth occlude.

**Elevation** is movement that raises a body part. Examples include elevating the mandible to close the mouth and lifting the shoulders to shrug (fig. 8.17c). **Depression** is the opposite of elevation. Both the mandible and shoulders are depressed when moved downward.

Many of the movements permitted at synovial joints are visually summarized in figures 8.18 through 8.20.

rotation: L. *rotare*, a wheel






**FIGURE 8.17** Special movements within synovial joints include (a) inversion and eversion, (b) protraction and retraction, and (c) elevation and depression.

## Biomechanics of Body Movement

A lever is any rigid structure that turns about a fulcrum when force is applied. Levers are generally associated with machines but can also apply to other mechanical structures, such as the human body. There are four basic elements in the function of a lever: (1) the lever itself—a rigid bar or other such structure; (2) a pivot or fulcrum; (3) an object or resistance to be moved; and (4) a force that is applied to one portion of the rigid structure. In the body, synovial joints usually serve as the fulcra (**F**), the muscles provide the force, or effort (**E**), and the bones act as the rigid lever arms that move the resisting object (**R**).

There are three kinds of levers, determined by the arrangement of their parts (fig. 8.21).

1. In a **first-class lever**, the fulcrum is positioned between the effort and the resistance. The sequence of elements in a first-class lever is much like that of a seesaw—a sequence of resistance-pivot-effort. Scissors and hemostats are mechanical examples of first-class levers. In the body, the head at the atlanto-occipital (*at-lan'to-ok-sip'i-tal*) joint is a first-class lever. The weight of the skull and facial portion of the head is the resistance, and the posterior neck muscles that contract to oppose the tendency of the head to tip forward provide the effort.
2. In a **second-class lever**, the resistance is positioned between the fulcrum and the effort. The sequence of elements is pivot-resistance-effort, as in a wheelbarrow or the action of a crowbar when one end is placed under a rock




**FIGURE 8.18** A photographic summary of joint movements. (a) Adduction of shoulder, hip, and carpophalangeal joints; (b) abduction of shoulder, hip, and carpophalangeal joints; (c) rotation of vertebral column; (d) lateral flexion of vertebral column; (e) flexion of vertebral column; (f) hyperextension of vertebral column; (g) flexion of shoulder, hip, and knee joints of right side of body and extension of elbow and wrist joints; (h) hyperextension of shoulder and hip joints on right side of body and plantar flexion of right ankle joint.

and the other end lifted. Contraction of the calf muscles (E) to elevate the body (R) on the toes, with the ball of the foot acting as the fulcrum, is another example.

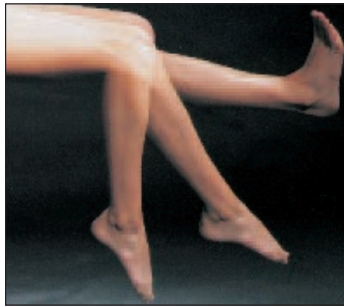
3. In a **third-class lever**, the effort lies between the fulcrum and the resistance. The sequence of elements is pivot-effort-resistance, as in the action of a pair of forceps in grasping an object. The third-class lever is the most common type in the body. The flexion of the elbow is an example. The effort occurs as the biceps

brachii muscle is contracted to move the resistance of the forearm, with the joint between the ulna and humerus forming the fulcrum.

Each bone-muscle interaction at a synovial joint represents some kind of lever system, and each lever system confers an advantage. Certain joints are adapted for force at the expense of speed, whereas most are clearly adapted for speed. The specific attachment of muscles that span a joint plays an extremely important role in determining the mechanical advantage



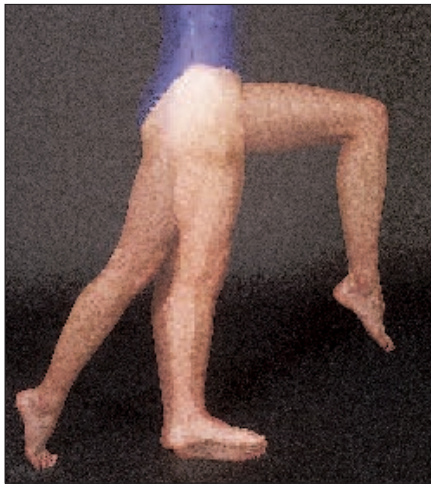
(a)



(b)



(c)



(d)




(e)

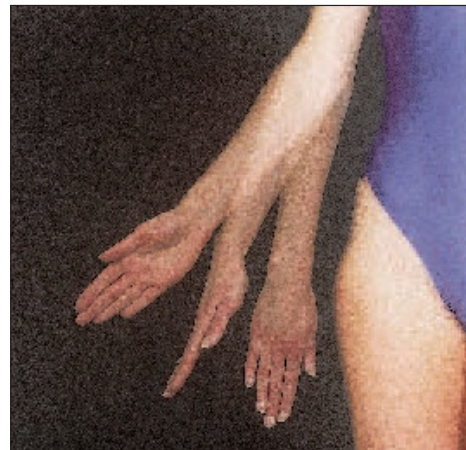

(f)

**FIGURE 8.19** A photographic summary of some angular movements at synovial joints. (a) Flexion, extension, and hyperextension in the cervical region; (b) flexion and extension at the knee joint, and plantar flexion and dorsiflexion at the ankle joint; (c) flexion and extension at the elbow joint, and flexion, extension, and hyperextension at the hip joint; (d) flexion, extension, and hyperextension at the knee joint; (e) adduction and abduction of the arm and fingers; (f) abduction and adduction of the wrist joint (posterior view). Note that the range of abduction at the wrist joint is less extensive than the range of adduction as a result of the length of the styloid process of the radius.



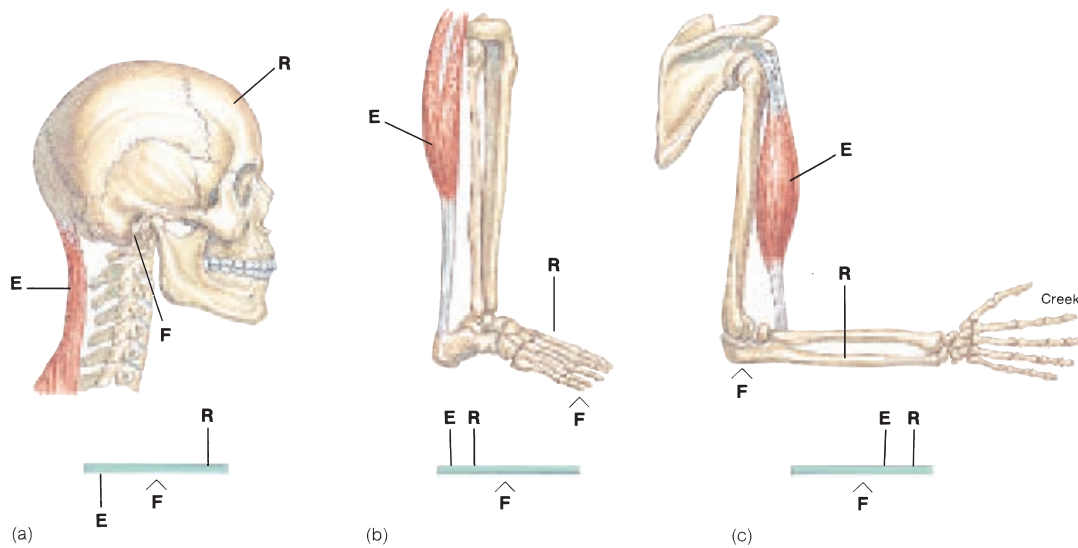
(a)



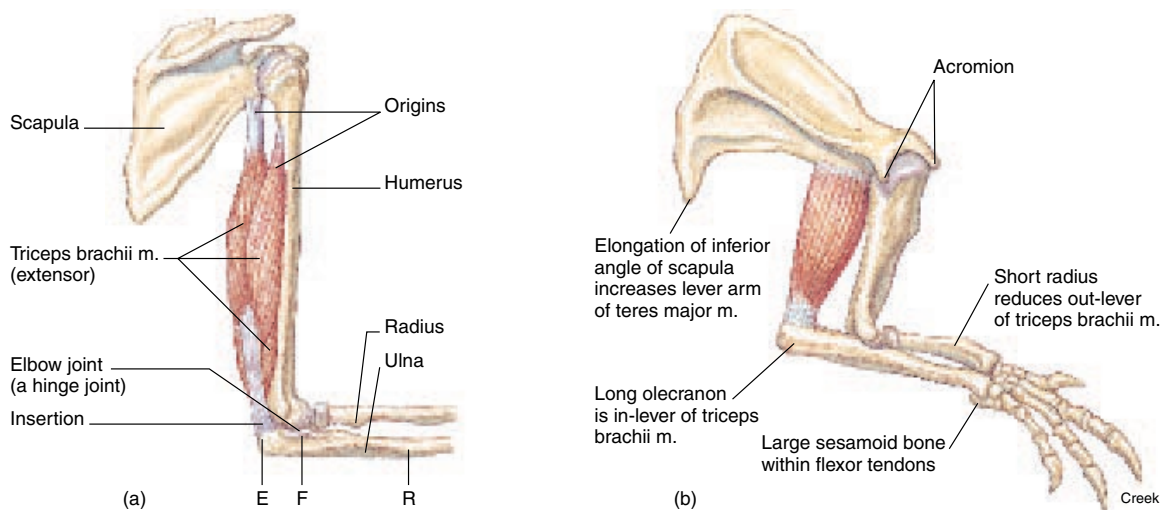
(b)

**FIGURE 8.20** A photographic summary of some rotational movements at synovial joints. (a) Rotation of the head at the cervical vertebrae, especially at the atlantoaxial joint, and (b) rotation of the forearm (antebrachium) at the proximal radioulnar joint.





**FIGURE 8.21** The three classes of levers. (a) In a first-class lever, the fulcrum (F) is positioned between the resistance (R) and the effort (E). (b) In a second-class lever, the resistance is between the fulcrum and the effort. (c) In a third-class lever, the effort is between the fulcrum and the resistance.

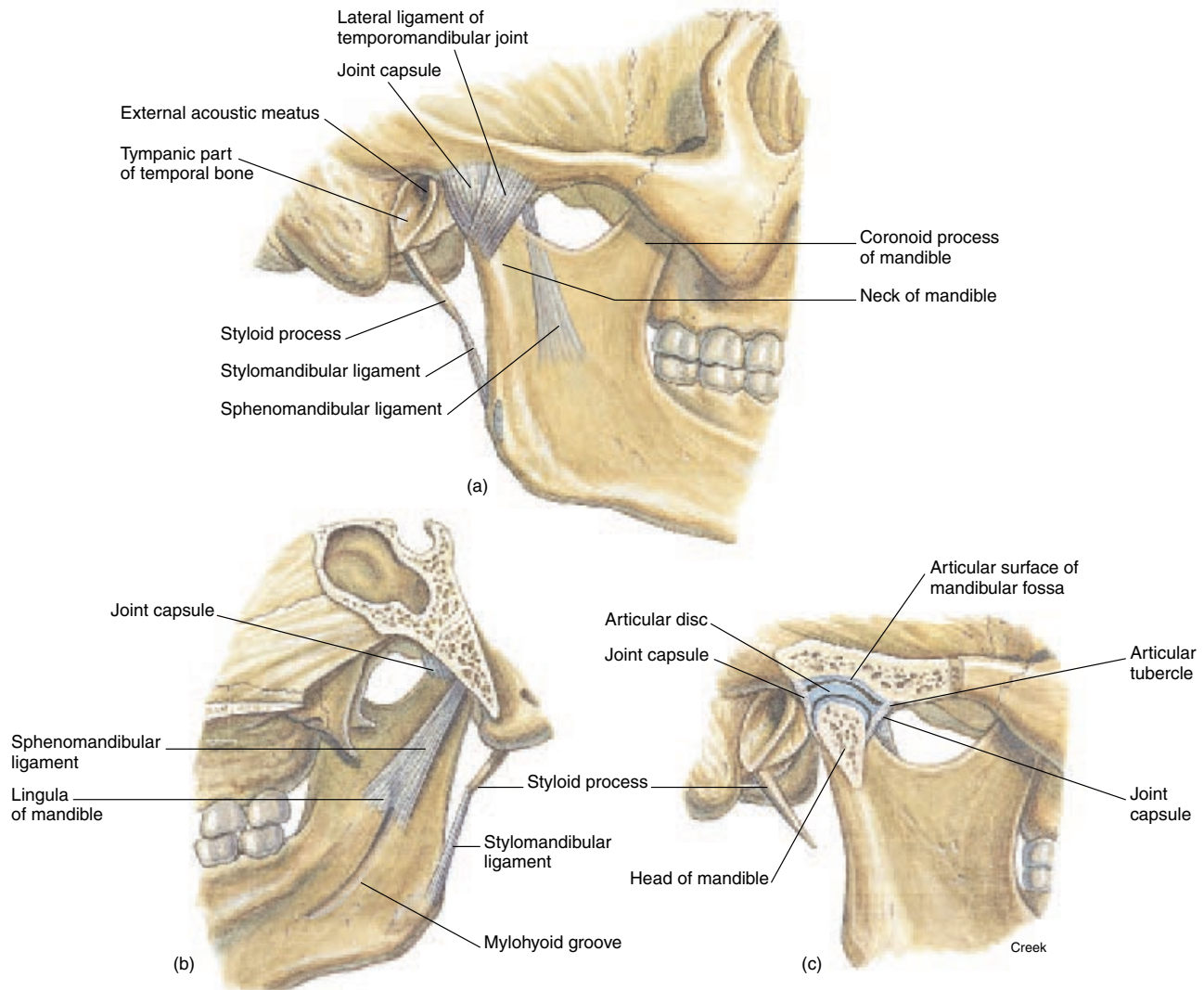


**FIGURE 8.22** The position of a joint (fulcrum) relative to the length of a long bone (lever arm) and the point of attachment of a muscle (force) determines the mechanical advantage when movement occurs. (a) The elbow joint and extensor muscles of a human and (b) the elbow joint and extensor muscles of an armadillo.

(fig. 8.22). The position of the insertion of a muscle relative to the joint is an important factor in the biomechanics of the contraction. An insertion close to the joint (fulcrum), for example, will produce a faster movement and greater range of movement than an insertion that is more distant from the joint. An attachment far from the joint capitalizes on the length of the lever arm (bone), and increases force at the sacrifice of speed and range of movement.

## ✓ Knowledge Check

- Describe the structure of a joint that permits rotational movement.
- What types of joints are involved in the body's lever systems?
- Which is the most common type of lever in the body?



**FIGURE 8.23** The temporomandibular joint. (a) A lateral view, (b) a medial view, and (c) a sagittal view.

## SPECIFIC JOINTS OF THE BODY

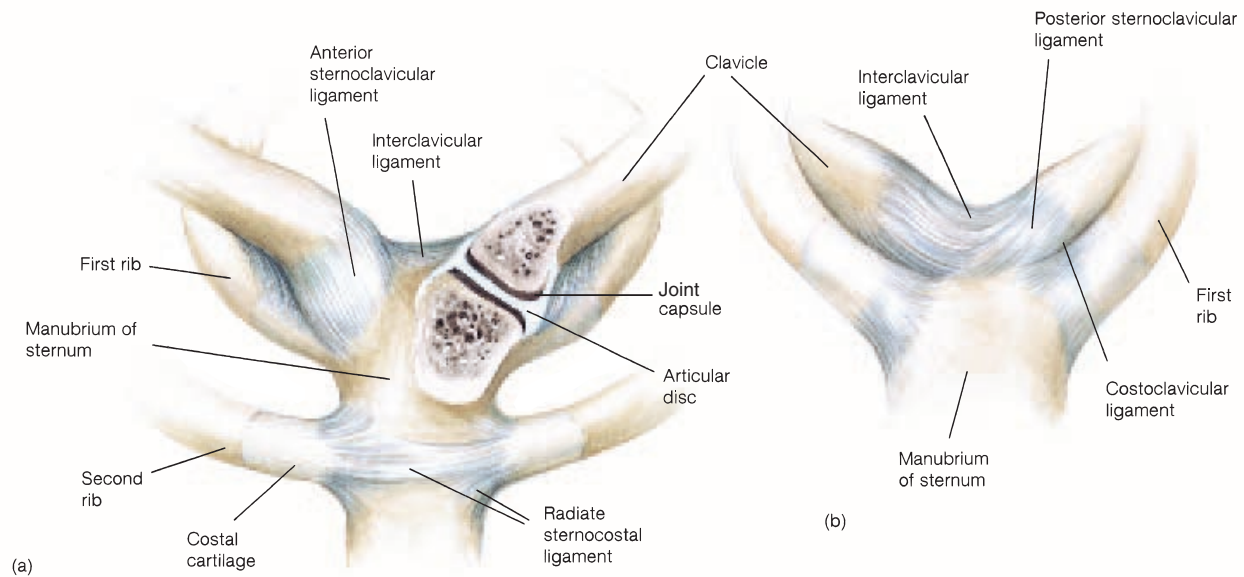
Of the numerous joints in the body, some have special structural features that enable them to perform particular functions. These joints are also somewhat vulnerable to trauma and are therefore clinically important.

**Objective 13** Describe the structure, function, and possible clinical importance of the following joints: temporomandibular, sternoclavicular, glenohumeral, elbow, metacarpophalangeal, interphalangeal, coxal, tibiofemoral, and talocrural.

## Temporomandibular Joint

The **temporomandibular joint** represents a unique combination of a hinge joint and a gliding joint (fig. 8.23). It is formed by the condylar process of the mandible and the mandibular fossa and articular tubercle of the temporal bone. An **articular disc** separates the joint cavity into superior and inferior compartments.

Three major ligaments support and reinforce the temporomandibular joint. The **lateral ligament** of the temporomandibular joint is positioned on the lateral side of the joint capsule and is covered by the parotid gland. This ligament prevents the head of the mandible from being displaced posteriorly and fracturing



**FIGURE 8.24** The sternoclavicular joint and associated ligaments. (a) An anterior view showing a coronal (frontal) section and (b) a posterior view.

the tympanic plate when the chin suffers a severe blow. The **stylomandibular ligament** is not directly associated with the joint but extends inferiorly and anteriorly from the styloid process to the posterior border of the ramus of the mandible. On the medial side by the joint, a **sphenomandibular** (*sfe''no-man-dib'yū-lar*) **ligament** extends from the spine of the sphenoid bone to the ramus of the mandible.

The movements of the temporomandibular joint include depression and elevation of the mandible as a hinge joint, protraction and retraction of the mandible as a gliding joint, and lateral rotatory movements. The lateral motion is made possible by the articular disc.



The temporomandibular joint can be easily palpated by applying firm pressure to the area in front of your ear and opening and closing your mouth. This joint is most vulnerable to dislocation when the mandible is completely depressed, as in yawning. Relocating the jaw is usually a simple task, however, and is accomplished by pressing down on the molars while pushing the jaw backward.



**Temporomandibular joint (TMJ) syndrome** is a recently recognized ailment that may afflict an estimated 75 million Americans. The apparent cause of TMJ syndrome is a malalignment of one or both temporomandibular joints. The symptoms of the condition range from moderate and intermittent facial pain to intense and continuous pain in the head, neck, shoulders, or back. Clicking sounds in the jaw and limitation of jaw movement are common symptoms. Some vertigo (dizziness) and tinnitus (ringing in the ears) may also occur.

## Sternoclavicular Joint

The **sternoclavicular** (*ster''no-klāv-ik'yū-lar*) **joint** is formed by the sternal extremity of the clavicle and the manubrium of the sternum (fig. 8.24). Although a gliding joint, the sternoclavicular joint has a relatively wide range of movement because of the presence of an articular disc within the joint capsule.

Four ligaments support the sternoclavicular joint and provide flexibility. An **anterior sternoclavicular ligament** covers the anterior surface of the joint, and a **posterior sternoclavicular ligament** covers the posterior surface. Both ligaments extend from the sternal end of the clavicle to the manubrium. An **interclavicular ligament** extends between the sternal ends of both clavicles, binding them together. The **costoclavicular ligament** extends from the costal cartilage of the first rib to the costal tuberosity of the clavicle.



Of all the joints associated with the rib cage, the sternoclavicular joint is the one most frequently dislocated. Excessive force along the long axis of the clavicle may displace the clavicle forward and downward. Injury to the costal cartilages is painful and is caused most frequently by a forceful, direct blow to the costal cartilages.

## Glenohumeral (Shoulder) Joint

The **shoulder joint** is formed by the head of the humerus and the glenoid cavity of the scapula (fig. 8.25). It is a ball-and-socket joint and the most freely movable joint in the body. A circular

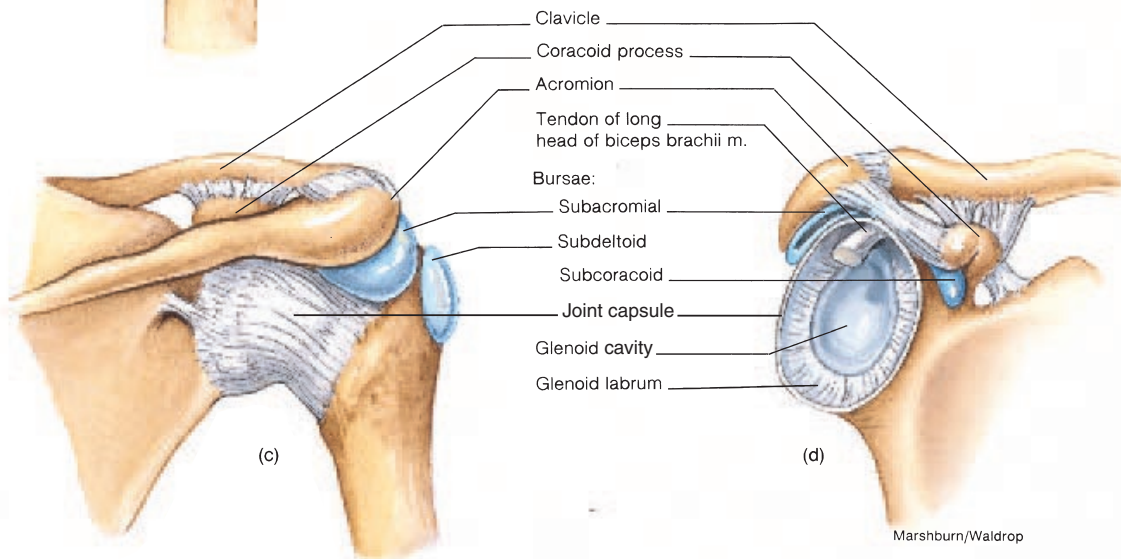


216 Unit 4 Support and Movement

Ligaments:

Coracoclavicular  
Acromioclavicular  
Coracoacromial  
Coracohumeral  
Bursae:  
Subacromial  
Subcoracoid  
Subdeltoid  
Subscapular  
Transverse  
humeral  
retinaculum  
Tendon of  
long head of  
biceps brachii m.  
Humerus

Supraspinatus m.  
Tendon of supraspinatus m.  
Acromion  
Subacromial  
bursa  
Coracoid  
process  
Joint  
capsule



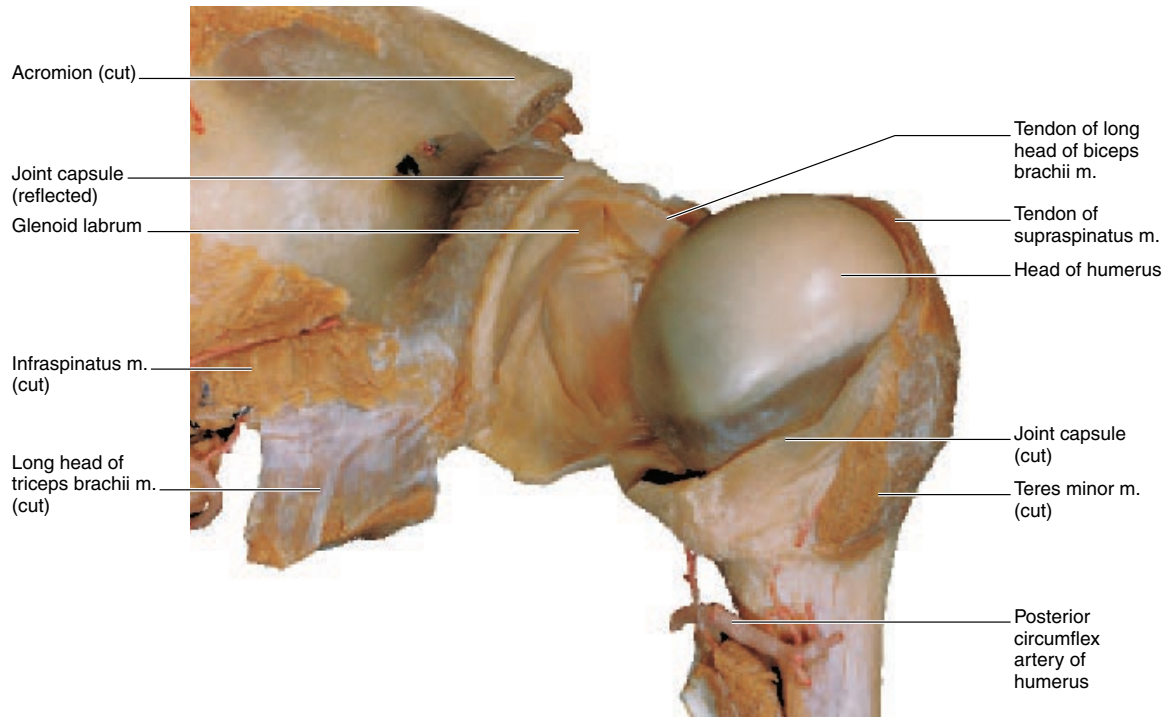
**FIGURE 8.25** The glenohumeral (shoulder) joint. (a) An anterior view, (b) a coronally sectioned anterior view, (c) a posterior view, and (d) a lateral view with the humerus removed.

band of fibrocartilage called the **glenoid labrum** passes around the rim of the shoulder joint and deepens the concavity of the glenoid cavity (figs. 8.25 and 8.26). The shoulder joint is protected from above by an arch formed by the acromion and coracoid process of the scapula and by the clavicle.

Although two ligaments and one retinaculum surround and support the shoulder joint, most of the stability of this joint de-

pends on the powerful muscles and tendons that cross over it. Thus, it is an extremely mobile joint in which stability has been sacrificed for mobility. The **coracohumeral** (*kor''ā-ko-hyoo'mer-al*) **ligament** extends from the coracoid process of the scapula to the greater tubercle of the humerus. The joint capsule is reinforced with three ligamentous bands called the **glenohumeral ligaments** (not illustrated). The final support of the shoulder joint is the **transverse humeral retinaculum**, a thin band that extends from the greater tubercle to the lesser tubercle of the humerus.

labrum: L. *labrum*, lip



**FIGURE 8.26** A posterior view of a dissected glenohumeral joint. An incision has been made into the joint capsule and the humerus has been retracted laterally and rotated posteriorly.

The stability of the shoulder joint is provided mainly by the tendons of the subscapularis, supraspinatus, infraspinatus, and teres minor muscles, which together form the *musculotendinous (rotator) cuff*. The cuff is fused to the underlying capsule, except in its inferior aspect. Because of the lack of inferior stability, most dislocations (subluxations) occur in this direction. The shoulder is most vulnerable to trauma when the arm is fully abducted and then receives a blow from above—as for example, when the outstretched arm is struck by heavy objects falling from a shelf. Degenerative changes in the musculotendinous cuff produce an inflamed, painful condition known as *pericapsulitis*.

Two major and two minor bursae are associated with the shoulder joint. The larger bursae are the **subdeltoid bursa**, located between the deltoid muscle and the joint capsule, and the **subacromial bursa**, located between the acromion and joint capsule. The **subcoracoid bursa**, which lies between the coracoid process and the joint capsule, is frequently considered an extension of the subacromial bursa. A small **subscapular bursa** is located between the tendon of the subscapularis muscle and the joint capsule.

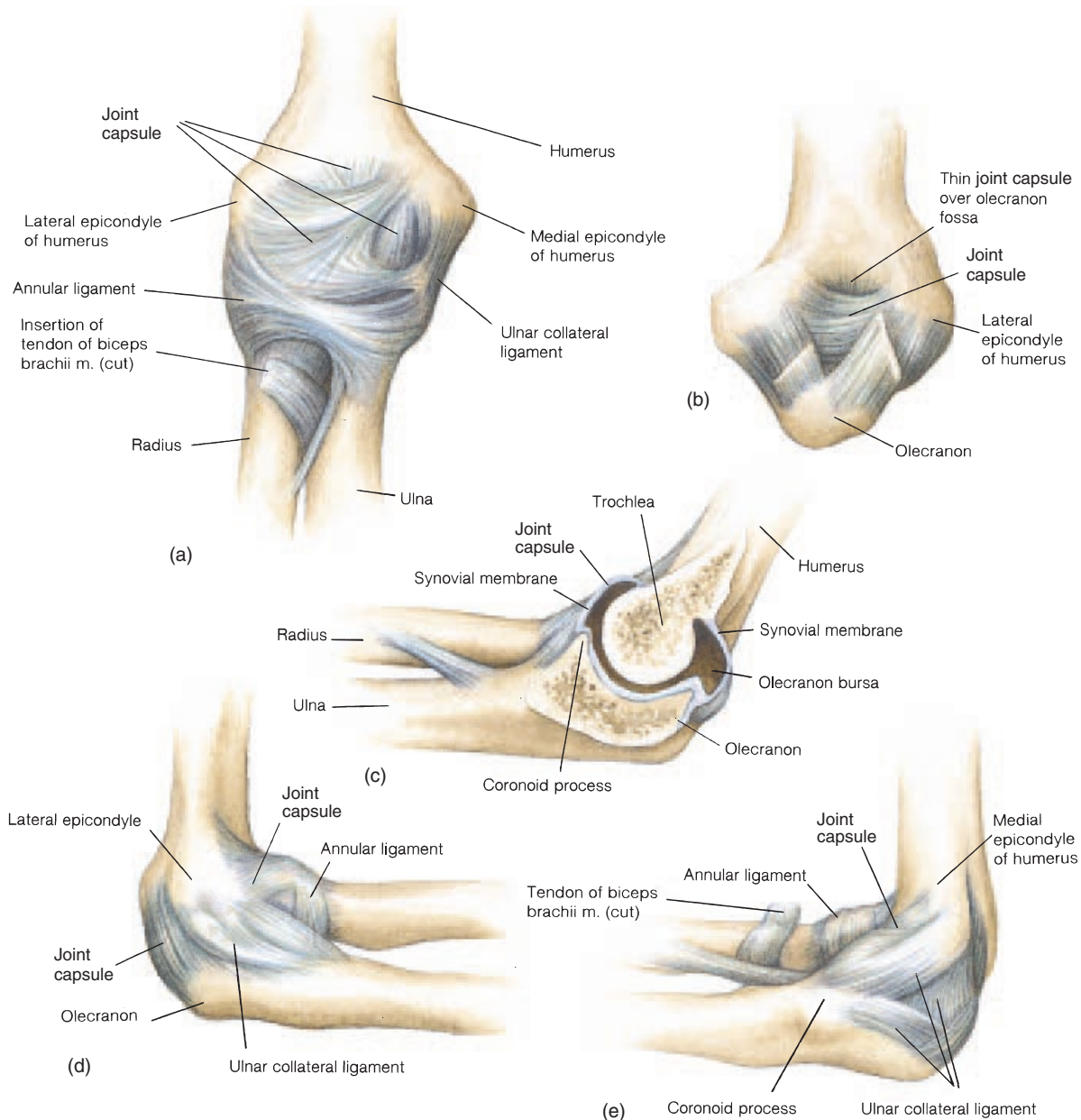
The shoulder joint is vulnerable to dislocations from sudden jerks of the arm, especially in children before strong shoulder muscles have developed. Because of the weakness of this joint in children, parents should be careful not to force a child to follow by yanking on the arm. Dislocation of the shoulder is extremely painful and may cause permanent damage or perhaps muscle atrophy as a result of disuse.

## Elbow Joint

The **elbow joint** is a hinge joint composed of two articulations—the **humeroulnar joint**, formed by the trochlea of the humerus and the trochlear notch of the ulna, and the **humeroradial joint**, formed by the capitulum of the humerus and the head of the radius (figs. 8.27 and 8.28). Both of these articulations are enclosed in a single joint capsule. On the posterior side of the elbow, there is a large **olecranon bursa** to lubricate the area. A **radial (lateral) collateral ligament** reinforces the elbow joint on the lateral side and an **ulnar (medial) collateral ligament** strengthens the medial side.

A third joint occurs in the elbow region—the **proximal radioulnar joint**—but it is not part of the hinge. At this joint, the head of the radius fits into the radial notch of the ulna and is held in place by the **annular ligament**.

Because so many muscles originate or insert near the elbow, it is a common site of localized tenderness, inflammation, and pain. **Tennis elbow** is a general term for musculotendinous soreness in this area. The structures most generally strained are the tendons attached to the lateral epicondyle of the humerus. The strain is caused by repeated extension of the wrist against some force, as occurs during the backhand stroke in tennis.




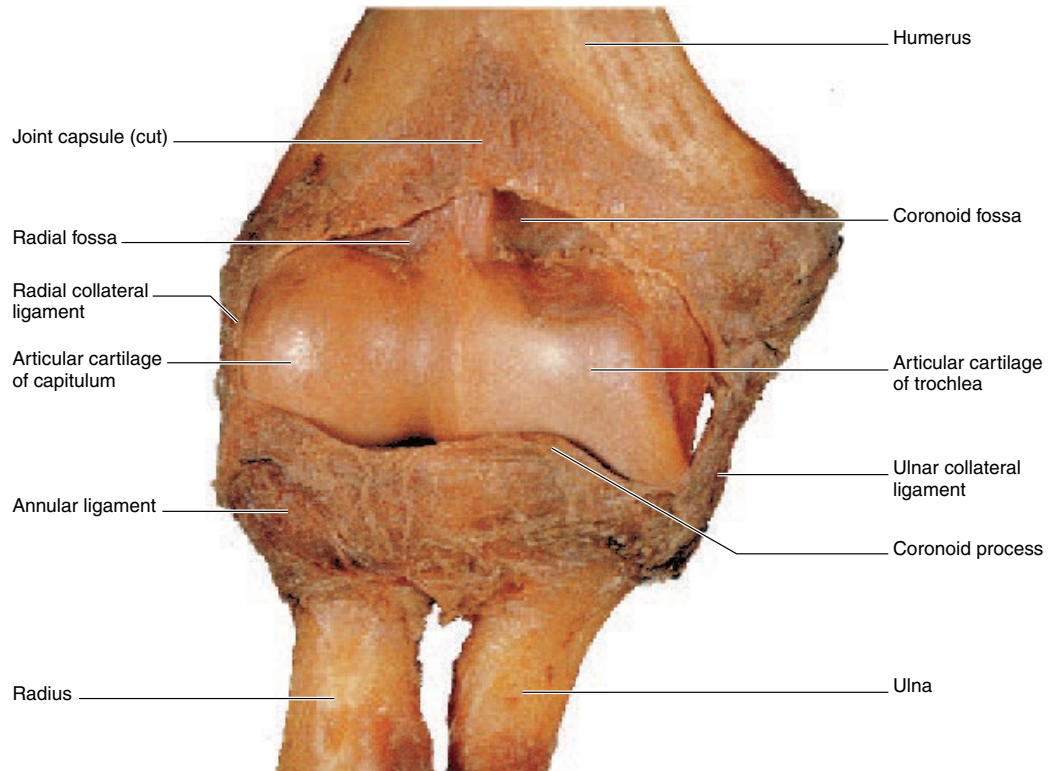
**FIGURE 8.27** The right elbow region. (a) An anterior view, (b) a posterior view, (c) a sagittal view, (d) a lateral view, and (e) a medial view.

## Metacarpophalangeal and Interphalangeal Joints

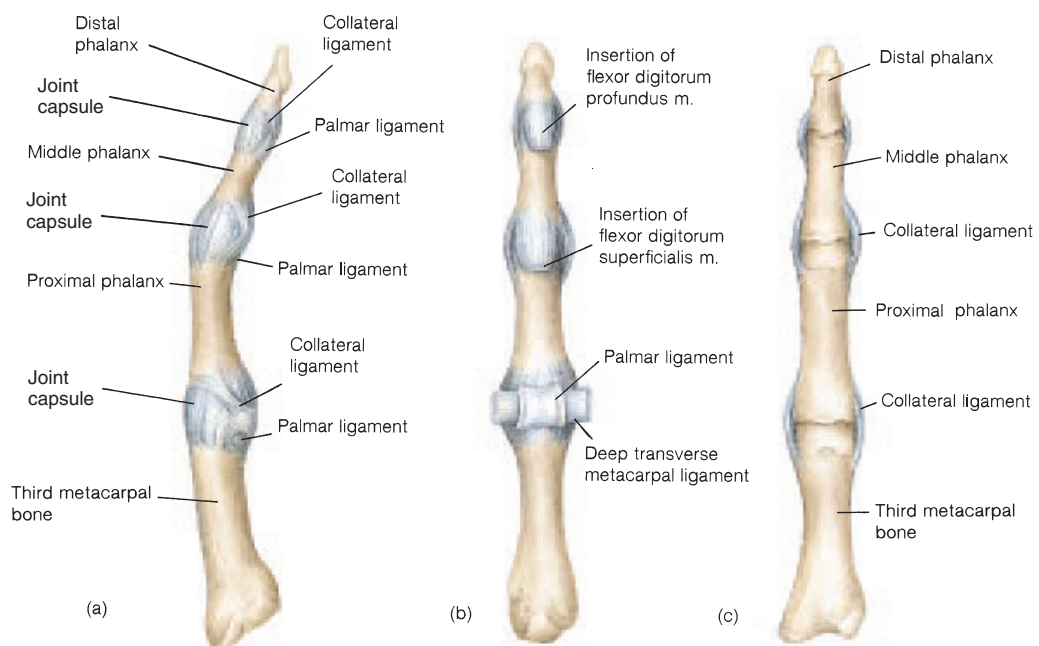
The **metacarpophalangeal joints** are condyloid joints, and the **interphalangeal joints** are hinge joints. The articulating bones of the former are the metacarpal bones and the proximal phalanges; those of the latter are adjacent phalanges (fig. 8.29). Each joint in both joint types has three ligaments. A **palmar ligament** spans each joint on the palmar, or anterior, side of the joint capsule.

Each joint also has two **collateral ligaments**, one on the lateral side and one on the medial side, to further reinforce the joint capsule. There are no supporting ligaments on the posterior side.

 Athletes frequently jam a finger. It occurs when a ball forcefully strikes a distal phalanx as the fingers are extended, causing a sharp flexion at the joint between the middle and distal phalanges. No ligaments support the joint on the posterior side, but there is a tendon from the digital extensor muscles of the forearm. It is this tendon that is damaged when the finger is jammed. Treatment involves splinting the finger for a period of time. If splinting is not effective, surgery is generally performed to avoid a permanent crook in the finger.

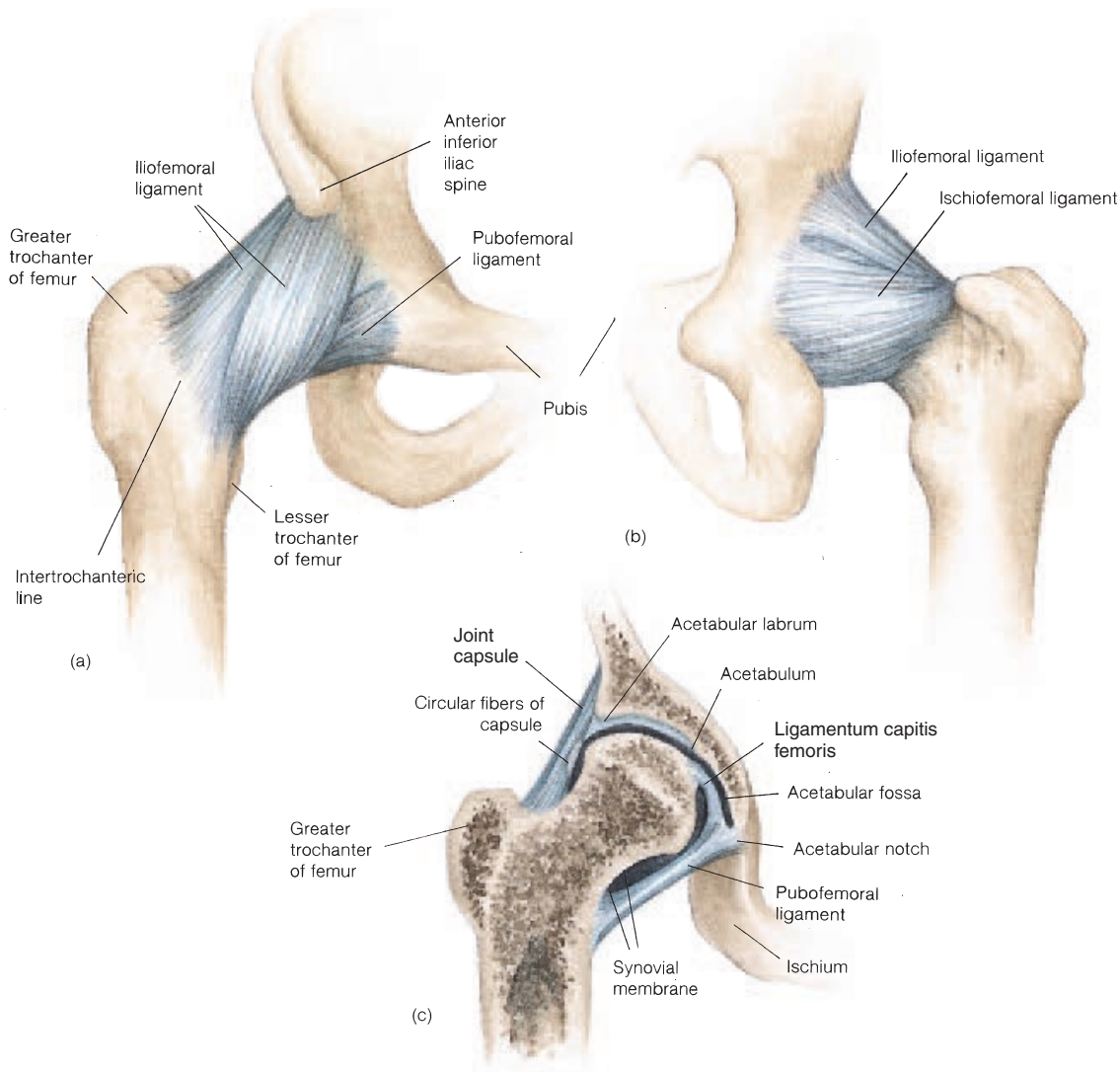


**FIGURE 8.28** A posterior view of a dissected elbow joint. A portion of the joint capsule has been removed to show the articular surface of the humerus.



**FIGURE 8.29** Metacarpophalangeal and interphalangeal joints. (a) A lateral view, (b) an anterior (palmar) view, and (c) a posterior view.





**FIGURE 8.30** The right coxal (hip) joint. (a) An anterior view, (b) a posterior view, and (c) a coronal view.

## Coxal (Hip) Joint

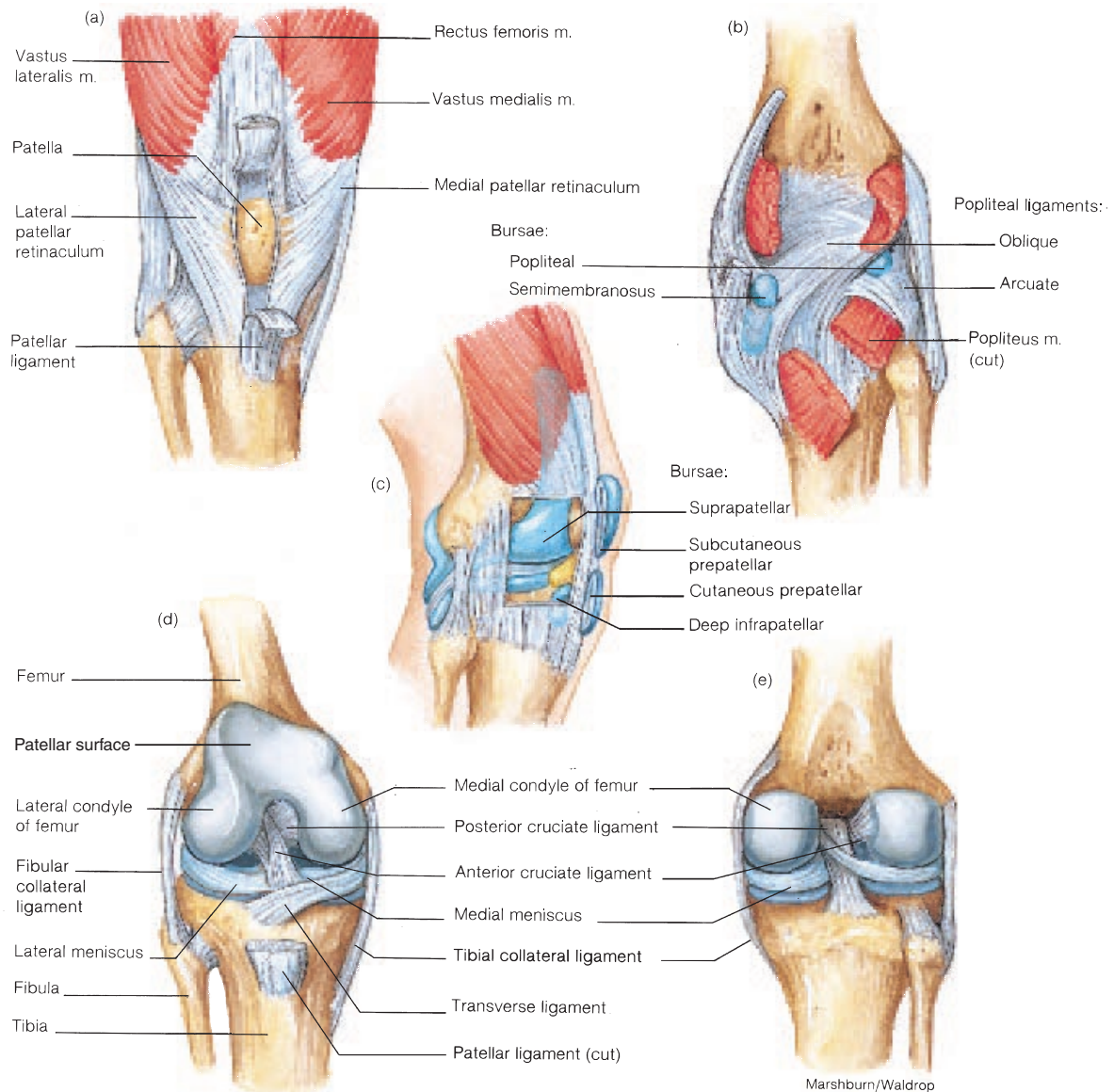
The ball-and-socket **hip joint** is formed by the head of the femur and the acetabulum of the os coxae (fig. 8.30). It bears the weight of the body and is therefore much stronger and more stable than the shoulder joint. The hip joint is secured by a strong fibrous joint capsule, several ligaments, and a number of powerful muscles.

The primary ligaments of the hip joint are the anterior **iliofemoral** (*il'e-o-fem'or-al*) and **pubofemoral** ligaments and the posterior **ischiofemoral** (*is'ke-o-fem'or-al*) ligament. The **ligamentum capitis femoris** is located within the articular capsule and attaches the head of the femur to the acetabulum. This is a relatively slack ligament, and does not play a significant role in holding the femur in its socket. However, it does contain a small artery that supplies blood to the head of the femur. The **trans-**

**verse acetabular** (*as''ē-tab'yū-lar*) **ligament** crosses the acetabular notch and connects to the joint capsule and the ligamentum capitis femoris. The **acetabular labrum**, a fibrocartilaginous rim that rings the head of the femur as it articulates with the acetabulum, is attached to the margin of the acetabulum.

## Tibiofemoral (Knee) Joint

The **knee joint**, located between the femur and tibia, is the largest, most complex, and probably the most vulnerable joint in the body. It is a complex hinge joint that permits limited rolling and gliding movements in addition to flexion and extension. On the anterior side, the knee joint is stabilized and protected by the patella and the **patellar ligament**, forming a gliding **patellofemoral joint**.



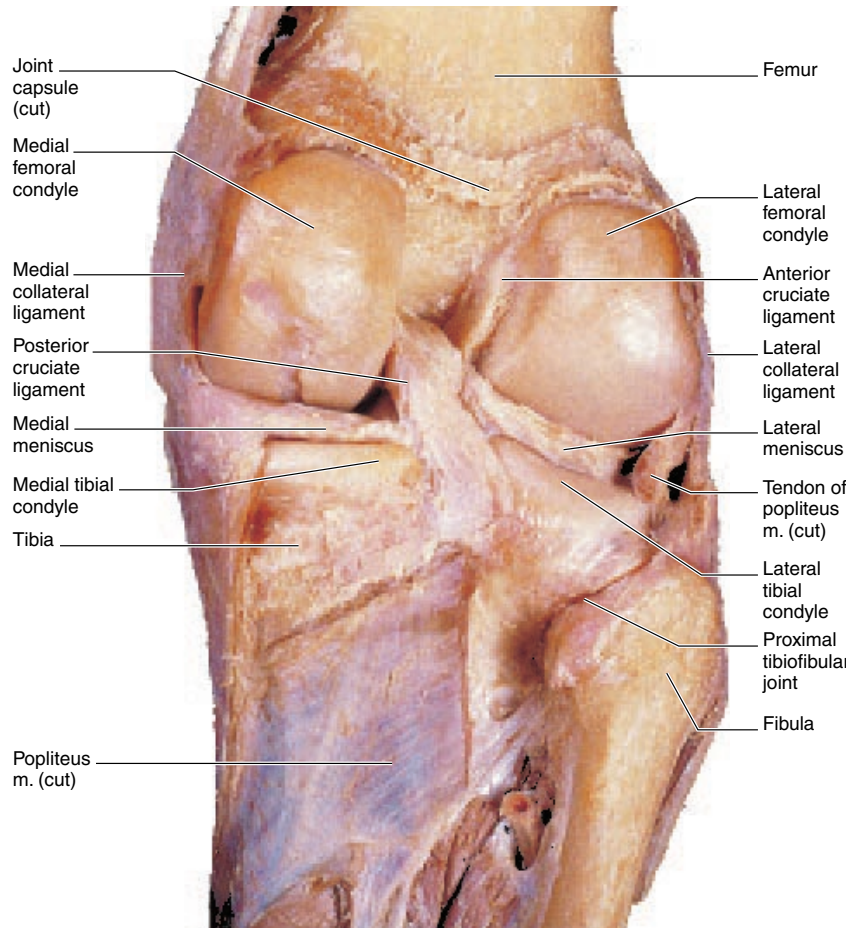
**FIGURE 8.31** The right tibiofemoral (knee) joint. (a) An anterior view, (b) a superficial posterior view, (c) a lateral view showing the bursae, (d) an anterior view with the knee slightly flexed and the patella removed, and (e) a deep posterior view.

Because of the complexity of the knee joint, only the relative positions of the ligaments, menisci, and bursae will be covered here. Although the attachments will not be discussed in detail, the locations of these structures can be seen in figures 8.31 and 8.32.

In addition to the patella and the patellar ligament on the anterior surface, the tendinous insertion of the quadriceps femoris muscle forms two supportive bands called the **lateral** and **medial patellar retinacula** (*ret''ī-nak-yŭ-lă*). Four bursae are associated with the anterior aspect of the knee: the **subcutaneous**

**prepatellar bursa**, the **suprapatellar bursa**, the **cutaneous prepatellar bursa**, and the **deep infrapatellar bursa** (see fig. 8.31c).

The posterior aspect of the knee is referred to as the **popliteal** (*pop''lŭ-te'al*) **fossa**. The broad **oblique popliteal ligament** and the **arcuate** (*ar''kyoo-ăt*) **popliteal ligament** are superficial in position, whereas the **anterior** and **posterior cruciate** (*kroo'she-ăt*) **ligaments** lie deep within the joint. The



**FIGURE 8.32** A posterior view of a dissected tibiofemoral joint. The joint capsule has been removed to expose the cruciate ligaments and the menisci.

**popliteal bursa** and the **semimembranosus bursa** are the two bursae associated with the back of the knee.

Strong **collateral ligaments** support both the medial and lateral sides of the knee joint. Two fibrocartilaginous discs called the **lateral** and **medial menisci** are located within the knee joint interposed between the distal femoral and proximal tibial condyles. The two menisci are connected by a **transverse ligament**. In addition to the four bursae on the anterior side and the two on the posterior side, there are 7 bursae on the lateral and medial sides, for a total of 13.

During normal walking and running, and in the support of the body, the knee joint functions superbly. It can tolerate considerable stress without tissue damage. However, the knee lacks bony support to withstand sudden forceful stresses, which frequently occur in athletic competition. Knee injuries often require surgery, and they heal with difficulty because of the avascularity of the cartilaginous tissue. Knowledge of the anatomy of the knee provides insight as to its limitations. The three C's—the anterior cruciate ligament, the collateral ligaments, and the cartilage—are the most likely sites of crippling injury.

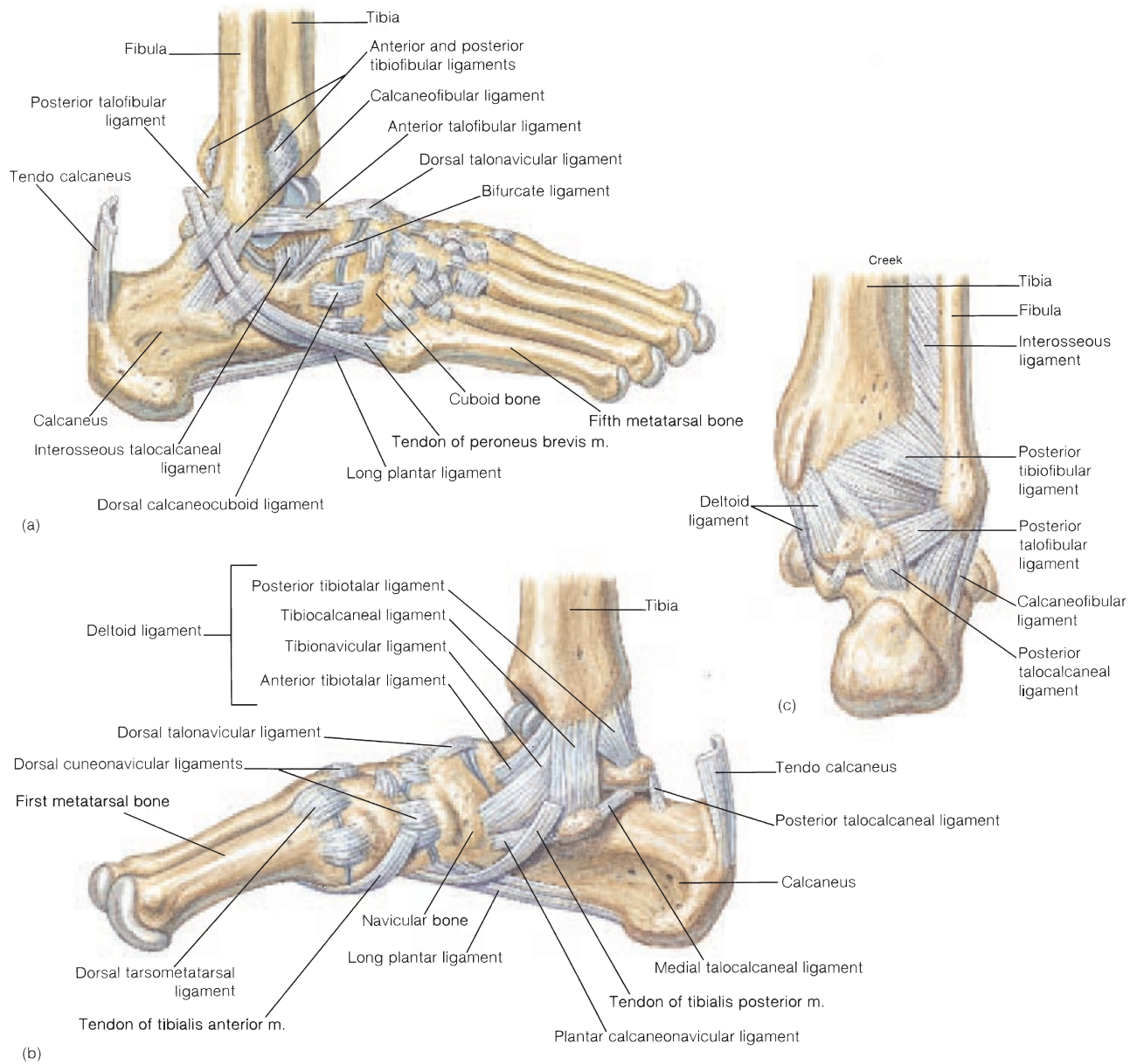
## Talocrural (Ankle) Joint

There are actually two principal articulations within the **ankle joint**, both of which are hinge joints (figs. 8.33 and 8.34). One is formed as the distal end of the tibia and its medial malleolus articulates with the talus; the other is formed as the lateral malleolus of the fibula articulates with the talus.

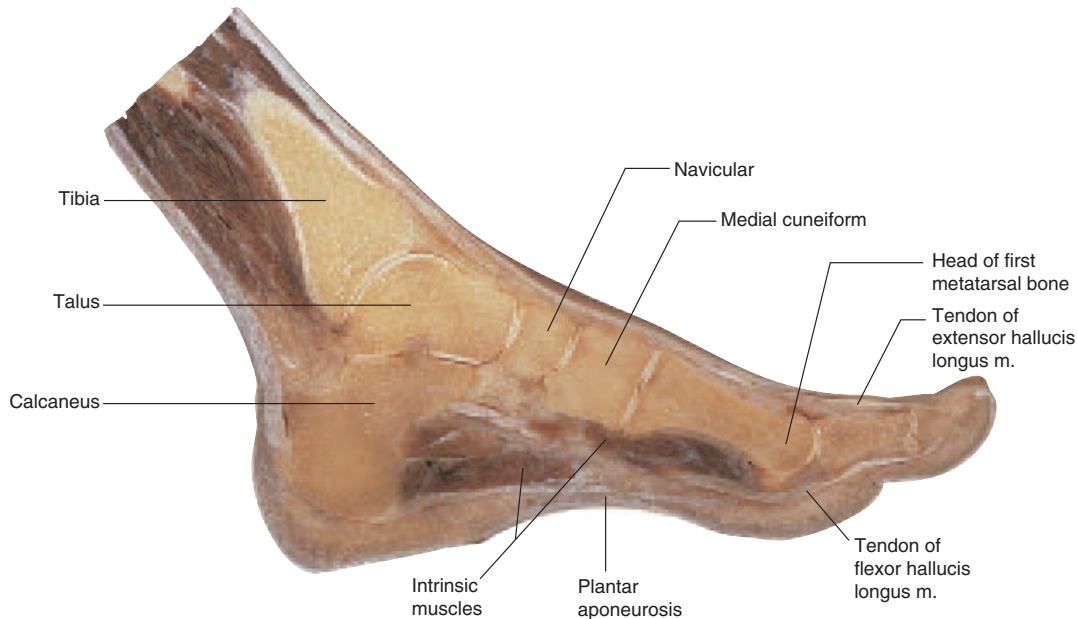
One joint capsule surrounds the articulations of the three bones, and four ligaments support the ankle joint on the outside of the capsule. The strong **deltoid ligament** is associated with the tibia, whereas the **lateral collateral ligaments**, **anterior talofibular** (*ta-lo-fib-yoo'lar*) **ligament**, **posterior talofibular** **ligament**, and **calcaneofibular** (*kal-ka''ne-o-fib'yoo-lar*) **ligament** are associated with the fibula.

The malleoli form a cap over the upper surface of the talus that prohibits side-to-side movement at the ankle joint. Unlike the condyloid joint at the wrist, the movements of the ankle are limited to flexion and extension. Dorsiflexion of the ankle is






**FIGURE 8.33** The right talocrural (ankle) joint. (a) A lateral view, (b) a medial view, and (c) a posterior view.



**FIGURE 8.34** A sagittal section of the foot from a cadaver.

checked primarily by the tendo calcaneus, whereas plantar flexion, or ankle extension, is checked by the tension of the extensor tendons on the front of the joint and the anterior portion of the joint capsule.

 *Ankle sprains* are a common type of locomotor injury. They vary widely in seriousness but tend to occur in certain locations. The most common cause of ankle sprain is excessive inversion of the foot, resulting in partial tearing of the anterior talofibular ligament and the calcaneofibular ligament. Less commonly, the deltoid ligament is injured by excessive eversion of the foot. Torn ligaments are extremely painful and are accompanied by immediate local swelling. Reducing the swelling and immobilizing the joint are about the only treatments for moderate sprains. Extreme sprains may require surgery and casting of the joint to facilitate healing.

A summary of the principal joints of the body and their movement is presented in table 8.2.

## ✓ Knowledge Check

14. What are the only joints that have menisci?
15. What two types of joints are found in the shoulder region? Why is the shoulder joint so vulnerable?

16. Which joints are reinforced with muscles that span the joint?
17. Describe the structure of the knee joint and indicate which structures protect and reinforce its anterior surface.

## CLINICAL CONSIDERATIONS

A synovial joint is a remarkable biologic system. Its self-lubricating action provides a shock-absorbing cushion between articulating bones and enables almost frictionless movement under tremendous loads and impacts. Under normal circumstances and in most people, the many joints of the body perform without problems throughout life. Joints are not indestructible, however, and are subject to various forms of trauma and disease. Although not all of the diseases of joints are fully understood, medical science has made remarkable progress in the treatment of arthrological problems.

**TABLE 8.2** Principal Articulations

Joint	Type	Movement
Most skull joints	Fibrous (suture)	Immovable
Temporomandibular	Synovial (hinge; gliding)	Elevation, depression; protraction, retraction
Atlanto-occipital	Synovial (condyloid)	Flexion, extension, circumduction
Atlantoaxial	Synovial (pivot)	Rotation
Intervertebral		
Bodies of vertebrae	Cartilaginous (symphysis)	Slight movement
Articular processes	Synovial (gliding)	Flexion, extension, slight rotation
Sacroiliac	Cartilaginous (gliding)	Slight gliding movement; may fuse in adults
Costovertebral	Synovial (gliding)	Slight movement during breathing
Sternocostal	Synovial (gliding)	Slight movement during breathing
Sternoclavicular	Synovial (gliding)	Slight movement when shrugging shoulders
Sternal	Cartilaginous (symphysis)	Slight movement during breathing
Acromioclavicular	Synovial (gliding)	Protraction, retraction; elevation, depression
Glenohumeral (shoulder)	Synovial (ball-and-socket)	Flexion, extension; adduction, abduction, rotation; circumduction
Elbow	Synovial (hinge)	Flexion, extension
Proximal radioulnar	Synovial (pivot)	Rotation
Distal radioulnar	Fibrous (syndesmosis)	Slight side-to-side movement
Radiocarpal (wrist)	Synovial (condyloid)	Flexion, extension; adduction, abduction; circumduction
Intercarpal	Synovial (gliding)	Slight movement
Carpometacarpal		
Fingers	Synovial (condyloid)	Flexion, extension; adduction, abduction
Thumb	Synovial (saddle)	Flexion, extension; adduction, abduction
Metacarpophalangeal	Synovial (condyloid)	Flexion, extension; adduction, abduction
Interphalangeal	Synovial (hinge)	Flexion, extension
Symphysis pubis	Fibrous (symphysis)	Slight movement
Coxal (hip)	Synovial (ball-and-socket)	Flexion, extension; adduction, abduction; rotation; circumduction
Tibiofemoral (knee)	Synovial (hinge)	Flexion, extension; slight rotation when flexed
Proximal tibiofibular	Synovial (gliding)	Slight movement
Distal tibiofibular	Fibrous (syndesmosis)	Slight movement
Talocrural (ankle)	Synovial (hinge)	Dorsiflexion, plantar flexion; slight circumduction; inversion, eversion
Intertarsal	Synovial (gliding)	Inversion, eversion
Tarsometatarsal	Synovial (gliding)	Flexion, extension; adduction, abduction

## Trauma to Joints

Joints are well adapted to withstand compression and tension forces. Torsion or sudden impact to the side of a joint, however, can be devastating. These types of injuries frequently occur in athletes.

In a **strained joint**, unusual or excessive exertion stretches the tendons or muscles surrounding a joint. The damage is not serious. Strains are frequently caused by not “warming up” the muscles and not “stretching” the joints prior to exercise. A **sprain** is a tearing of the ligaments or tendons surrounding a joint. There are various grades of sprains, and the severity

determines the treatment. Severe sprains damage articular cartilages and may require surgery. Sprains are usually accompanied by **synovitis**, an inflammation of the joint capsule.

**Luxation**, or **joint dislocation**, is a derangement of the articulating bones that compose the joint. Joint dislocation is more serious than a sprain and is usually accompanied by sprains. The shoulder and knee joints are the most vulnerable to dislocation.

luxation: L. *luxus*, out of place



## 226 Unit 4 Support and Movement

Self-healing of a dislocated joint may be incomplete, leaving the person with a “trick knee,” for example, that may unexpectedly give way.

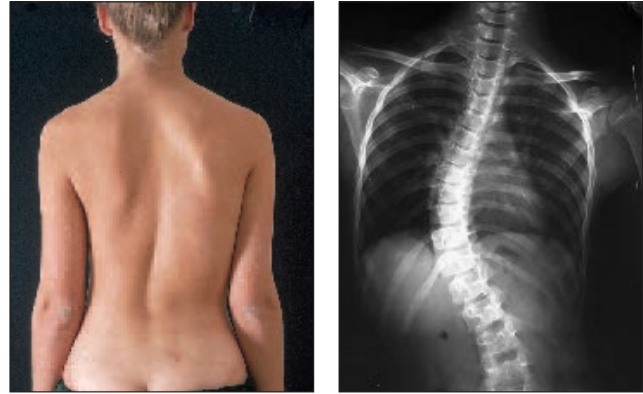
**Subluxation** is partial dislocation of a joint. Subluxation of the hip joint is a common type of birth defect that can be treated by bracing or casting to promote suitable bone development.

**Bursitis** (*bur-si'tis*) is an inflammation of the bursa associated with a joint. Because the bursa is close to the joint, the joint capsule may be affected as well. Bursitis may be caused by excessive stress on the bursa from overexertion, or it may be a local or systemic inflammatory process. As the bursa swells, the surrounding muscles become sore and stiff. **Tendonitis** involves inflammation of a tendon; it usually comes about in the same way as bursitis.

The flexible vertebral column is a marvel of mechanical engineering. Not only do the individual vertebrae articulate one with another, but together they form the portion of the axial skeleton with which the head, ribs, and ossa coxae articulate. The vertebral column also encloses the spinal cord and provides exits for 31 pairs of spinal nerves. Considering all the articulations in the vertebral column and the physical abuse it takes, it is no wonder that back ailments are second only to headaches as the most common physical complaint. Our way of life causes many of the problems associated with the vertebral column. Improper shoes, athletic exertion, sudden stops in vehicles, or improper lifting can all cause the back to go awry. Body weight, age, and general physical condition influence a person's susceptibility to back problems.

The most common cause of back pain is *strained muscles*, generally as a result of overexertion. The second most frequent back ailment is a *herniated disc*. The dislodged nucleus pulposus of a disc may push against a spinal nerve and cause excruciating pain. The third most frequent back problem is a *dislocated articular facet* between two vertebrae, caused by sudden twisting of the vertebral column. The treatment of back ailments varies from bed rest to spinal manipulation to extensive surgery.

Curvature disorders are another problem of the vertebral column. **Kyphosis** (*ki-fo'sis*) (hunchback) is an exaggeration of the thoracic curve. **Lordosis** (swayback) is an abnormal anterior convexity of the lumbar curve. **Scoliosis** (*sko-le-o'-sis*) (crookedness) is an abnormal lateral curvature of the vertebral column (fig. 8.35). It may be caused by abnormal vertebral structure, unequal length of the legs, or uneven muscular development on the two sides of the vertebral column.



(a)

(b)

**FIGURE 8.35** Scoliosis is a lateral curvature of the spine, usually in the thoracic region. It may be congenital, disease-related, or idiopathic (of unknown cause). (a) A posterior view of a 19-year-old woman and (b) a radiograph.

## Diseases of Joints

**Arthritis** is a generalized designation for over 50 different joint diseases (fig. 8.36), all of which have the symptoms of edema, inflammation, and pain. The causes are unknown, but certain types follow joint trauma or bacterial infection. Some types are genetic and others result from hormonal or metabolic disorders. The most common forms are *rheumatoid arthritis*, *osteoarthritis*, and *gouty arthritis*.

**Rheumatoid** (*roo'mă-toid*) **arthritis** results from an autoimmune attack against the joint tissues. The synovial membrane thickens and becomes tender, and synovial fluid accumulates. This is generally followed by deterioration of the articular cartilage, which eventually exposes bone tissue. When bone tissue is unprotected, joint ossification produces the crippling effect of this disease. Females are affected more often than males, and the disease usually begins between the ages of 30 and 50. Rheumatoid arthritis tends to occur bilaterally. If the right wrist or hip develops the disease, so does the left.

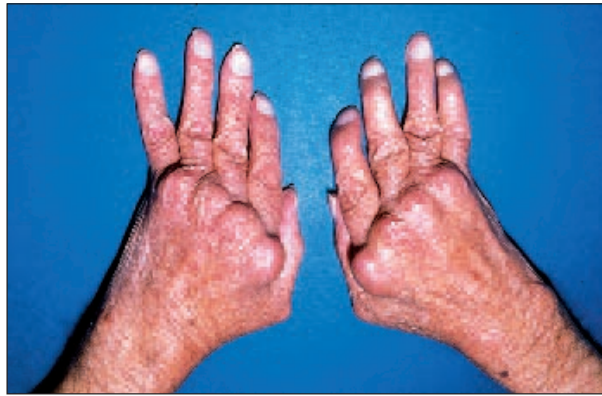**Osteoarthritis** is a degenerative joint disease that results from aging and irritation of the joints. Although osteoarthritis is far more common than rheumatoid arthritis, it is usually less

kyphosis: Gk. *kyphos*, hunched

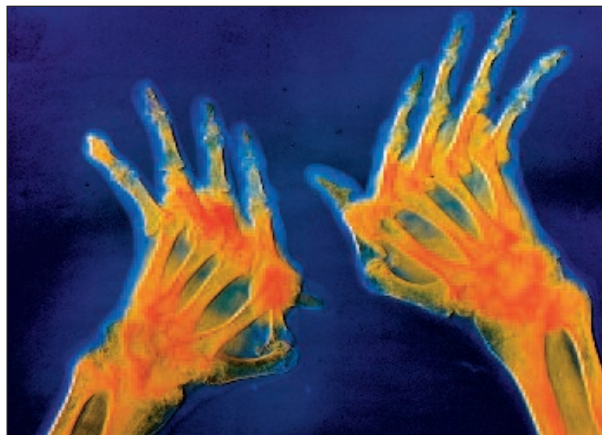
lordosis: Gk. *lordos*, curving forward

scoliosis: Gk. *skoliosis*, crookedness

rheumatoid: Gk. *rheuma*, a flowing



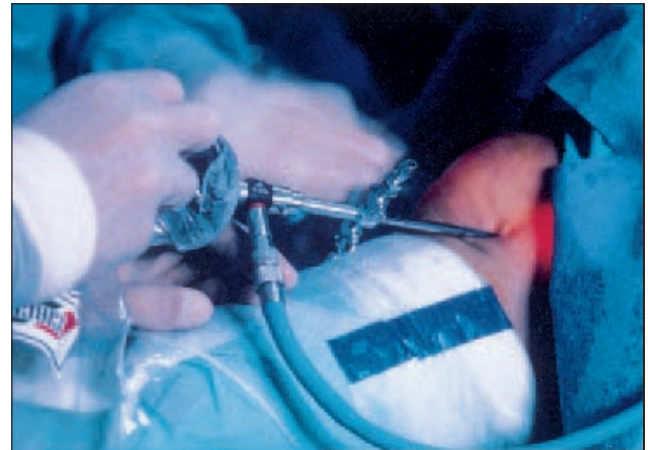
(a)



(b)

**FIGURE 8.36** Rheumatoid arthritis may eventually cause joint ossification and debilitation as seen in (a) a photograph of a patient's hands and (b) a radiograph.

damaging. Osteoarthritis is a progressive disease in which the articular cartilages gradually soften and disintegrate. The affected joints seldom swell, and the synovial membrane is rarely damaged. As the articular cartilage deteriorates, ossified spurs are deposited on the exposed bone, causing pain and restricting the movement of articulating bones. Osteoarthritis most frequently affects the knee, hip, and intervertebral joints.



**FIGURE 8.37** Arthroscopy. In this technique, a needlelike viewing arthroscope is threaded into the joint capsule through a tiny incision. The arthroscope has a fiberoptic light source that illuminates the interior of the joint. Thus, the position of the surgical instruments that may be inserted through other small incisions can be seen.

**Gouty arthritis** results from a metabolic disorder in which an abnormal amount of uric acid is retained in the blood and sodium urate crystals are deposited in the joints. The salt crystals irritate the articular cartilage and synovial membrane, causing swelling, tissue deterioration, and pain. If gout is not treated, the affected joint fuses. Males have a greater incidence of gout than females, and apparently the disease is genetically determined. About 85% of gout cases affect the joints of the foot and legs. The most common joint affected is the metatarsophalangeal joint of the hallux (great toe).

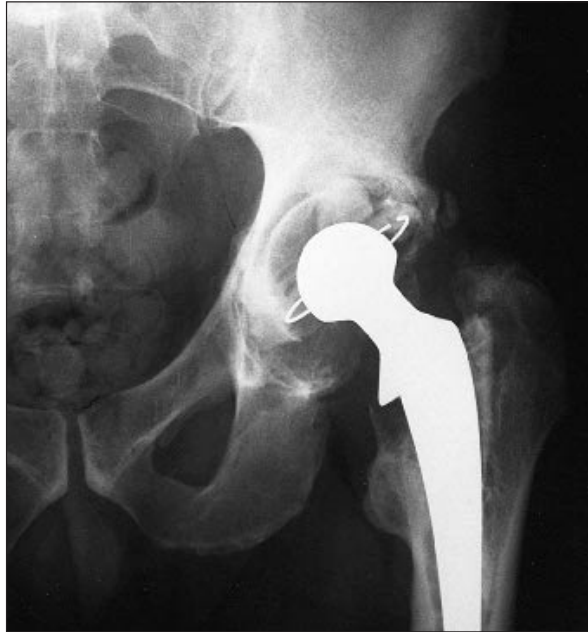## Treatment of Joint Disorders

**Arthroscopy** (*ar-thros'kō-pe*) is widely used in diagnosing and, to a limited extent, treating joint disorders (fig. 8.37). Arthroscopic inspection involves making a small incision into the joint capsule and inserting a tubelike instrument called an *arthroscope*. In arthroscopy of the knee, the articular cartilage, synovial

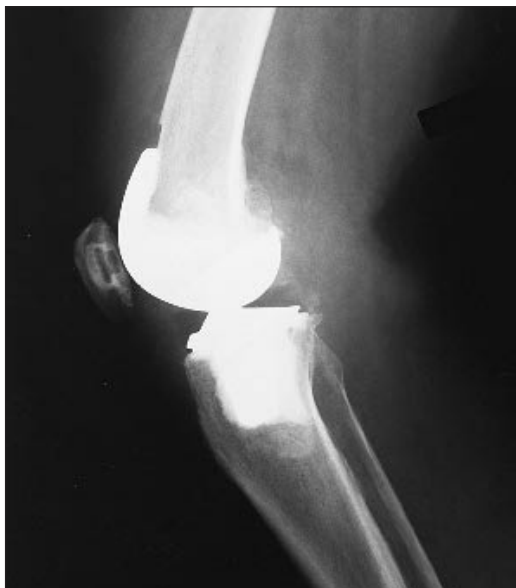gout: L. *gutta*, a drop (thought to be caused by "drops of viscous humors")



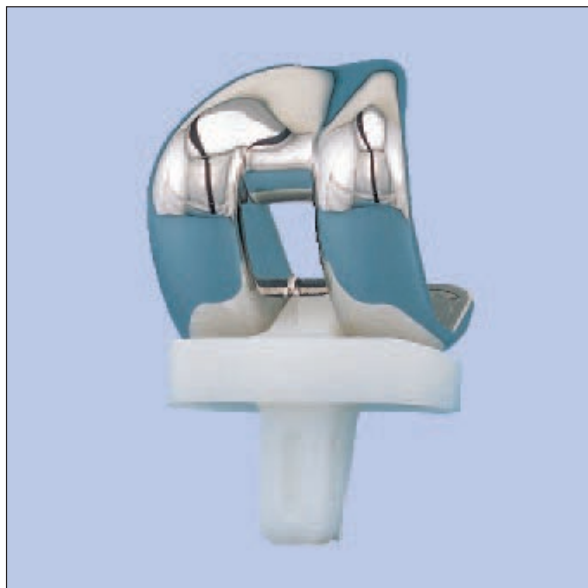(a)



(b)



(c)



(d)

**FIGURE 8.38** Two examples of joint prostheses. (a, b) The coxal (hip) joint and (c, d) the tibiofemoral (knee) joint.



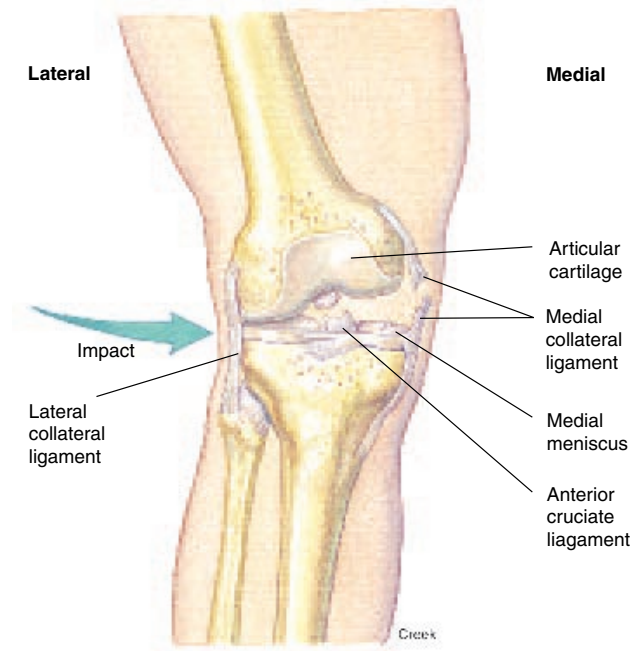
membrane, menisci, and cruciate ligaments can be observed. Samples can be extracted, and pictures taken for further evaluation.

Remarkable advancements have been made in the last 15 years in the development of **joint prostheses** (*pros-the'sēz*) (fig. 8.38). These artificial articulations do not take the place of normal, healthy joints, but they are a valuable option for chronically disabled arthritis patients. They are now available for finger, shoulder, and elbow joints, as well as for hip and knee joints.

## Clinical Case Study Answer

The way in which the knee was injured and the location of the pain, taken together with the exam findings, indicate a complete or near-complete tear of the medial collateral ligament. Because the medial meniscus is attached to this ligament, it is frequently torn as well in an injury of this sort. Other ligaments susceptible to athletic injury are the anterior cruciate ligament (most common) and the lateral collateral and posterior cruciate ligaments (fig. 8.39). Complete tears of these ligaments usually require surgical repair for acceptable results. Incomplete tears can often be managed by nonsurgical means.

prosthesis: Gk. *pros*, in addition to; *thesis*, a setting down



**FIGURE 8.39** A lateral blow to the knee frequently causes trauma to structures located on the medial side.

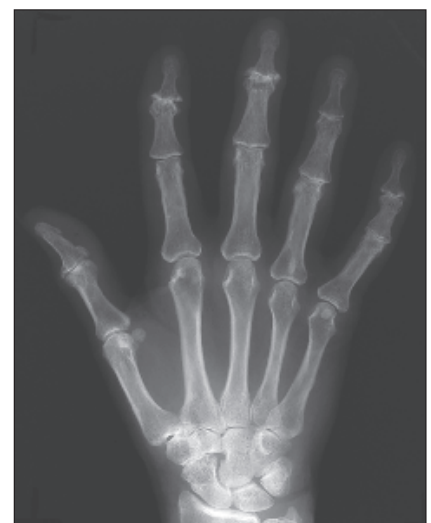## CLINICAL PRACTICUM 8.1

An 81-year-old female presents at your clinic complaining of pain in the joints of her fingers. She reports the pain is worse when she tries to move her fingers or hold something heavy. On further questioning, she tells you that her fingers are stiff when she gets up in the morning, but that this resolves quickly once she starts to move around. She also relates that this problem has been slowly worsening over many years. Upon physical exam, you note decreased range of motion as well as the sensation of bone rubbing against bone on

passive movement of the distal interphalangeal joints. There is swelling of several of the distal and proximal interphalangeal joints, and they are warm to the touch. You order a radiograph to further evaluate the joints.

### QUESTIONS

1. What abnormalities are present in the radiograph?
2. What is your diagnosis?
3. What other joints might be involved?



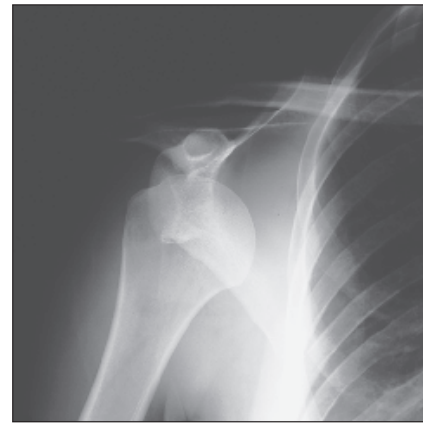## CLINICAL PRACTICUM 8.2

A 21-year-old male presents at the emergency room complaining of pain in his right shoulder and arm. While playing basketball, he had fallen and tried to catch himself with his right hand. The patient reports the pain began immediately and is worse upon movement. Physical examination reveals a limited range of motion and a

deformity of the right shoulder. You order a radiograph.

### QUESTIONS

1. What is the diagnosis?
2. What is the treatment?
3. What complications can result from this injury?



## Important Clinical Terminology

**ankylosis** (*ang''ki-lo'sis*) Stiffening of a joint, resulting in severe or complete loss of movement.

**arthralgia** (*ar-thral'je-ä*) Severe pain in a joint.

**arthrolith** (*ar'thro-lith*) A gouty deposit in a joint, also called *arthrdynia*.

**arthrometry** (*ar-throm'ē-tre*) Measurement of the range of movement in a joint.

**arthroncus** (*ar-thron'kus*) Swelling of a joint as a result of trauma or disease.

**arthropathy** (*ar-throp'ä-the*) Any disease affecting a joint.

**arthroplasty** (*ar'thro-plas'te*) Surgical repair of a joint.

**arthrosis** (*ar-thro'sis*) A joint or an articulation; also, a degenerative condition of a joint.

**arthrosteitis** (*ar'thros-te-i'tis*) Inflammation of the bony structure of a joint.

**chondritis** (*kon-dri'tis*) Inflammation of the articular cartilage of a joint.

**coxarthrosis** (*koks''ar-thro'sis*) A degenerative condition of the hip joint.

**hemarthrosis** (*hem-ar-thro'sis*) An accumulation of blood in a joint cavity.

**rheumatology** (*roo'mă-tol'ō-je*) The medical specialty concerned with the diagnosis and treatment of rheumatic diseases.

**spondylitis** (*spon-dil-i'tis*) Inflammation of one or more vertebrae.

**synovitis** (*sin'o-vi'tis*) Inflammation of the synovial membrane lining the inside of a joint capsule.

## Chapter Summary

### Classification of Joints (p. 197)

1. Joints are formed as adjacent bones articulate. Arthrology is the science concerned with the study of joints; kinesiology is the study of movements involving certain joints.
2. Joints are structurally classified as fibrous, cartilaginous, or synovial.
3. Joints are functionally classified as synarthroses, amphiarthroses, and diarthroses.

### Fibrous Joints (pp. 197–198)

1. Articulating bones in fibrous joints are tightly bound by fibrous connective tissue. Fibrous joints are of three types: sutures, syndesmoses, and gomphoses.
2. Sutures are found only in the skull; they are classified as serrate, lap, or plane.

3. Syndesmoses are found in the vertebral column between the articulating processes, the distal antebrachium between the radius and the ulna, and the distal leg between the tibia and the fibula. The articulating bones of syndesmoses are held together by interosseous ligaments, which permit slight movement.
4. Gomphoses are found only in the skull, where the teeth are bound into their sockets by the periodontal ligaments.

### Cartilaginous Joints (pp. 199–200)

1. The fibrocartilage or hyaline cartilage of cartilaginous joints allows limited motion in response to twisting or compression. The two types of cartilaginous joints are symphyses and synchondroses.

2. The symphysis pubis and the joints formed by the intervertebral discs are examples of symphyses.
3. Some synchondroses are temporary joints formed in the growth plates between the diaphyses and epiphyses in the long bones of children. Other synchondroses are permanent; for example, the joints between the ribs and the costal cartilages of the rib cage.

### Synovial Joints (pp. 200–205)

1. The freely movable synovial joints are enclosed by joint capsules that contain synovial fluid. Synovial joints include gliding, hinge, pivot, condyloid, saddle, and ball-and-socket types.

2. Synovial joints contain a joint cavity, articular cartilages, and synovial membranes that produce the synovial fluid. Some also contain articular discs, accessory ligaments, and associated bursae.
3. The movement of a synovial joint is determined by the structure of the articulating bones, the strength and tautness of associated ligaments and tendons, and the arrangement and tension of the muscles that act on the joint.

#### Movements at Synovial Joints (pp. 207–213)

1. Movements at synovial joints are produced by the contraction of the skeletal muscles that span the joints and attach to or near the bones forming the articulations. In these actions, the bones act as levers, the muscles provide the force, and the joints are the fulcrum, or pivots.
2. Angular movements increase or decrease the joint angle produced by the articulating bones. Flexion decreases the joint angle on an anterior-posterior plane; extension increases the same joint angle. Abduction is the movement of a body

part away from the main axis of the body; adduction is the movement of a body part toward the main axis of the body.

3. Circular movements can occur only where the rounded surface of one bone articulates with a corresponding depression on another bone. Rotation is the movement of a bone around its own axis. Circumduction is a conelike movement of a body part.
4. Special joint movements include inversion and eversion, protraction and retraction, and elevation and depression.
5. Synovial joints and their associated bones and muscles can be classified as first-, second-, or third-class levers. In a first-class lever, the fulcrum is positioned between the effort and the resistance. In a second-class lever, the resistance lies between the fulcrum and the effort. In a third-class lever, the effort is applied between the fulcrum and the resistance.

#### Specific Joints of the Body (pp. 214–224)

1. The temporomandibular joint, a combined hinge and gliding joint, is of clinical importance because of temporomandibular joint (TMJ) syndrome.

2. The glenohumeral (shoulder) joint, a ball-and-socket joint, is vulnerable to dislocations from sudden jerks of the arm, especially in children before strong shoulder muscles have developed.
3. There are two sets of articulations at the elbow joint as the distal end of the humerus articulates with the proximal ends of the ulna and radius. It is a hinge joint that is subject to strain during certain sports.
4. The metacarpophalangeal joints (knuckles) are condyloid joints, and the interphalangeal joints (between adjacent phalanges) are hinge joints.
5. The ball-and-socket coxal (hip) joint is adapted for weight-bearing. Its capsule is extremely strong and is reinforced by several ligaments.
6. The hinged tibiofemoral (knee) joint is the largest, most vulnerable joint in the body.
7. There are two hinged articulations within the talocrural (ankle) joint. Sprains are frequently associated with this joint.


## Review Activities

### Objective Questions

1. Which statement regarding joints is *false*?
  - (a) They are places where two or more bones articulate.
  - (b) All joints are movable.
  - (c) Arthrology is the study of joints; kinesiology is the study of the biomechanics of joint movement.
2. Synchondroses are a type of
  - (a) fibrous joint.
  - (b) synovial joint.
  - (c) cartilaginous joint.
3. An interosseous ligament is characteristic of
  - (a) a suture.
  - (b) a synchondrosis.
  - (c) a symphysis.
  - (d) a syndesmosis.
4. Which of the following joint type-function word pairs is *incorrect*?
  - (a) synchondrosis/growth at the epiphyseal plate
  - (b) symphysis/movement at the intervertebral joint between vertebral bodies
  - (c) suture/strength and stability in the skull
  - (d) syndesmosis/movement of the jaw
5. Which of the following is a *false* statement?
  - (a) Synchondroses occur in the long bones of children and young adults.
  - (b) Sutures occur only in the skull.
  - (c) Saddle joints occur in the thumb and in the neck, where rotational movement is possible.
  - (d) Syndesmoses occur in the antebrachium and leg.
6. Which of the following is *not* characteristic of all synovial joints?
  - (a) articular cartilage
  - (b) synovial fluid
  - (c) a joint capsule
  - (d) menisci
7. The atlantoaxial and the proximal radioulnar synovial joints are specifically classified as
  - (a) hinge.
  - (b) gliding.
  - (c) pivotal.
  - (d) condyloid.
8. Which of the following joints can be readily and comfortably hyperextended?
  - (a) an interphalangeal joint
  - (b) a coxal joint
  - (c) a tibiofemoral joint
  - (d) a sternocostal joint
9. Which of the following is most vulnerable to luxation?
  - (a) the elbow joint
  - (b) the glenohumeral joint
  - (c) the coxal joint
  - (d) the tibiofemoral joint
10. A thickening and tenderness of the synovial membrane and the accumulation of synovial fluid are signs of the development of
  - (a) arthroscleritis.
  - (b) gouty arthritis.
  - (c) osteoarthritis.
  - (d) rheumatoid arthritis.

### Essay Questions

1. What are the three structural classes of joints? Describe the characteristics of each.
2. Why is anatomical position so important in explaining the movements that are possible at joints?
3. What are the structural elements of a synovial joint that determine its range of movement?



**FIGURE 8.40** Which joints of the body are being flexed as this person assumes a fetal position?

- What are the advantages of a hinge joint over a ball-and-socket type? If ball-and-socket joints allow a greater range of movement, why aren't all the synovial joints of this type?
- What is synovial fluid? Where is it produced and what are its functions?
- Describe a bursa and discuss its function. What is bursitis?
- Identify four types of synovial joints found in the wrist and hand regions, and state the types of movement permitted by each.
- Discuss the articulations between the pectoral and pelvic regions and the axial skeleton with regard to range of movement, ligamentous attachments, and potential clinical problems.
- What is meant by a sprained ankle? How does a sprain differ from a strain or a luxation?
- What occurs within the joint capsule in rheumatoid arthritis? How does rheumatoid arthritis differ from osteoarthritis?

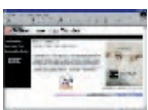### Critical-Thinking Questions

- Refer to figure 8.40 and identify the joints being flexed. In the upper and lower extremities of your own body, which are larger and stronger, the flexor muscles or the extensor muscles? Why?
- Considering the type of synovial joint at the hip and the location of the gluteal muscles of the buttock, explain why this type of lever system is adapted for rapid, wide-ranging movements.
- The star runningback of a local high school football team was taken to the emergency room of the local hospital following a knee injury during the championship game. The injury resulted from a hard blow ("clipping") to the back of his right knee as it was supporting the weight of his body. Suspecting a rupture of the anterior cruciate ligament, the ER physician informed the football player that this diagnosis could be confirmed by pulling the tibia forward as the knee was flexed. He explained that if the tibia

slipped forward at the knee ("bureau drawer sign"), it could be assumed that the anterior cruciate ligament was ruptured.

In terms of the anatomy of the knee joint, explain the occurrence of bureau drawer sign. What structure most likely would be traumatized if the tibia could be displaced backward?

- In what ways do the anatomical differences between the jaw, shoulder, elbow, hip, knee, and ankle joints relate to their differences in function?
- In chapter 6, you learned that the periosteum does not cover the articular cartilage. Review the functions of the periosteum and explain why it is not found in synovial joints.
- In anticipation of what you will learn about muscles in the following chapter, explain why each movement has an opposite movement. For example, extension is the opposite movement of flexion, and abduction is the opposite of adduction.



Visit our **Online Learning Center** at <http://www.mhhe.com/vdg> for chapter-by-chapter quizzing, additional study resources, and related web links.