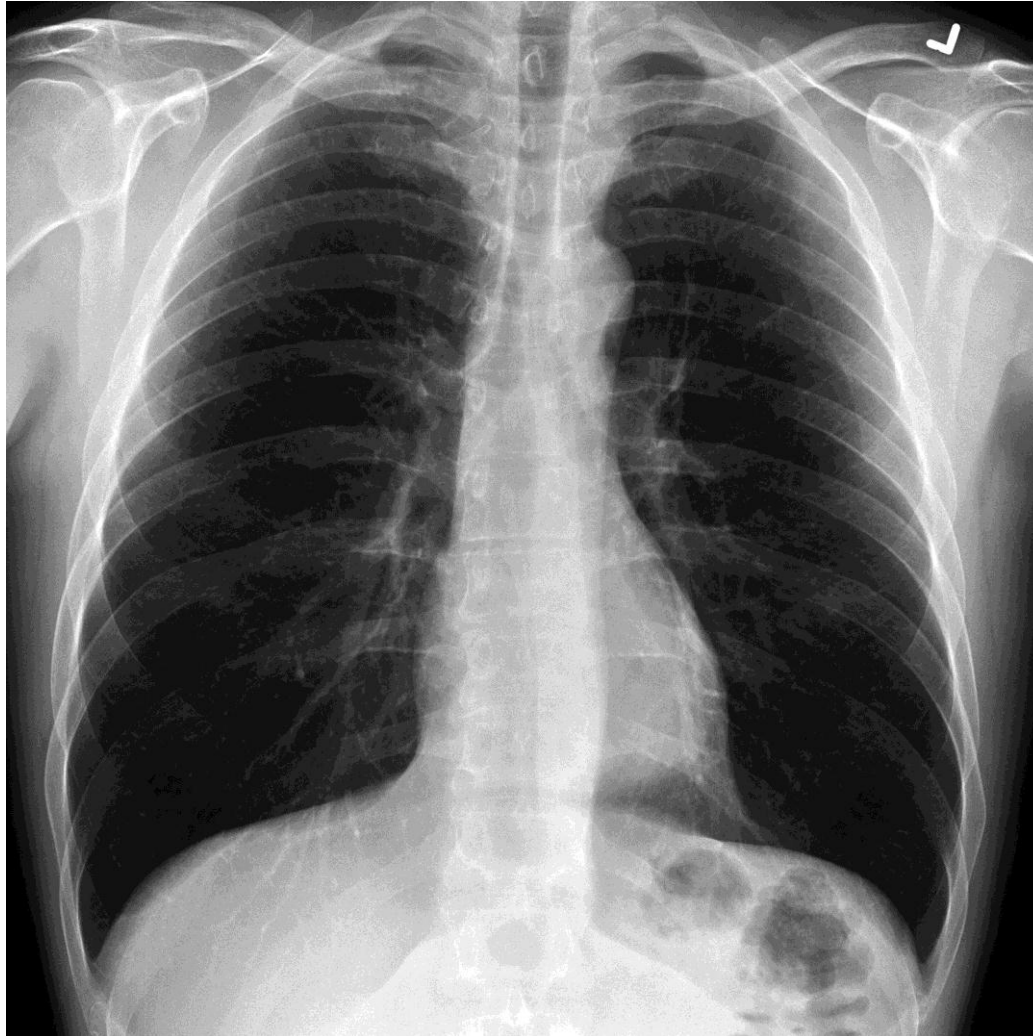


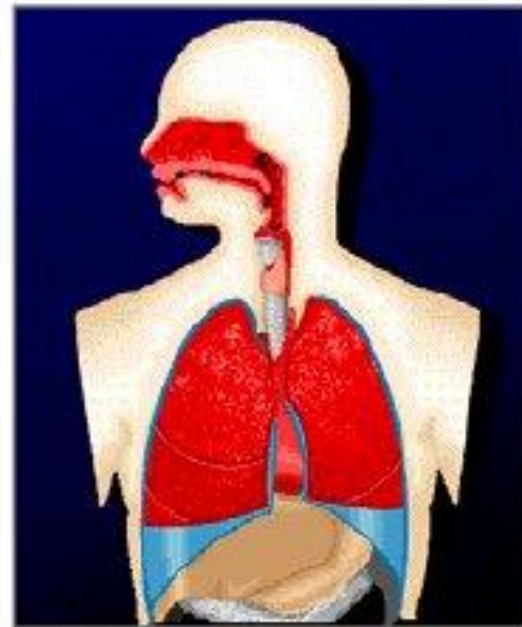
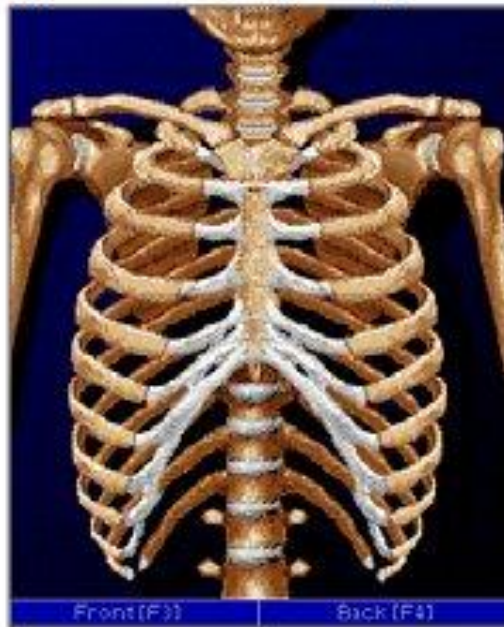# CHEST RADIOGRAPHY

---



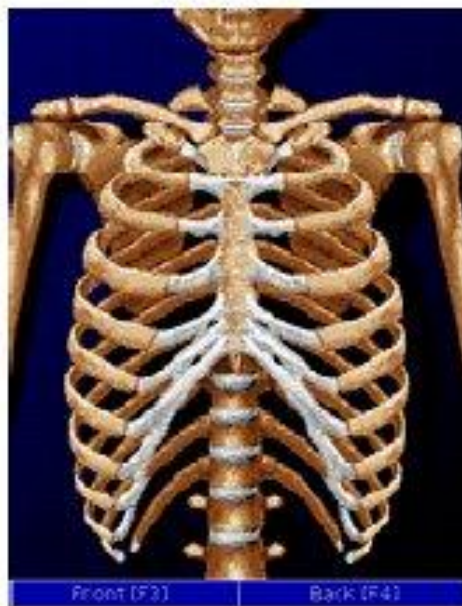# Chest Anatomy

- Thoracic cavity (chest)
  - Surrounded by boney thorax
  - Separated from abdomen by **diaphragm**
    - Muscular partition
    - Dome shaped
    - Lungs drape over diaphragm

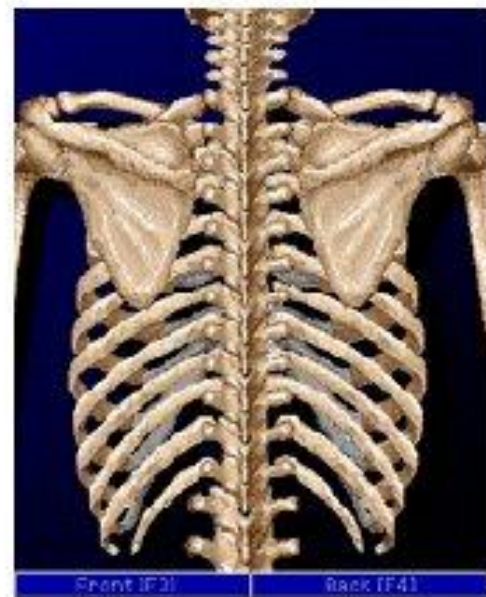

# Boney Thorax

- ENCLOSE THE ORGANS
  - STERNUM (breast bone)
  - 12 PAIR OF RIBS
  - 12 THORACIC VERTEBRA
- ATTACH UPPER EXTREMITY
  - 2 CLAVICLES
  - 2 SCAPULA



Anterior



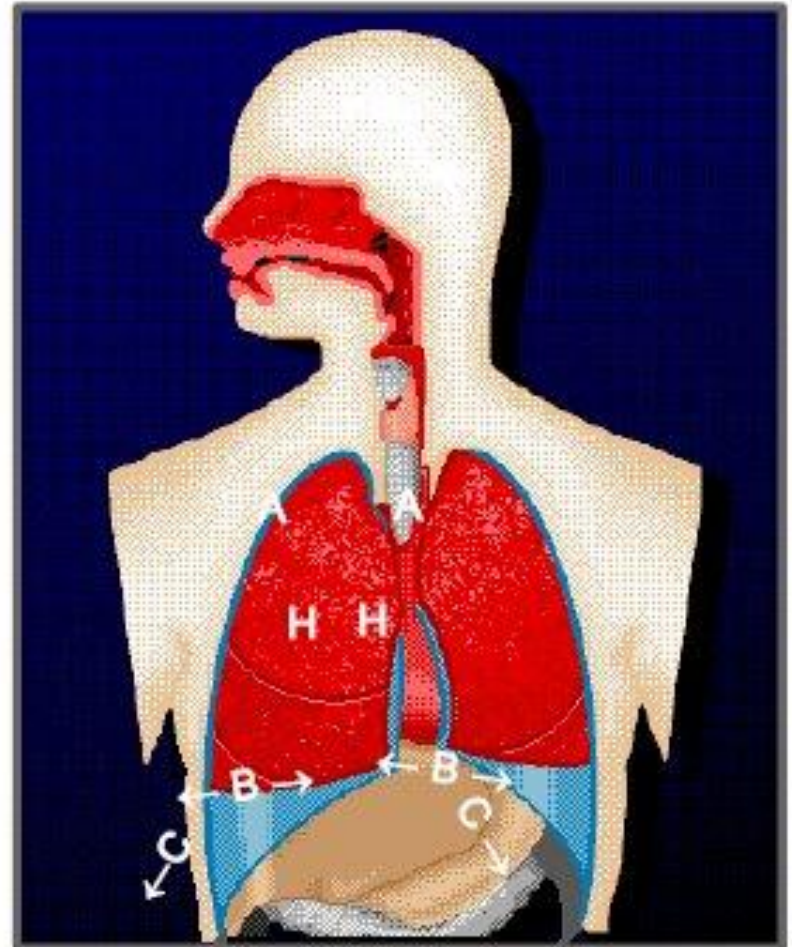
Posterior



# Respiratory System

## 1. Lungs

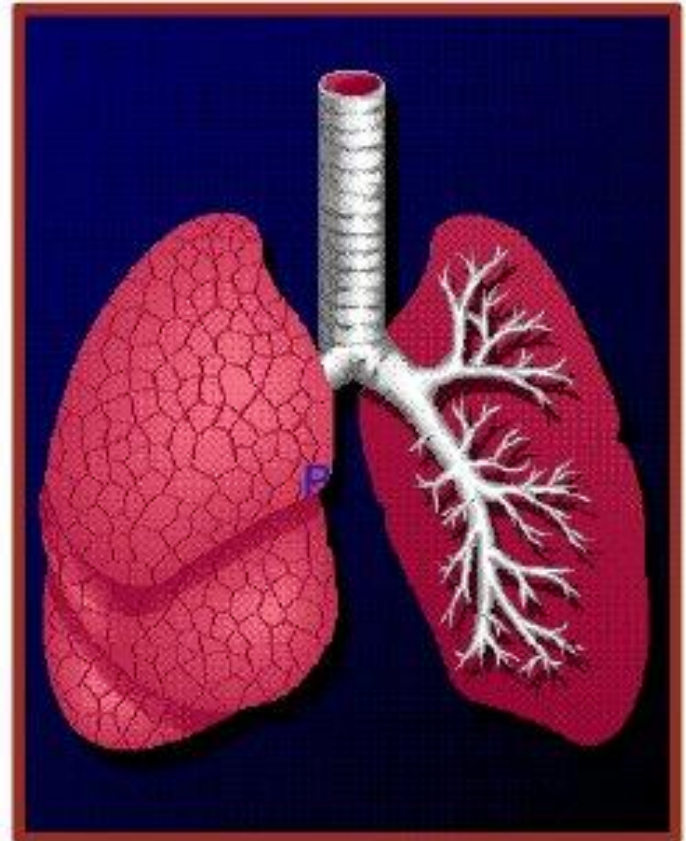
- Lobes
  - ☐ Right 3 lobes
  - ☐ Left 2 lobes
- Terminology
  - ☐ Apex
  - ☐ Hilum
  - ☐ Base
  - ☐ Costophrenic angles



# Bronchial Tree

## 2. Bronchi

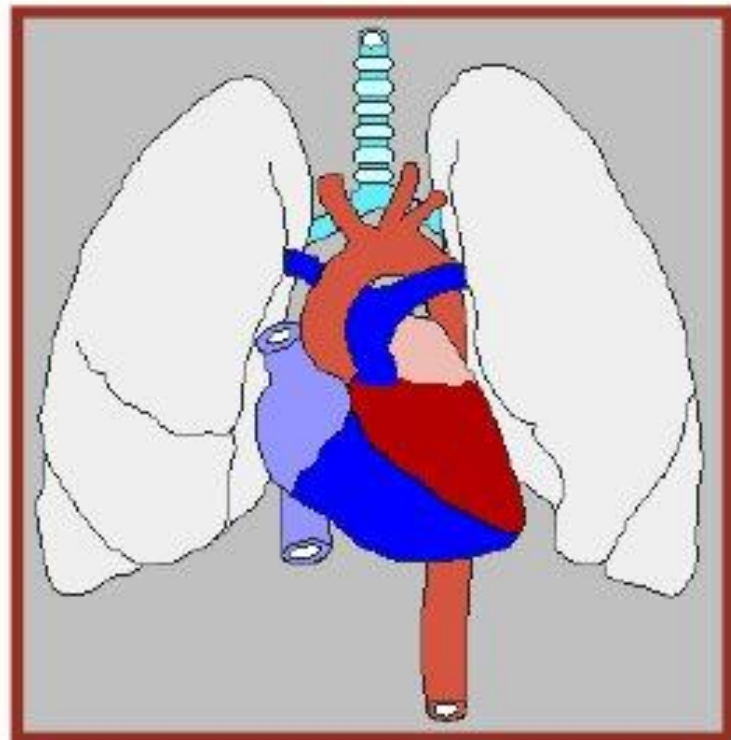
- Air tubes leading into the lung
- Right more vertical than left
- Branching structure
  - Primary → 2ndary →
- Only primary visible on PA projection



# Miscellaneous

- **Mediastinum contents**

- Trachea
- Major vessels
- Esophagus
- Lymphatic's
- Heart
- Thymus





# Technical Aspects

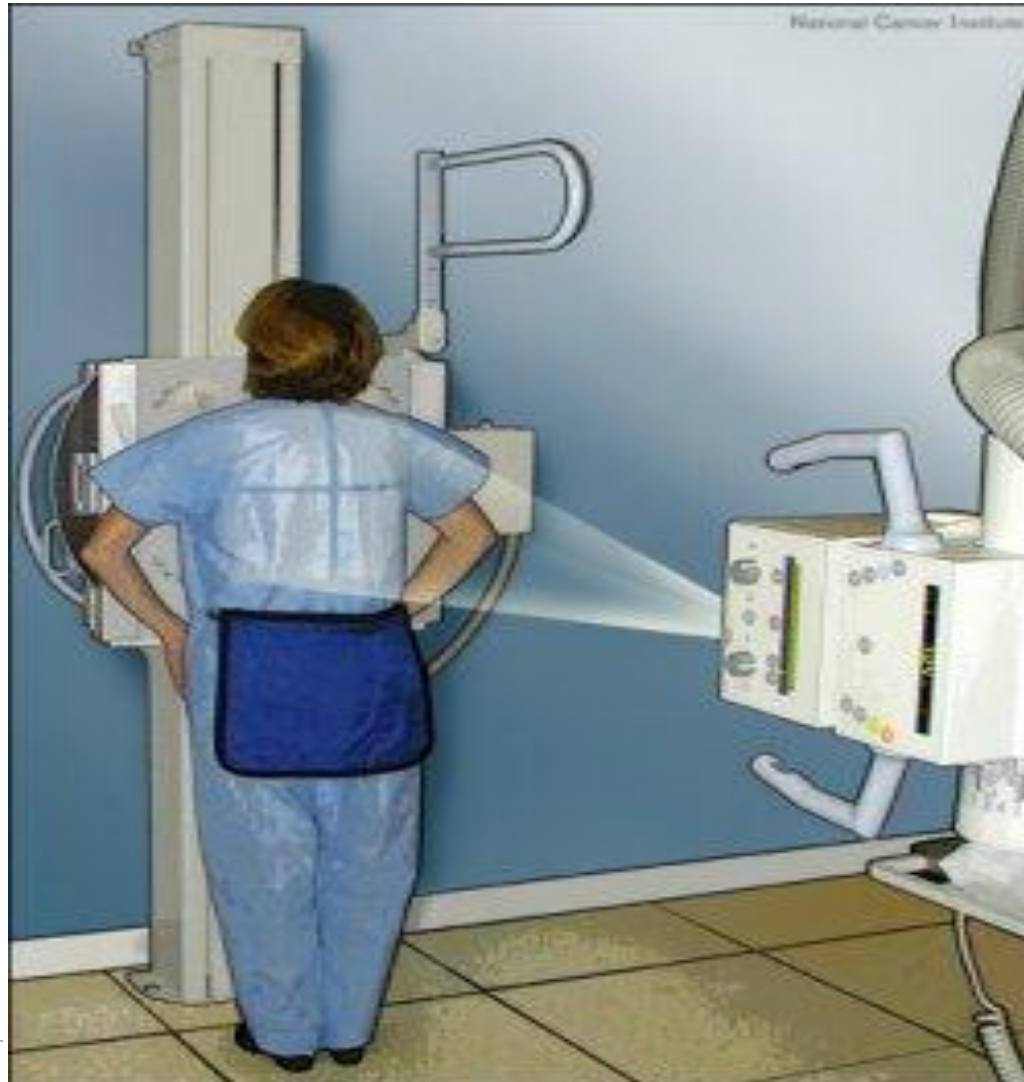
❑ For chest radiography, a lead-rubber Gonadal shield should be employed so to protect the abdomen below the chest (using vinyl-covered lead apron) around the waist for all patients of reproductive age, children, and pregnant women. Otherwise, an adjustable mobile lead shield screen must be used.

❑ Low contrast ( *long-scale contrast*) contrast must be adopted using 'High kV Technique' (100 - 130 kVp) with low mAs (3 mAs) at 72 inches (180 cm) FFD (SID) on full second inspiration, to produce more shades of gray that shows fine lung markings behind the heart and lung bases due to the higher penetration.

❑ Higher mA and short exposure times (0.01 s) must be used to reduce movement blur (due to movement unsharpness, ( $U_m$ )). Overall optimum density with sufficient mAs is necessary, which can be proved by seeing faint outlines of mid and upper vertebrae and posterior ribs.

# Protect gonadal area in CXR

---





# Technical Aspects

❑ A moving or high-lattice fine-line) focused grids must be used with the high kV technique. Grids should not be used with mobile and bed-side patients (mobile radiography).

❑ For pediatrics and newborns

❖ lower kV (60 – 70 KV) must be used with lower mAs

❖ Higher-speed films and screens are used to reduce motion and dose

❖ AP supine and laterals (dorsal decubitus) must to be done to exclude air- fluid levels

❑ For geriatrics (old age) higher center point (CP) must be used because of less inhalation capability of old people that produces 'shallow lung fields'.

❑ X-ray chest must be taken in full arrested second inspiration to show the lungs well expanded and full with 'contrasting air'. In pneumothorax, another full exposure on (expiration) must be done (on the same film) for diagnostic comparison purposes, with an increase of (+5 kVp) and half the usual mAs.

# Technical Aspects

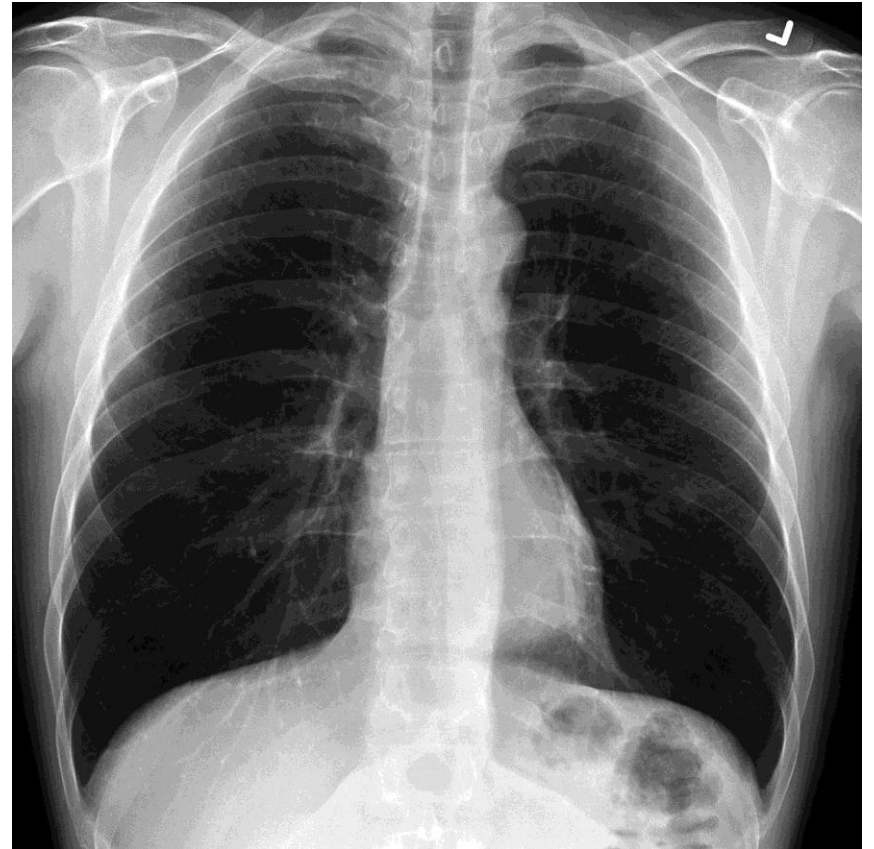
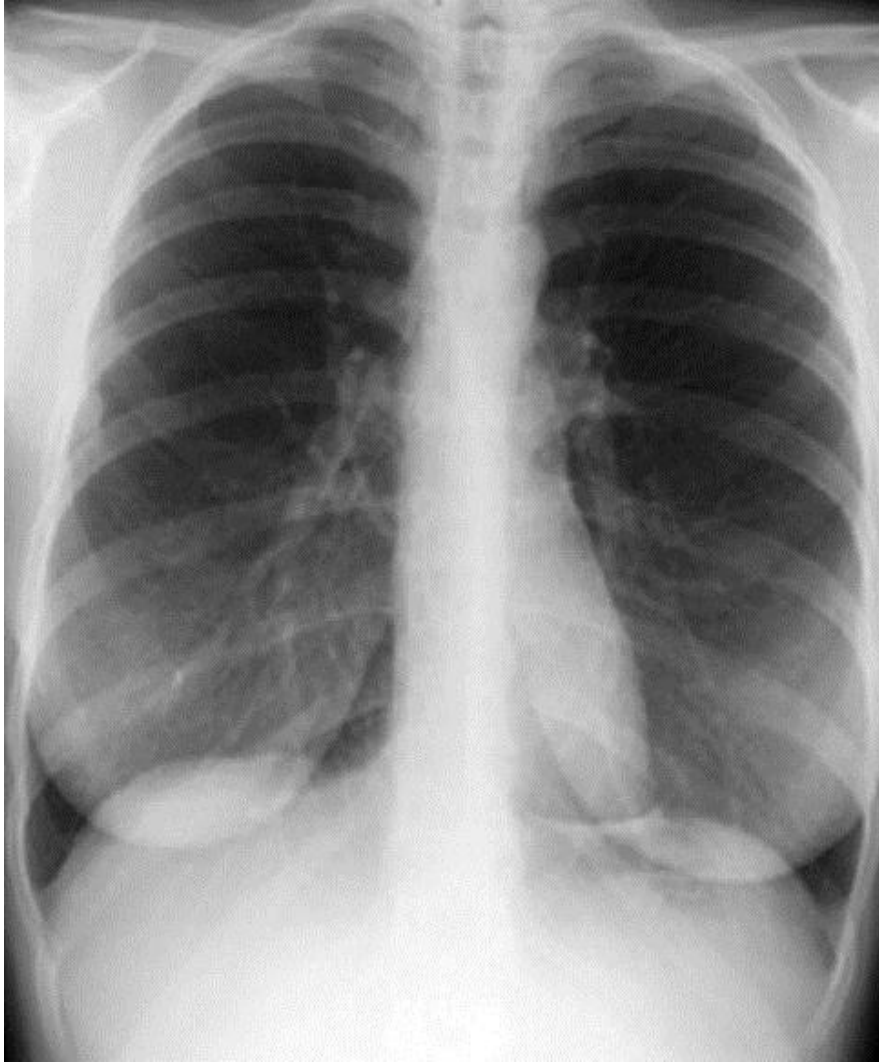
- ☐ A left lateral chest film must be done routinely as the heart is located on the left side, unless certain pathology in the right lung necessitates the need for a right lateral.
- ☐ Patient's neck must be extended (chin up) to prevent superimposition of chin or neck on lung apices. Also, large female breasts must be displaced away from lung fields to avoid creating 'breast shadows'
- ☐ Proper CP for the chest is (T7) to avoid irradiating the eyes, thyroid gland, and the mammary glands.
- ☐ Basic (routine) views are: PA and lateral. Special views include: AP or PA apical, Lordotic, lateral decubitus, AP supine (or semi-erect), LAO, and LPO.



Female

PA CHEST

Male





# Acronyms

---

**SID** (source to image receptor distance )

=

**FFD** (Film focal distance )

**CP** ( center point )

**CR** ( center ray )

**IR** (Image receptor )

**OFD** ( object film distance )

**MSP** (mid sagittal plan )

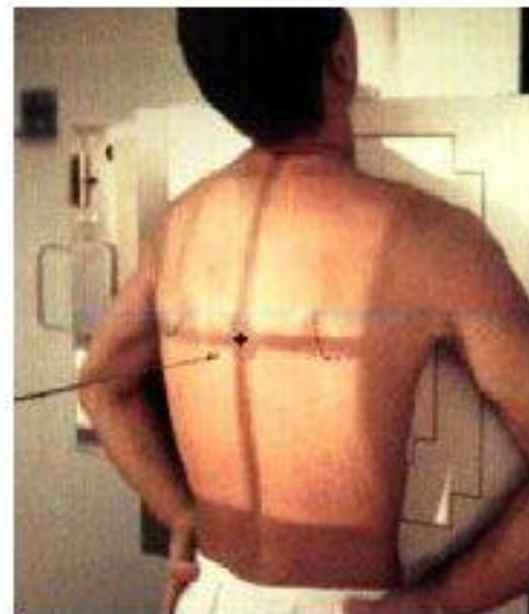

# PA Chest (Erect)

- Erect film shows pleural effusions, infections, Atelectasis, pneumo –thorax.

## Patient and Part Position

- Patient erect, feet apart, chin rested on film top edge, hands on lower hips, elbows partially flexed, the shoulders rotated forward (to move the clavicles below apices), top of film 5 cm above the shoulders (to include the apices), exposure on 2<sup>nd</sup> arrested (inspiration), collimation and protection should be applied.
- Instruct the patient to take in a breath, blow the breath out, and take another deep breath and hold it ( 2<sup>nd</sup> rested inspiration)
- **Film:** HD 35x43 cm (14x17 in) lengthwise  
(crosswise for large patients)
- **CR:** Horizontally 90° to film center.
- **CP:** T7 (Approximately at the level of  
inferior angle of the scapula)



# Diseases REQUEST

---

- ▶ **Atelectasis** : Atelectasis is a collapse of lung tissue affecting part or all of one lung. This condition prevents normal oxygen absorption to healthy tissues.
- ▶ **Pleural effusion** occurs when too much fluid collects in the pleural space (the space between the two layers of the pleura)
- ▶ **Pneumothorax** is a collection of air or gas in the chest or pleural space that causes part or all of a lung to collapse.

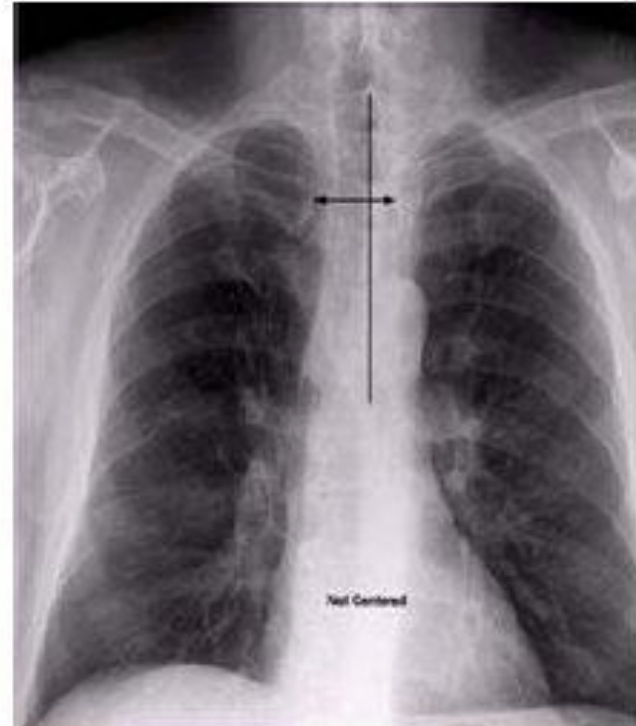
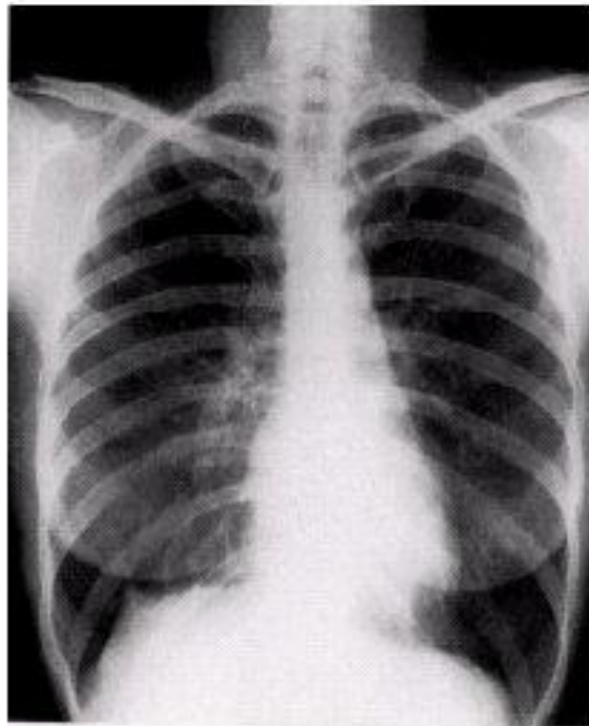




# PA Chest (Erect)

## Image Evaluation

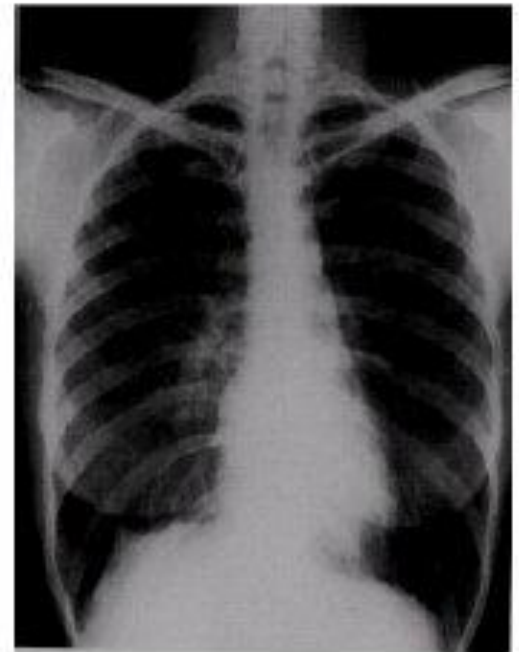
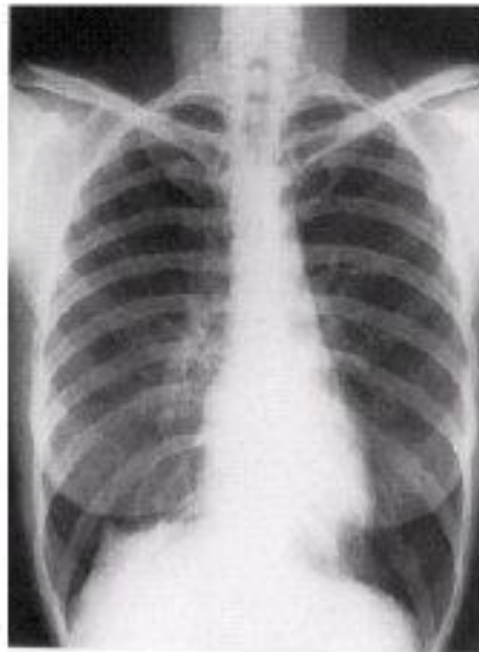
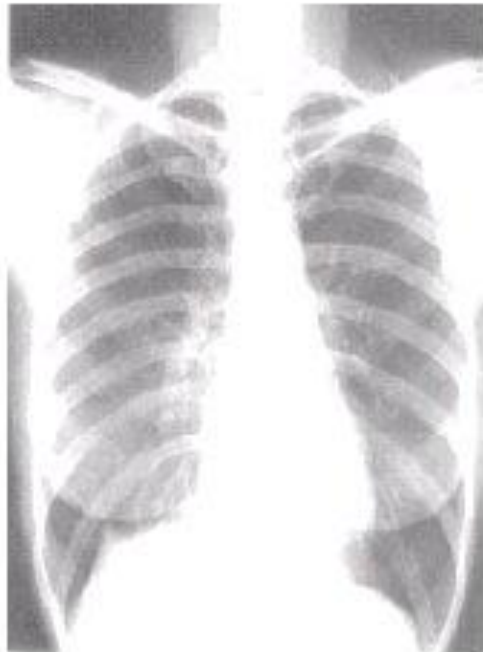
- The lung apices, costophrenic angles, and lateral margin of the ribs should be included in the film.
- The scapulae should be moved lateral to the lung fields
- The spine should be centered on the film



# PA Chest (Erect)

## Image Evaluation

- The heart should be adequately penetrated showing sharp outlines, with vascular markings near lateral lung margins.



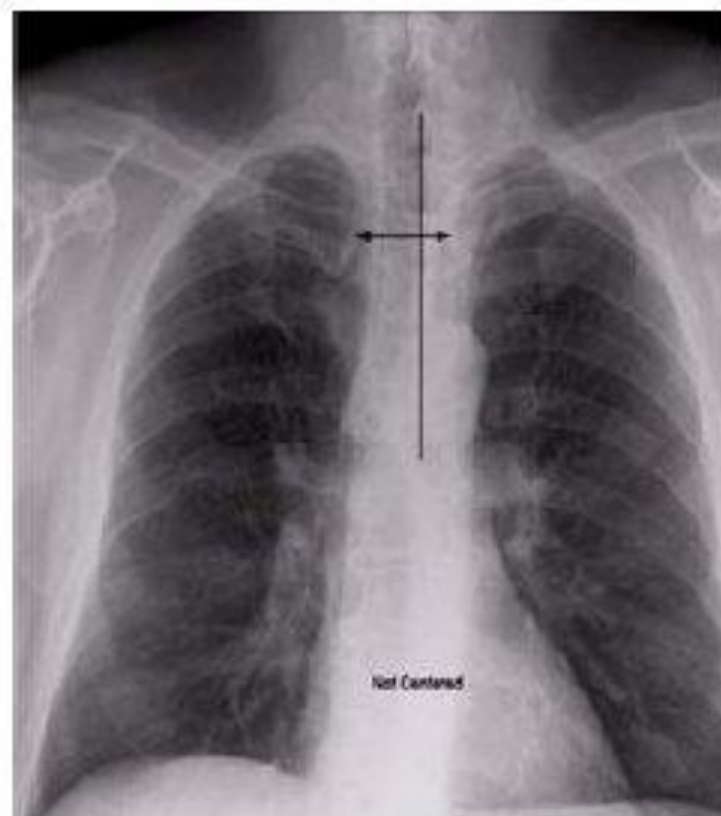
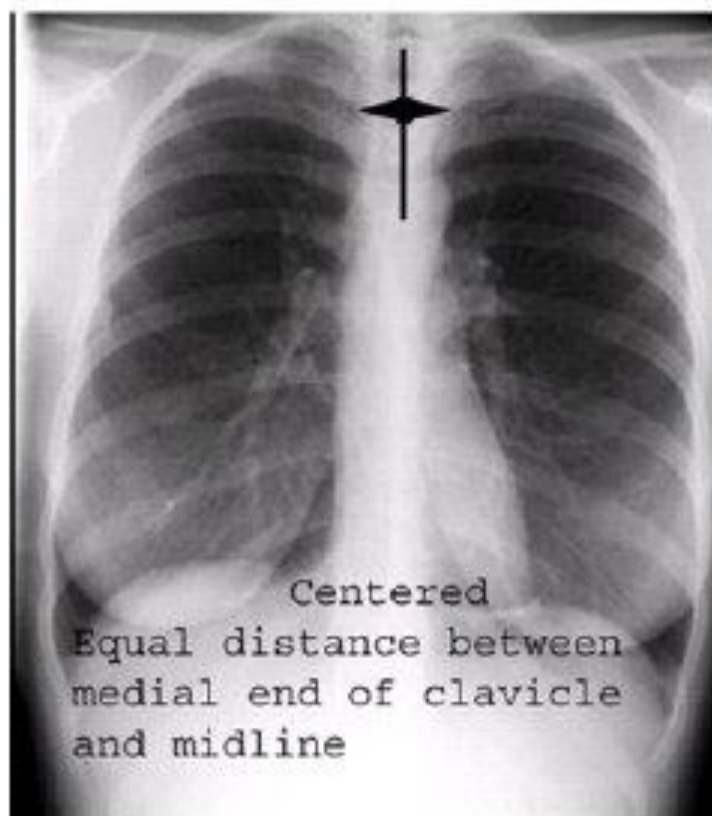
**OPTIMAL**

**EXPOSURE FACTORE**

# PA Chest (Erect)

## Image Evaluation

- The distance between the medial end of the clavicle and sternum (sterno-clavicular joints) should be equal in both sides.

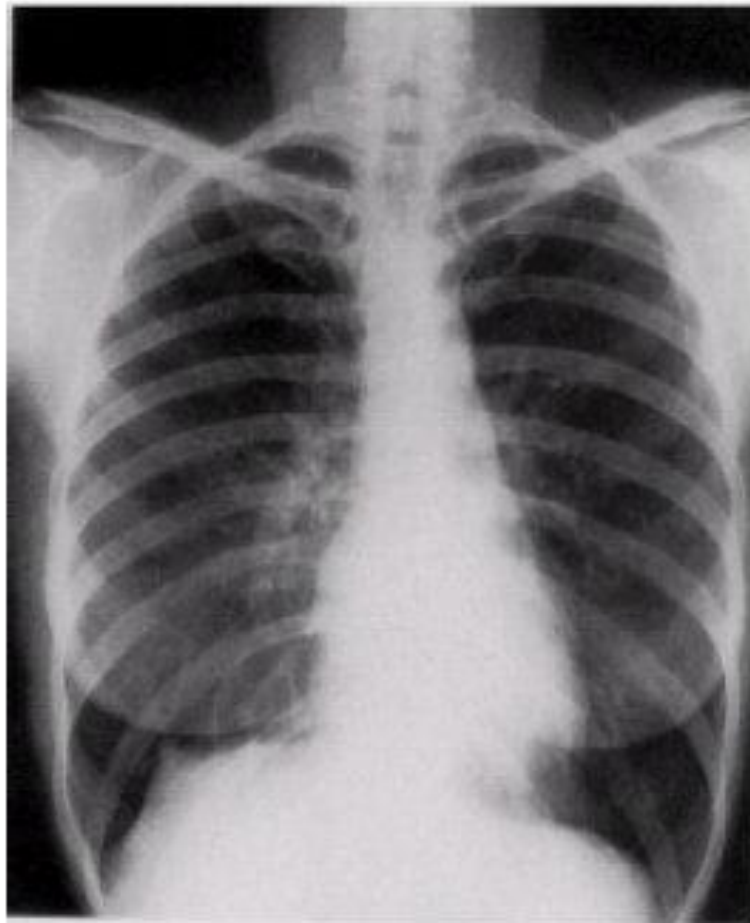


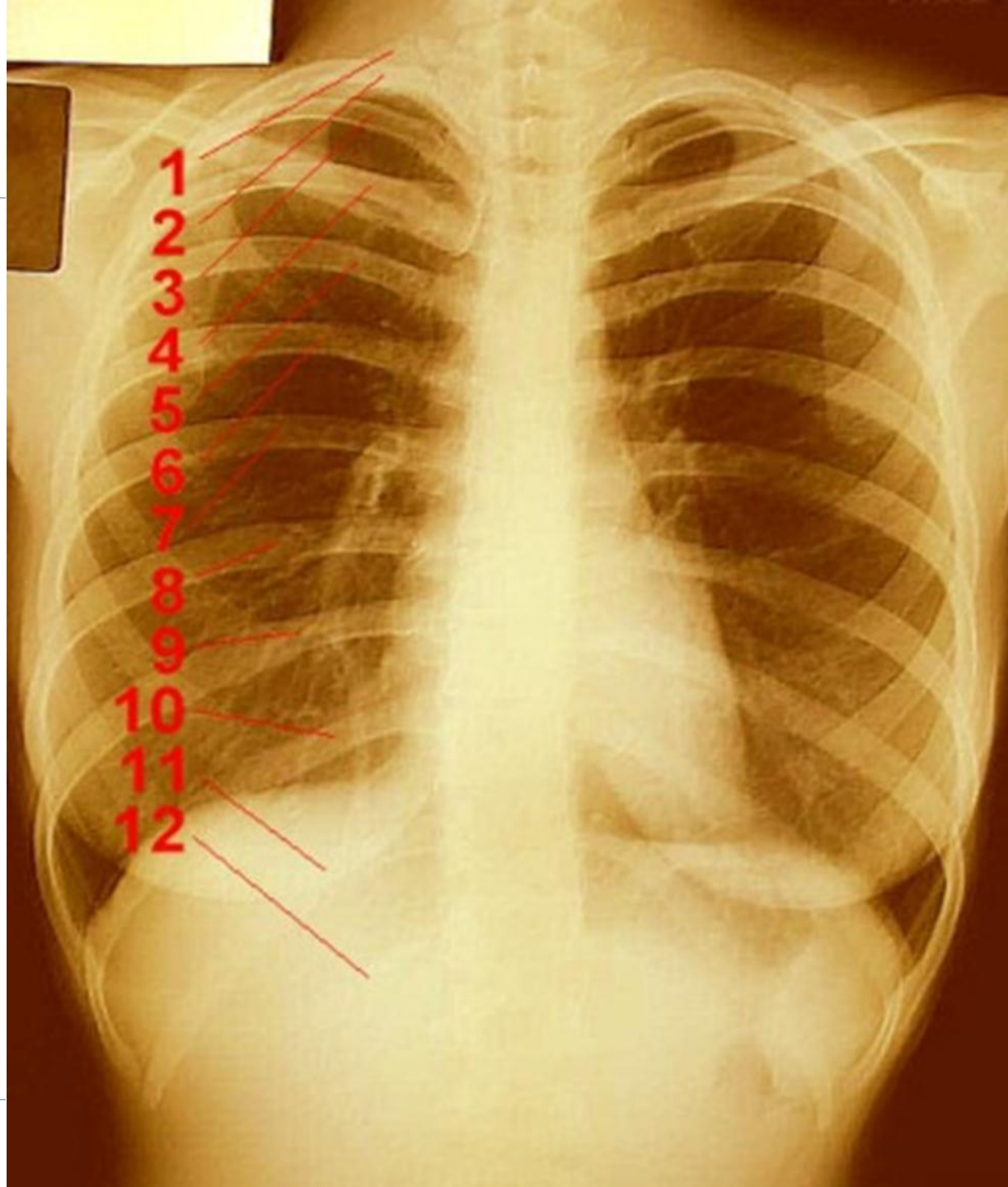


# PA Chest (Erect)

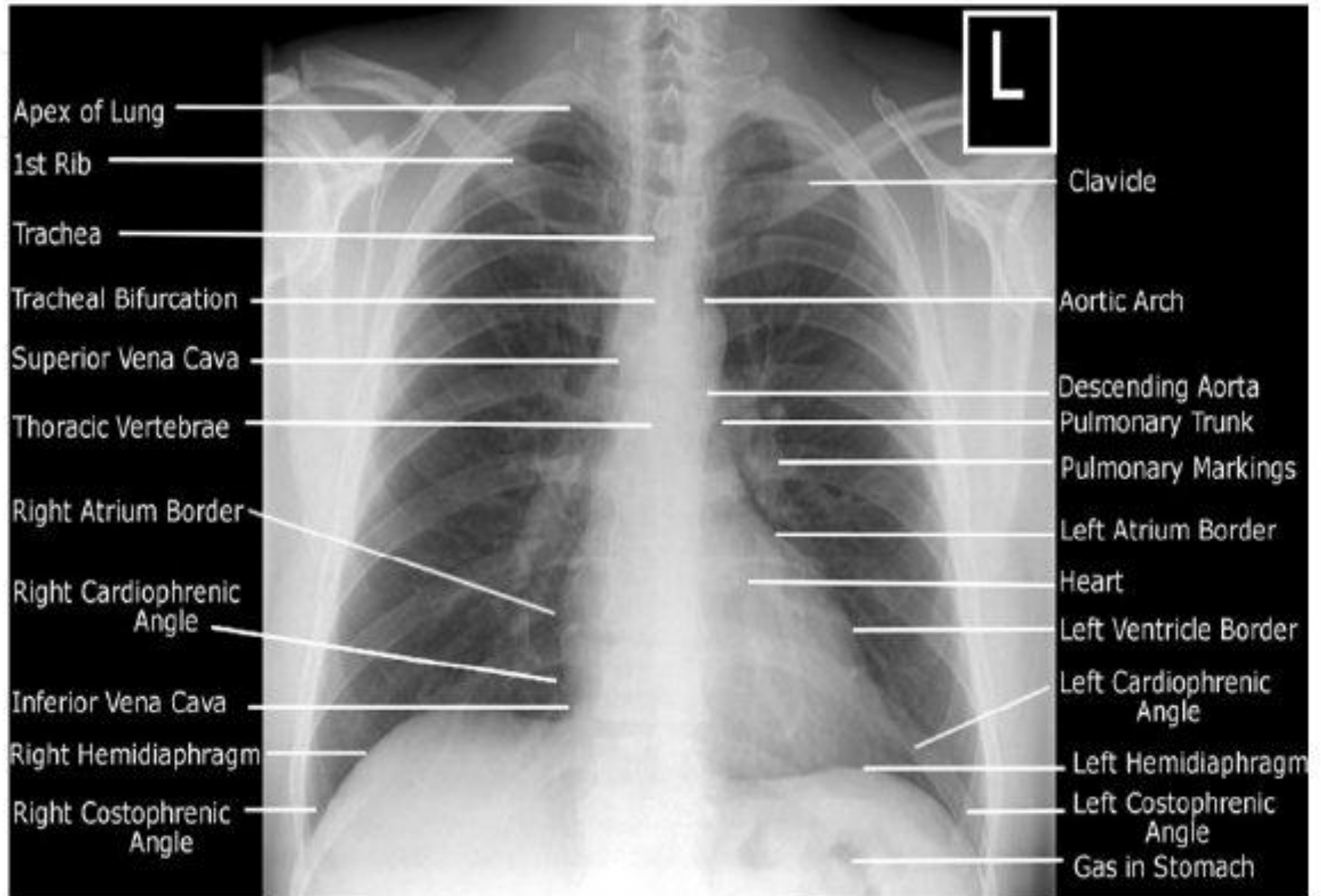
## Image Evaluation

- 10 posterior ribs should be demonstrated above the diaphragm.





# PA Chest (Radiographic Anatomy)



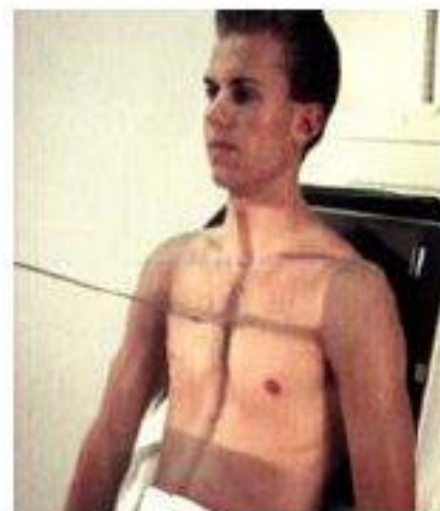
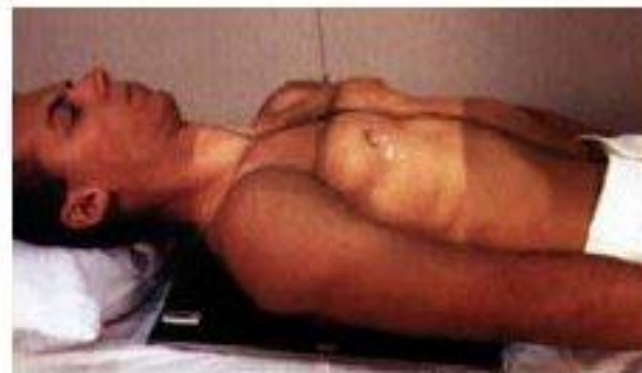
# AP Chest (supine/semi erect)

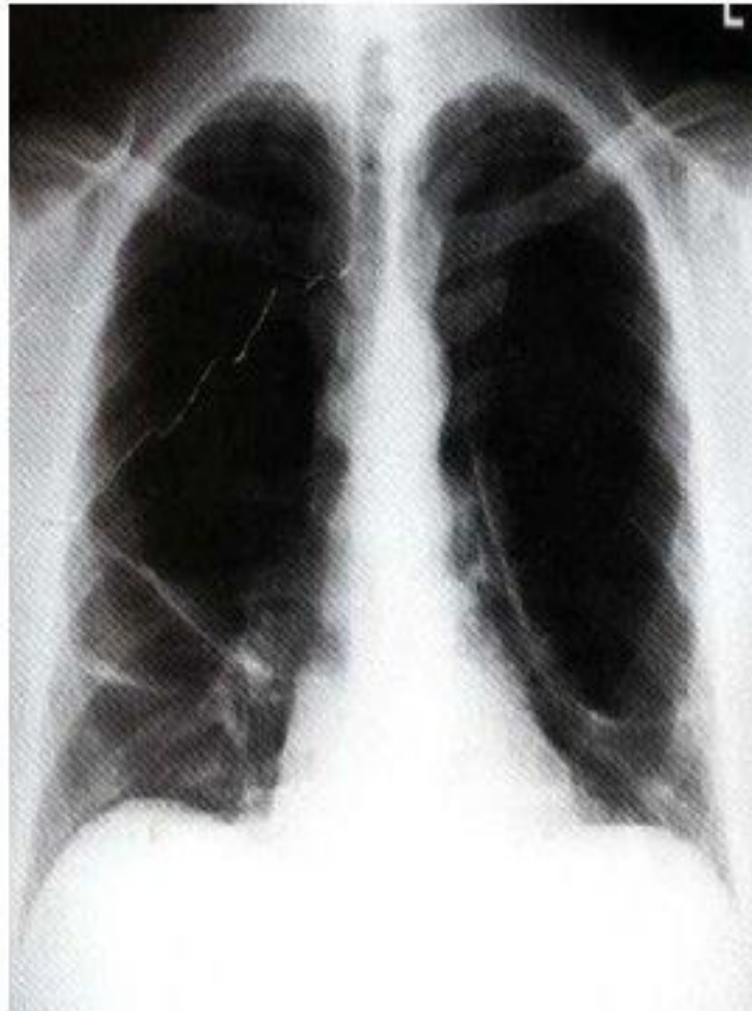
- For trolley and bedside patients to demonstrate pathology involving lungs, diaphragm, and the mediastinum. kV for bedside is 70-80 with a grid, for large patients 80-100 kV with grid, film cross-wise to eliminate possible lateral cutoff.

## Patient and Part Position

- Patient supine on trolley, trolley head raised into a semi erect position, film behind the patient.
- **Film:** HD (14x17 in) crosswise.
- **CR:** 5° caudal to prevent clavicles from obscuring the apices, FFD 100 cm, at least for supine.
- **CP:** T7 (3-4 inches below the jugular notch).
- **NB/** With this position it is impossible to show any fluid levels.



## AP Chest (supine/semi erect) **S**

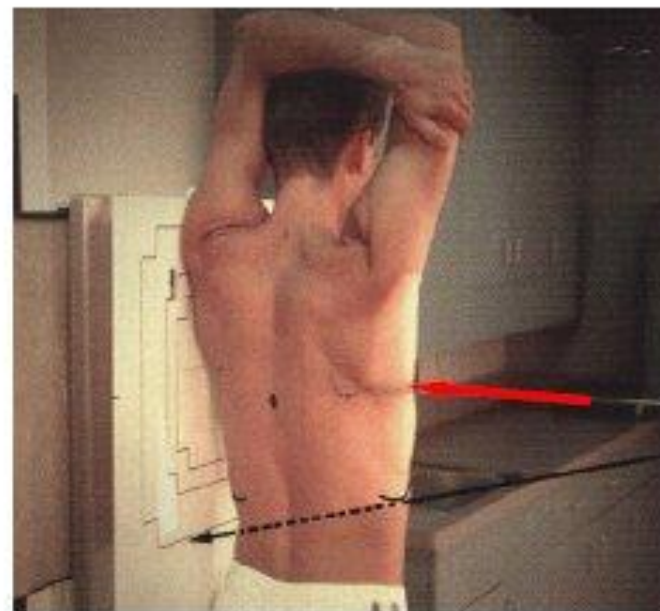


# Lateral Chest (Erect)

- Basic (additional) projection for localizing position of a lesion, or for the heart. A grid is used.

## Patient and Part Position

- Patient erect, turned with side of interest in close contact with the film, MSP parallel with film, arms folded over the head.
- Instruct the patient to take in a breath, blow the breath out, and take another deep breath and hold it ( 2<sup>nd</sup> rested inspiration)
- **Film:** HD 35x43 cm (14x17 in).
- **CR:** 90° horizontally.
- **CP:** T7. (Approximately at the level of inferior angle of the scapula)
- NB/** kV 125, at 6 mAs (with grid).

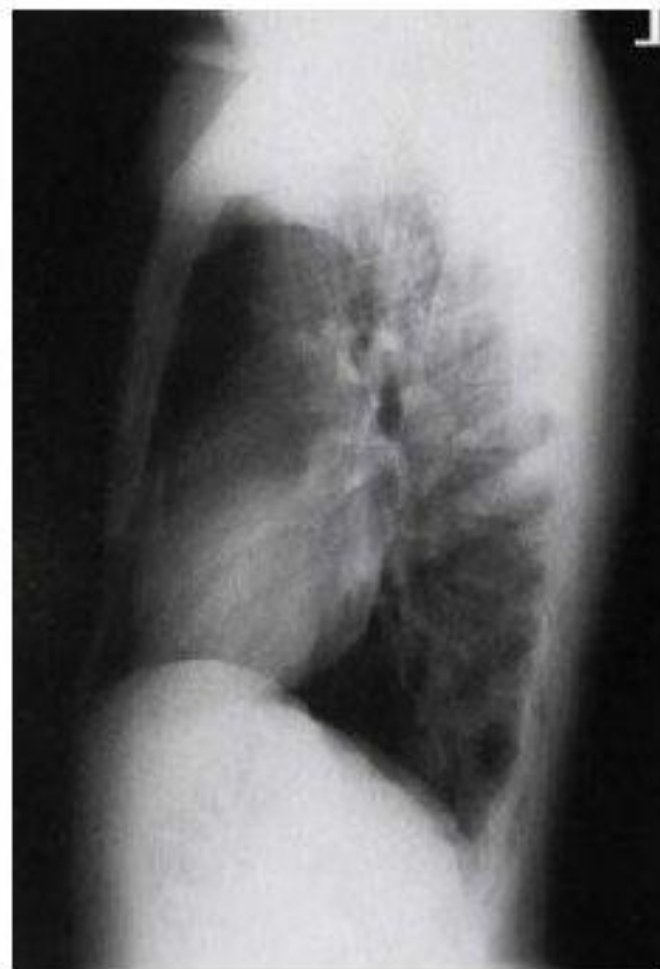



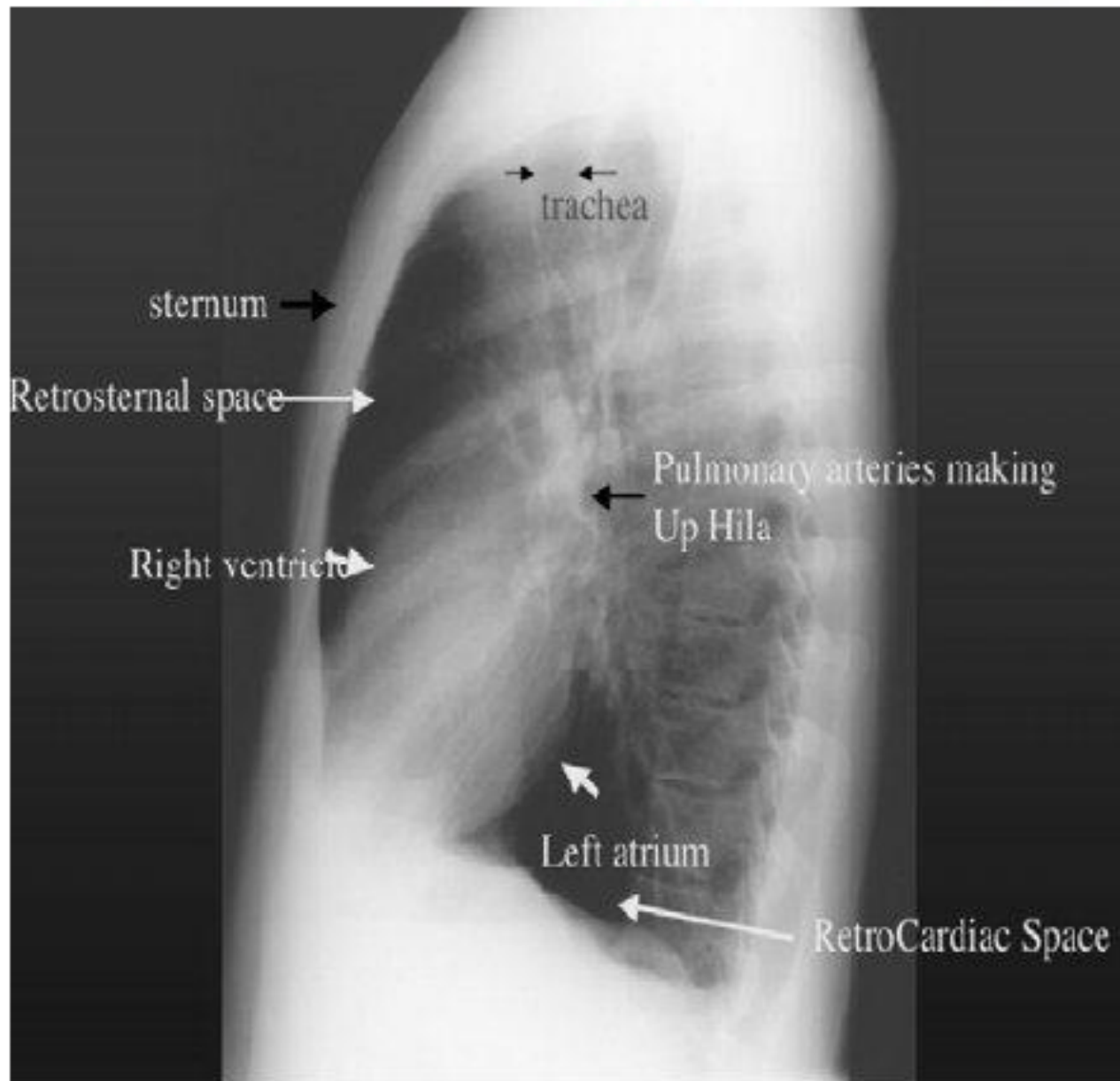
# Lateral Chest (Erect)

## Image Evaluation

- The lung apices, costophrenic angles, spine and sternum should be included in the film.
- The thorax should be in the center of the collimated area
- The heart should adequately penetrated showing sharp outlines, with vascular markings behind the sternum and heart.
- Patient arms and chin should not superimposed over the upper lung fields



# Lateral Chest (Radiographic Anatomy)



# Lateral Chest (stretcher / Wheelchair Patient)

● For ill patient who can't stand for an erect standing lateral

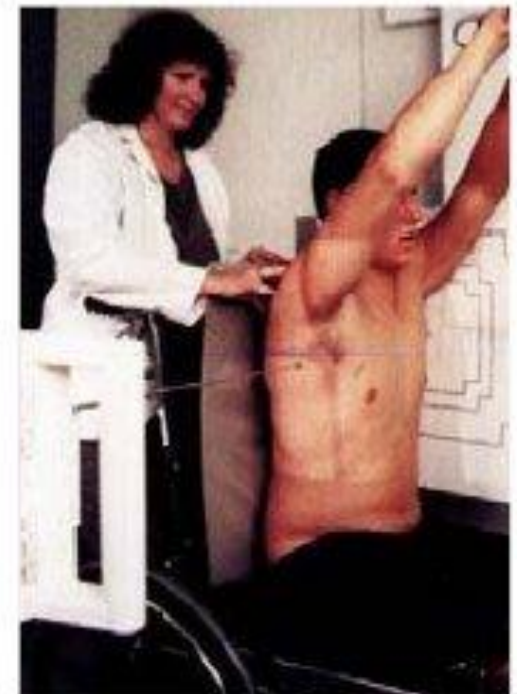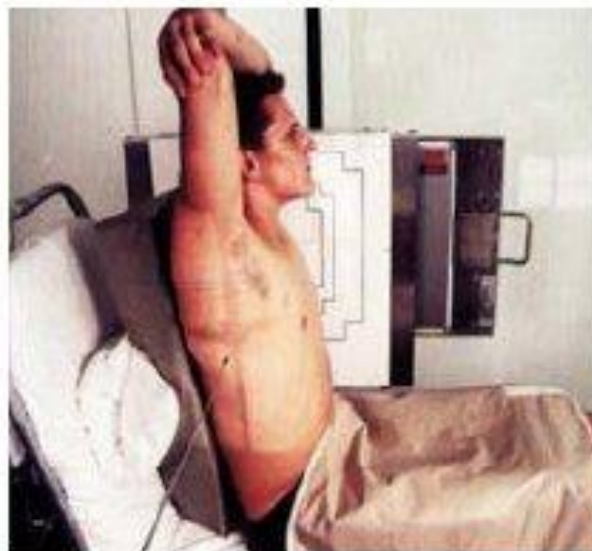## Patient and Part Position

- Patient seated on stretcher or wheelchair with side of interest in close contact with the film, MSP parallel with film, arms folded over the head.
- Instruct the patient to hold breathing on rested inspiration

● **Film:** HD 35x43 cm (14x17 in).

● **CR:** 90° horizontally.

● **CP:** T7.





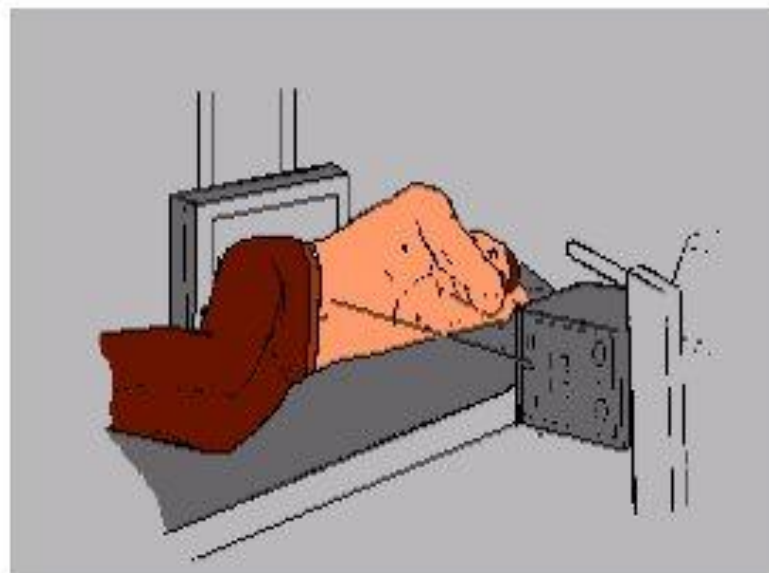
# Lateral Decubitus (AP Horizontal Beam)

- For patients who unable to stand to demonstrate small pleural effusions (air-fluid levels) ,pneumothorax. A (DECUBITUS) marker or (ARROW) should be used.

## Patient and Part Position

- Patient lying on one side on radiolucent pad, chin and arms raised above head, patient back against a vertical cassette, knees flexed slightly, top of the cassette approximately 1 inch above the vertebra prominens.

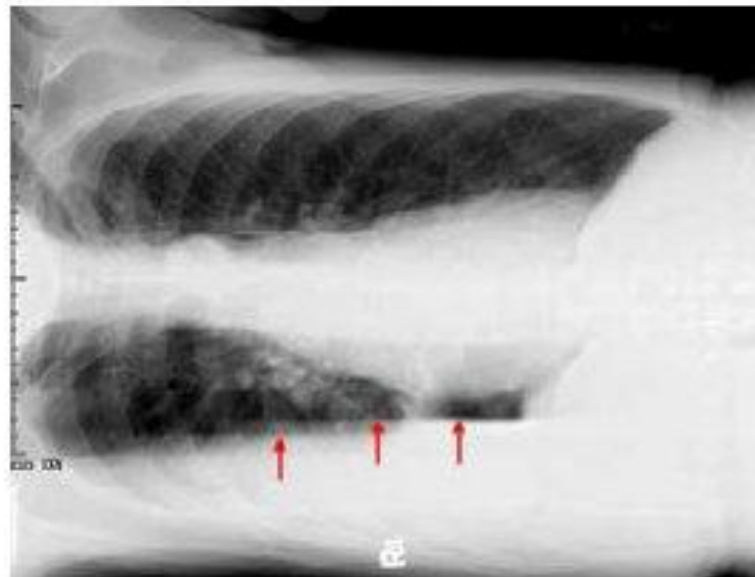
- **Film:** HD 35x43 cm vertical on the couch edge.
- **CR:** Horizontally 90° to film center.
- **CP:** T7(3-4 inches inferior to jugular notch



# Lateral Decubitus (AP Horizontal Beam)

## Image Evaluation

- The lung apices, costophrenic angles, lateral margins of the ribs should be included in the film.
- The thorax should be in the center of the collimated area
- The heart should adequately penetrated with sharp outlines without over exposure of the lungs
- Patient arms and chin should not superimposed over the upper lung fields



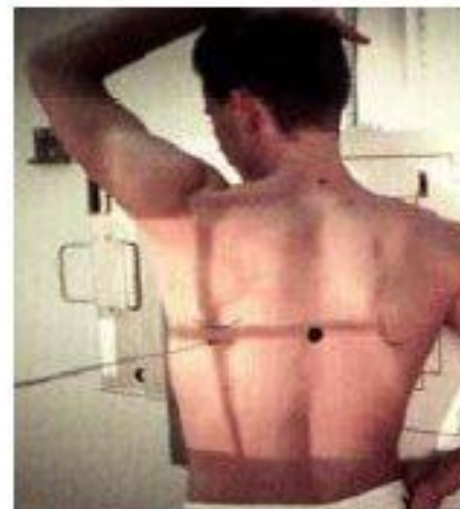# LAO/RAO Chest

- For pathology involving the lung fields, trachea, and mediastinum structures (including the heart).

## Patient and Part Position

- Patient erect rotated 45° (left anterior shoulder against film for LAO, and right anterior shoulder against film for RAO).
- Patient feet should be separated slightly with weight equally on feet
- Arm away from the film raised with hand on top of unit
- Arm nearest the film flexed at elbow with hand on the hip without obscuring the lower lungs
- **Film:** HD 35x43 cm (14x17 in).
- **CR:** horizontally 90° to film holder
- **CP:** T7. (Approximately at the level of inferior angle of the scapula)

**NB/** For heart patient should be rotated 55° to 60° in the LAO



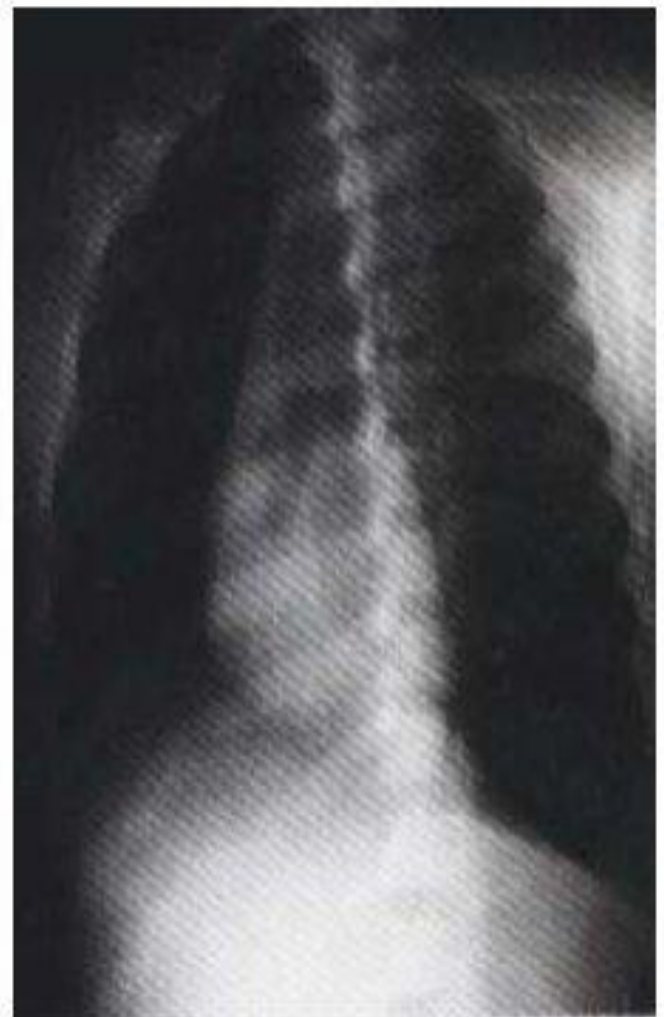


# LAO/RAO Chest

## Image Evaluation

- The lung apices, costophrenic angles, lateral margins of the ribs should be included without cut.
- The heart should be adequately penetrated with showing sharp outlines and without over exposure of the lungs
- The width from the spine to the lateral margin of the thoracic cage of the side away from the film should be twice the width of the side contact with the film

( This indicates true or correct oblique)



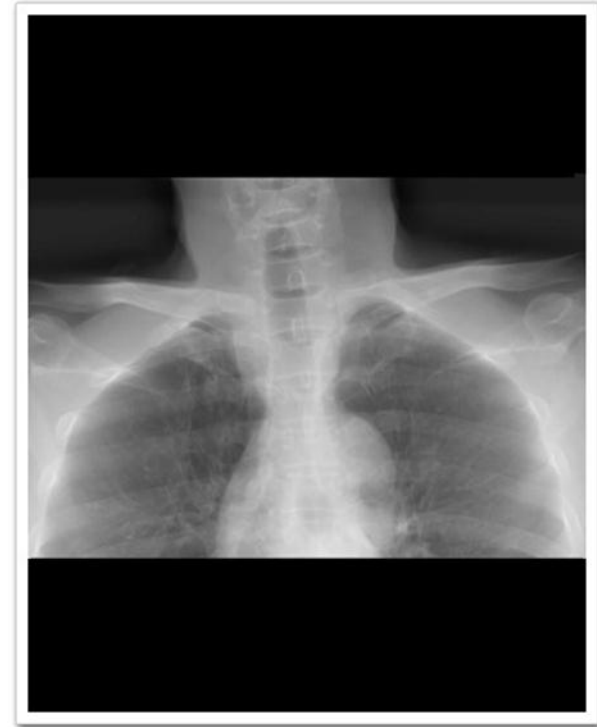# APICAL VIEW \ LORDATIC PROJECTION

To rule out calcification and masses beneath the clavicles **eg** :inactive disease like( TB )seen primarily in apex of one or both lungs .

**CR** : Mid of midsternum , 3-4inch (9cm ) below jugular notch .

**CR** : perpendicular

**PROTECTION** : lead shield around waist  
Respiration : 2nd full inspiration  
Colimate to area of interest (apices of the lungs



**SID** : 180 cm

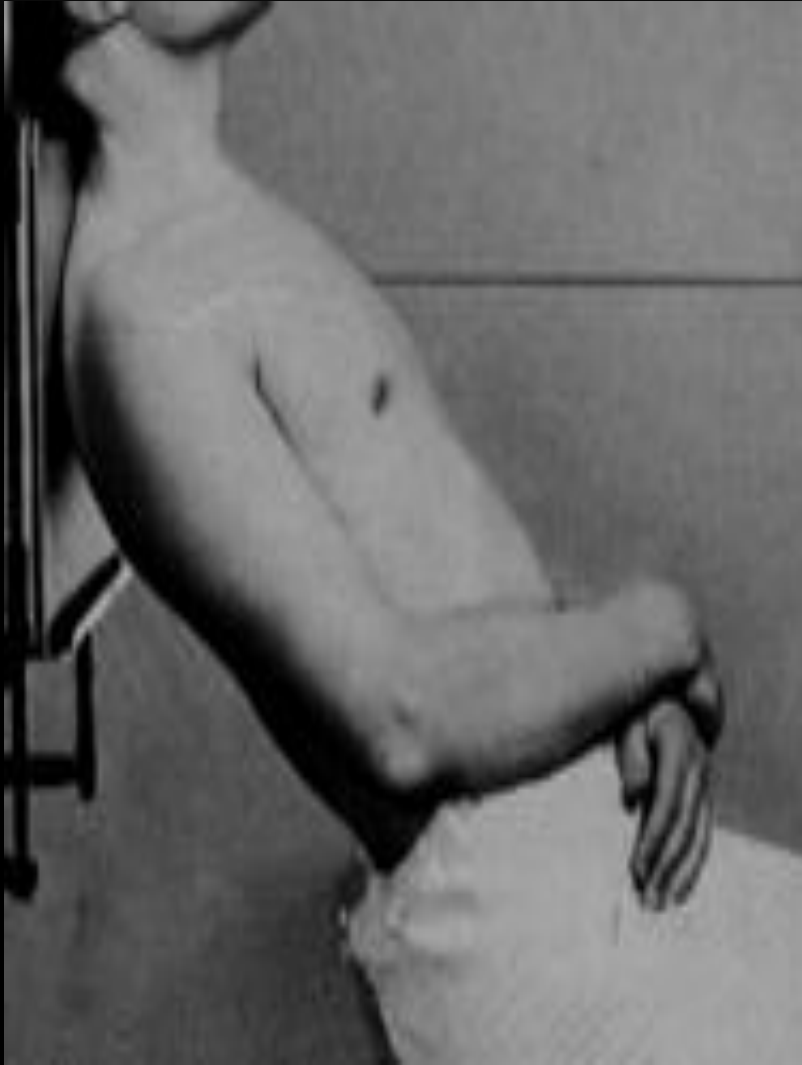**EXP. Factors** :

**KV** : 110-125

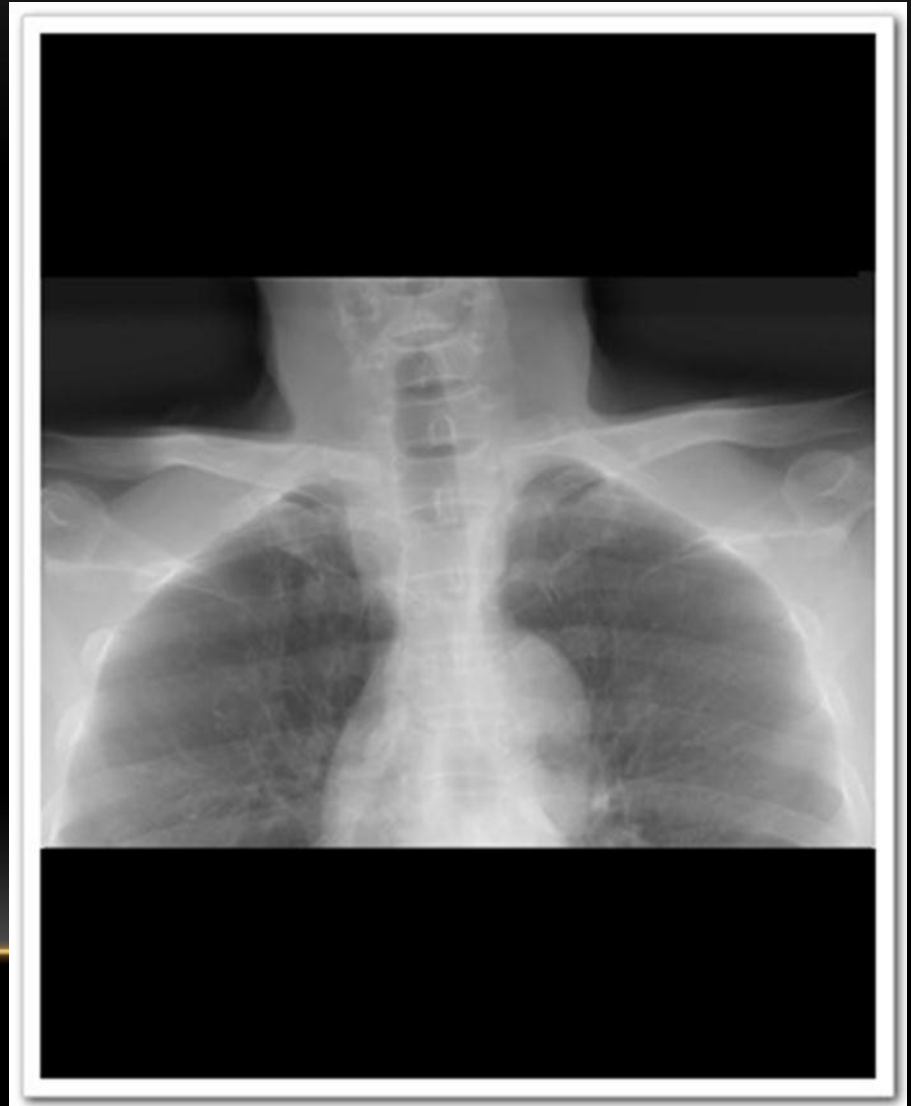**MAS** : 3

**GRID** : 180 cm

## LORDATIC PROJECTION



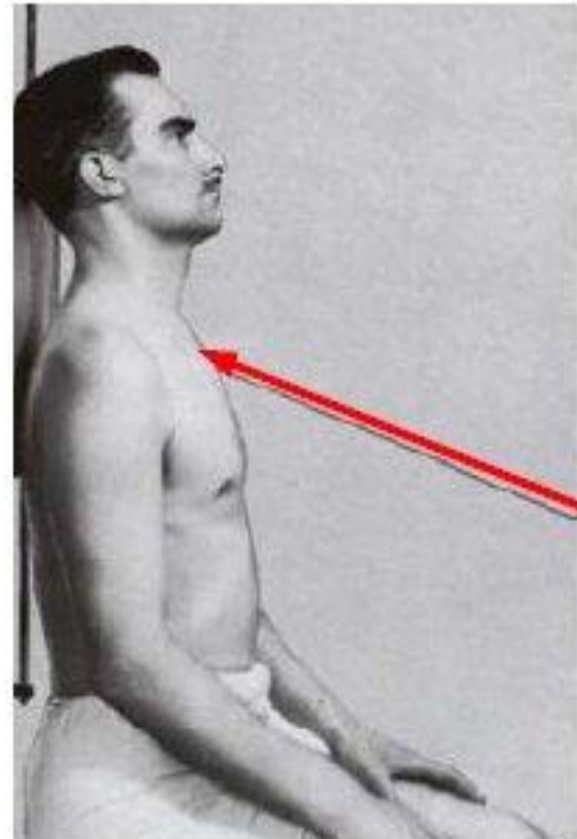
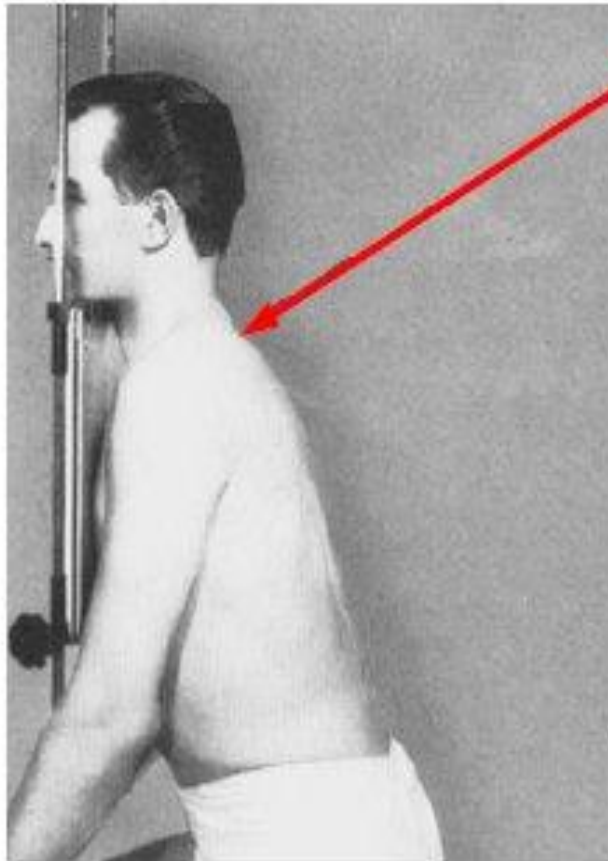
## APICAL VIEW





# Lordotic Chest

S



- If the patient unable to perform the Lordotic position angle the CR  $20^{\circ}$  cephalic for AP Lordotic or  $20^{\circ}$  caudad for PA Lordotic

---

## ▶ **References**

- ▶ • Positioning in Radiography: By k.C.Clarke.
- ▶ • Text book of radiographic positioning and related anatomy; by Kenneth L.Bontrager,
- ▶ 5th edition

## ▶ **Websites**

- ▶ • <http://www.e-radiography.net/>
- ▶ • [http://www.theodora.com/anatomy/surface\\_anatomy\\_index.html](http://www.theodora.com/anatomy/surface_anatomy_index.html)
- ▶ • [http://training.seer.cancer.gov/module\\_anatomy/unit1\\_3\\_terminology.html](http://training.seer.cancer.gov/module_anatomy/unit1_3_terminology.html)



# 331RAD

---

- ▶ **1<sup>ST</sup> med 15**
- ▶ **2<sup>nd</sup> med 15**
- ▶ **Practical 20**
- ▶ **Final 47**
- ▶ **Activity ,attitude and attendance 3**

