



King Saud University  
**Saudi Journal of Ophthalmology**

www.ksu.edu.sa  
www.sciencedirect.com



ORIGINAL ARTICLE

# Controlled Cyclophotocoagulation with diode laser in refractory glaucoma and long term follow up at King Abdulaziz University Hospital, Riyadh

**Essam A. Osman, MD, FRCS \***, **Abdulrahman Al-Muammar, FRCSC**,  
**Ahmed Mousa, MSc**, **Hani Al-Mezaine, MD**, **Saleh A. Al-Obeidan, MD**

*Department of Ophthalmology, College of Medicine, King Saud University, Riyadh, Saudi Arabia*

Received 24 August 2009; accepted 18 November 2009

Available online 7 January 2010

## KEYWORDS

Cyclophotocoagulation;  
Diode laser;  
Glaucoma;  
Intraocular Pressure

**Abstract** *Purpose:* To evaluate the clinical efficacy and safety of controlled contact transscleral diode laser Cyclophotocoagulation (COCO) procedure in reducing the Intraocular Pressure (IOP) among patients with refractory glaucoma.

*Methods:* Thirty two patients (35 eyes) with refractory glaucoma in prospective clinical studies were treated with trans-sclera diode laser in a controlled manner. The energy power used was 5 W in adults and 3 W in children, exposure time was 0.5 s, a total of 16 shots were applied over ciliary body and four shots in each quadrant. Pre and postoperative IOP were measured at different postoperative visits. Snellen visual acuity, the number of anti-glaucoma medications and associated complications were also recorded. Student *T* test was used to compare the pre and post intervention IOPs, while Wilcoxon Signed Ranks test was used, to detect significance change in medication dependency.

*Results:* The mean (SD) follow up time was 80.2(±9.6) months, range (36–84) m, where the mean IOP was significantly reduced from 35.1 mm Hg (±10.7) before intervention to 18.8 mm Hg (±7.3) after intervention, in the final visit ( $P < 0.0001$ ). Complete success was achieved in seven eyes (20%), 22 eyes (62.8%) showed qualified successes and complete failure was reported in six eyes (17.1%). The overall success rate was 82.8% (95% CI: 70.4–95.3). Visual acuity improved

\* Corresponding author. Address: King Abdul Aziz University Hospital, King Abdul Aziz Road, P.O. Box 245, Riyadh 11411, Saudi Arabia. Tel.: +966 1 4775723; fax: +966 1 4775724.  
E-mail address: [essam.osman065@gmail.com](mailto:essam.osman065@gmail.com) (E.A. Osman).



in three eyes (8.5%), no change took place in 27 eyes (77.1%) and decreased in five eyes (14.2%). The number of anti-glaucoma medications has significantly changed between pre and post intervention ( $P < 0.0001$ ). No cases of hypotony, phthisis bulbi or sympathetic ophthalmia were reported.

**Conclusion:** Controlled COCO is a simple procedure, safe with minimal complications and fewer side effects.

© 2009 King Saud University. All rights reserved.

## 1. Introduction

Contact transscleral diode laser Cyclophotocoagulation (COCO) has been established as a relatively safe and effective treatment for uncontrolled glaucoma in adult and pediatric patients (Hennis and Stewart, 1992; Hawkins and Stewart, 1993; Kosoko et al., 1996; Brancato et al., 1995; Threlkeld and Johnson, 1999; Egbert et al., 2001; Mistlberger et al., 2001). This is compared to ND:YAG laser COCO and cyclocryotherapy, that carry risk of hypotony and phthisis bulbi (Benson and Nelson, 1990; Brindley and Shields, 1968; Ulbig et al., 1995). Cyclodestructive procedures – contrary to filtering glaucoma surgery – and tube surgery lower the IOP by reducing the inflow as a result of destruction of ciliary body. The high rate of complications includes phthisis bulbi, visual loss, and an unpredictable degree of IOP reduction. These procedures are usually convenient to patients with refractory glaucomas where trabeculectomy or tube shunt operations have failed, patients with no visual potential, in need of pain relief, patients with complicated glaucoma and conjunctival scarring due to previous surgery.

Destruction of ciliary body has been introduced in the treatment of glaucoma since 1930 (Vogt, 1936). Cyclocryotherapy was introduced by Bietti in 1950 (Benson and Nelson, 1990; Brindley and Shields, 1968; Bietti, 1950), with less destructive effect than cyclodiathermy, but still having its complications of postoperative severe pain hypotony, visual loss and phthisis bulbi.

Cyclophotocoagulation was first proposed by Weekers and Coworker in 1961 using Xenon Arc (Weekers et al., 1961). Backman and colleagues used Ruby Laser in 1972 (Beckman et al., 1972). Moreover, Frakhauser and associate, incorporated a thermal mode into a Neodymium:YAG Laser System to perform transscleral CPC (Frankhauser and Kwasniewska, 1993).

Semiconductor diode laser (wave length of 809 nm) can effectively reduce IOP with potential advantage over YAG of greater melanin absorption (Peyman et al., 1990; Assia et al., 1991; Brancato et al., 1991). Meanwhile, diode laser requires less energy for achieving gross and histological changes in the ciliary body.

In our study we use a controlled transscleral by fixed power and fixed duration.

## 2. Patients and methods

Thirty two consecutive patients with refractory glaucoma (35 eyes) were prospectively enrolled in the current study. Out of the recruited patients; 26 (74.3%) were females and six (25.7%) were males while three female patients were bilaterally operated. All patients underwent transscleral contact controlled procedure.

The inclusion criteria were; presence of uncontrolled glaucoma on maximum tolerated anti-glaucoma medications and/or failed previous glaucoma surgery. Nevertheless, the exclusion criteria were presenting cases with history of prior laser cyclodestructive therapy.

Demographic data including; age, sex, pre and postoperative medications were collected. All patients went through the following ophthalmic examination; Best-corrected Snellen Visual Acuity (BCVA), Slit Lamp examination, IOP measured using Goldman Applanation Tonometry and Tono-pen in pediatric group. Different types of glaucoma etiologies were presenting in our study as demonstrated in (Table 1). This includes; 12 (34.3%) eyes with angle closure type, nine (25.7%) eyes with open angle glaucoma, eight (22.9%) eyes with congenital glaucoma, four (11.4) eyes with neovascular glaucoma, one (2.9%) with ghost cell type and one (2.9%) with combined mechanism. The mean ( $\pm$ SD) of age of the sample was 50 ( $\pm$ 27), (range: 3 M – 72 years), VA ranges between NLP – 20/80, the mean ( $\pm$ SD) preoperative IOP was 35.1 ( $\pm$ 10.7) (range 15–56 mm Hg) while the mean number of anti-glaucoma medications was three (range 1–4 medications).

Previous surgical procedures were done to 25 eyes (Table 2); seven (28%) of open angle glaucoma, six (24%) of chronic angle closure glaucoma, one (4%) of neovascular glaucoma, one (4%) of ghost cell glaucoma, and 10 (40%) of congenital glaucoma. Ten eyes were not operated, seven (70%) eyes had NLP and three (30%) were seeing eyes (Table 3).

All adult patients were operated under peribulber local anesthesia. General anesthesia was used in a pediatric group for the convenience of operation. Preoperative cycloplegic and mydriatic drops were applied to all patients, then they were exposed to a single treatment of diode laser (809 nm), four shots in each quadrant. Thus, a total of 16 shots were given using a fiber optic prop 1.5 mm, from the limbus with the help of transilluminator. Power of 5 W in adult group and 3 W in pediatric group, with a duration of 0.5 s.

Postoperative topical atropine and steroid drops as well as anti glaucoma medications were applied to patients. The mean follow up was of M ( $\pm$ SD) 80.23  $\pm$  9.5 (range: 36–84 months). Our outcome measurement indicators were mainly; change in pre and post IOP and the number of utilized medication.

**Table 1** Types of glaucoma etiologies.

Etiology of glaucoma	Number	Percentage (%)
Open angle type	9	25.7
Closed angle type	12	34.3
Congenital glaucoma	8	22.9
Ghost cell glaucoma	1	2.9
Combined mechanism glaucoma	1	2.9
Neovascular glaucoma	4	11.4
Total	35	100

**Table 2** Patients with previous surgical procedures.

Types	Previous surgical procedures	Number	Percentage (%)
Open angle types	Trabeculectomy with MMC	3	12
	ECCE and IOL	3	12
	Trabeculectomy with ECCE and PCIOL	1	4
Chronic angle closure glaucoma	ECCE-PCIOL	2	8
	Trabeculectomy with ECCE and PCIOL	1	4
	Trabeculectomy with MMC	3	12
NVG (neovascular glaucoma)	PPV (Parsplana Vitrectomy)	1	4
Ghost cell glaucoma	PPV (Parsplana Vitrectomy)	1	4
Congenital glaucoma	Trabeculotomy and trabeculectomy (combined)	7	28
	Trabeculectomy and tube surgery	1	4
	Deep sclerectomy and combined procedure	1	4
	Tube surgery and combined procedure	1	4
Total		25	100

**Table 3** Eyes with no previous surgery.

VA	NVG	OAG	CACG
NLP	2	2	3
LP			1
HM	1		
20/80		1	

IOP was measured in the second week, third month, after 6 months and at the final visit. *T* test to evaluate statistical significance of mean differences between preoperative and postoperative IOPs in the final visit were evaluated, differences between preoperative and postoperative VA. The number of anti-glaucoma medication taken before and after surgery was also investigated using Wilcoxon Signed Rank test for non-parametric categorical data.

The criteria of outcome of interest were as follows;

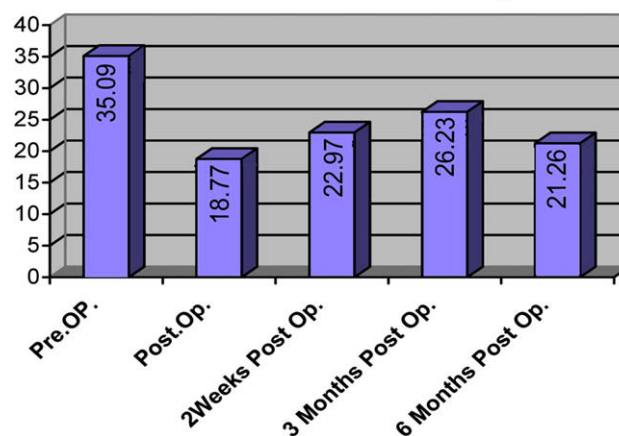
*Complete success:* if IOP  $\leq$  22 mm Hg without any glaucoma medication.

*Qualified success:* if IOP  $\geq$  22 mm Hg with glaucoma medication(s).

*Complete failure:* if IOP > 22 mm Hg & require further surgical intervention to control IOP.

### 3. Results

Thirty five eyes were enrolled in this study, out of which 30 (85.7%) eyes were females and five (14.3%) were males. The mean (SD) IOP before surgery was 35.1 ( $\pm$  10.74) (range 15–56 mm Hg) compared to postoperative values of 18.8 ( $\pm$  7.29) (range 6–40) Fig. 1. Preoperative Visual Acuity ranged from NLP to (20/80), M ( $\pm$  SD) Postoperative Visual Acuity ranged from NLP to 20/60. Snellen Log Mar pre-surgical Visual Acuity M ( $\pm$  SD) was 2.6 ( $\pm$  1.1), while it was 24.5 ( $\pm$  101.3) post surgery. Visual Acuity improved in three eyes (8.5%), did not change in 27 eyes (77.1%) and decreased in five eyes (14.2%). Fig. 2. The mean number of anti-glaucoma medications reduced from 2.8  $\pm$  0.83 (range 3–4) to 1.71  $\pm$  1.10 (range 0–3)

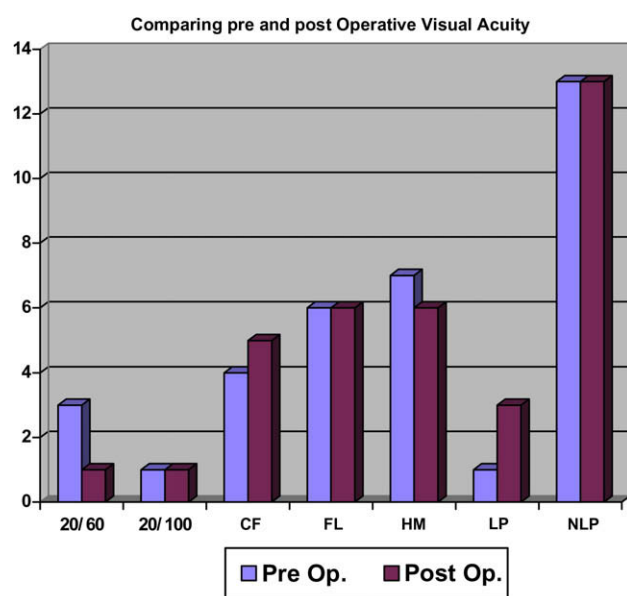
**Mean IOP level at different follow ups****Figure 1** Intraocular Pressure at different visits and postoperative final IOP.

post treatment *P* value < 0.0001 which is statistically significant.

In the first 2 weeks, the mean IOP was 22.97  $\pm$  10.83, which was about 35% reduction to the mean preoperative IOP (35.09  $\pm$  10.74). This reduction was found to be statistically significant (*t*: 9.8 [95% CI: 12.93–19.69], *P* < 0.001). The mean IOP at three months was 26.23  $\pm$  8.68 mm Hg which was about 22% reduction to the mean preoperative IOP. The mean IOP at six months was 21.26  $\pm$  7.72 mm Hg which was about a 37% reduction to the preoperative IOP.

At the final follow up visit, the mean IOP was M ( $\pm$  SD) 18.77  $\pm$  7.29 mm Hg, which was a 16.33% reduction to the preoperative IOP. According to criteria of treatment outcome for IOP control, complete success was achieved in seven eyes (20%), 22 eyes (62.8%) showed qualified successes and complete failure was reported in six eyes (17.1%) while the overall success rate in 29 eyes was (82.8%).

Among our patients there were eight eyes of congenital glaucoma with a history of previous glaucoma surgeries. Four eyes were controlled after COCO without medication (50%



**Figure 2** Comparison of pre- and postoperative visual acuity. NLP: no light perception, LP: light perception, FL: follow light.

**Table 4** Postoperative short complications.

Complication	Number	Percentage (%)
Pain	2	14.3
Subconjunctival hemorrhage	2	14.3
Corneal epithelial defect	2	14.3
AC reaction	8	57.1
Choroidal	0	N/A
Visual loss	0	N/A
Phthisis bulbi	0	N/A
Sympathetic ophthalmia	0	N/A

complete success) and four other eyes showed qualified success according to our previously mentioned criteria. Postoperative mean IOP was reduced to  $16.62 \pm 4.06$  (range 16–21 mm Hg) compared to a preoperative mean IOP of  $25.37 \pm 7.02$  (range 15–35 mm Hg). Postoperative short term complications showed pain in two (5.7%) eyes during the procedure, eight (22.9%) eyes developed postoperative mild anterior chamber reaction and two (5.7%) eyes developed subconjunctival hemorrhage (Table 4). No eyes developed choroidal detachment, phthisis bulbi, or sympathetic ophthalmia till the end of follow up.

#### 4. Discussion

Cyclodestructive procedure has been used to control IOP for many years (Bietti, 1950). Diathermy and cryotherapy are associated with complications including loss of vision and phthisis bulbi (Liu et al., 1994; de Roeth, 1986; Bellows and Grant, 1978; Mc Lean and Lincoff, 1964). The development of YAG, Ruby, and Krypton lasers have been used for many years with less side effects (Beckman et al., 1972; Schuman et al., 1990, 1992; Aubry et al., 1994; Seah et al., 1994).

YAG laser showed whitening and contraction of ciliary body epithelium however, diode laser produces less blanching, deeper ciliary body contraction and coagulation.

Semiconductor diode laser (805–810 nm) is effective as it is more absorbed by melanin pigment in the ciliary body. The mechanisms of decreasing IOP by diode laser, include; destruction of ciliary epithelium, ciliary body atrophy, decrease ciliary body vasculature, increase uveoscleral outflow and decrease ciliary body epithelial surface.

In transscleral cyclophotocoagulation (CPC) the surgeon cannot directly observe the effects of the applied laser. Over dosage, may result in unwanted pop effects, or under dosage with no therapeutic effect which often occur contrary in controlled COCO. Laser radiation passing through the sclera and ciliary body is partly reflected from the fundus and can be monitored from outside the eye by a detector system, since all other parameters influencing the intensity of the recorded radiation are constant in time during one laser exposure, The time dependence of this radiation directly reflects the change of transmission of the treated tissue. The laser exposure therefore, can be stopped by computer, when certain criteria of the recorded curves are fulfilled.

COCO machine needs a special calibration before using it, followed by setting the power and transilluminator to define the exact site of ciliary body, application of laser 1.5 mm from limbus and three mm from limbus which may enhance the uveoscleral outflow according to Liu et al. (1994).

#### 5. Compared to other studies

Very few studies of COCO procedures had been published Augustin et al reported that there was no case of severe complications and that reduction of risk may allow broader application of the method (Augustin et al., 1998). Jochen Wahl et al. recommended the procedure to be taken into account as a primary intervention because of low complication rates and good pressure reducing effect (Wahl and Preussner, 2002). Moreover, Preubner demonstrated results of more than 10 years of application experience with no observed complications including no phthisis bulbi in addition to a range of pressure reduction of (20–25%) (Preubner, 2008).

Compared to other cyclodestructive procedures; Carprioli has reported 70% visual loss in cyclocryotherapy (Carprioli et al., 1985), Krupin reported 34% phthisis bulbi (Krupin et al., 1978) while Shields reported up to 46.6% visual loss in cyclophotocoagulation (Shields and Shields, 1994).

In a recent study by Nitza Cohen; 32 patients who underwent diode Cyclophotocoagulation results demonstrate controlled IOP in 62.5%, two eyes of visual loss and one eye with phthisis bulbi (Goldenberg and Bahar, 2005).

In our study the majority of cases did not show significant changes of VA (77.1%) and no patients lost their visual acuity from seeing eyes. As regards to the eight cases with previous history of congenital glaucoma, four eyes had controlled IOP without medication (complete success = 50%) and the other four were controlled with medication (qualified success = 50%), which gives an overall success rate of 100%.

We conclude that COCO procedure increases the precision and safety of trans-scleral cyclophotocoagulation (Preubner et al., 1997), it is a simple procedure, non-penetrating and with minimal side effects. It is recommended to be used in

seeing eyes. It also reduces the number of anti-glaucoma medications. With COCO procedure to the best of our knowledge, patients do not develop phthisis bulbi or sympathetic ophthalmia as feared complications.

### Disclaimer

No financial or proprietary interest in any aspect of this study.

### References

- Assia, E.L., Hennis, H.L., Stewart, W.C., et al., 1991. A comparison of neodymium:yttrium aluminum garnet and diode laser transscleral cyclophotocoagulation and cyclocryotherapy. *Invest. Ophthalmol. Vis. Sci.* 32, 2774–2778.
- Aubry, I., Aranaud, B., Reda, C., et al., 1994. Transscleral cyclophotocoagulation: result over 6 months. *J. Fr. Ophthalmol.* 17, 325–330.
- Augustin, A.J., Bonn, G.K., Krieglstein, Koln, 1998. Controlled cyclophotocoagulation. *Ophthalmologie* 95, 645–650.
- Beckman, H., Kinoshita, A., Rota, A.N., Sugar, H.S., 1972. Transscleral ruby laser irradiation of the ciliary body in the treatment of intractable glaucoma. *Trans. Am. Acad. Ophthalmol. Otolaryngol.* 76, 423–436.
- Bellows, A.R., Grant, W.M., 1978. Cyclocryotherapy in chronic open angle glaucoma in aphakic eyes. *Am. J. Ophthalmol.* 85, 615–621.
- Benson, M.T., Nelson, M.E., 1990. Cyclocryotherapy: a review over a 10-year period. *Brit. J. Ophthalmol.* 74, 103–105.
- Bietti, G., 1950. Surgical intervention on the ciliary body, new trend for the relief of glaucoma. *JAMA* 142, 889–897.
- Brancato, R., Leoni, G., Trabucchi, G., Cappellini, A., 1991. Histopathology of continuous wave neodymium:yttrium aluminum garnet and diode laser contact transscleral lesions in rabbit ciliary body. A comparative study. *Invest. Ophthalmol. Vis. Sci.* 32, 1586–1592.
- Brancato, R., Carassa, R.G., Bettin, P., et al., 1995. Contact transscleral cyclophotocoagulation with diode laser in refractory glaucoma. *Eur. J. Ophthalmol.* 5, 32–39.
- Brindley, G., Shields, M.B., 1968. Value and limitation of cyclocryotherapy. *Graef. Arch. Clin. Exp. Ophthalmol.* 224, 545–548.
- Carprioli, J., Strang, S.L., Spaeth, G.L., et al., 1985. Cyclocryotherapy in the treatment of advanced glaucoma. *Ophthalmology* 92, 947–952.
- de Roeth Jr., A., 1986. Cryotherapy for treatment of advanced chronic simple glaucoma. *Am. J. Ophthalmol.* 66, 1034–1041.
- Egbert, P.R., Fiadoyor, S., Budenz, D.L., et al., 2001. Diode laser transscleral cyclophotocoagulation as a primary surgical treatment for primary open angle glaucoma. *Arch. Ophthalmol.* 119, 345–350.
- Frankhauser, H., Kwasniewska, S., 1993. The role of laser cyclophotocoagulation in cyclodestructive glaucoma surgery. *Curr. Opin. Ophthalmol.* 4, 79–84.
- Goldenberg, Nitzza, Bahar, Irit, et al., 2005. Cyclotherapy versus transscleral diode laser cyclophotocoagulation for uncontrolled intraocular pressure. *Ophthalmic surgery. Laser Imaging* 36, 272–279.
- Hawkins, T.A., Stewart, W.C., 1993. One year result of semiconductor transscleral cyclophotocoagulation in patient with glaucoma. *Arch. Ophthalmol.* 111, 488–491.
- Hennis, H.L., Stewart, W.C., 1992. Semiconductor diode laser transscleral cyclophotocoagulation in patients with glaucoma. *Am. J. Ophthalmol.* 133, 81–85.
- Kosoko, O., Goasterland, D.E., Pollack, I.P., et al., 1996. Long-term outcome of initial ciliary ablation with contact diode laser transscleral cyclophotocoagulation for severe glaucoma. The diode laser ciliary body study group. *Ophthalmology* 103, 1294–1302.
- Krupin, T., Mitchell, K.B., Becker, B., 1978. Cyclocryotherapy in neovascular glaucoma. *Am. J. Ophthalmol.* 86, 24–26.
- Liu, G.J., Mizukawa, A., Okisaka, S., 1994a. Mechanism of intraocular pressure decrease after contact transscleral continuous-wave ND:YAG Laser cyclophotocoagulation. *Ophthalmic Res.* 26, 65–79.
- Liu, G.J., Mizukawa, A., Okisaka, S., 1994b. Mechanism of intraocular pressure decrease after contact transscleral continuous-wave ND:YAG laser cyclophotocoagulation. *Ophthalmic Res.* 26, 65–79.
- Mc Lean, J.M., Lincoff, H.A., 1964. Cryotherapy of ciliary body. *Trans. Am. Ophthalmol. Soc.* 62, 385–407.
- Mistlberger, A., Liebmann, J.M., et al., 2001. Diode laser transscleral cyclophotocoagulation for refractory glaucoma. *J. Glaucoma* 10, 288–293.
- Peyman, G.A., Naguib, K.S., Gaasterland, D., 1990. Trans-scleral application of a semiconductor diode laser. *Lasers Surg. Med.* 10, 569–575.
- Preubner, P.-R., 2008. Controlled cyclophotocoagulation (COCO). *Spekt. Augenheilkd.* 22 (4), 247–251.
- Preubner, P.-R., Boos, N., Fassbender, K., et al., 1997. Real time control for transscleral cyclophotocoagulation. *Graef. Arch. Clin. Exp. Ophthalmol.* 235, 794–801.
- Schuman, J.S., Puliafito, C.A., Allingham, R.R., et al., 1990. Contact transscleral continuous wave neodymium:YAG laser cyclophotocoagulation. *Ophthalmology* 97, 571–580.
- Schuman, J.S., Bellows, A.R., Shingleton, B.J., et al., 1992. Contact transscleral ND:YAG Laser cyclophotocoagulation. Midterm result. *Ophthalmology* 99, 1089–1094.
- Seah, S.K., Jap, A., Geh, M., 1994. Contact transscleral cyclophotocoagulation for end stage glaucoma. *Ann. Acad. Med. Singapore* 23, 18–20.
- Shields, M.B., Shields, S.E., 1994. Noncontact transscleral ND:YAG cyclophotocoagulation: a long term follow-up of 500 patients. *Trans. Am. Ophthalmol. Soc.* 92, 271–283 (discussion 283–7).
- Threlkeld, A.B., Johnson, M.H., 1999. Contact transscleral diode cyclophotocoagulation for refractory glaucoma. *J. Glaucoma* 8, 3–7.
- Ulbis, M.W., McHugh, D.A., McNaught, A.L., et al., 1995. Clinical comparison of semiconductor diode laser versus neodymium:YAG non contact cyclophotocoagulation. *Brit. J. Ophthalmol.* 79, 569–574.
- Vogt, A., 1936. Veruche zur intraokularen druckherabsetzung mittelst diathermieschadigung des corpus ciliare (Zyklodiatheriestichelung). *Klim. Monatsbl. Augenheilkd.* 97, 672–673.
- Wahl, J., Preussner, P.-R., 2002. Controlled cyclophotocoagulation. *Med. Laser Appl.* 17, 341–346.
- Weekers, R., Laverne, G., Watillon, M., et al., 1961. Effects of photo-coagulation of the ciliary body upon ocular tension. *Am. J. Ophthalmol.* 52, 156–163.