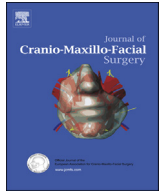

Contents lists available at [SciVerse ScienceDirect](http://www.sciencedirect.com)

Journal of Cranio-Maxillo-Facial Surgery

journal homepage: www.jcmfs.com

Evaluation of bone regenerative capacity following distraction osteogenesis of goat mandibles using two different bone cutting techniques

Nasser Nooh^{a,b,*}, Walid A. Abdullah^{a,c}, Mohammed El-Awady Grawish^{d,e},
Sundar Ramalingam^a, Ghada Hassan^f, Fawad Javed^{g,b}, Khalid Al-Hezaimi^{g,b}

^a Department of Oral and Maxillofacial Surgery, College of Dentistry, King Saud University, PO Box 60169, Riyadh 11545, Saudi Arabia

^b Engineer Abdullah Bugshan Research Chair for Growth Factors and Bone Regeneration, 3D Imaging and Biomechanical Lab, College of Biomedical Applied Science, King Saud University, Saudi Arabia

^c Department of Oral and Maxillofacial Surgery, Faculty of Dentistry, Mansoura University, Mansoura, Egypt

^d Oral Medicine and Diagnostic Science, College of Dentistry, King Saud University, Riyadh, Saudi Arabia

^e Department of Oral Biology, Faculty of Dentistry, Mansoura University, Mansoura, Egypt

^f Oral Biology, Dental Health Department, College of Applied Medical Sciences, King Saud University, Saudi Arabia

^g Department of Periodontics and Community Dentistry, College of Dentistry, King Saud University, Riyadh, Saudi Arabia

ARTICLE INFO

Article history:

Paper received 9 February 2013

Accepted 7 May 2013

Keywords:

Vertical body osteotomy
Sagittal split osteotomy
Distraction osteogenesis
Micro-CT
Histology
Mandible

ABSTRACT

Purpose: To compare the regenerative capacity of goat mandibles following sagittal split osteotomy and distraction osteogenesis with a vertical body osteotomy.

Animals and methods: Bilateral vertical and sagittal body osteotomy was performed on the left and right sides of the mandibles in 18 goats. The distraction period lasted for 10 days at 1 mm/day. Animals were sacrificed at 0, 10, and 35 days post-distraction. Bone mineral density (BMD) and bone volume (BV) were analysed by microcomputed tomography (MCT). Types of bone and cells present in the regenerated defect sites were analysed histologically.

Results: At 0, 10, and 35 days, BMD was 0.358 ± 0.012 , 0.410 ± 0.012 , and 1.070 ± 0.019 , respectively, for vertical osteotomy and 0.420 ± 0.013 , 0.421 ± 0.009 and 1.182 ± 0.030 , respectively, for sagittal osteotomy. BV was 973.310 ± 5.048 , 1234.589 ± 4.159 , and 2121.867 ± 6.519 , respectively, for vertical osteotomy and 995.967 ± 2.781 , 1755.938 ± 4.379 , and 2618.441 ± 21.429 , respectively, for sagittal osteotomy at these three time points. BMD and BV differed significantly at all three times. Histological analysis shows that sagittal splitting was characterized by more robust lamellar bone formation bridging the distraction gap than vertical body osteotomy.

Conclusion: Both MCT and histological analyses showed that distraction using the sagittal osteotomy technique resulted in significantly higher BV and BMD than using vertical body osteotomy.

© 2013 European Association for Cranio-Maxillo-Facial Surgery. Published by Elsevier Ltd. All rights reserved.

1. Introduction

Distraction osteogenesis (DO) is a surgical technique used to generate new bone in the area between two vascularized bone surfaces that are gradually separated mechanically by a distractor (Figuerola and Polley, 2002). DO is frequently used in the treatment

of bony loss, pseudoarthrosis, and chronic osteomyelitis, and for biological reconstruction after wide tumour resection and deformity, and limb length discrepancy (Nakase et al., 2007). DO is widely used for the repair of human calvarial defects (Cho-Lee et al., 2010), to correct oral and maxillofacial deformities (Park et al., 2011), for the treatment of micrognathia, obstructive sleep apnoea syndrome (Shang et al., 2012), transverse mandibular discrepancies (de Gijt et al., 2012), and large cleft alveolus and palate reconstruction (Rachmiel et al., 2013).

Ilizarov's (1989) technique of DO consists of four steps. In the first, a cut (osteotomy) is made around the perimeter of the bone requiring elongation. In the second step, a rigid fixator (distractor)

* Corresponding author. Engineer Abdullah Bugshan Research Chair for Growth Factors and Bone Regeneration, 3D Imaging and Biomechanical Lab, College of Biomedical Applied Science, King Saud University, Riyadh, Saudi Arabia. Tel.: +966 (0) 504253820; fax: +966 (0) 4695892.

E-mail address: nassernoohomfs@gmail.com (N. Nooh).

is applied, followed by a latency period of 5–7 days for initial healing. In the third step, distraction forces are gradually delivered, and, in the fourth step, the newly formed bone is allowed to consolidate (regenerate) while the fixator remains in place (Ilizarov, 1989). Mandibular distraction osteogenesis (MDO) is used to treat a variety of craniofacial disorders ranging from simple asymmetries to hypoplasia of the entire mandible (Mandell et al., 2004). Various MDO procedures, using different types of distraction devices, have been tested in animal and clinical studies (Snyder et al., 1973; McCarthy et al., 1992; Perrott et al., 1993; Al Ruhaimi, 2000). In addition, more sophisticated devices have since been developed to improve the results of mandibular lengthening (Choi et al., 2001).

Osteotomy of the mandible is a common procedure performed in orthognathic surgery. During the early development of orthognathic surgery, subcondylar osteotomy, horizontal osteotomy of the ramus and mandibular body or step osteotomy were used to treat mandibular prognathism (Bell et al., 1980). Bilateral sagittal split osteotomy (BSSO) was initially introduced as a surgical treatment of mandibular prognathism (Trauner and Obwegeser, 1957). Several modifications have been found to reduce morbidity and improve stability (Dal Pont, 1961); but complications of these procedures include up to 75% loss of function of the inferior alveolar nerve, 1 year after surgery (Schreuder et al., 2007).

Although various osteotomy techniques were developed after Ilizarov's technique, none has been shown to be optimal for the formation and remodelling of bone in patients with DO (Ilizarov and Shreiner, 1979; Brutscher et al., 1993; Frierson et al., 1994; Krawczyk et al., 2007). We have used microcomputed tomography (MCT) and histological analysis to evaluate the amount of bone generation following sagittal split osteotomy and DO, compared with vertical body osteotomy, in goat mandibles.

2. Materials and methods

2.1. Ethical guidelines

The present study was approved by the College of Dentistry Research Centre Ethical Consideration for Animals, in conformity with the NIH-guidelines for the care and use of laboratory animals (NIH Publication #85-23 Rev.1985).

2.2. Preparation of animals

Eighteen male goats, with a mean body weight of 24 ± 2.2 kg and mean age of 18 ± 1.5 months, were kept in the animal holding facility in the Laboratory Animal Center of King Khalid University Hospital, King Saud University, under veterinary supervision.

2.3. Surgical operations

The goats were anaesthetized by intramuscular injection of xylazine (5 mg/kg, Lloyd Laboratories, Shenandoah, IA, USA), acepromazine (1.5 mg/kg, Vedco, St. Joseph, MO, USA), and ketamine (20 mg/kg, Sigma Chemical, St. Louis, MO, USA). Following the subcutaneous injection of 1.8 mL of local anaesthetic (lidocaine 2%, Parhawk Laboratories, Inc., Lenexa, KS, USA) into the surgical area (Long et al., 2009), a 5 cm horizontal incision was made along the inferior border of the mandible using a surgical blade (No. 15) held on a Brad–Parker blade handle number 3 (Fig. 1a).

2.4. Distraction protocol

After reflection of the periosteum, the distractor devices (Arnaud-Marchac cranial monobl, KLS Martin, Tuttlingen, Germany) were adapted to fit the bone. Using Ilizarov's technique

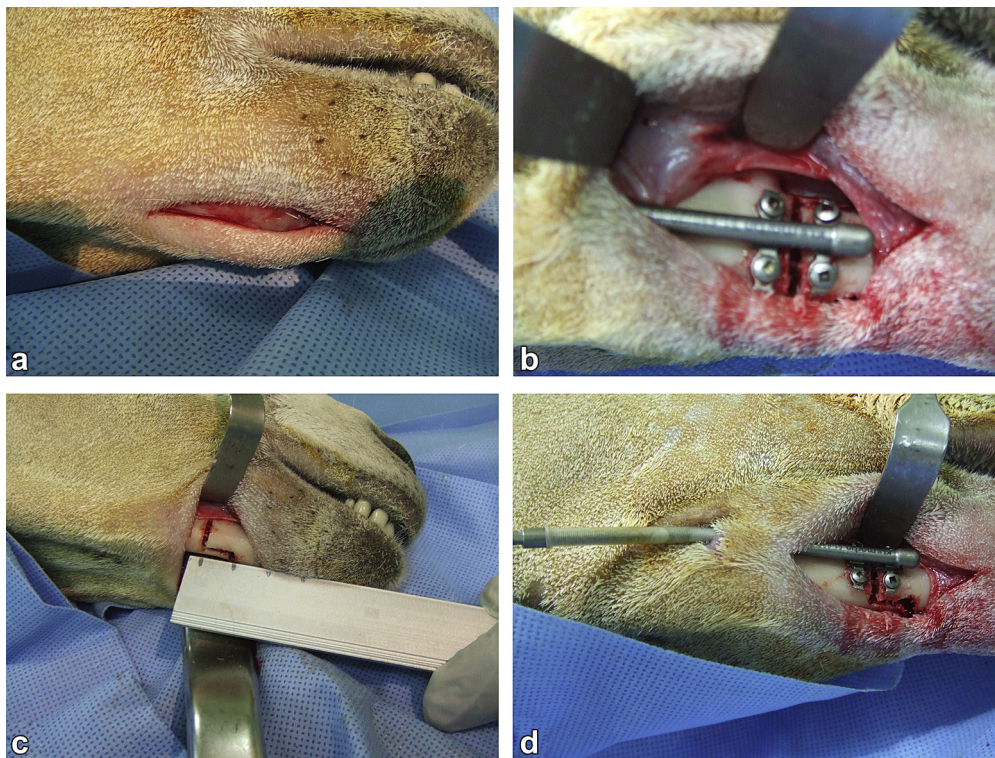


Fig. 1. Photographs showing the horizontal incision along the inferior border of the mandible (a), vertical osteotomy with the distraction device in place (b), the sagittal split osteotomy with a 1 cm width between the lateral and medial cuts (c) and the distraction device on the lateral border of the mandible (d).

(Ilizarov and Shreiner, 1979), the cortical bone was cut on the lateral side of the mandibular edentulous area, with the distractor installed prior to the completion of bone cutting to mark the position of the screws. Following completion of the cuts, the distractor was secured on the edentulous area of the left side of the mandible (Fig. 1b). On the right side, sagittal splitting of the bone was performed, with a distance of 1 cm between the medial and lateral cuts (Fig. 1c and d). The distractor was inserted prior to the completion of bone cutting to mark the position of screws. Following completion of the cuts, the distractor was secured.

The initial gap between the two bone segments was standardized at a width of 2 mm. The wounds were closed in layers, using 3/0 vicryl (Ethicon; Johnson & Johnson Intel. Belgium) for the deep layers and 3/0 silk (Ethicon; Johnson & Johnson Intel. Scotland) for the skin. In all animals, distraction was started bilaterally after a 5-day latency period. The distraction period lasted for 10 days, at 1 mm/day. Six animals each were sacrificed at the end of the distraction period and 10 and 35 days later.

2.5. MCT analysis

Following euthanasia, the mandibles were dissected, sectioned into halves and fixed in 10% formaldehyde. Subsequently, the specimens were wrapped in parafilm (Brand GMBH, Germany) to prevent drying during scanning. All samples were scanned at an energy of 100 kV and an intensity of 343 μ A with a resolution of 12.39 μ m pixels using an aluminium filter (1 mm) (SkyScan 1176 high resolution in vivo X-ray microtomograph, Kontich, Belgium). The rotation step was 0.6° and the exposure time was 15–20 min. The frame averaging was 4 while the tomographic rotation was 1800 and the camera was adapted as standard (1000 pixel field width). Projection images of cone-beam acquisition and reconstruction were saved as 16 bit TIF files. All scanning and reconstruction parameters were identical for all specimens and calibrations. After the scan, a control computer with Windows 7, 64 bit version, launched NRecon reconstruction software, data Viewer scan viewing software and the CT-Analyzer analysis program.

The parameters acquired via MCT were bone volume (BV, mm^3) and bone mineral density (BMD, g/cm^3) of mineralized tissue within the region of interest (ROI). BV was defined as the volume of mineralized tissue formed at the defect site during healing (Parfitt et al., 1987; Anderson et al., 1999; Ott, 2008); and BMD was defined as the density of mineralized tissue within the volume of interest, and is an indicator of the quality of mineralized tissue (Parfitt et al., 1987; Anderson et al., 1999; Ott, 2008).

Following MCT analysis, the ROIs for BV (sites of new bone formation between the osteotomy edges) were identified using the computer programme. The area of new bone formed was measured in each section of the MCT scan and the product of the measured area and the slice thickness of the scan section was the BV in that particular scan section. The sum of the BVs of each section was calculated to determine the total BV of new bone formed. To calculate the BMD of the newly formed bone between the osteotomy edges, eight representative sites were selected from the specimen as the ROI, four selected sites on the buccal side and four on the lingual side of the specimen. Each site was selected to represent either the superior or the inferior aspect of the proximal and distal portions of the distracted bone, 2 mm away from the osteotomy edges. The mean of the individual BMD obtained from each site was calculated to obtain the total BMD of new bone formed.

2.6. Specimen processing and histological evaluation

The specimens were fixed in 10% neutral buffered formalin and decalcified by immersion in formic acid sodium citrate solution

(1 M/L sodium citrate in 45% formic acid) for 5 weeks. The decalcified bone was trimmed with a sharp scalpel blade, such that the specimen included the proximal and distal ends of the distraction gap with safety borders of about 1 mm. The specimens were embedded in paraffin and 5- μ m thick serial sections were stained with haematoxylin and eosin.

2.7. Statistical analysis

BV and BMD were compared by two-way analysis of variance (ANOVA) followed by the least significant difference (LSD) post-hoc test. The factors for ANOVA were examination periods (i.e. 0, 10, and 35 days after the end of treatment) and type of osteotomy (i.e. sagittal split osteotomy and vertical body osteotomy), with LSD post-hoc tests performed only for the former. A P -value <0.05 was

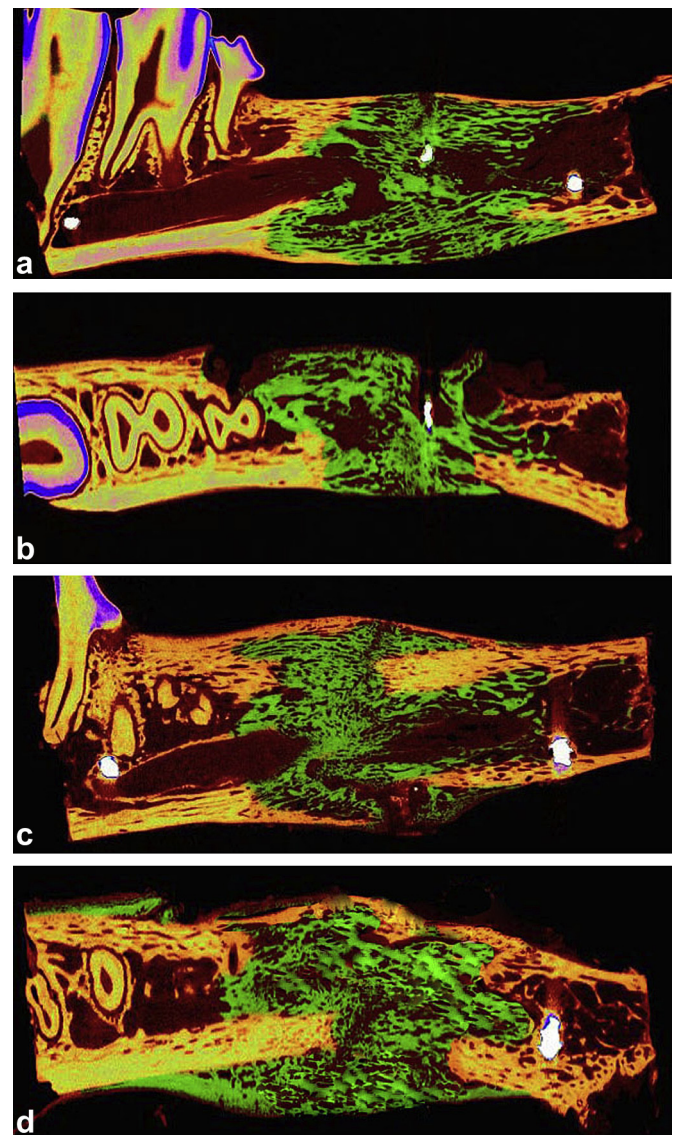


Fig. 2. MCT images reconstructed for distraction gaps of goat mandibles 35 days after the end of distraction, showing the amount of newly formed bone trabeculae (green) in the gap between the proximal and distal fractured ends. The old and remodelled bones are coloured yellow, while the medullary cavities and soft structures are coloured brown. The upper images represent vertical osteotomy while the lower images represent sagittal splitting. The views in (a) and (c) were reconstructed in sagittal plane while the views in (b) and (d) were reconstructed in the axial plane.

considered statistically significant. All statistical analyses were performed using SPSS for Windows, version 16 (SPSS; Chicago, IL, USA).

3. Results

3.1. MCT results

The MCT results were in accordance with our histological findings. The reconstructed axial and sagittal images of the specimens acquired 35 days after the end of distraction showed that sagittal splitting resulted in greater amounts of newly formed bone, consolidation with signs of neocortilization and callus remodelling at the distraction gap between the proximal distal ends than did vertical body osteotomy (Fig. 2a–d).

Two-way ANOVA showed that BV was significantly correlated with the examination periods and the type of osteotomy used ($P < 0.0001$ each) (Table 1). We also observed a significant interaction between the type of osteotomy and the time after distraction with respect to BV ($P < 0.0001$) (Fig. 4).

An LSD post-hoc test for multiple comparisons showed that BV differed significantly on the sagittal splitting and vertical body osteotomy sides at each examination period (i.e. 0, 10, and 35 days after the end of distraction) (Table 1). Two-way ANOVA also showed that BMD differed significantly with respect to examination period and type of osteotomy ($P < 0.0001$). We also observed a significant interaction between type of osteotomy and time after distraction with respect to BMD ($P < 0.0001$) (Table 2, Fig. 5). An LSD post-hoc test for multiple comparisons showed that BMD differed significantly on the sagittal splitting and vertical body osteotomy sides at each examination period (Table 2).

Table 1

Two-way ANOVA and LSD post-hoc test for BV (mm^3) and their statistical significance.

| Two-way ANOVA (<i>F</i> ratio and <i>P</i> -value) | | | LSD post-hoc test | | |
|---|--------------------------|--|--------------------------|---------------------|--------------------------------|
| Type of osteotomies | Examination periods | Type of osteotomies \times Examination periods | Distraction groups | Examination periods | Mean (S.D.) |
| 9474.651 (<0.0001) | 51,552.330 (<0.0001) | 2073.349 (<0.0001) | Vertical osteotomy | End of distraction | 973.310 (5.048) ^a |
| | | | | 10 days | 1234.589 (4.159) ^a |
| | | | | 35 days | 2121.867 (6.519) ^a |
| | | | Sagittal split osteotomy | End of distraction | 995.967 (2.781) ^a |
| | | | | 10 days | 1755.938 (4.379) ^a |
| | | | | 35 days | 2618.441 (21.429) ^a |

^a The mean difference is significant at the 0.05 level.

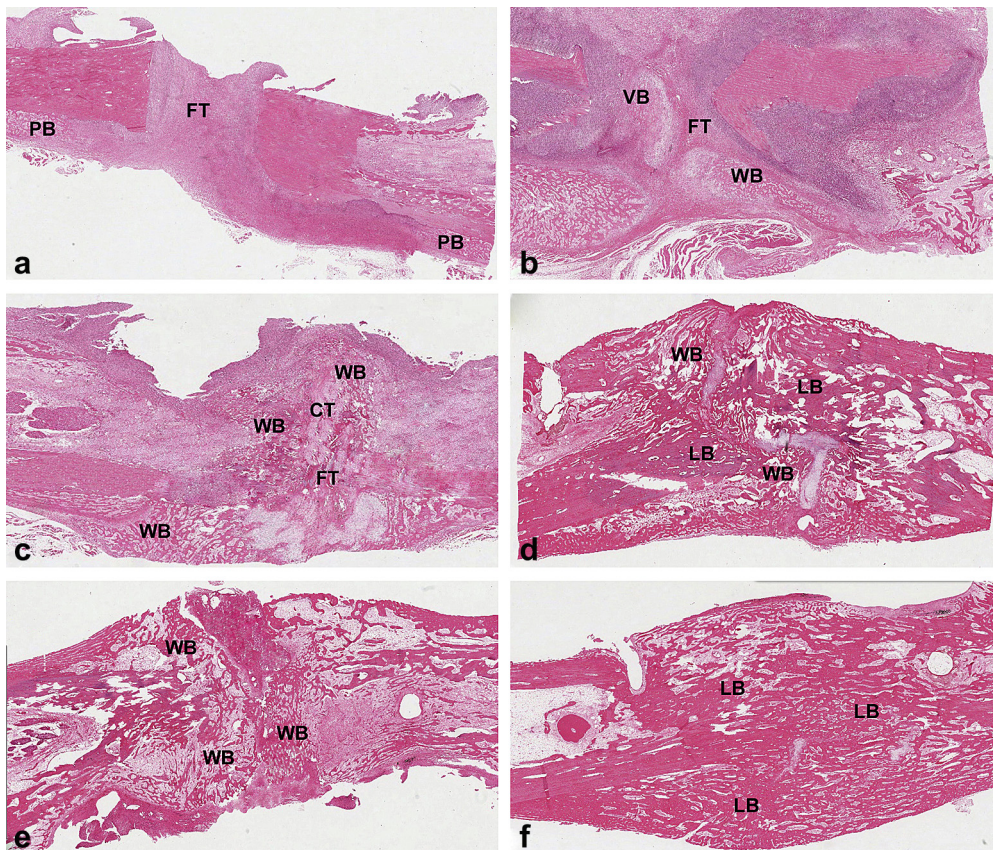


Fig. 3. Histological assessment of bone healing during splitting and DO. Representative H & E 100 \times micrographs of sections depicting the gap regions localized between the proximal and distal ends of the osteotomy are presented. Vertical osteotomies at the end of the distraction period (a) and 10 (c) and 35 (f) days later are represented by (a), (c) and (f); sagittal splitting at the end of the distraction period (b) and 10 (d) and 35 days (e). Fibrous tissue (FT), woven bone (WB), lamellar bone (LB), cartilaginous tissue (CT), periosteal bone (PB).

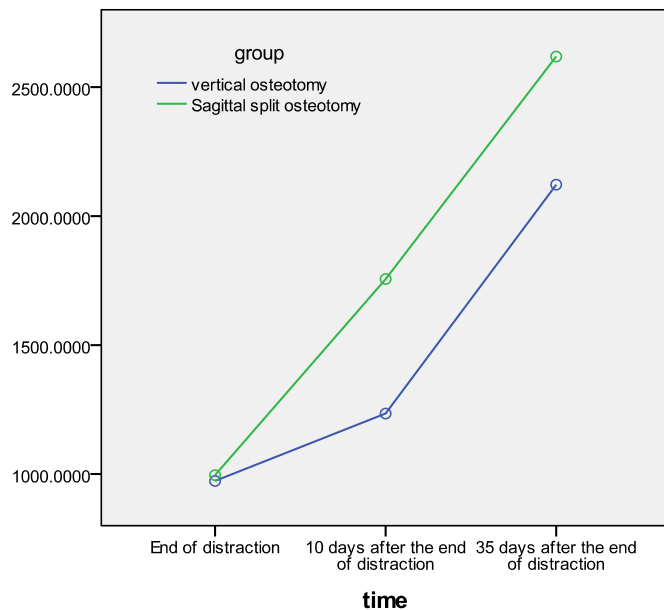


Fig. 4. Line chart histogram showing the interaction between the groups at the different examination periods relative to BV (mm³).

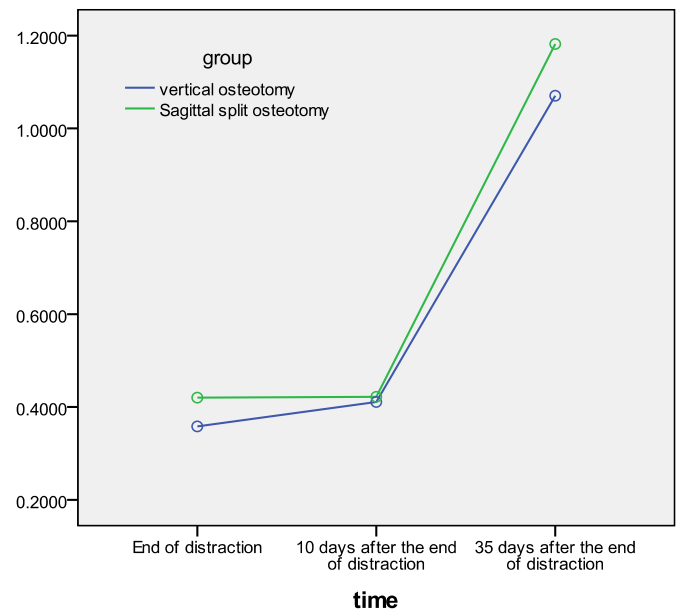


Fig. 5. Line chart histogram showing the interaction between the groups at the different examination periods relative to BMD (g/cm³).

Table 2

Two-way ANOVA for BMD and LSD post-hoc test for BMD (g/cm³) and their statistical significance.

| Two-way ANOVA (F ratio and P-value) | | | LSD post-hoc test | | |
|-------------------------------------|---------------------|---|--------------------------|---------------------|----------------------------|
| Type of osteotomies | Examination periods | Type of osteotomies × Examination periods | Distraction groups | Examination periods | Mean (S.D.) |
| 90.316 (<0.0001) | 5553.605 (<0.0001) | 20.014 (<0.0001) | Vertical osteotomy | End of distraction | 0.358 (0.012) ^a |
| | | | | 10 days | 0.410 (0.012) ^a |
| | | | | 35 days | 1.070 (0.019) ^a |
| | | | Sagittal split osteotomy | End of distraction | 0.420 (0.013) ^a |
| | | | | 10 days | 0.421 (0.009) ^a |
| | | | | 35 days | 1.182 (0.030) ^a |

^a The mean difference is significant at the 0.05 level.

3.2. Histological findings

None of the goats showed any evidence of morbidity or infection following surgery. At the end of the distraction period, the vertical body osteotomy fracture gaps showed a central zone of fibrous tissue proliferation, along with periosteal bone calluses around the ends of the fractured bone segments (Fig. 3a), whereas the sagittal split osteotomy fracture gaps showed a central zone of fibrous tissue rich in chondrocyte-like cells, fibroblasts, and oval cells that were morphologically intermediate between fibroblasts and chondrocytes (Fig. 3b). The proximal and distal zones showed the development of newly woven bone rimmed by osteoblasts adjacent to the bone edges and around the fractured ends (Fig. 3b). Ten days later, the vertical body osteotomy fracture gaps showed fibrous tissue from the central zone growing towards the proximal and distal ends and subsequently replaced by woven bone with areas of cartilaginous tissue (Fig. 3c). The ends of the sagittal splitting osteotomy fracture gaps showed the remodelling of woven bone as well as cartilage into lamellar bone (Fig. 3d). The volume of newly formed callus in the regenerated bone parallel to the vector of distraction was higher in the sides that underwent sagittal splitting than in the sides that underwent vertical body osteotomy. After 35 days, the sagittally split sides showed greater evidence of robust lamellar bone formation bridging the distraction gap than the vertical body sides. The regenerating bone on the sagittally split sides showed completion of consolidation with signs of

neocortilization and callus remodelling (Fig. 3e), whereas the sides that underwent vertical body osteotomy did not fully consolidate (Fig. 3f).

4. Discussion

Determining the appropriate animal model for experimental craniofacial DO is essential for the success of the experimental design. Since the rate and potential for bone repair have been shown to be inversely related to the evolutionary scale and age of the animal, the choice of animal model may have a pronounced effect on the results (Bardach and Kelly, 1988). Although goat bones differ physiologically from human bones, as they do not undergo normal haversian remodelling, they have been widely used in orthopaedic research (An and Friedman, 1998). The goat has been found to be a suitable animal model for testing human implants and materials, as goats and humans have similar metabolic and bone remodelling rates (Anderson et al., 1999). For DO, the goats were used as animal models to compare the transport distraction versus costochondral graft for reconstruction of temporomandibular joint ankylosis (Cheung et al., 2009), in the reconstruction of condylar osteochondral defect using DO combined with tissue-engineered cartilage (Yu et al., 2011), to investigate the feasibility of using an internal bidirectional mandibular distractor to elongate the mandibular bodies and rami (Lin et al., 2012).

The optimal osteotomy technique in DO for the formation and remodelling of bone regeneration is unclear, as is the postoperative stability of the mandible after bilateral lengthening by BSSO (Schendel and Linck, 2004; Krawczyk et al., 2007; Schreuder et al., 2007). Assessment of the postoperative stability of the mandible after bilateral lengthening showed no difference between BSSO or DO after 4 years (Baas et al., 2012). In contrast, sagittal split ramus osteotomy was reported to result in greater callus stability (Choi et al., 2001). The amount of callus tissue has been considered the key factor for successful distraction, with the area of osteotomy interface being much larger in BSSO than in vertical osteotomy, resulting in the formation of a larger amount of callus (Sahoo and Rangarajan, 2011). Our histologic and MCT findings support the latter results.

The surgical results of sagittal splitting were mainly evaluated using X-rays, such as orthopantomograms. Since this method does not allow a precise analysis of the split pattern (Plooij et al., 2009), the morphology of the forming and remodelled regenerating tissue can best be assessed histologically. Our histological results indicate that, following sagittal splitting and DO, new bone was formed through a cascade of cellular events. This bone was of intramembranous or endochondral type and formed parallel to the direction of pull, maturing into lamellar bone following the end of distraction and during the consolidation period. These results support clinical findings in 20 patients, showing that, after 24 months, mandibular body distraction with BSSO was a better option than distraction with vertical osteotomy (Sahoo and Rangarajan, 2011). Sagittal splitting was found to allow the immediate rotation and lengthening of the proximal segment while still providing a large surface interface for bone regeneration (Schendel and Linck, 2004).

Although we observed a significant association between type of osteotomy and examination periods with respect to BV, this interaction may have been due to the small difference in BV between the two types of osteotomy at the end of the distraction period. We also observed a significant association between type of osteotomy and examination period with respect to BMD, but this may also be due to the small difference in BMD between the two types of osteotomy 10 days after the end of the distraction period.

At each examination period, we found that the mean BV at the distraction gap and its mean BMD were significantly greater on the side that underwent sagittal splitting and DO than on the side that underwent vertical osteotomy and DO. Thus, as expected, we found that sagittal splitting significantly improved the regenerative capacity of the gap between the distraction ends. This is in agreement with a previous study, which demonstrated long-term osseous healing in the cleavage space between bone fragments 2 years after sagittal splitting ramus osteotomy (SSRO) surgery, indicating that remodelling between bone fragments is a major mechanism of osseous healing after SSRO (Hasegawa et al., 2011).

5. Conclusion

To our knowledge, this study is the first to evaluate new bone formation after DO in animal models. Our results indicate that sagittal split osteotomy was associated with a better regenerative capacity than vertical body osteotomy, possibly due to the large overlapping surfaces of the split segments. The significant increase in the volumes of newly formed bone and in its mineral density resulted in increased consolidation following sagittal split osteotomy.

Sources of support in the form of grants

Not funded.

Conflict of interest

The authors have no conflicts of interest to declare.

Acknowledgement

Special acknowledgement for the College of Dentistry Research Center (CDRC), King Saud University, Saudi Arabia for the approval of this research as a non-funded research no. FR 0002.

References

- Al Ruhaimi KA: A submerged osteodistractor device: an innovative technique for experimental animal studies. *J Craniofac Surg* 11: 59–61, 2000
- An YH, Friedman RJ: Animal models of orthopedic implant infection. *J Invest Surg* 11: 139–146, 1998
- Anderson ML, Dhert WJ, de Bruijn JD, Dalmeijer RA, Leenders H, van Blitterswijk CA, et al: Critical size defect in the goat's os ilium. A model to evaluate bone grafts and substitutes. *Clin Orthop Relat Res* 364: 231–239, 1999
- Baas EM, Pijpe J, de Lange J: Long term stability of mandibular advancement procedures: bilateral sagittal split osteotomy versus distraction osteogenesis. *Int J Oral Maxillofac Surg* 41: 137–141, 2012
- Bardach J, Kelly KM: Role of animal models in experimental studies of craniofacial growth following cleft lip and palate repair. *Cleft Palate J* 25: 103–113, 1988
- Bell WH, White RP, Hall HD: Mandibular excess. In: Bell WH, Proffit WR, White RP (eds), *Surgical correction of dentofacial deformities*, vol. 2. Philadelphia: WB Saunders Co., 844–1013, 1980
- Brutscher R, Rahn BA, Ruter A, Perren SM: The role of corticotomy and osteotomy in the treatment of bone defects using the Ilizarov technique. *J Orthop Trauma* 7: 261–269, 1993
- Cheung LK, Zheng LW, Ma L, Shi XJ: Transport distraction versus costochondral graft for reconstruction of temporomandibular joint ankylosis: which is better? *Oral Surg Oral Med Oral Pathol Oral Radiol Endod* 108: 32–40, 2009
- Cho-Lee GY, Naval-Gías L, González-García R, Martos-Díaz PL, Muñoz-Guerra MF, Sastre-Pérez J, et al: Bifocal transport osteogenesis for the reconstruction of adult calvarial defects: a new surgical technique. *J Craniomaxillofac Surg* 38: 368–373, 2010
- Choi JY, Hwang KG, Baek SH, Lee JH, Kim TW, Kim MJ, et al: Original sagittal split osteotomy revisited for mandibular distraction. *J Craniomaxillofac Surg* 29: 165–173, 2001
- Dal Pont G: Retromolar osteotomy for the correction of prognathism. *J Oral Surg Anesth Hosp Dent Serv* 19: 42–47, 1961
- de Gijt JP, Vervoorn K, Wolvius EB, Van der Wal KG, Koudstaal MJ: Mandibular midline distraction: a systematic review. *J Craniomaxillofac Surg* 40: 248–260, 2012
- Figueroa AA, Polley JW: Mandibular distraction osteogenesis. *Op Tech Otolaryngol Head Neck Surg* 13: 17–28, 2002
- Frierson M, Ibrahim K, Boles M, Bote H, Ganey T: Distraction osteogenesis. A comparison of corticotomy techniques. *Clin Orthop Relat Res* 301: 19–24, 1994
- Hasegawa T, Tateishi C, Uchida R, Nishi C, Furudoi S, Shibuya Y, et al: Osseous healing after a sagittal splitting ramus osteotomy. *Int J Oral Maxillofac Surg* 40: 475–482, 2011
- Ilizarov GA, Shreiner AA: A new method of closed flexion osteoclasis (experimental study). *Ortop Travmatol Protez* 1: 9–14, 1979
- Ilizarov GA: The tension-stress effect on the genesis and growth of tissues: part II. The influence of the rate and frequency of distraction. *Clin Orthop Relat Res* 239: 263–285, 1989
- Krawczyk A, Kuropka P, Kurysko J, Wall A, Dragan S, Kulej M: Experimental studies on the effect of osteotomy technique on the bone regeneration in distraction osteogenesis. *Bone* 40: 781–791, 2007
- Lin X, Zhou L, Shang H, Liu Y, Bo B: Use of an internal bidirectional distractor to elongate goats' mandibles. *Br J Oral Maxillofac Surg* 50: e49–e52, 2012
- Long J, Tang W, Fan YB, Tian WD, Feng F, Liu L, et al: Effects of rapid distraction rate on new bone formation during mandibular distraction osteogenesis in goats. *Injury* 40: 831–834, 2009
- Mandell DL, Yellon RF, Bradley JP, Izadi K, Gordon CB: Mandibular distraction for micrognathia and severe upper airway obstruction. *Arch Otolaryngol Head Neck Surg* 130: 344–348, 2004
- McCarthy JG, Schreiber J, Karp N, Thorne CH, Grayson BH: Lengthening the mandibular body by gradual distraction. *Plast Reconstr Surg* 89: 1–10, 1992
- Nakase T, Yasui N, Kawabata H, Shimizu N, Ohzono K, Hiroshima K, et al: Correction of deformity and shortening due to post traumatic epiphyseal arrest by distraction osteogenesis. *Arch Orthop Trauma Surg* 127: 659–663, 2007
- Ott SM: Histomorphometric measurements of bone turnover, mineralization, and volume. *Clin J Am Soc Nephrol* 3(Suppl. 3): S151–S156, 2008
- Parfitt AM, Drezner MK, Glorieux FH, Kanis JA, Malluche H, Meunier PJ, et al: Bone histomorphometry: standardization of nomenclature, symbols, and units. Report of the ASBMR Histomorphometry Nomenclature Committee. *J Bone Miner Res* 2: 595–610, 1987
- Park JT, Lee JG, Kim SY, Kim GH, Hu KS, Cha JY, et al: A piezoelectric motor-based microactuator-generated distractor for continuous jaw bone distraction. *J Craniofac Surg* 22: 1486–1488, 2011

- Perrott DH, Berger R, Vargervik K, Kaban LB: Use of a skeletal distraction device to widen the mandible: a case report. *J Oral Maxillofac Surg* 51: 435–439, 1993
- Plooi JM, Naphausen MT, Maal TJ, Xi T, Rangel FA, Swennnen G, et al: 3D evaluation of the lingual fracture line after a bilateral sagittal split osteotomy of the mandible. *Int J Oral Maxillofac Surg* 38: 1244–1249, 2009
- Rachmiel A, Emodi O, Gutmacher Z, Blumenfeld I, Aizenbud D: Oral and dental restoration of wide alveolar cleft using distraction osteogenesis and temporary anchorage devices. *J Craniomaxillofac Surg*. <http://dx.doi.org/10.1016/j.jcms.2012.12.008>, 2013 Feb 9 pii: S1010–5182(13)00014-0
- Sahoo NK, Rangarajan H: Comparative evaluation of vertical body osteotomy and sagittal split osteotomy for mandibular corpus distraction. *J Oral Maxillofac Surg* 69: 381–389, 2011
- Schendel SA, Linck 3rd DW: Mandibular distraction osteogenesis by sagittal split osteotomy and intraoral curvilinear distraction. *J Craniofac Surg* 15: 631–635, 2004
- Schreuder WH, Jansma J, Bierman MW, Vissink A: Distraction osteogenesis versus bilateral sagittal split osteotomy for advancement of the retrognathic mandible: a review of the literature. *Int J Oral Maxillofac Surg* 36: 103–110, 2007
- Shang H, Xue Y, Liu Y, Zhao J, He L: Modified internal mandibular distraction osteogenesis in the treatment of micrognathia secondary to temporomandibular joint ankylosis: 4-year follow-up of a case. *J Craniomaxillofac Surg* 40: 373–378, 2012
- Snyder CC, Levine GA, Swanson HM, Browne Jr EZ: Mandibular lengthening by gradual distraction. Preliminary report. *Plast Reconstr Surg* 51: 506–508, 1973
- Trauner R, Obwegeser H: The surgical correction of mandibular prognathism and retrognathia with consideration of genioplasty. I. Surgical procedures to correct mandibular prognathism and reshaping of the chin. *Oral Surg Oral Med Oral Pathol* 10: 677–689, 1957
- Yu H, Yang X, Cheng J, Wang X, Shen SG: Distraction osteogenesis combined with tissue-engineered cartilage in the reconstruction of condylar osteochondral defect. *J Oral Maxillofac Surg* 69: e558–e564, 2011