جامعة الملك سعود
King Saud University

LABORATORY DIAGNOSIS OF PARASITIC INFECTIONS

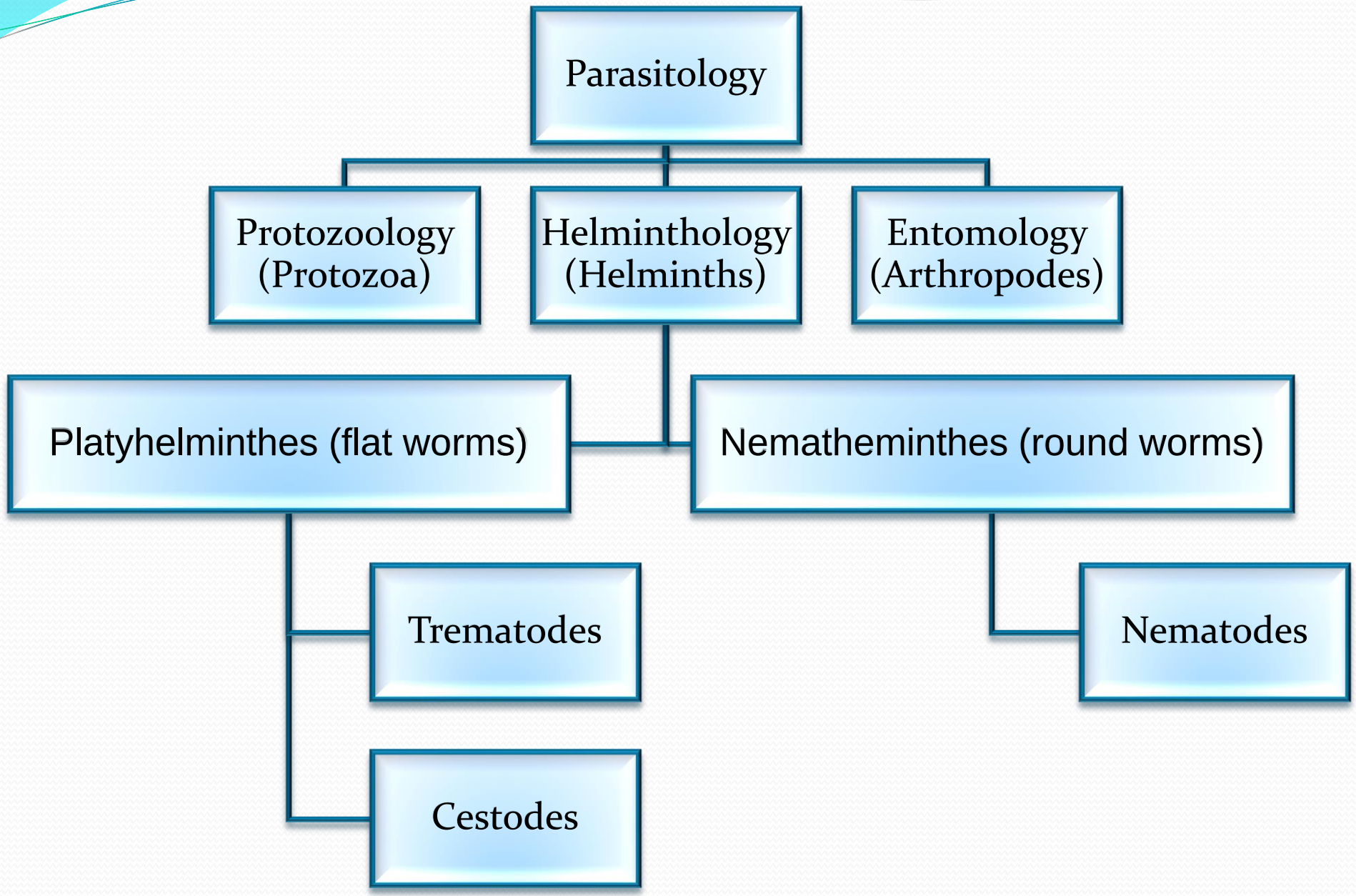
Parasitology
Protozoology (Protozoa)
Helminthology (Helminths)
Entomology (Arthropodes)
Platyhelminthes (flat worms)
Nematheminthes (round worms)
Trematodes
Cestodes
Nematodes

Collection of the specimens

- Delivery
- Safety
- Safety precautions

DIAGNOSIS

DIRECT	INDIRECT	MOLECULAR
Urine **Stool** **Sputum** **Biopsy** **Blood** **Aspirates**	**IHAT** **LAT** **IFAT** **ELISA** **CFT** **DEIDT**	**PCR** **DNA probes**

Urine examination

Terminal drops of urine.

Parasites detected in urine:

Helminths:

Schistosoma haematobium eggs.

Enterobius vermicularis eggs in female patients.

Microfilaria of Wuchereria bancrofti.

Protozoa:

Trichomonas vaginalis trophozoite in female patients.

URINE EXAMINATION

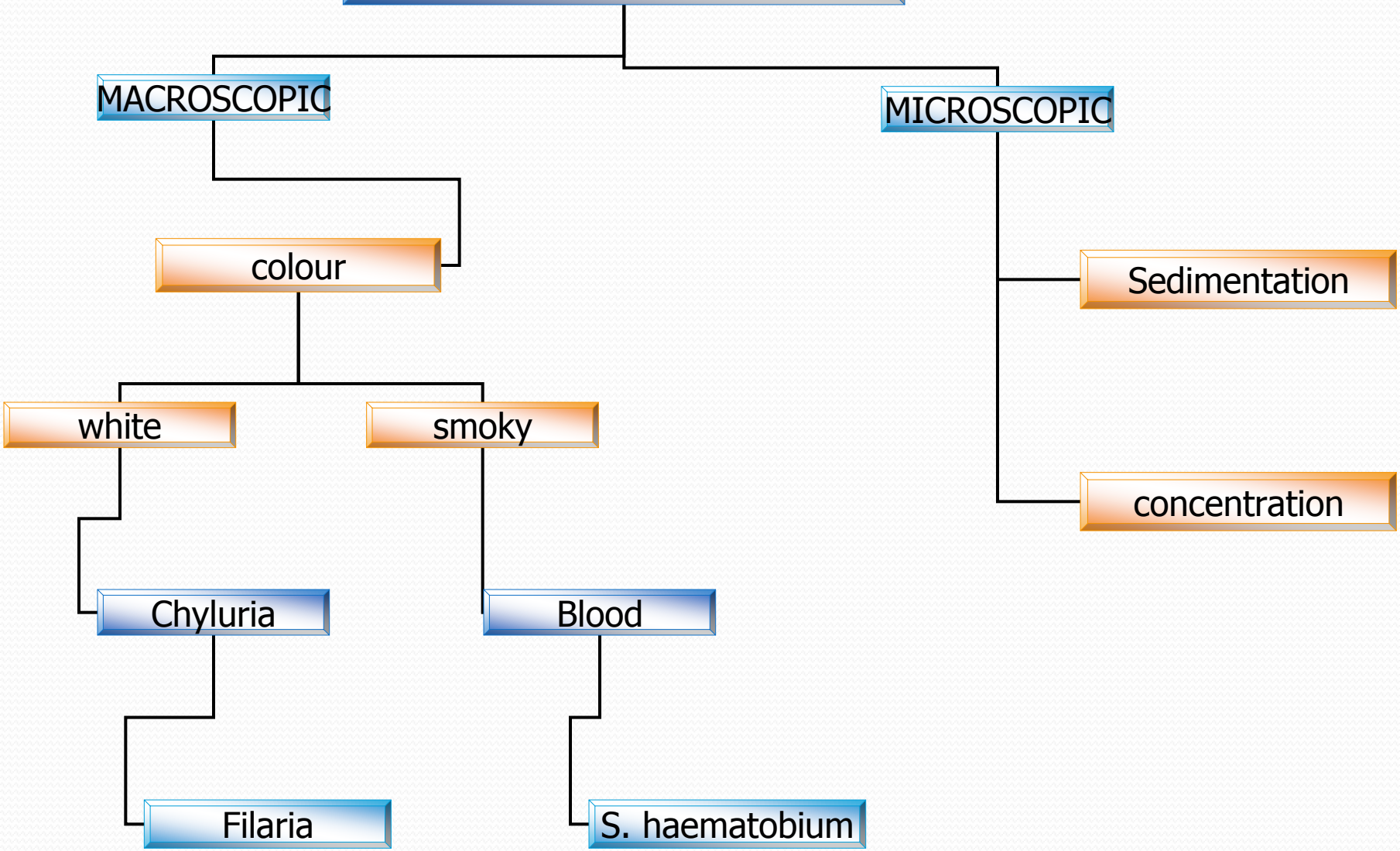

URINE EXAMINATION

SEDIMENTATION

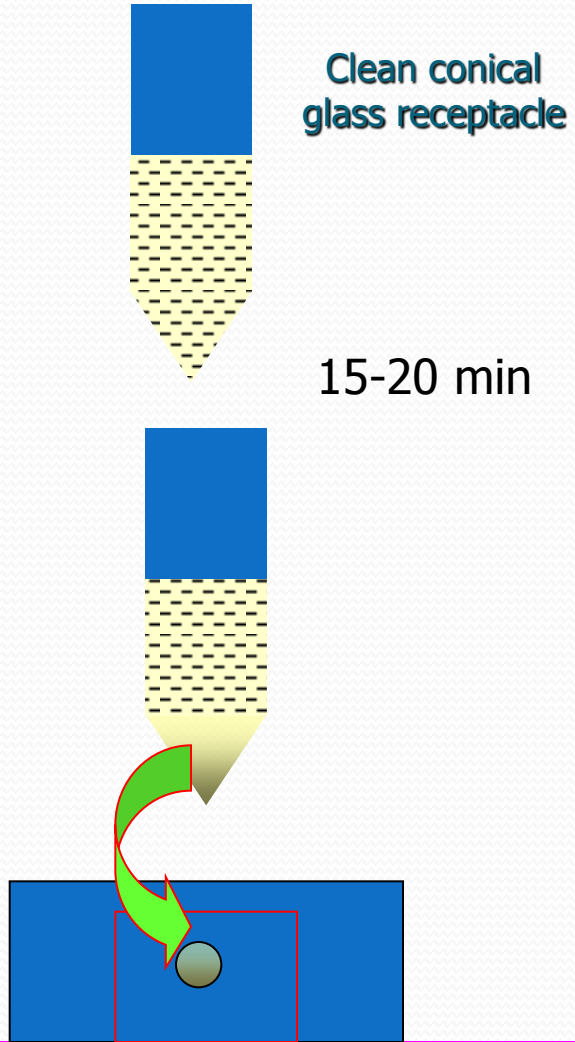

CONCENTRATION

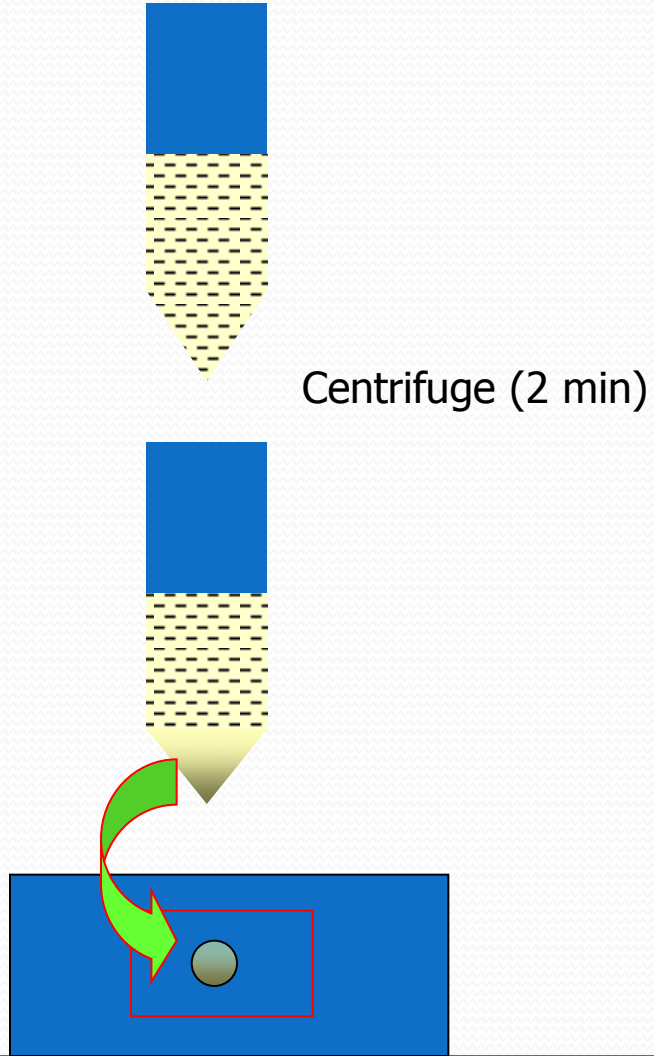

Urine examination

Other techniques:

Membrane Filter technique:

For concentration of Schistosoma eggs

Fill a syringe with urine, pass the urine through a filter. Remove the filter and place it on the slide, and examine it microscopically.

Iodine mounts of Faecal specimens

- You will see a lot more than just parasites!
- 1 drop of mixed specimen + 1 drop of iodine for contrast
- Kohler illumination will also give you the right contrast to see the parasites among the other constituents
- http://dpd.cdc.gov/dpdx/

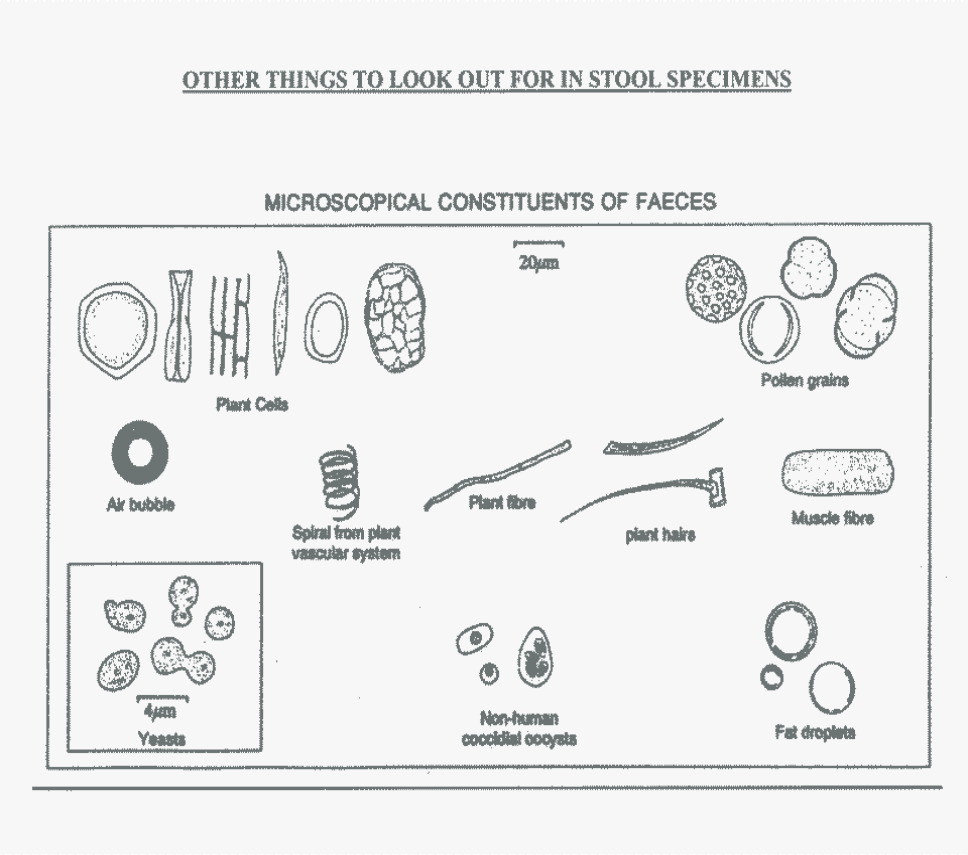

DIAGNOSIS

DIRECT	INDIRECT	MOLECULAR
Urine **Stool** **Sputum** **Biopsy** **Blood** **Aspirates**	**IHAT** **LAT** **IFAT** **ELISA** **CFT** **DEIDT**	**PCR** **DNA probes**

- **Collection method:**
- **Number of specimens:**
- **Collection time:**

- **Specimen type and stability:**
  - Liquid specimens
  - Soft (semi-formed) specimens
  - Formed specimens

- **Preservation of stool specimens:**

  - Aim:

    1- To preserve protozoan morphology.

    2- To prevent the continued development of some helminthic eggs and larvae.

  - The most common preservative used is 10% formalin.

Microscopic Examination of Faecal Specimens: Direct Smears

❖ Principle

- to assess the worm burden of a patient
- to provide a quick diagnosis of a heavily infected specimen
- to check organism motility
- to diagnose parasites that may be lost in concentration techniques.

ParaTest (Kit) for Fecal Examination for Intestinal Parasites

- **Principle**

A new way of doing Natural Sedimentation Technique using 4ml of 5% buffered formalin in special container covered with pointed end with small cover, the cover line with a fine filter and the pointed tip is open working as a dropper.

Microscopic Examination of Fecal Specimens: Permanent Stained Seamer (Trichrome)

- **Principle**

A modification of Gomori's original staining procedure for tissue. It is a rapid, simple procedure that produces uniformly well-stained smears of intestinal protozoa, human cells, yeast cells, and artifact material.

Flotation methods

1-Saturated saline flotation method

2-Zinc sulphate flotation method

3-Sheather's sugar flotation method

The main disadvantage:

- The operculated eggs like Fasciola their operculum will open and the fluid will enter inside, make them heavy, so they descend to the bottom. While the ascaris eggs are heavy, so they descend also to the bottom.

SPUTUM EXAMINATION

- MACROSCOPIC
  - Appearance
    - Bloody (Parag)
    - Rusty brown (Parag)
- MICROSCOPIC
  - Concentration

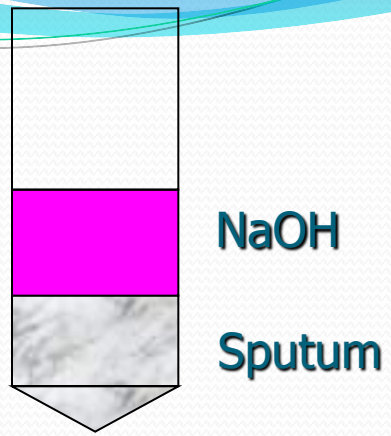

Centfifuge





Sputum examination

- Abnormally, it is purulent, bloody, contains rusty brown particles (Paragonimus).

Technique for examination:

- Add on a sputum sample equal volume of NaOH to dissolve the mucus.
- Leave this combination for a while, then centrifuge at 200xg for 5 minutes, then examine the sediment.

Sputum examination

- Parasites that could be detected in sputum:

1- The inhabitat in the lung: Paragonimus

2- Migratory larvae: - Ascaris
- Hook worm (Ancylostoma)
- Strongyloides.

3- Parasites causing pathology in the lung:

- Trophozoites of Entamoeba histolytica.
- Hydatid sand due to rupture of hydatid cyst that could be Present in the lung.

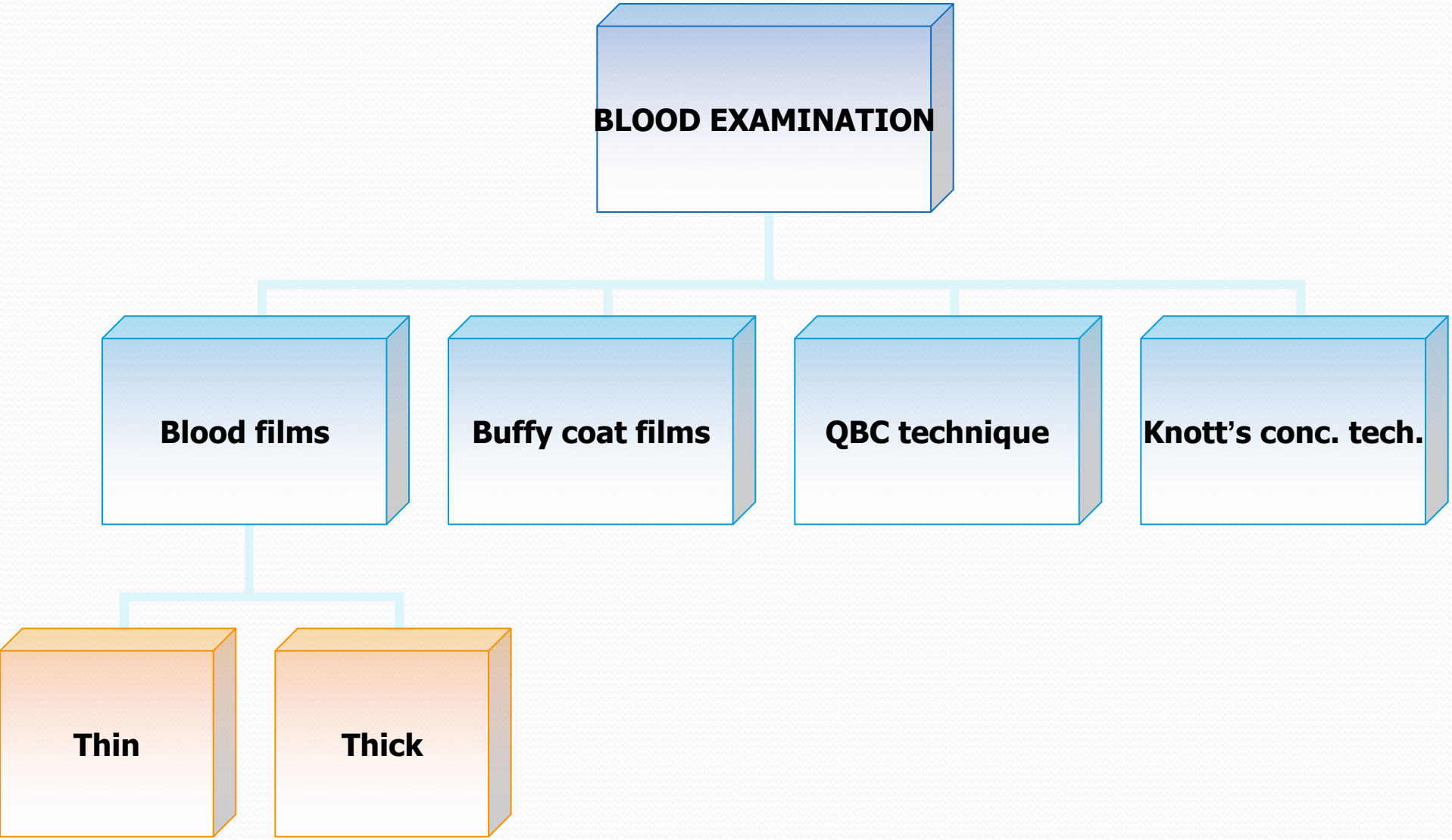
BLOOD EXAMINATION
Blood films
Buffy coat films
QBC technique
Knott's conc. tech.
Thin
Thick

Collection of blood

- **Specific precaution:**
  - The time the specimen was drawn should be clearly indicated on the tube of the blood and also on the result report.

- **Preparation**:
  - Fresh whole blood collected with no anticoagulants.
  - Anticoagulated blood (EDTA anticoagulant is preferred).
  - Sediment from the various concentration procedures.

  Fresh whole blood is used for detection of some organisms which may be motile, such as trypanosomes. However, species identification is normally accomplished from the examination of both thick and thin permanent stained blood films.

Blood films

- Two types of blood films can be made, thin and thick blood films:
  - **Thick films**
  - **Thin films**

- Thin

Bld drop

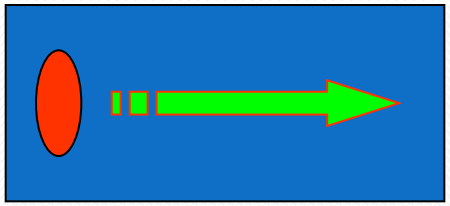

spread



Air dry



methyl alcohol



Geimsa

- Thick

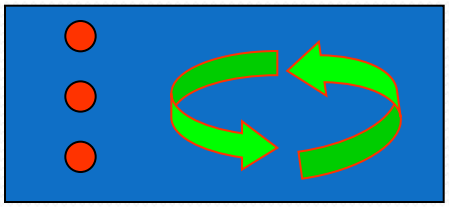

Circular motion



Air dry

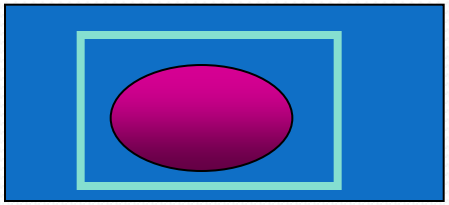

Geimsa

Blood films

- **Parasites that could be detected in blood film:**

- Malaria
- Trypanosoma (African and American).
- Microfilaria of all types Filaria except Onchocerca volvulus.
- Indian type of Leishmania donovani.

Examination of Other Specimen

- **Procedure**:

- **Examination for Enterobius Vermicularis** -(Commonly known as pin worm or seat worm)

- **Cellophane Tape - Slide preparation**

Examination of Other Specimen

- **Sigmoidscopy Material**

- **Duodenal Materials**
  - **Wet Preparation**

- **Aspirate**
  - Examination of aspirated material has become a valuable diagnostic aid and may reveal parasites when other methods have failed.

Examination of Other Specimen

- **Lung and Liver**
  - Aspiration from lung and liver could be examined for:

1- Pneumocytosis

2- Amoebiasis:

- **Technique: The use of proteolytic enzymes is recommended to free the organisms from the aspirate material**

3- Hydatid Disease

Examination of Other Specimen

- **Lymph nodes, Spleen, Liver, Bone Marrow and Spinal Fliud:** Aspirated material may be examined for presence of trypanosomes, leishmanial forms and amoebae.

- **Cutaneous Ulcers**
- **Leishmaniasis**
  - **NNN Medium**: (Novy-Mac Neal-Nicolle)

Fecal Occult Blood Test

Fecal occult blood is a term for (hidden) blood present in the feces that cannot be seen by naked eye.



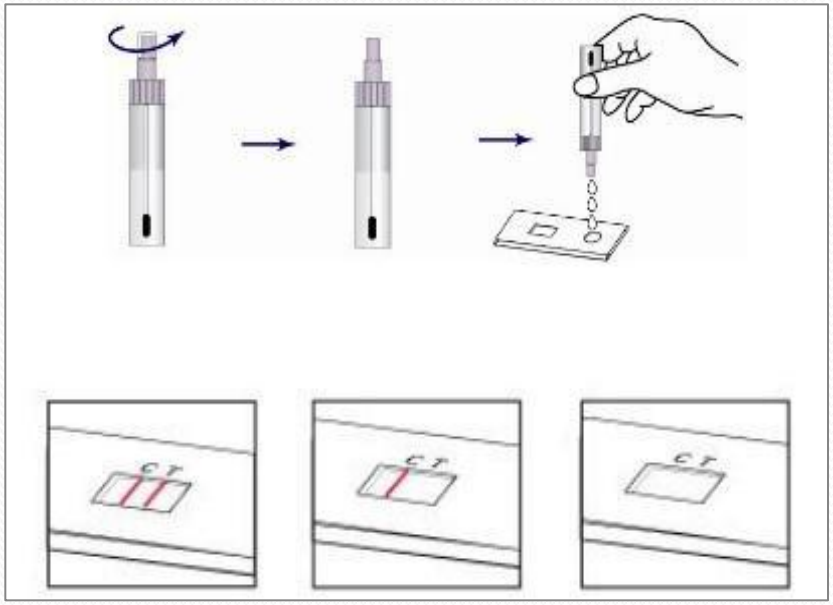

DIAGNOSIS

DIRECT

Urine
Stool
Sputum
Biopsy
Aspirates
Blood

INDIRECT

IHAT
LAT
IFAT
ELISA
CFT
DEIDT

MOLECULAR

PCR
DNA probes