



King Saud University

Collage of Nursing

Medical Surgical Nursing depart

## Application of Health Assessment

NUR 225

### Module Three


#### Physical examination of Head and Neck



## Physical Examination techniques for head and neck

- 1- Prepare patient and environment
- 2- Obtain health history
- 3- Prepare equipment needed as listed in the lecture

### 1- Assessment technique: The Head

| Objective data normal range of findings  | Abnormal findings  |
|--|--|
| <p><b><u>Inspect and Palpate the Skull</u></b></p> <p>General size and shape</p> <p><b><u>Size</u></b><br/>Note the general size and shape.<br/>Normocephalic is the term that denotes a round symmetric skull that is appropriately related to body size.</p> <p><b><u>Shape</u></b><br/>To assess shape, place your fingers in the person's hair and palpate the scalp.<br/>The scalp normally feels symmetric and smooth. There is no tenderness to palpation.</p> <p>Use a gentle rotating motion with finger tips. Begin at the front and palpate down the midline.<br/>Palpate each side of the head then occipital region for occipital lymph.</p> <p>Palpate the joint as the person opens the mouth and note normally smooth movement with no limitation or tenderness.</p> <p><b><u>Inspect the Face:</u></b><br/>Note facial expression and its appropriateness to behavior or reported mood. Anxiety is common in the hospitalized or ill person.</p> <p>Although shape of facial structures may vary among races, they should always be symmetric, eyebrows, palpebral fissures, nasolabial folds, and the creases extending from the nose to each corner of the mouth.</p> | <p><b><u>Deformities:</u></b><br/>Microcephaly (abnormally small head)<br/>Macrocephaly (abnormally large head)<br/>acromegaly (Paget's disease)</p>  <p>Crepitation, limited range of motion or tenderness.</p> <p>Hostility or embarrassment. Tense, rigid muscles may indicate anxiety or pain; a flat affect may indicate depression; excessive smiling may be inappropriate.</p> <p>Marked asymmetry with central brain lesion (brain attack) or with peripheral cranial nerve VII damage (Bell's Palsy).</p> |

Note any abnormal facial structures (coarse facial features, exophthalmos, changes in skin color or pigmentation), or any abnormal swelling.  
Note any involuntary movements (tics) in the facial muscles, normally none occur.

**Inspect External Ocular Structures (The Eye)**

Size, placement, alignment

All three should be symmetrical

**Eyebrows**

Normally eyebrows are present bilaterally, move symmetrically as the facial expression changes, and have no scaling or lesions.

**Inspect lashes** for hair distribution and growth  
Short Evenly spaced upper lashes curl upward and lower lashes curve downward and away from eye

**Eyelids**

When eye is open the upper lid should fall between the upper iris and top portion of pupil.

The skin is intact without redness, swelling, discharge, or lesions.

**Sclera**

**Conjunctiva** and sclera should be white and free from nodules or swelling

**Eyeballs**

The eyeballs are aligned normally in their sockets with no protrusion or sunken appearance. Blacks normally may have a slight protrusion of the eyeball beyond the supraorbital ridge.

Eyeballs look moist and glossy.

Explain procedure to the patient then put on examination gloves and keep his eyes closed , gently palpate eyelids for tenderness, mass & swelling, Eye ball firm Feeling touch sensation

Edema in the face occurs first around the eyes (periorbital) and the cheeks where the subcutaneous tissue is relatively loose.

Exophthalmus – abnormal protrusion of the eyeball

Absent lateral third of brow with hypothyroidism.

Unequal or absent movement with nerve damage.

Scaling with seborrhea.

Unequal distribution of hair

Lid lag with hyperthyroidism

Incomplete closure of lids can cause damage to cornea

Ptosis – drooping of upper eye lid

Yellow sclera (Jaundice)

Pale palpebral conjunctiva (anemia)

Increased number of blood vessels (inflammation)

Exophthalmos (protruding eyes) and enophthalmos (sunken eyes)

|   |   |
|---|---|
| <p style="text-align: center;"><b><u>Pupil</u></b></p> <p>Note size, shape and equality of pupils<br/>Round, clear and equal<br/>Test pupillary light reflex, darken the room and ask the person to gaze into the distance. (This dilates pupils)</p> <p><b><u>Test for accommodation</u></b> by asking the person to focus on a distant object. This process dilates the pupils. Then have the person shift the gaze to near object, such as your finger held about 7-8 cm from the nose, a normal response is pupillary constriction.<br/>Record normal response to these maneuvers s PERRLA, or Pupils Equal, Round, React to Light and Accommodation.</p> <p><b><u>Testing visual field</u></b><br/>This test is used to evaluate the peripheral extent of visual field.</p> <p><b><u>Testing visual acuity</u></b><br/>Ask patient to sit or stand 4-6m from Sellen-chart and cover the left eye with opaque card .Ask patient to read the letters on one line of the chart and then to move downward to increasingly smaller lines until he can no longer discern all of the letters Repeat the test with the other eye.</p> <p><b><u>Testing corneal reflex</u></b><br/>By lightly touching the cornea with wisp of cotton.<br/><b>Blinking is normal reaction</b></p> <p><b><u>Testing eye ball movement</u></b><br/>Ask patient to follow the object with his eyes Without moving his head. Nurse moves the object to each of the six cardinal positions, returning to the midpoint after each movement.</p> <p style="text-align: center;"><b><u>Inspection of the Ear</u></b></p> <p>Location / Alignment hygiene<br/>The top of the ear should be in a straight line with the corner of the eye<br/>No swelling or thickening</p> <p><b><u>Discharge or odor</u></b><br/>May be caused by a perforated tympanic membrane, foreign body, exudates or wax<br/><b><u>Inspect ear canal</u></b> (external auditory canal &amp;tympanic membrane) by using otoscope .The auricle is gently pulled upward and backward to straight the ear canal.</p> | <p>resting adult 3mm-5mm<br/>Changes in pupils can indicate central nervous system injury<br/>Observe for cataracts</p> <p>Absence of constriction or convergence.</p> <p>Asymmetric response.</p> <p>Hemianopia ( loss half of visual field)</p> <p>Blindness, Myopia (impaired distant vision)<br/>Presbyopia (Impaired Near vision).</p> <p>No reaction</p> <p>Microtia – small ears<br/>Macrotia – Larger than normal ears<br/>Edema<br/>Redness – indicates inflammation<br/>Crusts over external area – eczema , contact dermatitis</p> <p>Purulent otorrhea – otitis externa or media<br/>Frank blood or clear watery drainage –especially after trauma - possible skull fracture<br/>Foreign body – loss of hearing</p> |
|---|---|

**Palpate auricle** for texture and pain sensation on movement. Moveable without pain. The auricle is firm in texture

**Palpate mastoid area** behind ear for tenderness. No tenderness

### Hearing acuity tests

#### Weber's test:

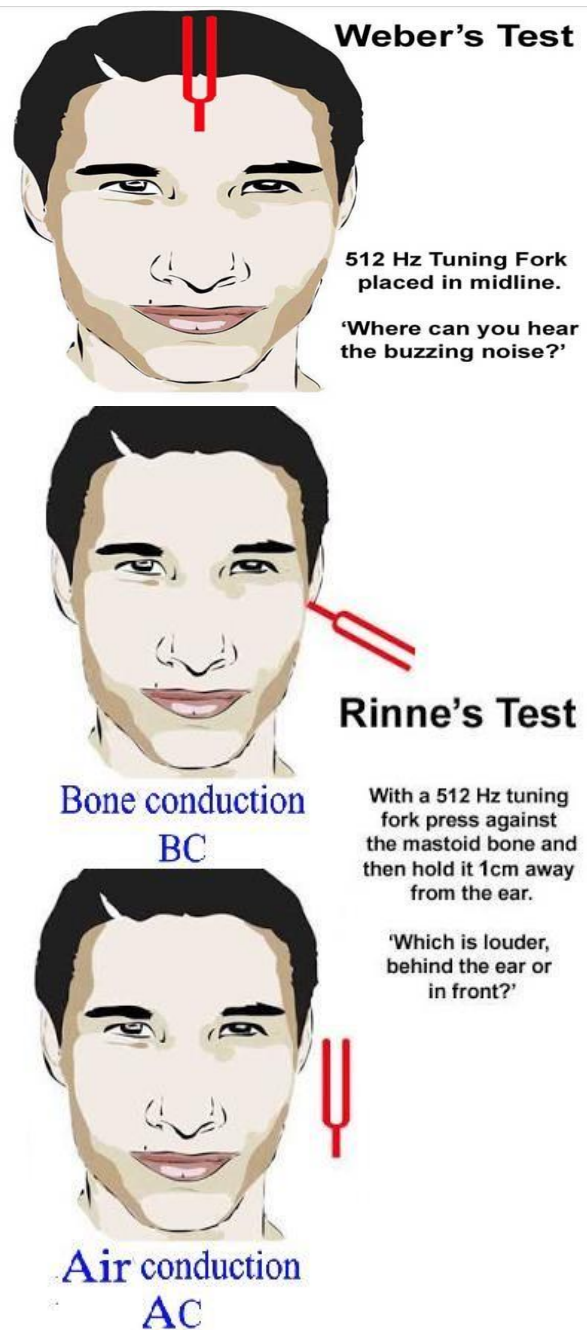
Uses to evaluate bone conduction.

#### Rinnes Test:

Uses to evaluate air conduction of the sound

Moveable with pain

Tenderness



### Inspection of the Nose

Shape  
Symmetry  
Patency  
Mucosal Integrity  
Should be pink and moist  
Septum should be straight

**Palpate frontal and maxillary Sinus** for tenderness.

#### **\*Frontal**

Place your thumbs above the patient eyes just under the bony ridges of the upper orbits and place your fingertips on his forehead

#### **\* Maxillary**

Gently press your thumb on each side of the nose just below cheek bones

#### **Test Olfactory nerve**

Ask patient to close his eyes and block one nostril and inhale a familiar aromatic substance through the other nostril

### Inspect and Palpate the Mouth

#### **Lips**

Integrity  
Symmetry  
Color

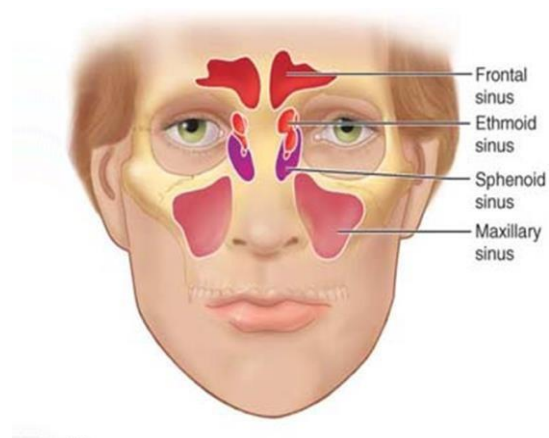
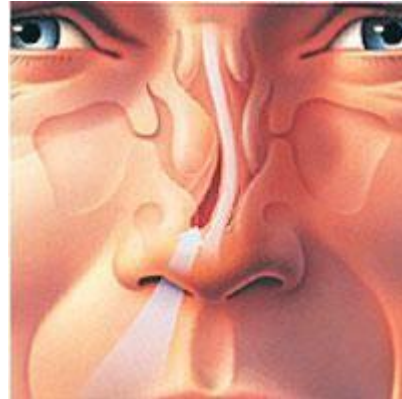
Moist, soft and pink

**Gum**- color ,lesion

**Teeth** – should be in good condition

**Mucous Membrane** – colour, texture, discharge, swelling

Erythema and / or discharge from one side of the nares is suggestive of a foreign body



In light skinned people circumoral pallor occurs in shock and anemia  
Cyanosis with hypoxemia and chilling  
Cherry red lips with carbon monoxide poisoning, acidosis from aspirin poisoning or ketoacidosis

History helps to determine if oral lesions have infectious, traumatic, immunological, or malignant etiology  
Dysphagia – occurs with many conditions, gastroesophageal reflux, pharyngitis, stroke, neurological diseases, esophageal cancer

**Tongue** – size, colour, thickness, lesions, moisture, symmetry

Palpate the tongue and floor of mouth with a gloved finger.

Pink, free from ulcer, nodules

**Pharynx** – inflammation, exudates, masses. Press a tongue blade firmly upon the tongue for visualization of the pharynx

**roof of mouth** for color and architecture of [hard palate](#)

### Inspect and palpate the NECK

#### **Symmetry**

Head position is centered in the midline, and the accessory neck muscles should be symmetrical. The head should be held erect and still.

#### **Range of Motion**

Note any limitation of movement during active motion, ask the person to touch the chin to the chest, turn the head to the right and left, try to touch each ear to the shoulder (without elevating shoulders), and to extend the head backward. When the neck is supple, motion is smooth and controlled.

**Test muscle strength** and the status of cranial nerve XI by trying to resist the person's movements with your hands, as the person shrugs the shoulders and turns the head to each side.

**\*Inspect thyroid gland** for symmetry, visible mass.

You should stand in front of the client & Ask client to sip some water and swallow. Symmetrical, no mass.

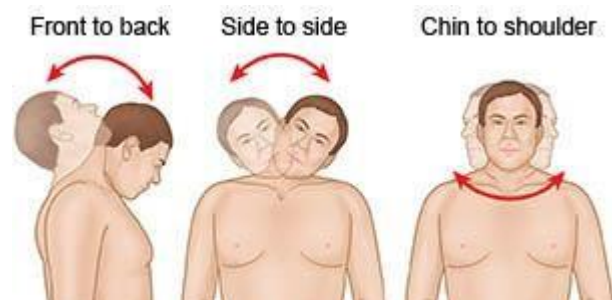
Thyroid gland ascends normally during swallowing & not visible, Except in extremely thin person

White patch

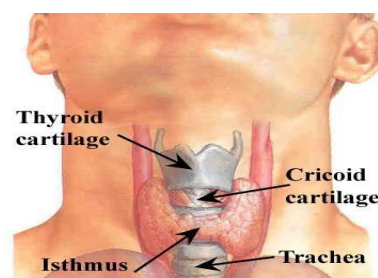
Untreated strep throat may lead to the complication of rheumatic fever

Pigmentation-Thrush on the palate.

Head tilt occurs with muscle spasm. Rigid head and neck occur with arthritis. Note pain at any particular movement. Note limited movement due to cervical arthritis or inflammation of neck muscles.



Thyroid enlargement may be a unilateral lump, or it may be diffuse and look like a doughnut lying across the lower neck.

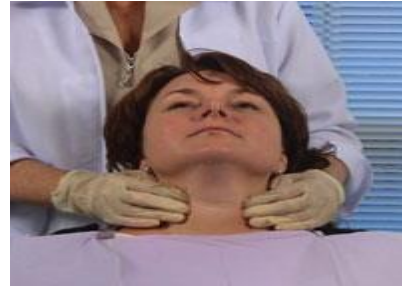

**Palpate thyroid** by standing behind the client. Put your hands around his neck with your finger tips on the lower half of the neck over the-trachea.

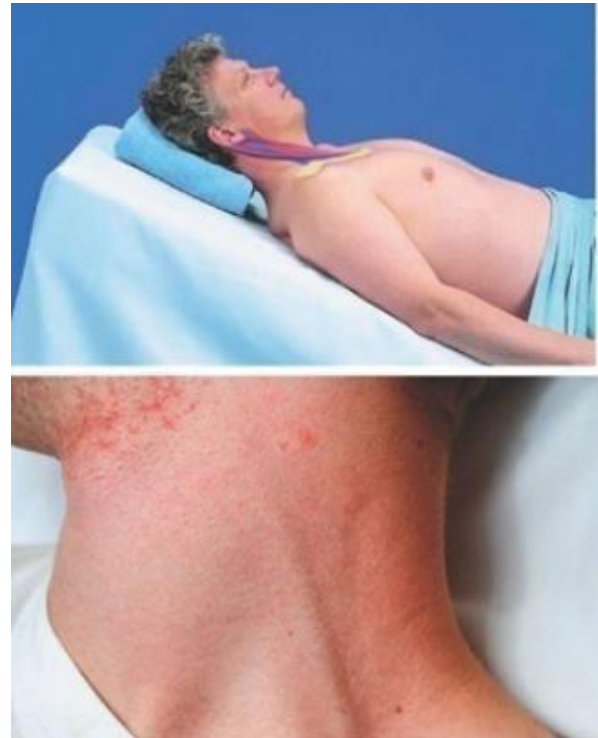#### Inspect External jugular veins

Observe with patient sitting and then lying at 30-45 angle.

**Normal finding:** Jugular veins should be flat, without sign of distention



Distention Heart failure



#### Lymph Nodes

Using gentle circular motion of your finger pads, palpate the lymph nodes.

Use gentle pressure because strong pressure could push the nodes into the neck muscles.

If any nodes are palpable, note their location, size, shape, delimitation (discrete or matted together), mobility, consistency, and tenderness.

Cervical nodes are often palpable in healthy persons, although, this palpability decreases with age. Normal nodes feel movable, discrete, soft, and non tender.

Lymphadenopathy is enlargement of the lymph nodes ( $> 1$  cm) due to infection, allergy, or neoplasm.

The following criteria are common clues but are not definitive in all circumstances.

Acute infection – nodes are bilateral, enlarged, warm, tender, and firm but freely movable.

Chronic inflammation e.g., in tuberculosis the nodes are clumped.

Cancerous nodes are hard, unilateral, nontender, and fixed.

Nodes with HIV infection are enlarged, firm, nontender, and mobile. Occipital node enlargement is common with HIV infection.

Painless, rubbery, discrete nodes that gradually appear occur with Hodgkin's lymphoma.



**Preauricular** - In front of the ear

**Postauricular** - Behind the ear

**Occipital** - At the base of the skull

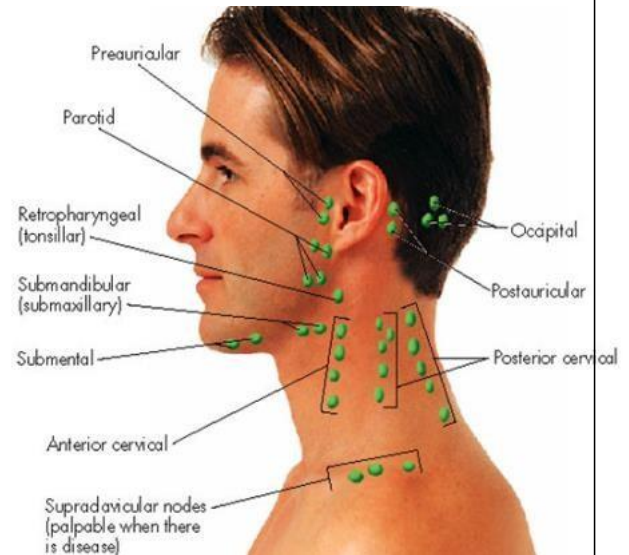
**Tonsillar** - At the angle of the jaw

**Submandibular** - Under the jaw on the side

**Submental** - Under the jaw in the midline

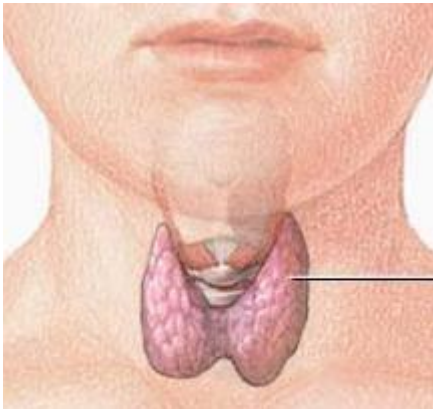
**Superficial (Anterior) Cervical** over and in front of the sternomastoid muscle

**Supraclavicular** - In the angle of the sternomastoid and the clavicle



### Trachea

Normally, trachea is midline, palpate for tracheal shift. The space should be symmetric on both sides. Note any deviation from the midline.



### **Conditions of tracheal shift:**

The trachea is pushed to the unaffected (healthy) side with an aortic aneurysm, a tumor, unilateral thyroid lobe enlargement, and pneumothorax.

The trachea is pulled toward the affected (diseased) side with large atelectasis, pleural adhesions, or fibrosis.

## Appendix

| Number | Name                   | Function                                | Test  |
|--------|------------------------|---|---|
| I      | Olfactory Nerve        | Smell                                   | <b><u>Test Olfactory nerve</u></b><br>Ask patient to close his eyes and block one nostril and inhale a familiar aromatic substance through the other nostril Such as ( coffee, vanilla, lemon )   |
| II     | Optic Nerve            | Vision                                  | <b><u>Testing visual acuity</u></b><br>Ask patient to sit or stand 4-6m from Sellen-chart and cover the left eye with opaque card .Ask patient to read the letters on one line of the chart and then to move downward to increasingly smaller lines until he can no longer discern all of the letters Repeat the test with the other eye.   |
| III    | Oculomotor Nerve       | pupil constriction<br>Eye movement;     | Test pupillary light reflex, darken the room and ask the person to gaze into the distance. (This dilates pupils)<br><br><b><u>Test for accommodation</u></b> by asking the person to focus on a distant object. This process dilates the pupils. Then have the person shift the gaze to near object, such as your finger held about 7-8 cm from the nose, a normal response is papillary constriction.<br>Record normal response to these maneuvers s PERRLA, or Pupils Equal, Round, React to Light and Accommodation. |
| IV     | Trochlear Nerve        | Eye movement                            |   |
| VI     | Abducens Nerve         | Eye movement                            |   |
| XI     | Spinal Accessory Nerve | Controls muscles used in head movement. | <b><u>Test muscle strength</u></b> and the status of cranial nerve XI by trying to resist the person's movements with your hands, as the person shrugs the shoulders and turns the head to each side.   |

## Nursing health assessment documentation format

### Head & neck (adapted from KFSH & RC)

**Instructions:** Circle or fill in the blanks with actual physical assessment findings. WNL=Within Normal Limits for age. Mark items which require additional documentation with an asterisk (\*) and document in the Nurse's Notes sections of the Daily Nurses Record.

#### Pt. Identification data

Name----- Age----- Sex----- occupation ----- Marital status-----

Tel/Address----- Known Allergies-----

#### General Survey

Physical appearance \_ WNL, abnormality----- Body structure \_ WNL, abnormality-----

Mobility \_ WNL, abnormality----- Behavior \_ WNL, abnormality-----

#### Present history

Chief complaint: P----- P -----

Q----- R----- R-----

S----- T----- T-----

T----- Associated symptoms -----

Medication -----

Past history-----

-----

Family history-----

-----

#### Physical examination

##### Head

Hair: -                      Equal in distribution                      Fine                      Coarse

Scalp: -                      Intact / Injury                      Dandruff                      Nits

Skull: -                      Intact / Injury                      Enlarged /smaller

##### Eye and vision

Sclera: -                      Clear                      Yellow                      Red

Pupil: -                      Equal /Unequal

Visual acuity: -    WNL                      impaired distant /near vision

**Ear and hearing****Auricle: - Firm****Tenderness****Ear opening: -Discharge****Hearing field; - WNL****Hearing problem****Nose****Mucous membrane; - Pink /Moist****Red****Swelling****Discharge****Mouth****Lips:- Pink/Moist****Red****Bleeding****Gums Pink/Moist****Red****Bleeding****Neck****Thyroid gland; Mass****Visible****Lymph node: Normal****Enlargement****COMMENTS:-**

---

---

---

---

**Signature:-****Date:-**

Performance checklist

Head & Neck

The student nurse should be able to:

| Performance criteria  | Competency Level |                      |          |                |                      |          |         |
|---|------------------|----------------------|----------|----------------|----------------------|----------|---------|
|   | Trial 1          |                      |          | Trial 2        |                      |          | Comment |
|   | Done correctly   | Done with assistance | Not Done | Done correctly | Done with assistance | Not Done |         |
| -Collect appropriate objective, subjective data about head and neck related to general survey.  |                  |                      |          |                |                      |          |         |
| Collect appropriate equipment   |                  |                      |          |                |                      |          |         |
| HEAD & FACE   |                  |                      |          |                |                      |          |         |
| Inspection  |                  |                      |          |                |                      |          |         |
| 1- Inspect Skull for size and shape<br>2- Inspect face for skin color, facial expression and its appropriateness to behavior or reported mood.<br>Shape of facial structures, eyebrows, nasolabial folds. And the symmetry  |                  |                      |          |                |                      |          |         |
| PALPATION   |                  |                      |          |                |                      |          |         |
| 3- To assess shape Palpate the scalp for symmetry tenderness mass and nodules.  |                  |                      |          |                |                      |          |         |
| EYE AND VISION  |                  |                      |          |                |                      |          |         |
| Inspection  |                  |                      |          |                |                      |          |         |
| 1- Inspect eye for Size, placement, alignment<br>All three should be symmetrical<br>2- Inspect pupils for size, shape and symmetry<br>3- Inspect eyebrows and lashes for symmetry, Distribution of hair and scaling or lesions.<br>4- Inspect eyelid and lid margins for swelling, discharge color, scaling, erythema.<br>5- Inspect Conjunctiva sclera for color.<br>6- Test pupil for accommodation.<br>7- Test visual acuity |                  |                      |          |                |                      |          |         |

|   |  |  |  |  |  |  |  |
|---|--|--|--|--|--|--|--|
| 8- Test Corneal reflex<br>9- Test Pupil react to light<br>10- Test Eyeball movement<br>11- Test Peripheral field acuity   |  |  |  |  |  |  |  |
| <b>PALPATION</b>  |  |  |  |  |  |  |  |
| - Palpate eyeball for tender and feeling sensation.   |  |  |  |  |  |  |  |
| <b>EAR AND HEARNING</b>   |  |  |  |  |  |  |  |
| <b>Inspection</b>   |  |  |  |  |  |  |  |
| 1- Location, Alignment, hygiene, Discharge or odor<br>2-Inspect ear canal for tympanic membrane, Discharge or redness   |  |  |  |  |  |  |  |
| <b>Palpation</b>  |  |  |  |  |  |  |  |
| 3- Palpate auricle for pain sensation on movement. And texture<br>4- Palpate mastoid area behind ear for tenderness   |  |  |  |  |  |  |  |
| <b>5-Hearing field tests</b><br>Webers test<br>Rinnes test  |  |  |  |  |  |  |  |
| <b>NOSE AND SINUSES</b>   |  |  |  |  |  |  |  |
| 1- Inspect nose for Shape Symmetry Mucosal Integrity Septum should be straight discharge<br><br>2-Inspect for nasal obstruction and air way patency<br><br>3-Test Olfactory nerve |  |  |  |  |  |  |  |
| <b>Palpation</b>  |  |  |  |  |  |  |  |
| 3-Palpate frontal and maxillary sinus for Tenderness.   |  |  |  |  |  |  |  |

| MOUTH  |  |  |  |  |  |  |  |
|--|--|--|--|--|--|--|--|
| <b>Inspection</b>  |  |  |  |  |  |  |  |
| 1-Inspect lips, gums, Mucous Membrane for Color, Moist, integrity swelling and ulcer.<br><br>2-Inspect the teeth for number and condition.<br>3-Inspect tongue for size, color, lesions, moisture surface and mid-line protrusion. |  |  |  |  |  |  |  |
| <b>Palpation</b>   |  |  |  |  |  |  |  |
| 4-Palpate the tongue and floor of mouth with a gloved finger for redness, ulceration, nodules,   |  |  |  |  |  |  |  |
| Pharynx  |  |  |  |  |  |  |  |
| <b>Inspection</b>  |  |  |  |  |  |  |  |
| 1- Inspect uvula and pharynx for color moisture and inflammation.<br>2- Note tonsils for size, inflammation, swelling, discharge.<br>3- Inspect roof of mouth for color, integrity and architecture of hard palate                 |  |  |  |  |  |  |  |
| NECK   |  |  |  |  |  |  |  |
| <b>Inspection</b>  |  |  |  |  |  |  |  |
| 1- Inspect the neck for position symmetry range of motion mass<br>2- Test muscle strength<br><br>3- Inspect thyroid gland for size and visible mass.<br><br>4- External jugular vein   |  |  |  |  |  |  |  |
| <b>Palpation</b>   |  |  |  |  |  |  |  |
| Palpate thyroid<br><br>Palpation of lymph nodes<br><br>Palpate for Trachea shift   |  |  |  |  |  |  |  |
| Document findings following designated format  |  |  |  |  |  |  |  |

Evaluated by: \_\_\_\_\_ Date Evaluated: \_\_\_\_\_

Name and Signature of Faculty \_\_\_\_\_ Total grade \_\_\_\_\_