



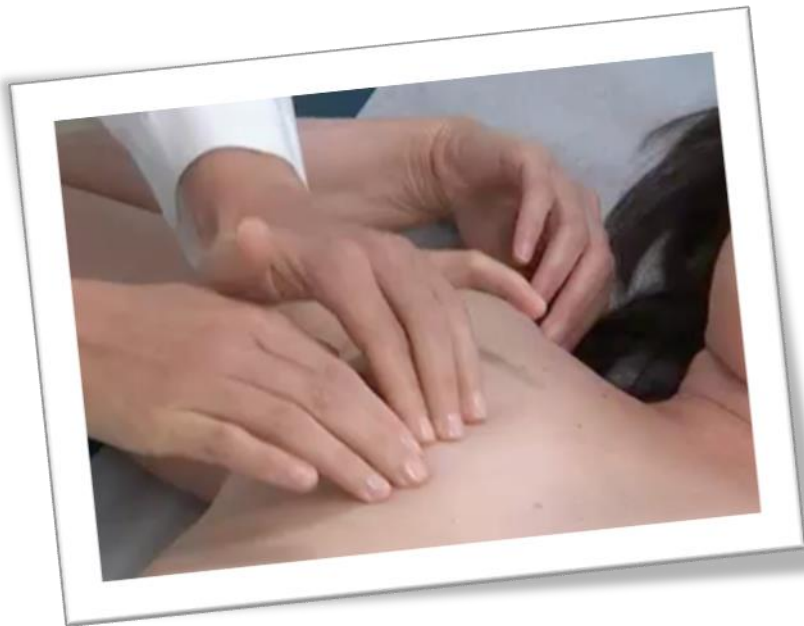King Saud University
Collage of Nursing
Medical Surgical Nursing depart

Application of Health Assessment

NUR 225

Module Six

Physical examination of Breast & lymphatic system

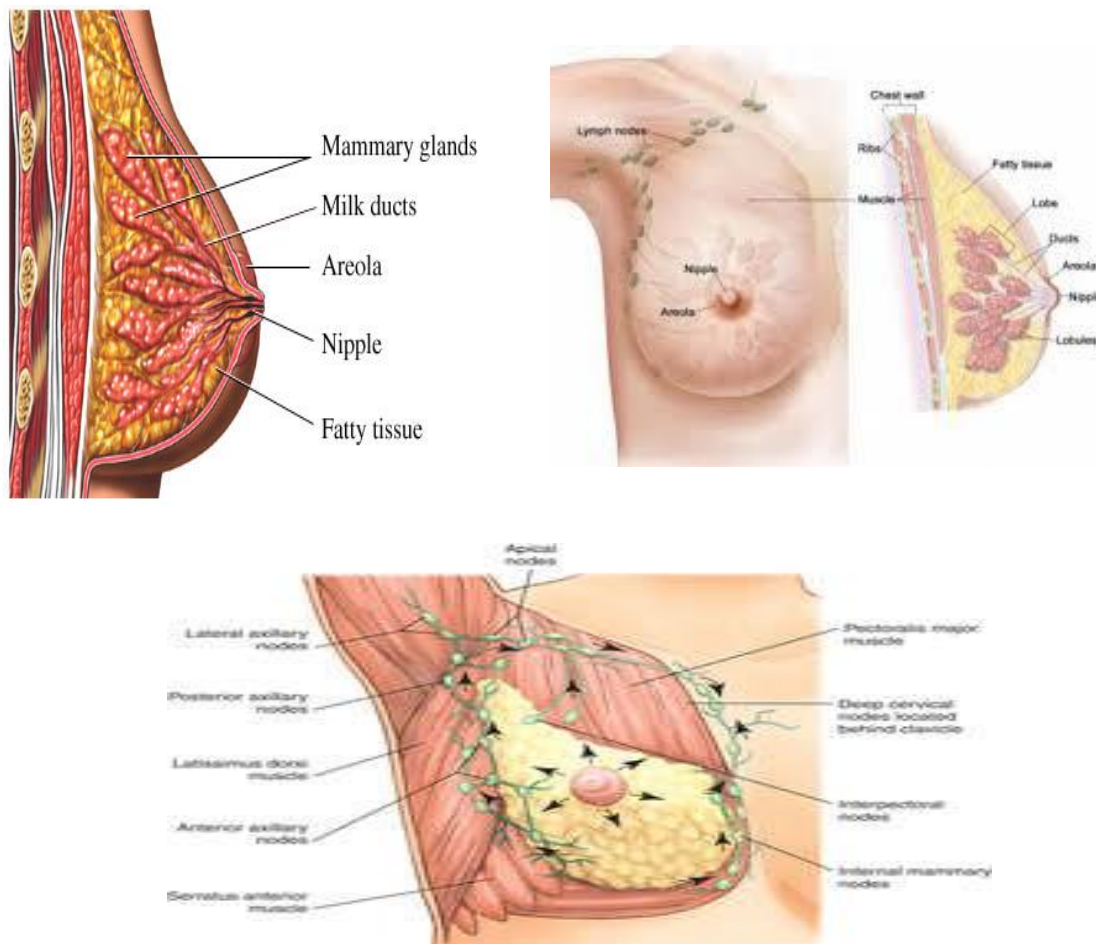


OUTLINE

- I. Overview of the Anatomy
- II. Purpose of Breast Examination
- III. Obtaining Health History
- IV. Physical Examination
- V. Performance Checklist

I. Overview of anatomy:

- The breast also called mammary glands in women .lie on anterior chest wall.
- They are located vertically between the second or third and sixth ribs over the pectoralis muscle and horizontally between the sternal border and the midaxillary line
- Each breast has centrally located nipple of pigmented erectile tissue ringed by an areola that darker than tissue



II. Purpose of breast examination:

- ✓ To early detection and screening of breast cancer
- ✓ To prevent breast cancer prevalence
- ✓ To improve prognosis of breast cancer
- ✓ To evaluate plan of care for breast cancer patient

III. Obtain health history:

Chief complains	Includes breast pain, nipple discharge, rash, lump, masses& other changes Explore PAIN using COLDSPA : <u>Character</u> : Describe pain (dull, aching, sharp) <u>Onset</u> : When did this first begin? <u>Location</u> : Point to the area where the pain occur. Ask whether it radiates to other areas. <u>Duration</u> : Ask how long does it last, recurrence and how often. <u>Severity</u> : Let patient describe pain using scale of 1-10 (10 being the most severe). Ask if it limits performance of activities of daily living. <u>Pattern</u> : What do you do when you have this pain? What medications do you take to relieve the pain? <u>Associated Factors</u> : Ask whether it occur at specific time during the menstrual cycle. Other associated symptoms (nipple discharge, changes in color of breast, swelling).
Present history:	Age, day of menstrual cycle appears symptom, changes in underarm area axilla , tenderness , lump , or swelling , rash
Past history:	LMP(Last menstrual period) , Delivery and pregnancy, breast feeding, history of breast disease, history of surgery or biopsy
Family history	Breast cancer, breast disorder , other types of cancer
Medication	Oral contraceptive pills
Nutritional	High fat diet , caffeine
Habits	Smoking, alcohol
Self care behavior and psychological status	Perform breast self examination

IV. Physical Examination

✓ **Equipment needed:**

- Centimeter ruler
- Small pillow
- Gloves
- Client handout for BSE
- Slide for specimen

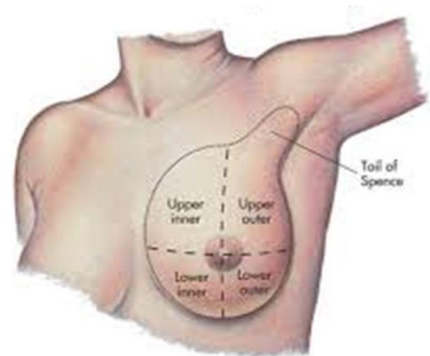
✓ **Prepare Patient:**

- Explain the procedure in detail and answer any questions the client may have.
- Provide privacy during the examination.
- Work in a well lighted room.
- Prepare the client for examination by having the client sit in an upright position.
 - o Explain to the client that this is necessary to expose both breasts to compare for symmetry during the inspection.
 - o One breast may be draped while the other breast is palpated.
 - o The breasts are first inspected in the sitting position while the client is asked to hold arms in different positions.
 - o The breasts are then palpated while the client assumes a supine position.
- The final part of the examination involves teaching clients how to perform BSE and asking them to demonstrate what they have learned.

Establish landmark and visualize the anatomy to describe clinical finding :

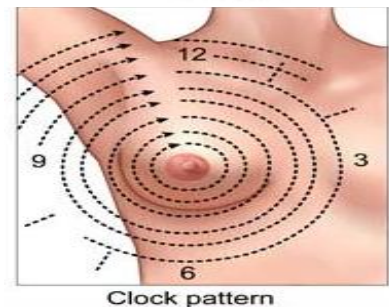
- ✓ **Method I:** Divide the breast into four quadrants by imaginary horizontal and vertical lines intersecting at the nipple. Describe findings according to:

- Appropriate quadrant
- The distance in centimeters from the nipple




- ✓ **Method II-**Think of the breast as a clock with the nipple in the centre. Describe findings according to:

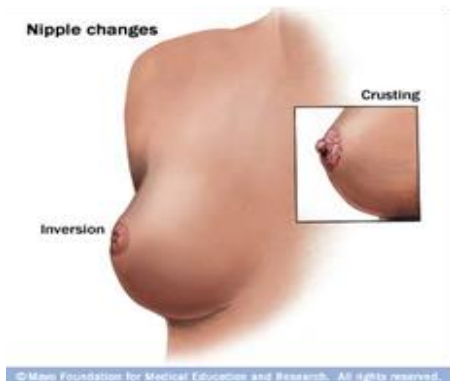
- Location according to time
- The distance in centimeters from the nipple

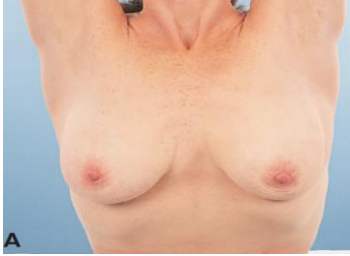

Remember: The upper outer quadrant of breast is the site of most breast tumors.

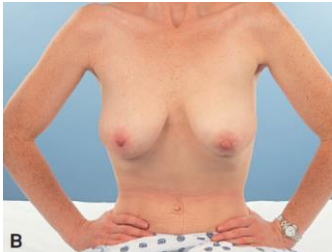PHYSICAL EXAMINATION

FEMALE BREAST		
ASSESSMENT PROCEDURE	NORMAL FINDINGS	ABNORMAL FINDINGS
INSPECTION		
1- Inspect size and symmetry. <ul style="list-style-type: none"> ✓ Have the client disrobe and sit with arms hanging freely. ✓ Explain what you are observing to help ease client anxiety. 	<p>May vary in size. Somewhat Around and pendulous. One breast may be normally larger than the other</p> <p><u>Older Adult considerations:</u> The older client often has more pendulous, less firm, and saggy breasts.</p>	<p>Recent increase in the size of one breast may indicate inflammation or an abnormal growth.</p>
2- Inspect color and texture. <ul style="list-style-type: none"> ✓ Be sure to note client's overall skin tone when inspecting the breast skin. ✓ Note any lesions. 	<p>Color varies depending on the client's skin tone. Texture is smooth, with no edema.</p> <p>Linear stretch marks may be seen during and after pregnancy or with significant weight gain or loss.</p>	<p>Redness is associated with breast inflammation.</p> <p>A pigskin-like or orange-peel (peau d'orange) appearance results from edema, which is seen in metastatic breast disease.</p>  <p>The edema is caused by blocked lymphatic drainage.</p>
3- Inspect superficial venous pattern. <ul style="list-style-type: none"> ✓ Observe visibility and pattern of breast veins. 	<p>Veins radiate either horizontally and toward the axilla (transverse) or vertically with a lateral flare (longitudinal).</p> <p>Veins are more prominent during pregnancy.</p>	<p>A prominent venous pattern may occur as a result of increased circulation due to a malignancy. An asymmetric venous pattern may be due to malignancy.</p>
4- Inspect the areolas. <ul style="list-style-type: none"> ✓ Note the color, size, shape, and texture of the areolas of both breasts. 	<p>Areolas vary from dark pink to dark brown, depending on the client's skin tones. They are round and may</p>	<p>Peau d'orange skin, associated with carcinoma, may be first seen in the areola.</p>

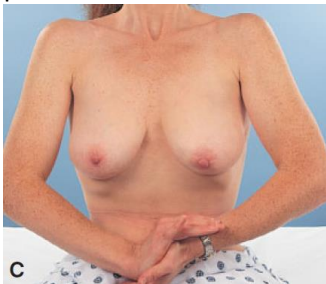	vary in size. Small Montgomery tubercles are present.	
<p>5- Inspect the nipples.</p> <ul style="list-style-type: none"> ✓ Note the size and direction of the nipples of both breasts. ✓ Also note any dryness, lesions, bleeding, or discharge. 	<p>Nipples are nearly equal bilaterally in size and are in the same location on each breast.</p> <p>Nipples are usually everted, but they may be inverted or flat.</p> <p>No discharge should be present.</p> <p><u>Older Adult Considerations</u> The older client may have smaller, flatter nipples that are less erectile on stimulation.</p>	<p>A recently retracted nipple that was previously everted suggests malignancy.</p>  <p>Any type of spontaneous discharge should be referred for cytologic study and further evaluation.</p>
<p>6- Inspect for retraction and dimpling.</p> <ul style="list-style-type: none"> ✓ To inspect the breasts accurately for retraction and dimpling, ask the client to remain seated while performing several different maneuvers. ✓ Ask the client to raise her arms overhead. 	<p>The client's breasts should rise symmetrically, with no sign of dimpling or retraction.</p>	<p>Dimpling or retraction is usually caused by a malignant tumor that has fibrous strands attached to the breast tissue and the fascia of the muscles. As the muscle contracts, it draws the breast tissue and skin with it, causing dimpling or retraction.</p>



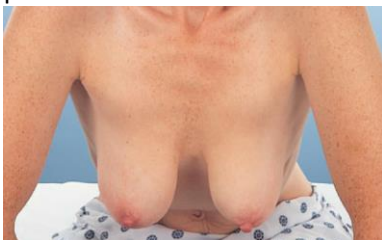
- ✓ then press her hands against her hips.



- ✓ Next ask her to press her hands together. These actions contract the pectoral muscles.



- ✓ Finally, ask the client to lean forward from the waist. The nurse should support the client by the hands or forearms. This is a good position to use in women who have large, pendulous breasts.



Breasts should hang freely and symmetrically.


Restricted movement of breast or retraction of the skin or nipple indicates fibrosis and fixation of the underlying tissues. This is usually due to an underlying malignant tumor.


PALPATION


1- Palpate texture and elasticity.

Palpation reveals smooth, firm, elastic tissue.

Thickening of the tissues may occur with an underlying malignant tumor.

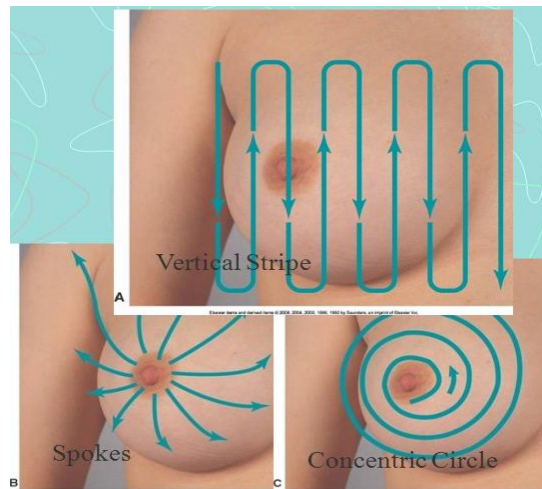
	<p><u>OLDER ADULT CONSIDERATIONS</u></p> <p>The older client's breasts may feel more granular, and the inframammary ridge may be more easily palpated as it thickens.</p>	
<p>2- Palpate for tenderness and temperature.</p> <ul style="list-style-type: none"> ✓ Help the woman to a supine position , place a small pillow under the side to be palpated and raise her arm over her head. ✓ Cover one breast with the gown while examining the other ✓ Use superficial then deep palpation using gentle rotator motion. <p>Palpation technique of breast:</p> <ol style="list-style-type: none"> 1- Parallel line 2- Spokes on a wheel 3- Concentric circle 	<p>A generalized increase in nodularity and tenderness may be a normal finding associated with the menstrual cycle or hormonal medications. Breasts should be a normal body temperature.</p> <p>The non pregnant female breast is normally firm, smooth and elastic .</p> <p>-From midcycle up to menstruation the breast is :</p> <ul style="list-style-type: none"> *slightly enlarged , *tender to palpation *generalized nodularity <p><u>-During the 3-4 days before menstruation the breast feel</u> full, tight, heavy and occasionally sore</p> <p><u>-On days 4 to 7 of the menstrual cycle</u> the breast volume is smallest(this is the best time to perform breast examination)</p>	<p>Painful, tender breasts may be indicative of fibrocystic breasts, especially right before menstruation.</p> <p>However, pain may also occur with a malignant tumor.</p> <p>Heat in the breasts of women who have not just given birth or who are not lactating indicates inflammation.</p>
<p>3- Palpate for masses.</p> <ul style="list-style-type: none"> ✓ Note location, size in centimeters, shape, mobility, consistency, and tenderness. Also note the condition 	<p>No masses should be palpated. Firm inframammary transverse</p>	<p>Malignant tumors are most often found in the upper outer quadrant of the breast, usually unilateral, with</p>

<p>of the skin over the mass.</p> <ul style="list-style-type: none"> ✓ If you detect any lump, patient is referred for further evaluation. <p>Remember, take note of:</p> <ul style="list-style-type: none"> ✓ Location : Using the breast as a clock face , describe the distance in centimeters from the nipple , e.g. (7:00 , 2 cm from the nipple) Or four quadrant method . ✓ Size : judge in centimeters in three dimensions width X Length X thickness. ✓ Shape : Oval, round , lobulated or indistinct. ✓ Consistency : if the lump soft, firm or hard. ✓ Mobility : freely movable or fixed ✓ Number : Solitary or multiple ✓ Tenderness : tender to palpate 	<p>ridge may normally be palpated at the lower base of the breasts.</p> <p>Fibrocystic breast tissue that feels ropy, lumpy, or bumpy in texture is referred to as “nodular” or “glandular” breast tissue.</p> <p>Benign breast disease consists of bilateral multiple, firm, regular, rubber, mobile, nodules with well-demarcated border. Pain and fullness occurs just before menses.</p>	<p>irregular, poorly delineated borders. They are hard, and nontender and fixed to underlying tissues.</p> <p>Fibroadenomas – usually 1-5cm, round or oval, mobile, firm, solid, elastic, nontender, single or multiple benign masses found in one or both breasts.</p> <p>Milk cysts (sacs filled with milk) and infections (mastitis), may turn into an abscess and occur if breastfeeding or recently given birth.</p> <p>Bruising from injury will have a blood collection that appears as lump, which goes away in days or weeks.</p> <p>Lipomas are collection of fatty tissue that may also appear as lump.</p>
<p>4- Palpate the nipples.</p> <ul style="list-style-type: none"> ✓ Wear gloves to compress the nipple gently with your thumb and index finger. ✓ Note any discharge. If spontaneous discharge occurs from the nipples, a specimen must be applied to a slide and the smear sent to the laboratory for cytologic evaluation. 	<p>The nipple may become erect and the areola may pucker in response to stimulation. A milky discharge is usually normal only during pregnancy and lactation. However, some women may normally have a clear discharge.</p>	<p>Discharge may be seen in endocrine disorders and with certain medications</p> <p>Discharge from one breast may indicate benign intraductal papilloma, fibrocystic disease, or cancer of the breast.</p> <p>Sometimes there is only a watery, pink discharge from the nipple. This should be referred to a primary care provider.</p>
<p>5- Palpate mastectomy or lumpectomy site.</p> <ul style="list-style-type: none"> ✓ If the client has had a mastectomy or lumpectomy, it is still important to perform a thorough examination. 	<p>Scar is whitish with no redness or swelling. No lesions, lumps, or tenderness noted.</p>	<p>Redness and inflammation of the scar area may indicate infection. Any lesions, lumps, or tenderness should be referred for further evaluation.</p>

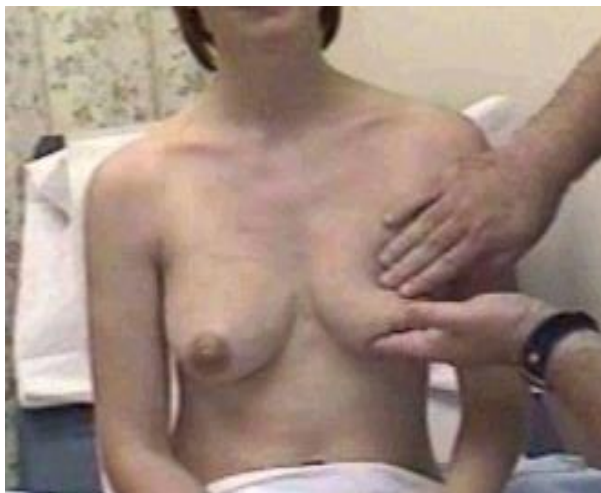<ul style="list-style-type: none"> ✓ Palpate the scar and any remaining breast or axillary tissue for redness, lesions, lumps, swelling, or tenderness . 		
THE AXILLAE		
INSPECTION AND PALPATION		
<p>1- Inspect and palpate the axillae.</p> <ul style="list-style-type: none"> ✓ Ask the client to sit up. ✓ Inspect the axillary skin for rashes or infection. 	No rash or infection noted.	<p>Redness and inflammation may be seen with infection of the sweat gland.</p> <p>Dark, velvety pigmentation of the axillae (acanthosis nigricans) may indicate an underlying malignancy.</p>
<ul style="list-style-type: none"> ✓ Hold the client's elbow with one hand, and use the three finger pads of your other hand to palpate firmly the axillary lymph nodes. ✓ First palpate high into the axillae, moving downward against the ribs to feel for the central nodes. ✓ Continue to move down the posterior axillae to feel for the posterior nodes. ✓ Use bimanual palpation to feel for the anterior axillary nodes. Finally palpate down the inner aspect of the upper arm. 	No palpable nodes or one to two small (less than 1 cm), discrete, non tender, movable nodes in the central area.	<p>Enlarged (greater than 1 cm) lymph nodes may indicate infection of the hand or arm. Large nodes that are hard and fixed to the skin may indicate an underlying malignancy</p>

ASSESSMENT GUIDE: PALPATING THE BREASTS

1. Ask the client to lie down and to place overhead the arm on the same side as the breast being palpated. Place a small pillow or rolled towel under the breast being palpated.
2. Use the flat pads of three fingers to palpate the client's breasts.
3. Palpate the breasts using one of three different patterns. Choose one that is most comfortable for you, but be consistent and thorough with the method chosen.



4. Be sure to palpate every square inch of the breast, from the nipple and areola to the periphery of the breast tissue and up into the tail of Spence. Vary the levels of pressure as you palpate.
 - ✓ Light—superficial
 - ✓ Medium—mid-level tissue
 - ✓ Firm—to the ribs
5. Use the bimanual technique if the client has large breasts. Support the breast with your nondominant hand and use your dominant hand to palpate.





King Saud University
College of Nursing
Medical-Surgical Nursing

Application of Health Assessment
NURS 225

Performance Checklist

Brest and axilla assessment

Students Name: _____ Rating: _____

Student Number: _____ Date Performed: _____

Performance Criteria	Competency Level			Comments
	Done correctly (2)	Done with assistance(1)	Not done	
Obtain the health history				
Prepare required equipment.				
Explain procedure to patient.				
Wash hands.				
Put the patient in the desired position. (sitting and supine positions)				
Expose body part to be examined and Drape patient appropriately .				
Compare findings of any side of body to the other .				
Follow the inspection & palpation techniques				
Inspection of the breast				
Inspect size and symmetry				
Inspect color and texture				
Inspect superficial venous pattern				

Inspect areolas (Note color, size, shape and texture)				
Inspect the nipples. (Note size, direction of the nipples. Also, note of any dryness, lesions, bleeding or discharge).				
Inspect for retraction and dimpling. Instruct client to do different positions: <ol style="list-style-type: none"> Raise her arms overhead (seated position) Press her hands against her hips (seated position) Press her hands together (to contract pectoral muscles) For pendulous or large breast, the nurse ask the client to lean forward from the waist while supporting the client by the hands or forerams. 				
Palpation				
Palpate texture and elasticity. Palpation Techniques: <ul style="list-style-type: none"> ✓ Parallel line ✓ Spokes on a wheel ✓ Concentric circle 				
Palpate for tenderness and temperature.				
Palpate the nipples. (Note any discharges)				
Palpate mastectomy or lumpectomy site. (Note scar and any remaining breast or axillary tissue for redness, lesions, lumps, swelling or tenderness).				
Inspection and Palpation of Axilla				
Inspect axillary skin for rashes or infection. (sitting position)				
Palpate axillary lymph nodes.				

Evaluated by: _____

Date Evaluated: _____