

Neck Mass Diagnosis Work Up & Management

Khalid Hussain AL-Qahtani

MD,MSc,FRCSC(c)

Assistant Professor

Consultant of Otolaryngology

Advance Head & Neck Oncology , Thyroid
& Parathyroid, Microvascular
Reconstruction, and Skull Base Surgery

Introduction

- Common clinical finding
- All age groups
- Very complex differential diagnosis
- Age, Location and Time line
- Systematic approach essential

Diagnostic Steps

- History

- Developmental time course
- Associated symptoms (dysphagia, otalgia, voice)
- Personal habits (tobacco, alcohol)
- Previous irradiation or surgery

- Physical Examination

- Complete head and neck exam (visualize & palpate)
- Emphasis on location, mobility and consistency

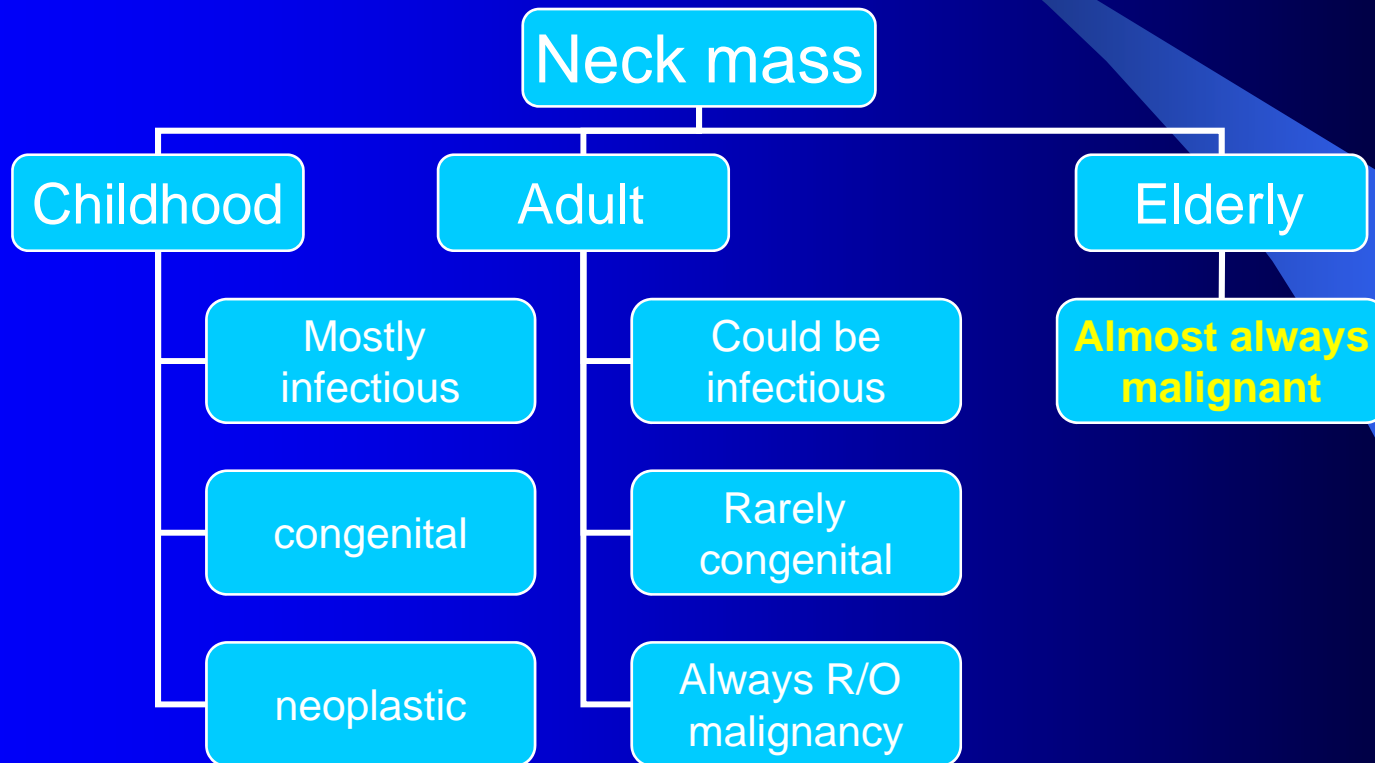
Alarming sings

- Hoarseness
- Unilateral nasal blockage
 - In children
 - In adult and elderly
- Ear pain with normal exam
- Epistaxis
 - In adult
 - In children
- Neck mass
- None healing ulcer
- Facial weakness or numbness
- Dysphagia or odynophagia
- Diplopia
- Pain with denture or poorly fitting denture

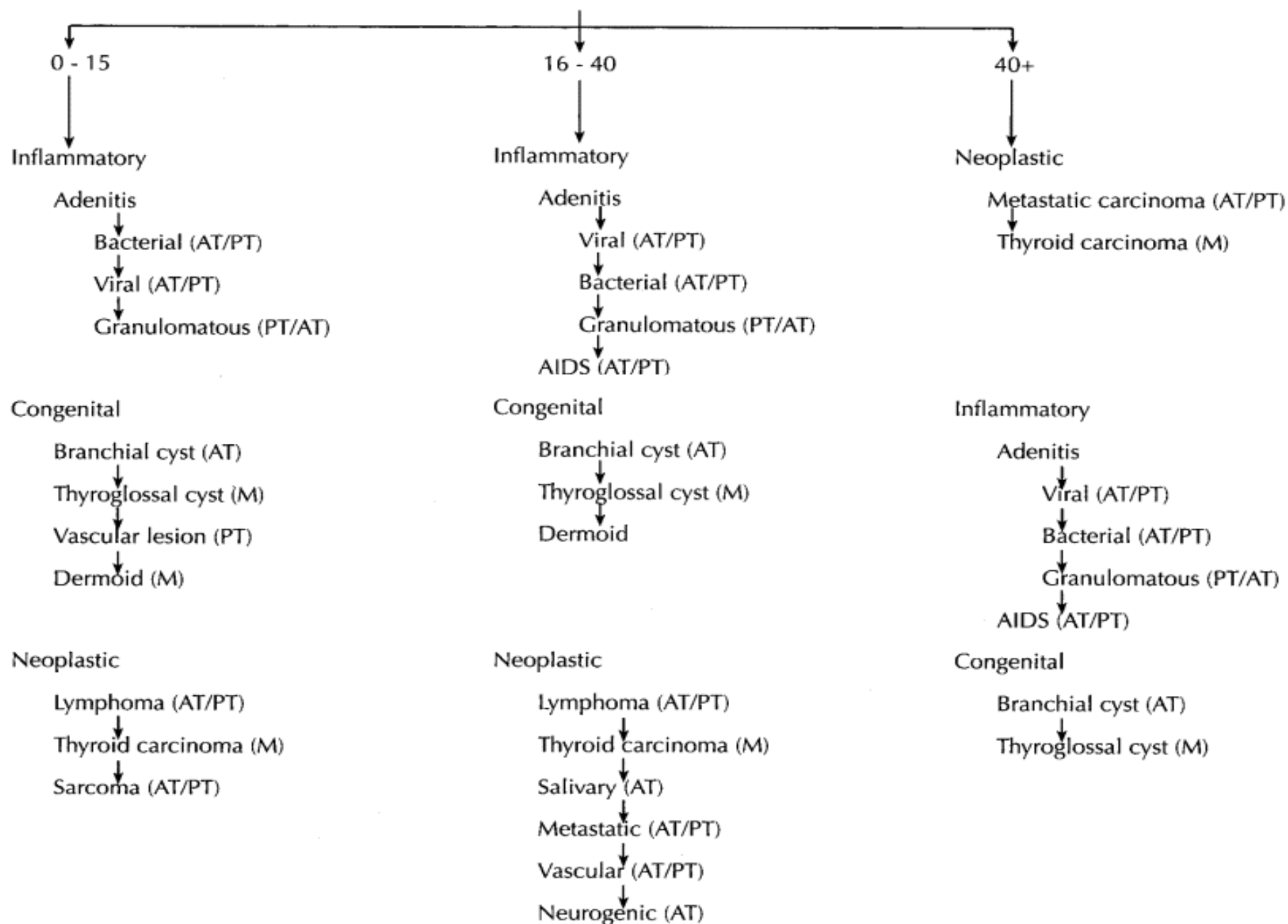
Risk Factors

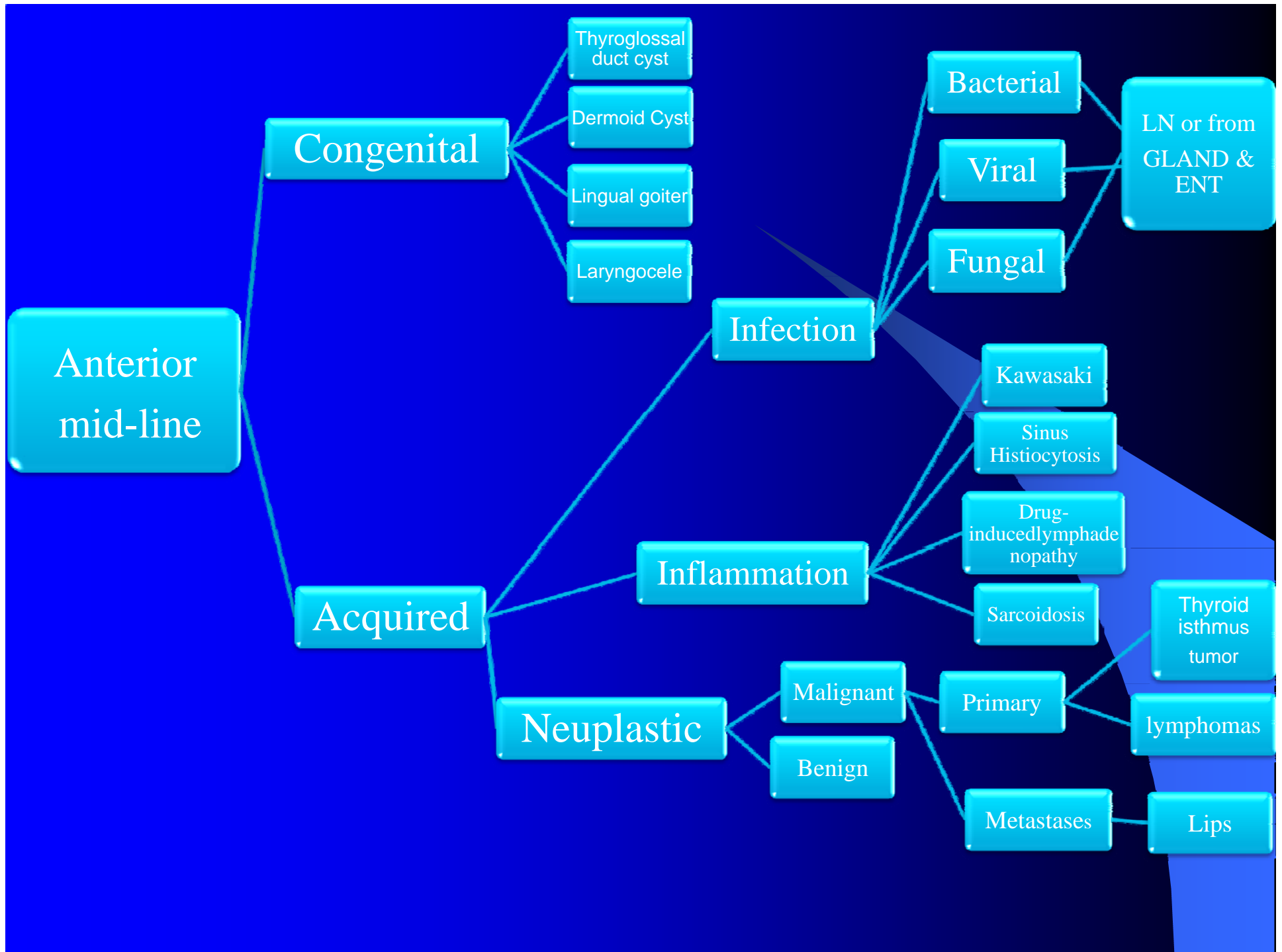
- Smoking
- Alcohol
- Wood dust exposure
- Sun exposure
- Previous burn or scar
- Family history
- Immune deficiency
- History of other cancer

Age



RELATIVE FREQUENCY OF SPECIFIC NECK MASSES WITHIN CAUSATIVE GROUPS BY AGE (Years)





Anterior triangle

Congenital

- Branchial cyst
- Thymic cyst
- Hemangioma
- Torticollis

Acquired

Infection And inflammation
SAME AS above

Acquired

● **Benign**

- i. Lipoma
- ii. Neurofibroma
- iii. Carotid body tumour
- iv. Salivary G lesions
- v. Thyroid

● **Malignant**

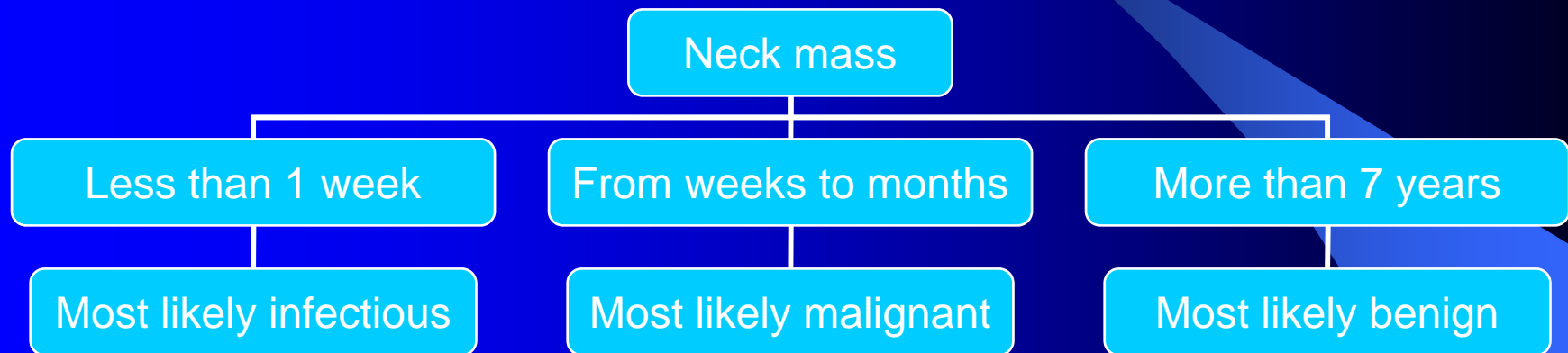
● **Primary**

Same as benign

Posterior triangle

- **Congenital :**
Lymphangioma (cystic hygroma)
- **Acquired:**
Lymphadenitis
Lymphoma
Metastatic ca.

Time line



General Considerations

- Patient age
 - Pediatric (0 – 15 years): 90% benign
 - Young adult (16 – 40 years): similar to pediatric
 - Late adult (>40 years): “rule of 80s”
- Location
 - Congenital masses: consistent in location
 - Metastatic masses: key to primary lesion
- Time Line

Empirical Antibiotics

- Inflammatory mass suspected
- Two week trial of antibiotics
- Follow-up for further investigation

Diagnostic Tests

- Fine needle aspiration biopsy (FNAB)
- Computed tomography (CT)
- Magnetic resonance imaging (MRI)
- Ultrasonography
- Radionucleotide scanning

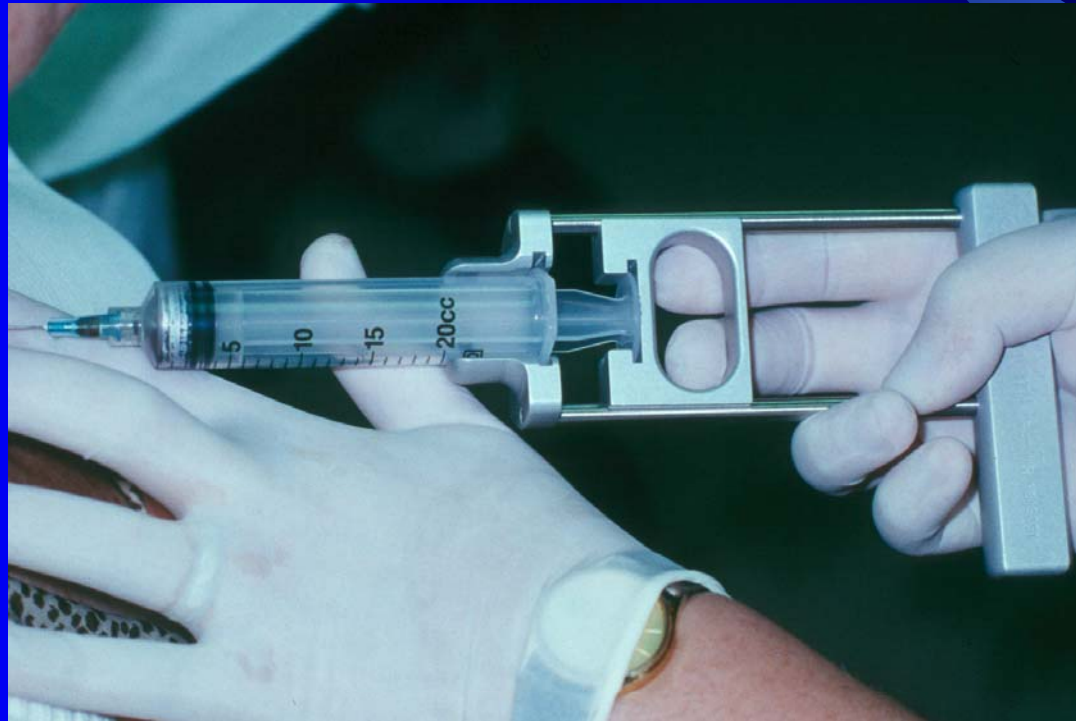
Fine Needle Aspiration Biopsy

- Standard of diagnosis
- Indications
 - Any neck mass that is not an obvious abscess
 - Persistence after a 2 week course of antibiotics
- Small gauge needle
 - Reduces bleeding
 - Seeding of tumor – not a concern
- No contraindications (vascular ?)

Fine Needle Aspiration Biopsy

- Proper collection required
- Minimum of 4 separate passes
- Skilled cytopathologist essential
- On-site review best

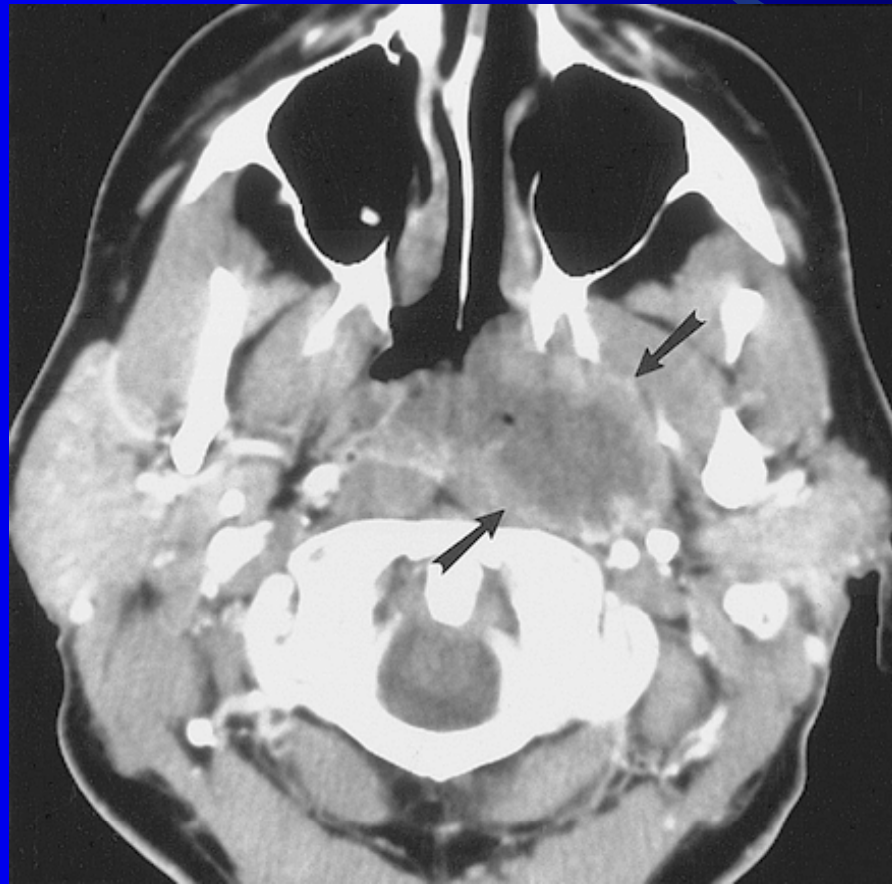
Fine Needle Aspiration Biopsy



Computed Tomography

- Distinguish cystic from solid
- Extent of lesion
- Vascularity (with contrast)
- Detection of unknown primary (metastatic)
- Pathologic node (lucent, >1.5cm, loss of shape)
- Avoid contrast in thyroid lesions

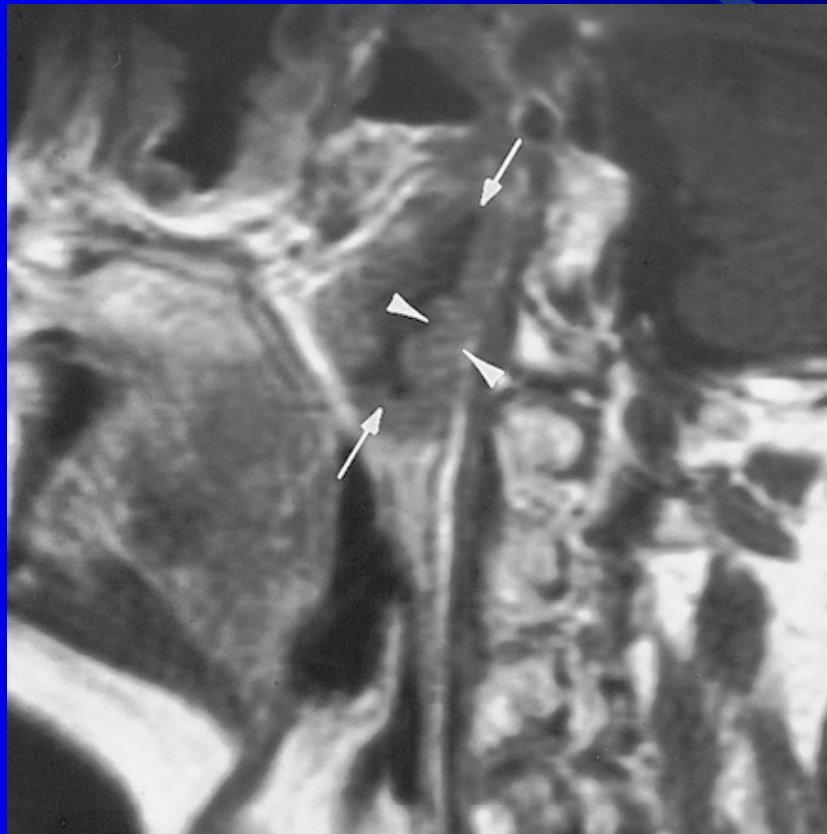
Computed Tomography



Magnetic Resonance Imaging

- Similar information as CT
- Better for upper neck and skull base
- Vascular delineation with infusion

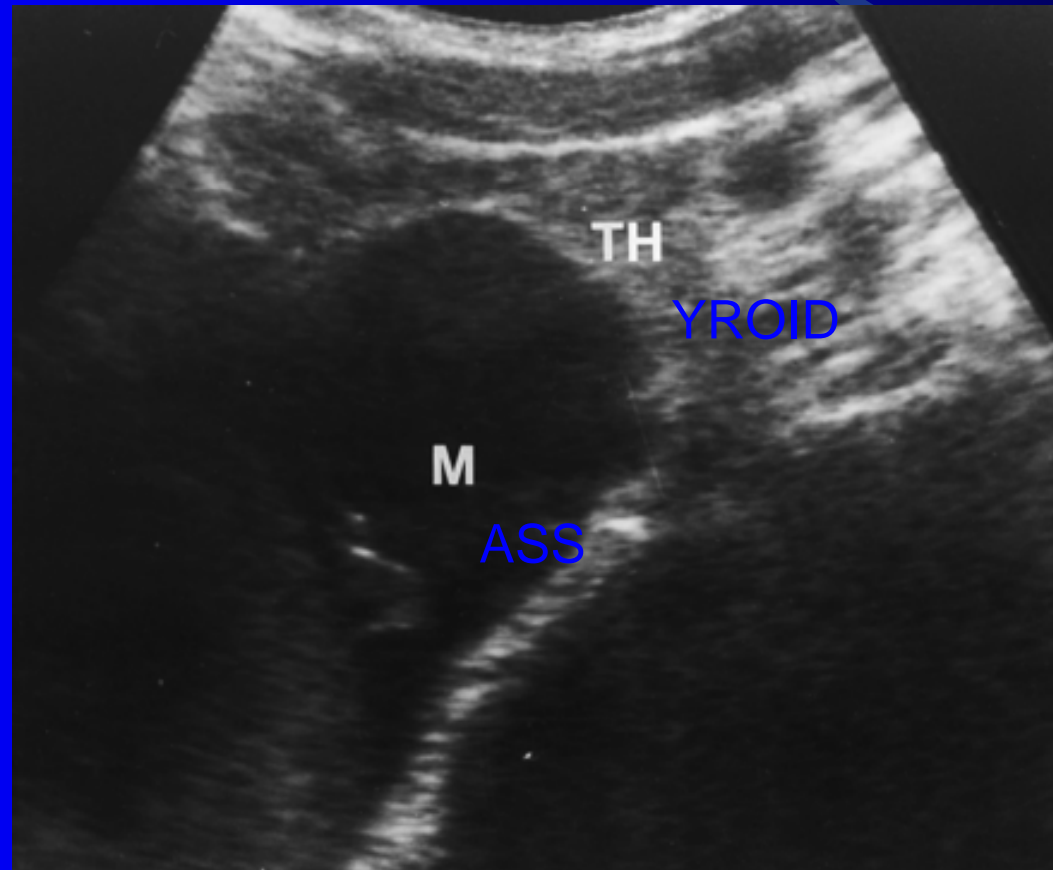
Magnetic Resonance Imaging



Ultrasonography

- Less important now with FNAB
- Solid versus cystic masses
- Congenital cysts from solid nodes/tumors
- Noninvasive (pediatric)

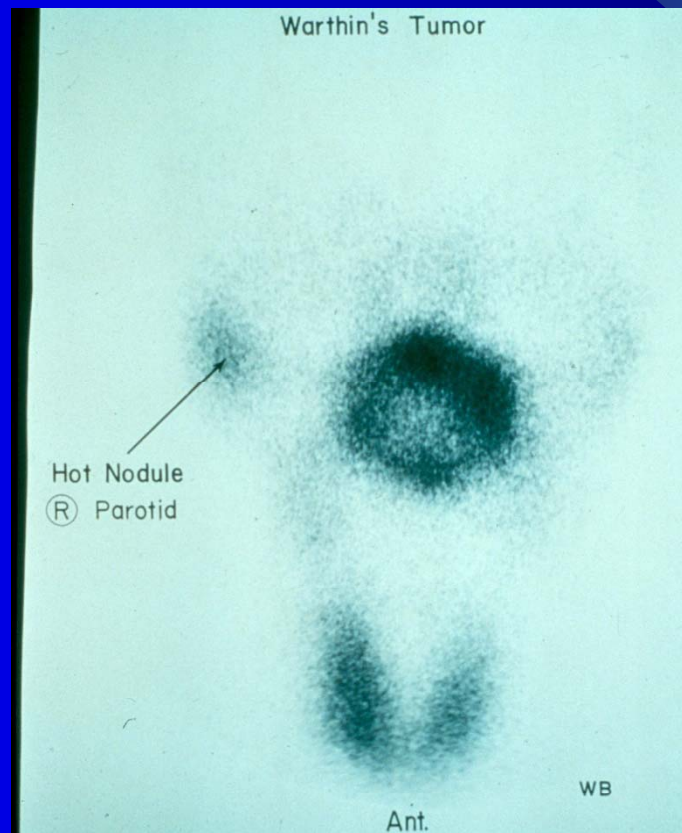
Ultrasonography



Radionuclide Scanning

- Salivary and thyroid masses
- Location – glandular versus extra-glandular
- Functional information

Radionuclide Scanning



Nodal Mass Workup in the Adult

- Any solid asymmetric mass **MUST** be considered a metastatic neoplastic lesion until proven otherwise
- Asymptomatic cervical mass – 12% of cancer
- ~ 80% of these are SCCa

Nodal Mass Workup in the Adult

- Ipsilateral otalgia with normal otoscopy – direct attention to tonsil, tongue base, supraglottis and hypopharynx
- Unilateral serous otitis – direct examination of nasopharynx

Nodal Mass Workup in the Adult

- Panendoscopy
 - FNAB positive with no primary on repeat exam
 - FNAB equivocal/negative in high risk patient
- Directed Biopsy
 - All suspicious mucosal lesions
 - Areas of concern on CT/MRI
 - None observed – nasopharynx, tonsil (ipsilateral tonsillectomy for jugulodigastric nodes), base of tongue and piriforms
- Synchronous primaries (10 to 20%)

Nodal Mass Workup in the Adult

- Unknown primary
 - University of Florida (August, 2001)
 - Detected primary in 40%
 - Without suggestive findings on CT 20%
 - Tonsillar fossa in 80%

Nodal Mass Workup in the Adult

- Open excisional biopsy
 - Only if complete workup negative
 - Occurs in ~5% of patients
 - Be prepared for a complete neck dissection
 - Frozen section results (complete node excision)
 - Inflammatory or granulomatous – culture
 - Lymphoma or adenocarcinoma – close wound

Head and Neck Cancer

- Head and neck cancer makes up about 10 % of all malignancies excluding skin.
- Approximately 32,000 new cases are diagnosed in the USA yearly.
- Surgery is involved as part of the treatment in most cases

Etiology

- Squamous cell carcinoma of the head and neck arises from the accumulation of multiple genetic alterations to genes important to the regulation of cellular growth and death.
- These alterations may be inherited but are more often acquired from exposure to environmental agents

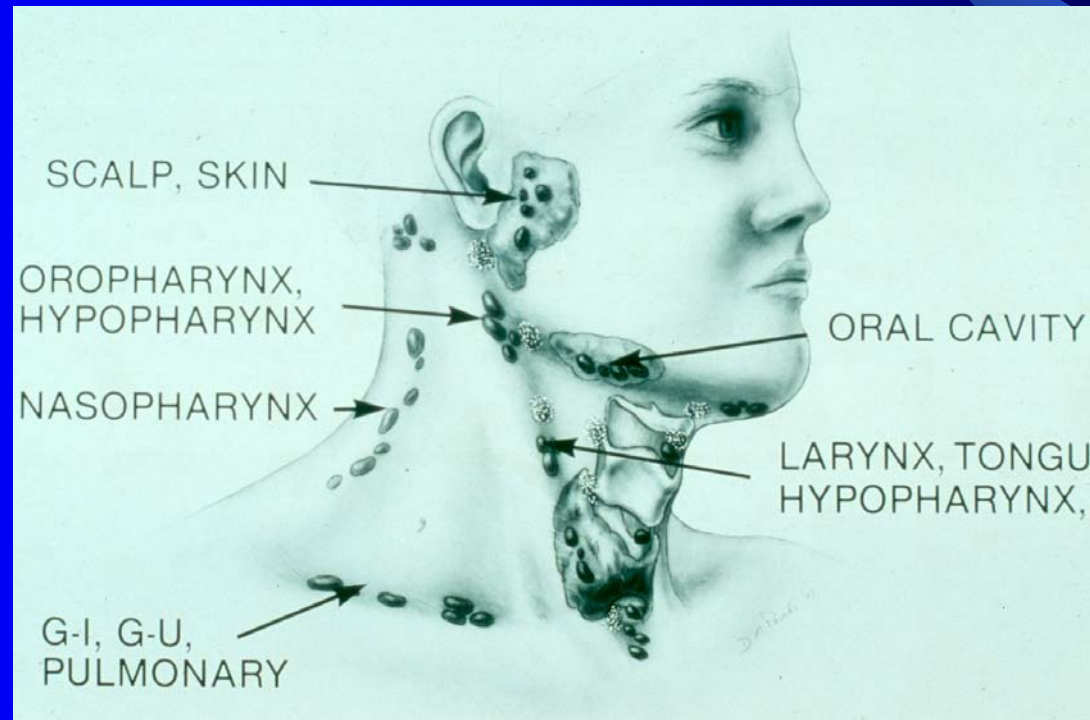
Natural History

- SCC starts on the surface and spreads superficially, deeply, and submucosally.
- Lymphatic metastasis are common in advanced tumors.
- Distant metastasis are rare

Natural History

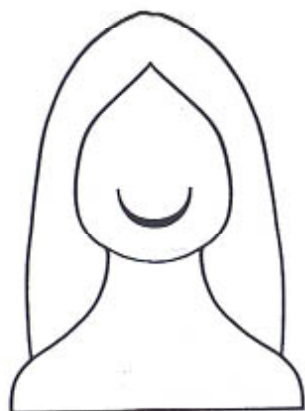
- Status of the cervical lymph nodes important prognostic factor in SCCA of the upper aerodigestive tract
- Cure rates drop in half when there is regional lymph node involvement

Metastasis Location according to Various Primary Lesions

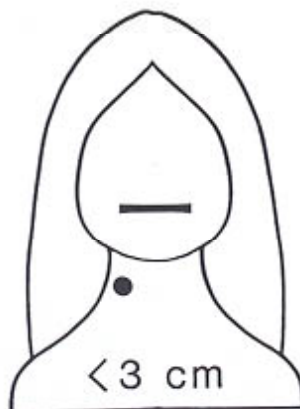


Staging of the neck

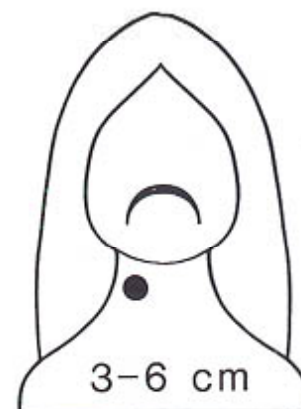- “N” classification – AJCC (1997)
- Consistent for all mucosal sites except the nasopharynx
- Thyroid and nasopharynx have different staging based on tumor behavior and prognosis
- Based on extent of disease prior to first treatment



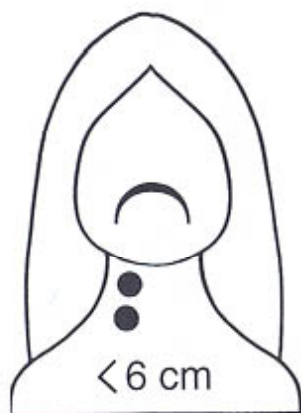
N_0



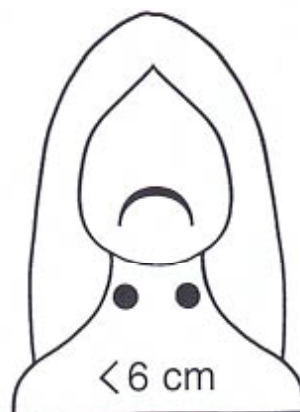
N_1



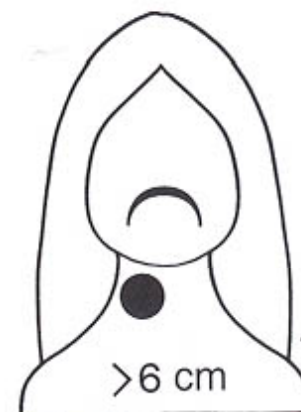
N_{2a}



N_{2b}



N_{2c}



N_3

Staging of the neck

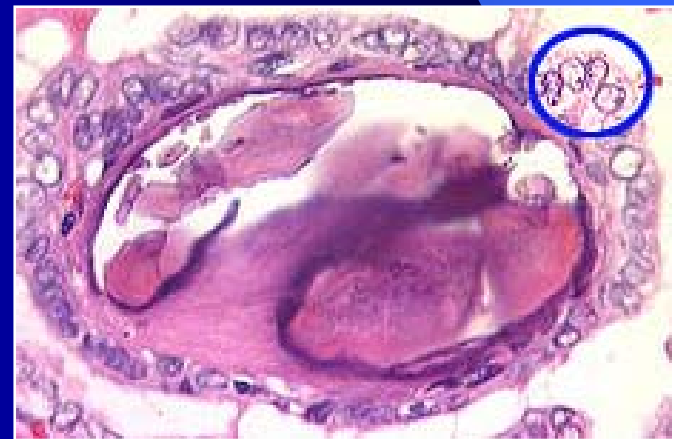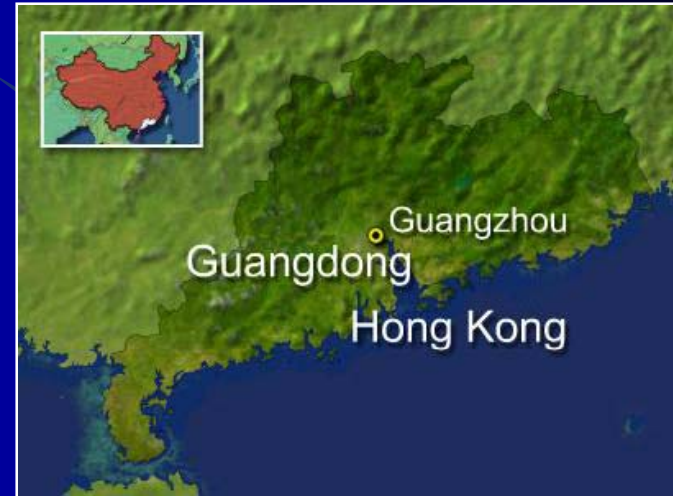- NX: Regional lymph nodes cannot be assessed
- N0: No regional lymph node metastasis
- N1: Metastasis in a single ipsilateral lymph node, ≤ 3
- N2a: Metastasis in a single ipsilateral lymph node 3 to 6 cm

Staging of the Neck

- N2b: Metastasis in multiple ipsilateral lymph nodes, none more than 6 cm
- N2c: Metastasis in bilateral or contralateral nodes ≤ 6 cm
- N3: Metastasis in a lymph node more than 6 cm in greatest dimension

Staging

- Nasopharyngeal Carcinoma
 - N1 – Unilateral < 6cm
 - N2 – Bilateral < 6 cm
 - N3a > 6 cm
 - N3b – Extension to supraclavicular fossa
- Thyroid
 - N1 – Regional node mets
 - N1a - Ipsilateral
 - N1b - Bilateral, midline, contralateral cervical or mediastinal LN



Lymph node levels/Nodal regions

- Developed by Memorial Sloan-Kettering Cancer Center
- Ease and uniformity in describing regional nodal involvement in cancer of the head and neck

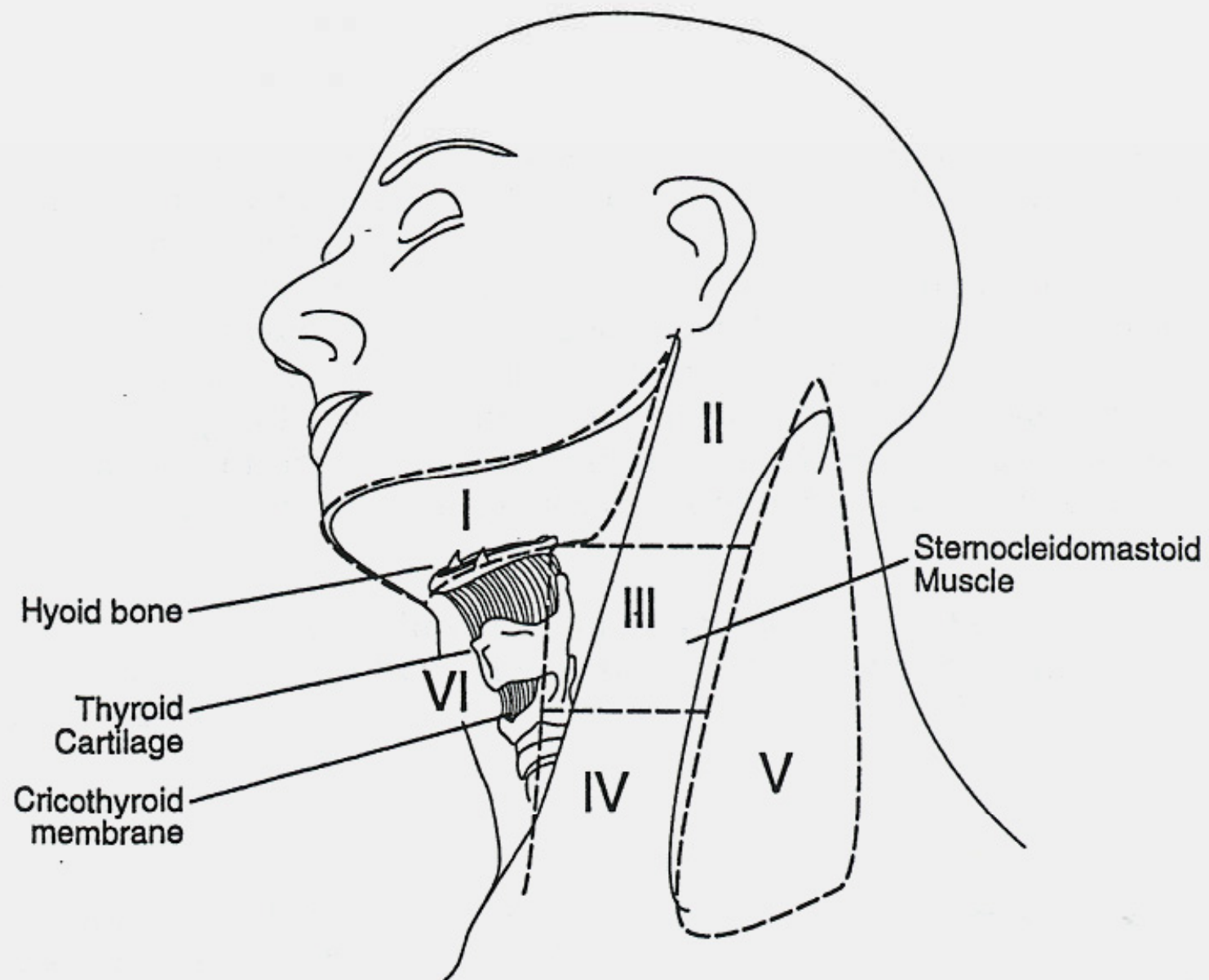


FIG. 1. Schematic diagram indicating the location of the lymph node levels in the neck as described in the text.

- Level I: Submental and submandibular triangles

Lymph node levels/Nodal regions

- Levels II, III, IV: nodes associated with IJV within fibroadipose tissue (posterior border of SCM and lateral border of sternohyoid)

Lymph node levels/Nodal regions

- Level II: Upper third jugular chain, jugulodigastric, and upper posterior cervical nodes
 - Boundaries - hyoid bone (clinical landmark) or carotid bifurcation (surgical landmark)

Lymph node levels/Nodal regions

- Level III: Middle jugular nodes
 - Boundaries - Inferior border of level II to cricothyroid notch (clinical landmark) or omohyoid muscle (surgical landmark)
- Level IV: Lower jugular nodes
 - Boundaries inferior border of level III to clavicle.

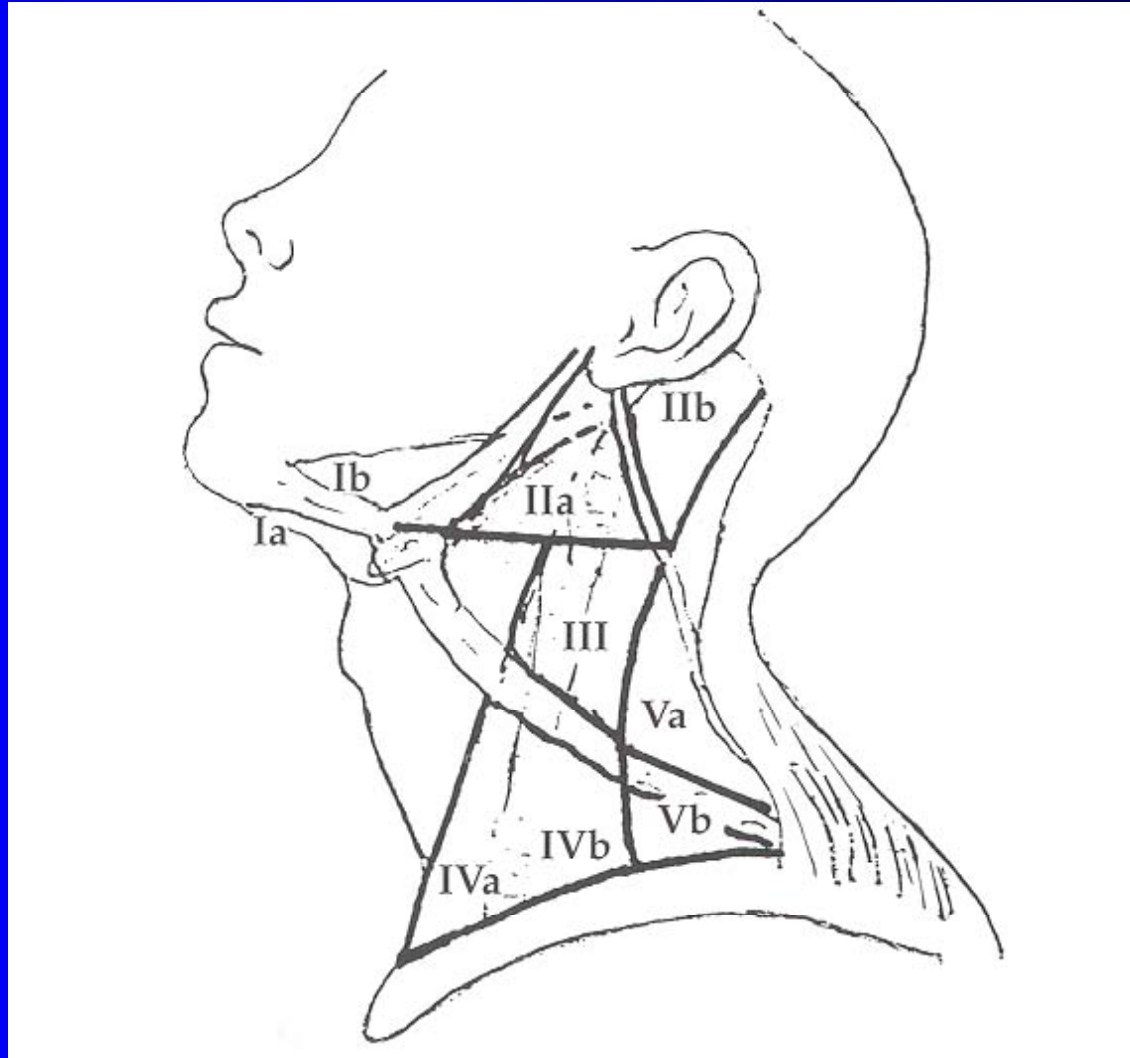
Lymph node levels/Nodal regions

- Level V: Posterior triangle of neck
 - Boundaries - posterior border of SCM, clavicle, and anterior border of trapezius

Lymph node levels/Nodal regions

- Level VI: Anterior compartment structures (hyoid, suprasternal notch, medial border of carotid sheath)

Subzones of Levels I-V



Rationale for subzones

- Suggested by Suen and Goepfert (1997)
- Biologic significance for lymphatic drainage depending on site of tumor
 - Level I subzones
 - Lower lip, FOM, ventral tongue – Ia
 - Other oral cavity subsites – Ib, II, and III

Rationale for Subzones

- Level II subzones
 - Oropharynx and nasopharynx – IIb
 - XI should be mobilized
 - Oral cavity, larynx and hypopharynx – may not be necessary to dissect IIb if level IIa is not involved
- Level IV subzones
 - Level IVa nodes – increased risk in Level VI
 - Level IVb nodes – increased risk in Level V

Rationale for Subzones

- Level V subzones

- Oropharynx, nasopharynx, and cutaneous – Va
- Thyroid - Vb

Classification of Neck Dissections

- Standardized until 1991
- Academy's Committee for Head and Neck Surgery and Oncology publicized standard classification system

Classification of Neck Dissections

- Academy's classification
 - Based on 4 concepts
 - 1) RND is the standard basic procedure for cervical lymphadenectomy against which all other modifications are compared
 - 2) Modifications of the RND which include preservation of any non-lymphatic structures are referred to as modified radical neck dissection (MRND)

Classification of Neck Dissections

- Academy's classification
 - 3) Any neck dissection that preserves one or more groups or levels of lymph nodes is referred to as a selective neck dissection (SND)
 - 4) An extended neck dissection refers to the removal of additional lymph node groups or non-lymphatic structures relative to the RND

Classification of Neck Dissections

- Academy's classification
 - 1) **Radical neck dissection (RND)**
 - 2) **Modified radical neck dissection (MRND)**
 - 3) **Selective neck dissection (SND)**
 - **Supra-omohyoid type**
 - **Lateral type**
 - **Posterolateral type**
 - **Anterior compartment type**
 - 4) **Extended radical neck dissection**

Radical Neck Dissection

- Definition

- All lymph nodes in Levels I-V including spinal accessory nerve (SAN), SCM, and IJV

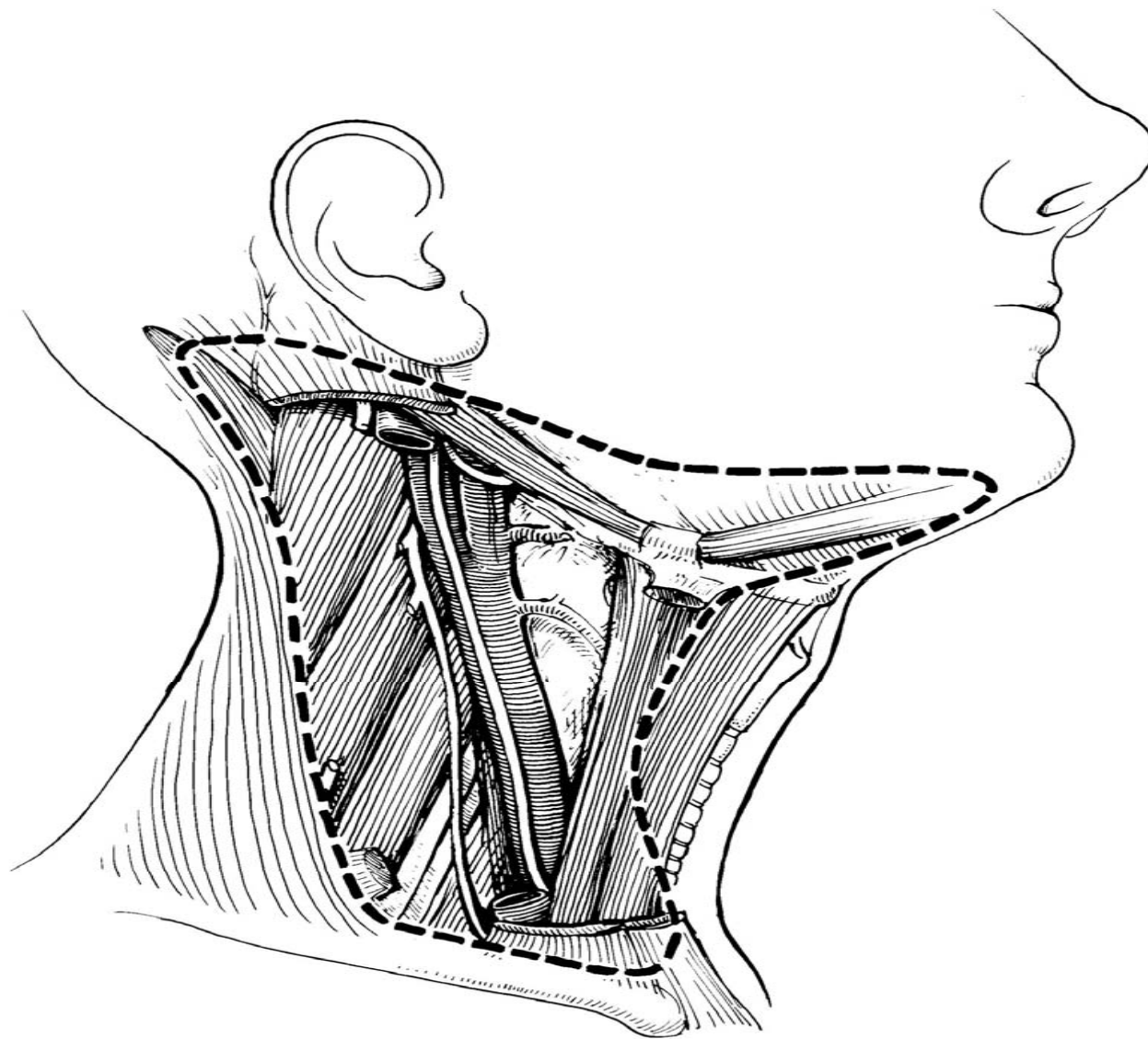


FIGURE 7-4
Extent of radical neck dissection.

Radical Neck Dissection

- Indications

- Extensive cervical involvement or matted lymph nodes with gross extracapsular spread and invasion into the SAN, IJV, or SCM

Modified Radical Neck Dissection (MRND)

- Definition

- Excision of same lymph node bearing regions as RND with preservation of one or more non-lymphatic structures (SAN, SCM, IJV)
- Spared structure specifically named
- MRND is analogous to the “functional neck dissection” described by Bocca

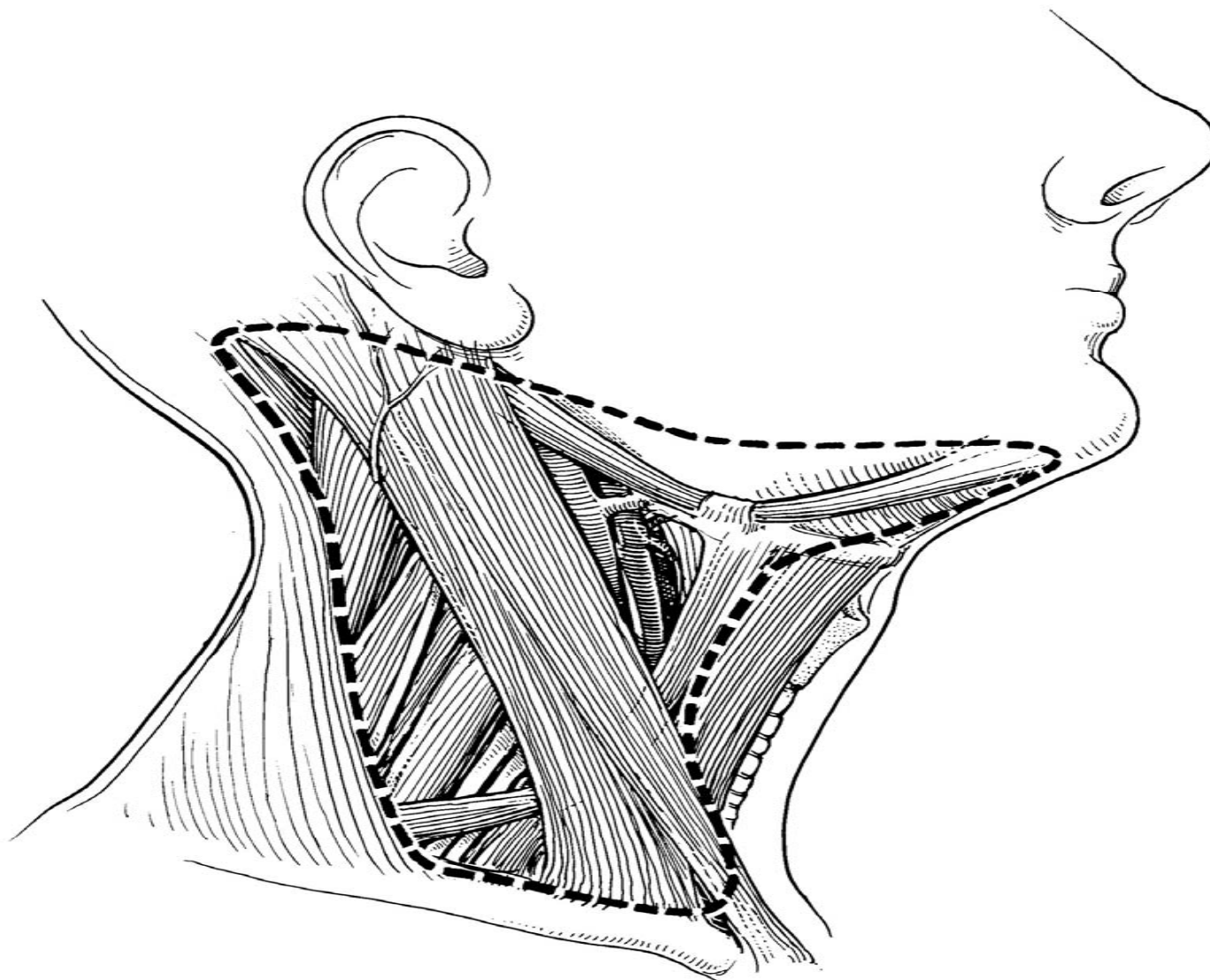
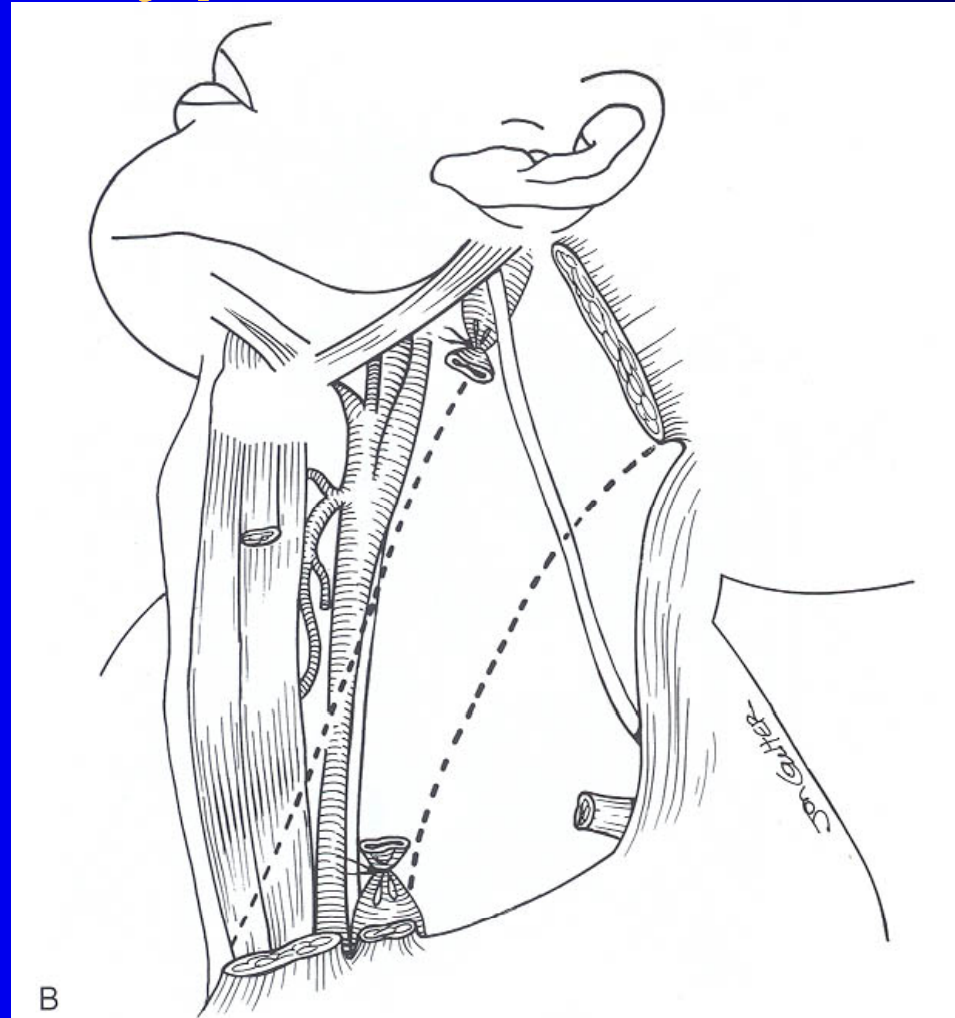


FIGURE 7-5
Extent of modified radical neck dissection.

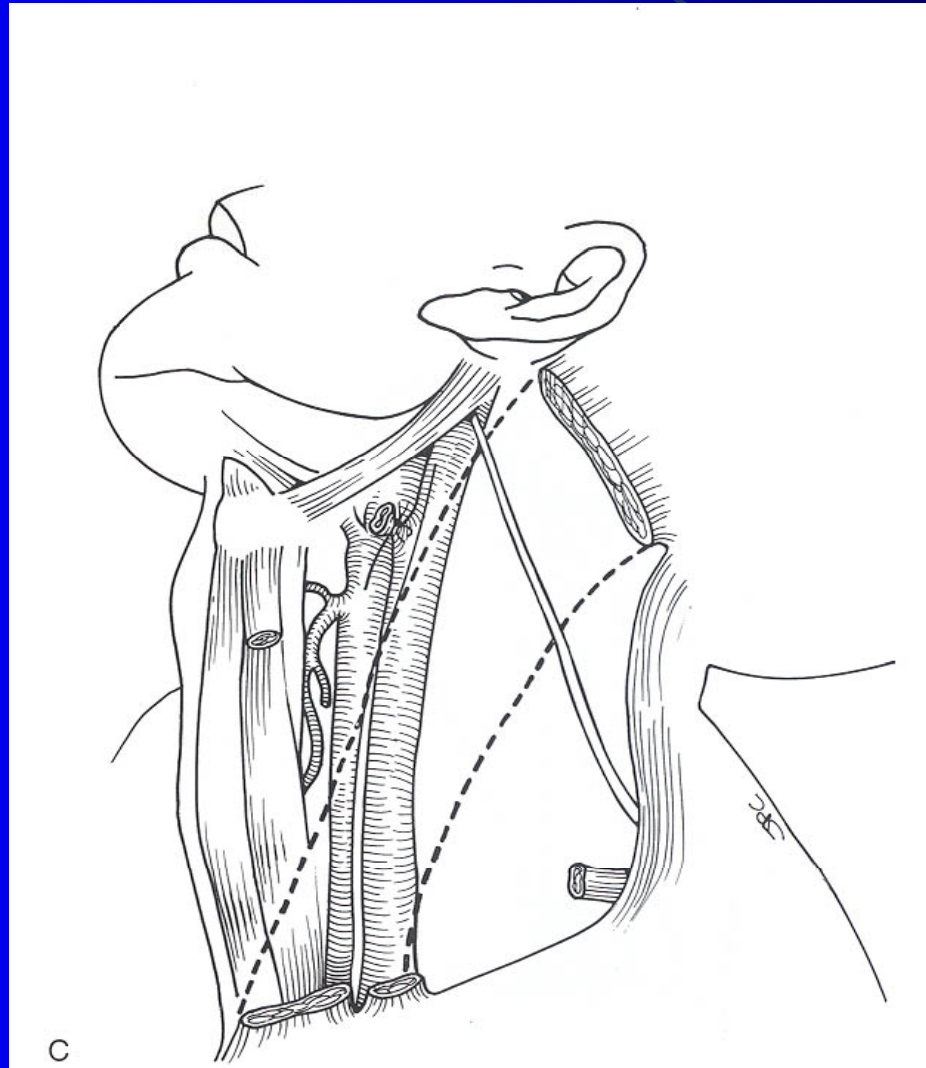
Modified Radical Neck Dissection

- Three types (Medina 1989) commonly referred to not specifically named by committee.
- Type I: Preservation of SAN
- Type II: Preservation of SAN and IJV
- Type III: Preservation of SAN, IJV, and SCM (“Functional neck dissection”)

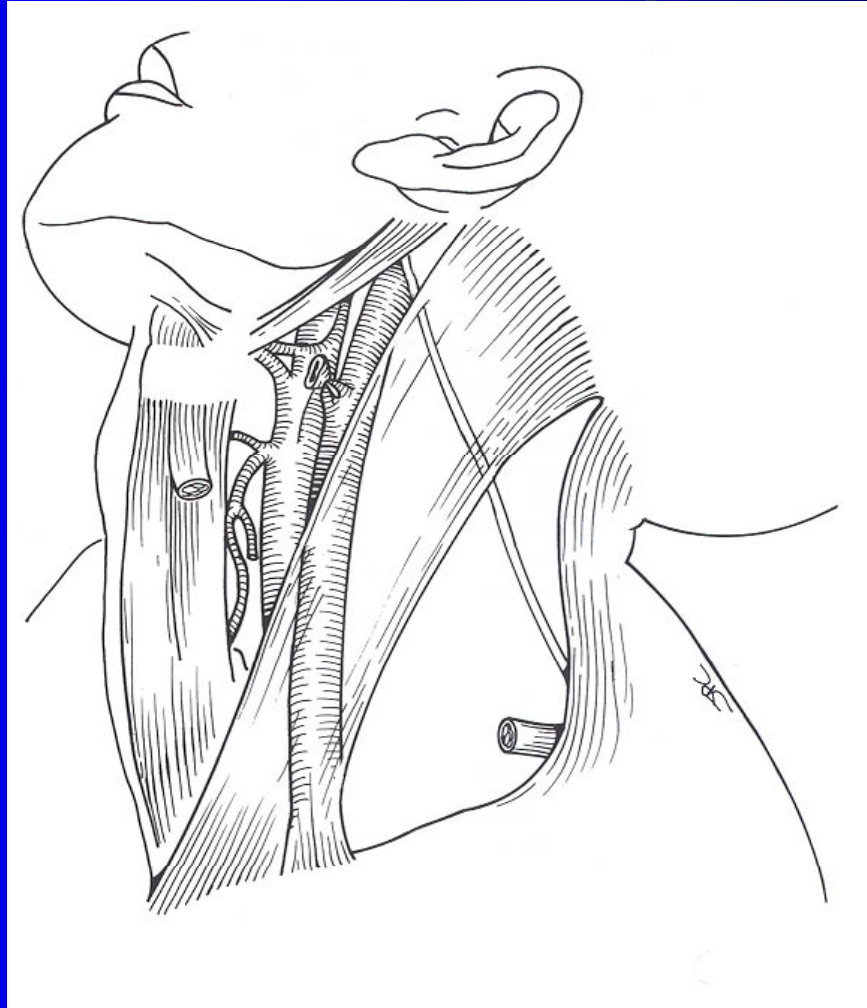
MRND Type I



MRND Type II



MRND Type III



MRND Type I

- Indications

- Clinically obvious lymph node metastases
- SAN not involved by tumor
- Intraoperative decision

MRND Type I

- Rationale

- RND vs MRND Type I:
- Actuarial 5-year survival and neck failure rates for RND (63% and 12%) not statistically different compared to MRND I (71% and 12%) (Andersen)
- No difference in pattern of neck failure

MRND Type II

- Indications

- Rarely planned
- Intraoperative tumor found adherent to the SCM, but not IJV and SAN

MRND TYPE III

- Rationale

- Suarez (1963) – necropsy and surgery specimens of larynx and hypopharynx – lymph nodes do not share the same adventitia as adjacent BV's
- Nodes not within muscular aponeurosis or glandular capsule (submandibular gland)
- Sharpe (1981) showed) 0% involvement of the SCM in 98 RND specimens despite 73 have nodal metastases
- Survival approximates MRND Type I assuming IJV, and SCM not involved

MRND Type III

- Widely accepted in Europe
- Neck dissection of choice for N1 neck

Modified Radical Neck Dissection

- Rationale

- Reduce postsurgical shoulder pain and shoulder dysfunction
- Improve cosmetic outcome
- Reduce likelihood of bilateral IJV resection
 - Contralateral neck involvement

Selective Neck Dissections

- Definition

- Cervical lymphadenectomy with preservation of one or more lymph node groups
- Four common subtypes:
 - Supraomohyoid neck dissection
 - Posterolateral neck dissection
 - Lateral neck dissection
 - Anterior neck dissection

SELECTIVE NECK DISSECTION

- Also known as an elective neck dissection
- Rate of occult metastasis in clinically negative neck 20-30%
- Indication: primary lesion with 20% or greater risk of occult metastasis
- Studies by Fisch and Sigel (1964) demonstrated predictable routes of lymphatic spread from mucosal surfaces of the H&N
- May elect to upgrade neck intraoperatively
- Frozen section needed to confirm SCCA in suspicious node (Rassekh)

SND: Supraomohyoid type

- Most commonly performed SND
- Definition
 - En bloc removal of cervical lymph node groups I-III
 - Posterior limit is the cervical plexus and posterior border of the SCM
 - Inferior limit is the omohyoid muscle overlying the IJV

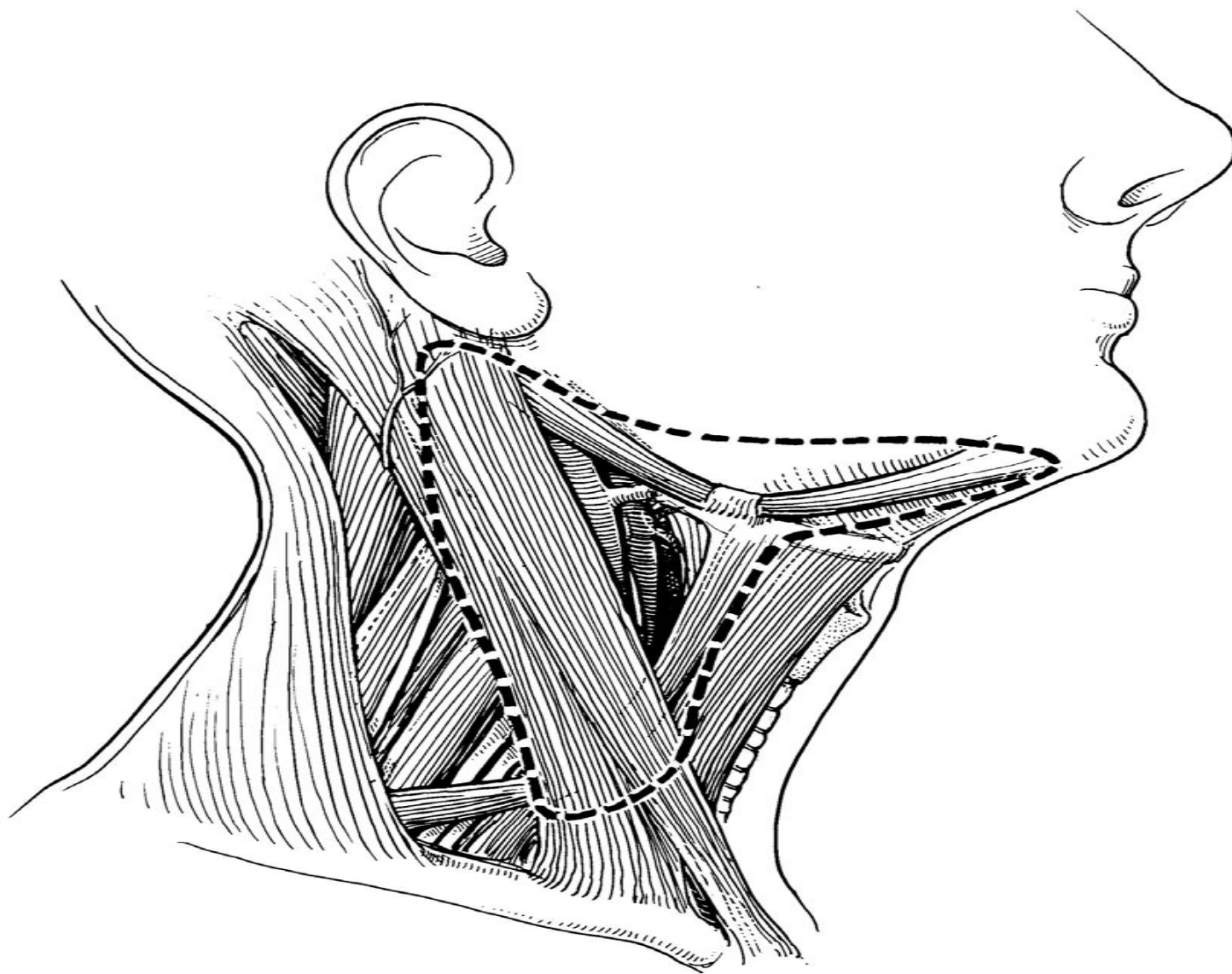


FIGURE 7-6

Extent of supraomohyoid selective neck dissection.

SND: Supraomohyoid type

- Indications

- Oral cavity carcinoma with N0 neck
 - Boundaries – Vermillion border of lips to junction of hard and soft palate, circumvallate papillae
 - Subsites - Lips, buccal mucosa, upper and lower alveolar ridges, retromolar trigone, hard palate, and anterior 2/3s of the tongue and FOM
- Medina recommends SOHND with T2-T4NO or TXN1 (palpable node is <3cm, mobile, and in levels I or II)

SND: Supraomohyoid type

- Bilateral SOHND
 - Anterior tongue
 - Oral tongue and FOM that approach the midline
- SOHND + parotidectomy
 - Cutaneous SCCA of the cheek
 - Melanoma (Stage I – 1.5 to 3.99mm) of the cheek
- Exceptions
 - inferior alveolar ridge carcinoma
 - Byers does not advocate elective neck dissection for buccal carcinoma
- Adjuvant XRT given to patients with > 2- 4 positive nodes +/- ECS.

SND: Supraomohyoid type

- Rationale

- Expectant management of the N0 neck is not advocated
- Based on Linberg's study (1972)
 - Distribution of lymph node mets in H&N SCCA
 - Subdigastric and midjugular nodes mostly affected in oral cavity carcinomas
 - Rarely involved Level IV and V

SND: Supraomohyoid type

- Hoffman (2001) oral cavity – combination of 5 reviews
 - Level I – 30.1%
 - Level II – 35.7%
 - Level III – 22.8%
 - Level IV – 9.1%
 - Level V - 2.2%

SND: Lateral Type

- Definition
 - En bloc removal of the jugular lymph nodes including Levels II-IV

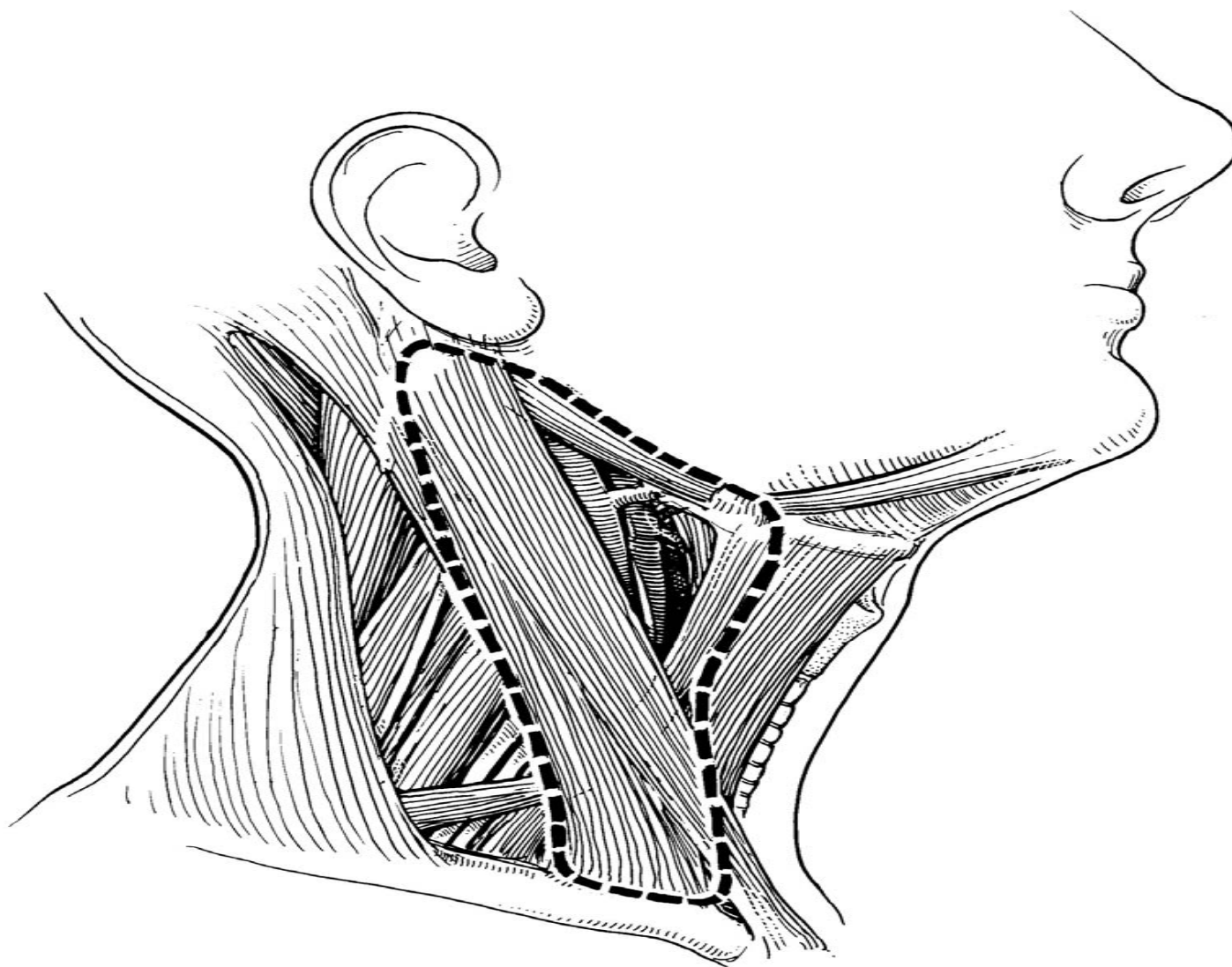


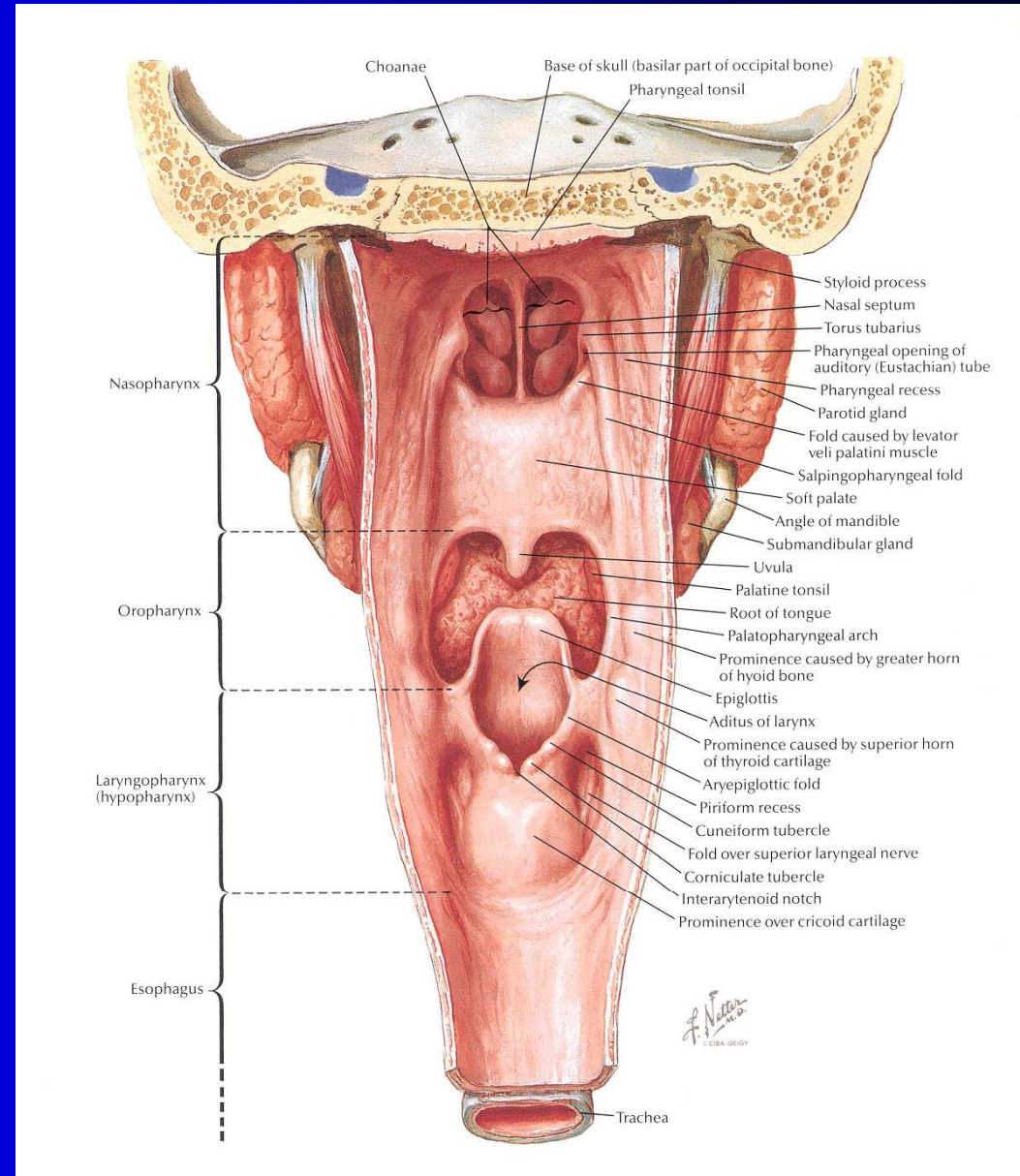
FIGURE 7-7
Extent of lateral selective neck dissection.

SND: Lateral Type

- Indications

- N0 neck in carcinomas of the oropharynx, hypopharynx, supraglottis, and larynx

- Oropharynx
 - Tonsils
 - Tonsillar pillars
 - Tonsillar fossa
 - Tongue base
 - Pharyngeal wall
- Hypopharynx
 - Pyriform sinus
 - Postcricoid
 - Pharyngeal wall
- Supraglottis
 - Epiglottis
 - Aryepiglottic folds
 - FVC
 - Sup. Ventricle
- Larynx
 - Apex of ventricle to 1cm below



SND: Lateral Type

- Rationale – oropharynx
 - Overall risk of occult mets is 30-35%
 - Hoffman (2001)
 - Level I – 10.3%
 - Level V – 7%
 - <5% for both Levels I and V if only N0 necks considered

SND: Lateral Type

- Rationale – Hypopharynx
 - Occult metastases in 30-35%
 - Johnson (1994)
 - Medial pyriform (MP) vs. lateral pyriform carcinomas (LP)
 - MP – 15% failed in the contralateral neck
 - LP – 5% failed in the contralateral neck
 - Johnson advocates bilateral SNDs for N0 MP carcinomas and ipsilateral SND for N0 LP carcinomas
 - Bilateral SND is often indicated in the majority of hypopharyngeal tumors because of extensive submucosal spread and involvement of multiple subsites

SND: Lateral Type

- Rationale – supraglottic
 - Highest incidence of occult nodal metastasis or any other subsite in the larynx
 - Occult nodal disease in 30%
 - >20% with contralateral occult disease
 - Shah (1990)
 - Level I – 6% involvement
 - Level V – 1% involvement
 - Bilateral SND recommended by most authors

SND: Lateral Type

- Rationale – glottic larynx
 - Sparse lymphatics – late spread
 - T1 – 5% occult metastases
 - T2 – 2% to 6% occult metastases
 - Byers (1988) and Candela (1990)
 - Recurrent T1 and T2 had higher rate of metastases
 - 20% to 22%
 - Recommend unilateral SND for these lesions

SND: Lateral Type

- T3 – 10% to 20% occult metastases
- T4 – up to 40% occult metastases
- 30% salvage rate for
- Ipsilateral SND advocated for T3 and T4 glottic carcinomas

SND: Posterolateral Type

- Definition

- En bloc excision of lymph bearing tissues in Levels II-IV and additional node groups – suboccipital and postauricular

SND: Posterolateral Type

- Indications

- Cutaneous malignancies
 - Melanoma
 - Squamous cell carcinoma
 - Merkel cell carcinoma
- Soft tissue sarcomas of the scalp and neck

SND: Anterior Compartment

- Definition

- En bloc removal of lymph structures in Level VI
 - Perithyroidal nodes
 - Pretracheal nodes
 - Precricoid nodes (Delphian)
 - Paratracheal nodes along recurrent nerves
- Limits of the dissection are the hyoid bone, suprasternal notch and carotid sheaths

SND: Anterior Compartment

- Indications

- Selected cases of thyroid carcinoma
- Parathyroid carcinoma
- Subglottic carcinoma
- Laryngeal carcinoma with subglottic extension
- CA of the cervical esophagus

Extended Neck Dissection

- Definition

- Any previous dissection which includes removal of one or more additional lymph node groups and/or non-lymphatic structures.
- Usually performed with N+ necks in MRND or RND when metastases invade structures usually preserved

Extended Neck Dissection

- Indications

- Carotid artery invasion
- Other examples:
 - Resection of the hypoglossal nerve resection or digastric muscle,
 - dissection of mediastinal nodes and central compartment for subglottic involvement, and
 - removal of retropharyngeal lymph nodes for tumors originating in the pharyngeal walls.