



King Saud University

Collage of Nursing

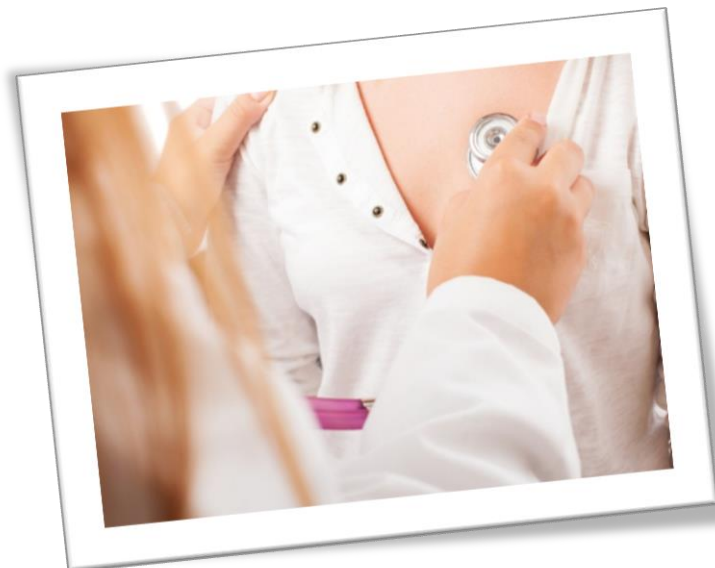Medical Surgical Nursing depart

Application of Health Assessment

NUR 225

Module Five

Physical examination of Cardiovascular System

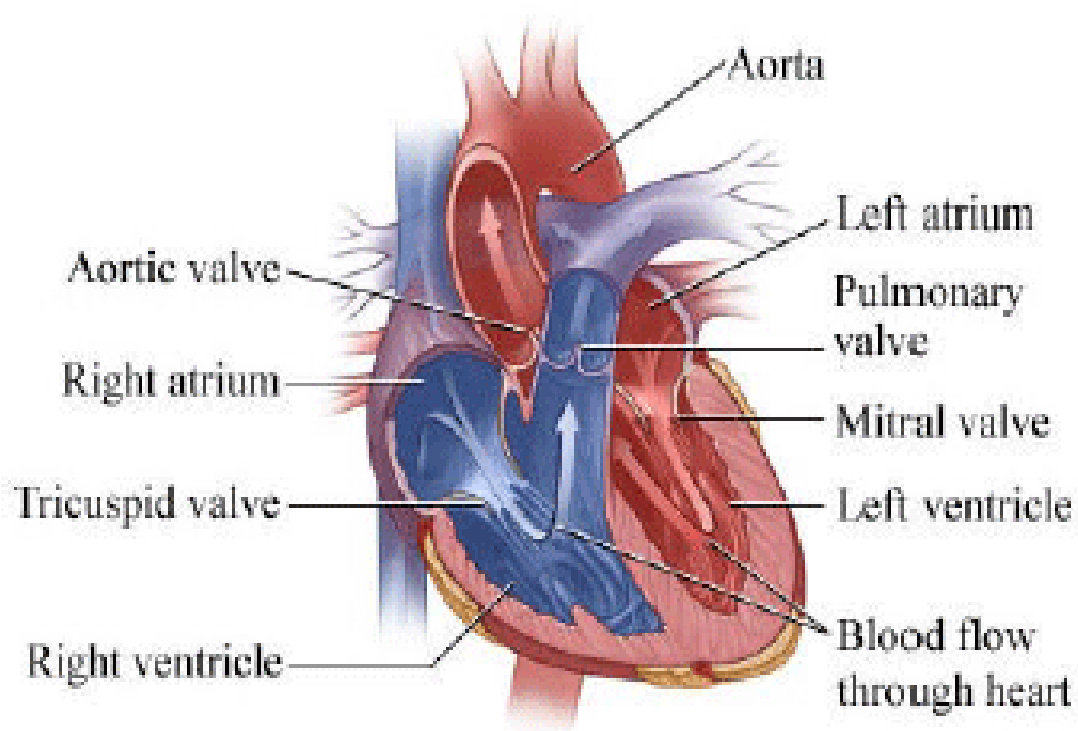


Introduction

The cardiovascular system plays a vital role in the body. It delivers oxygenated blood to tissues and removes waste products. It pumps blood to all organs and tissues of the body. The vascular network – arteries and veins – carry blood through the body, keep heart filled with blood, and maintain blood pressure.

The peripheral vascular system consists of a network of arteries, arterioles, capillaries and veins that is constantly filled with blood. It delivers oxygen, nutrients and other substances to the body's cells and removes the waste products of cellular metabolism.

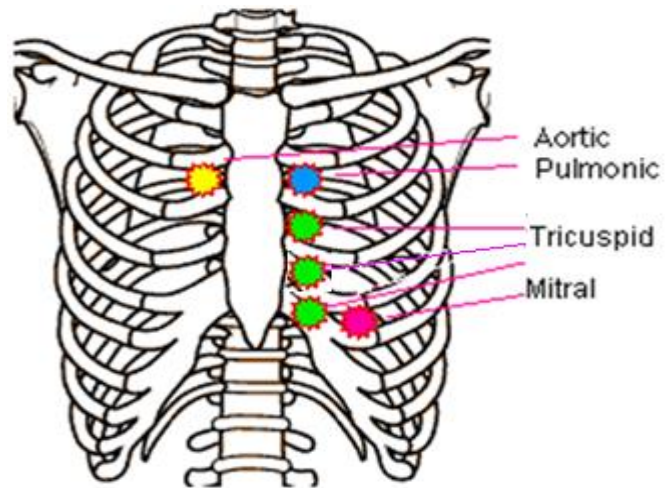
Anatomy and Physiology :



Cardiovascular System Landmarks:

The pericardium , the area of the chest overlying the heart, is assessed in a systematic manner at the following anatomical landmarks:

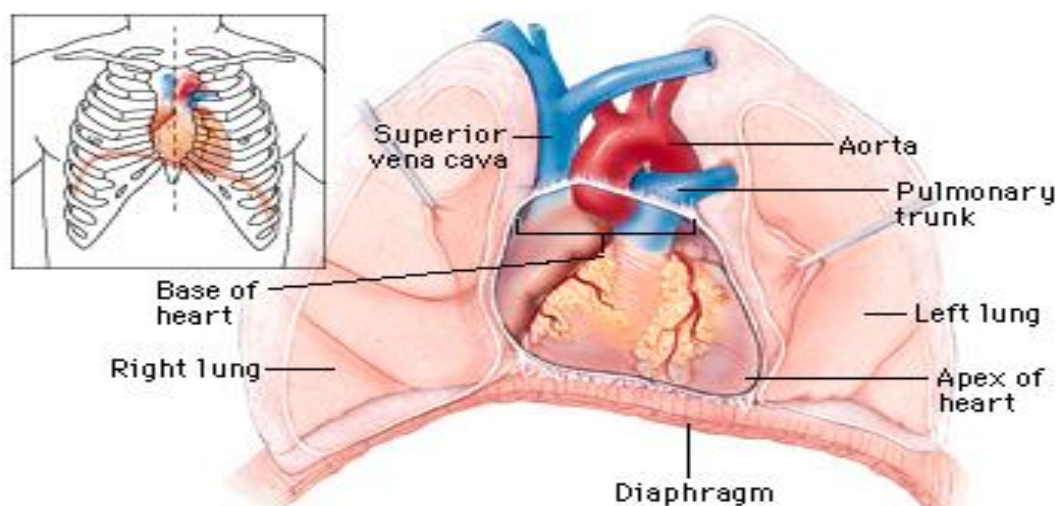
- 1- Aortic area.
- 2- Pulmonic area.
- 3- Tricuspid area.
- 4- Apical area.
- 5- Epigastric area.



Remarks:

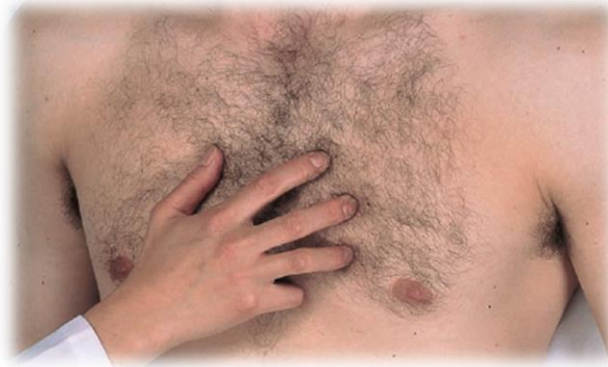Aortic, Pulmonic , Tricuspid, Apical area are the sites on the chest wall where sounds produced by the valves are best heard. The sound radiates with the direction of blood flow. They are not over the actual anatomic location of the valves.

The heart and the great vessels are located between the lungs in the middle third of the thoracic cage (mediastinum). The heart extends from the 2nd to the 5th intercostals spaces & from the right border of the **sternum** to the left **midclavicular line**. Think of the heart as an upside – down triangle in the chest. The "Top" of the heart is the border base; the "bottom" is the **APEX** which points down to the left.

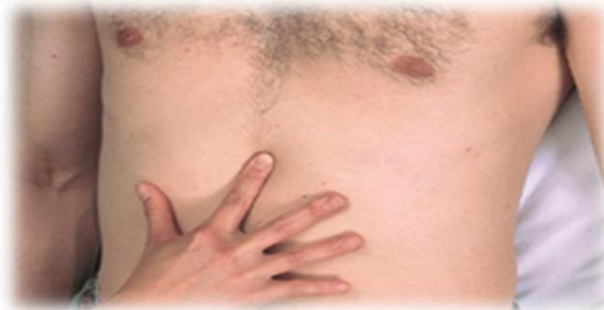

How to identify anatomical landmarks?

- 1- Assist the client to a fowler position with head elevated (30-45 degrees), and stand at the client right side. ***This position allows for optimal inspection and facilitates palpation.***
- 2- Locate the ***angle of Louis***, between the ***manubrium*** and the body of ***sternum***. ***It is felt as a prominence on the sternum.***
- 3- Move your fingertips down each side of the angle until you can feel the 2nd intercostals spaces. ***The client's right 2nd intercostals space is the aortic area, and the left is the pulmonic area.***
- 4- From the pulmonic area , move your fingertips down three intercostals spaces along the side of the sternum. ***The left fifth intercostals space close to the sternum in the tricuspid area.***

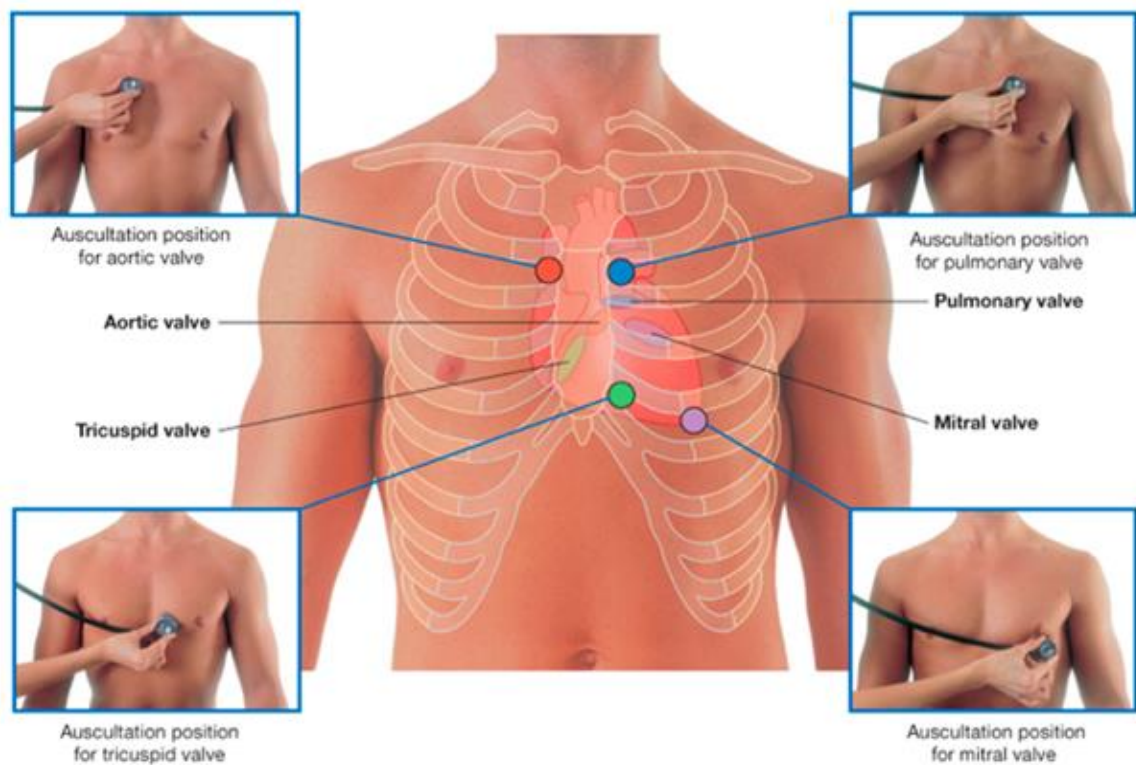
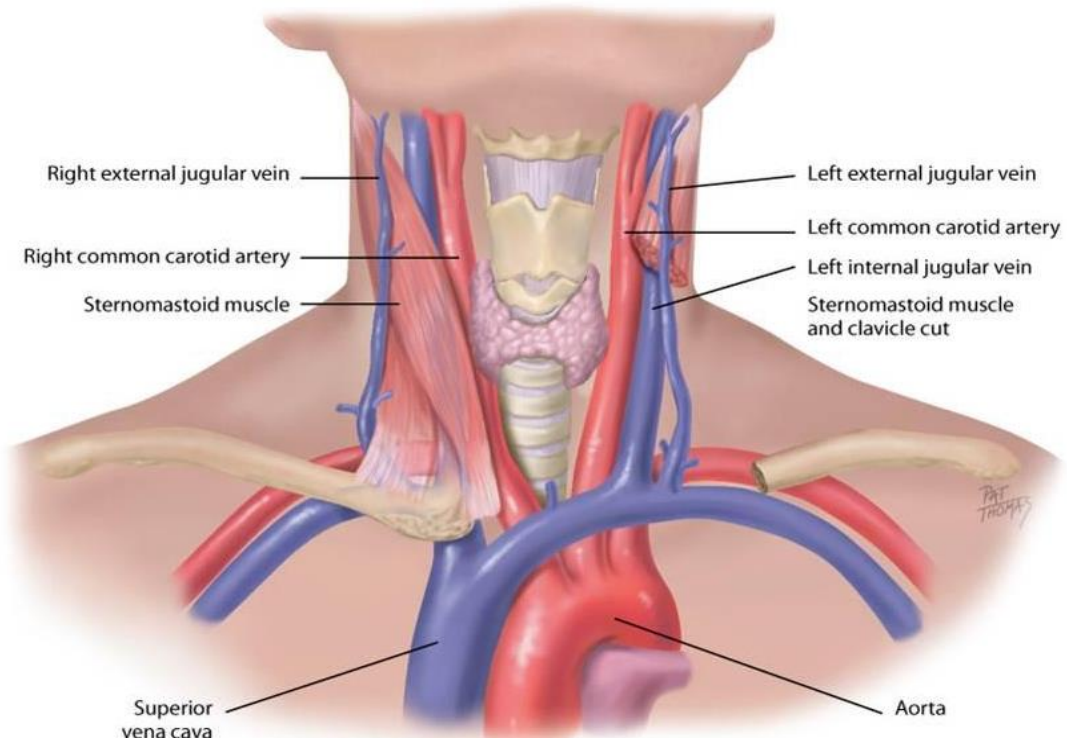


- 5- From the tricuspid area, move your fingertips laterally 5-7cm to the left midclavicular line. ***This is the mitral area , or point of maximum impulse (PMI) .***
- 6- ***The epigastric*** area is located at the base of the sternum.



- 7- ***The carotid artery*** is located in the groove between the trachea and the sternomastoid muscle , medial to and alongside that muscle.

- 8- **The external jugular vein** is a superficial vein located lateral to the sternomastoid muscle, above the clavicle. (The **jugular vein** pulse is caused by a waveform moving backwards).



Nursing Assessment of the Cardiovascular:

General purpose:

1. To determine general baseline data about patients cardiac function.
2. To detect cardiac problems.
3. To identify potential risk factors for cardiac disease.

A: Health History:

Heart /Cardiac History:

- **Presence of symptoms:**
fatigue , dyspnea, cough , hypertension, wheezing, chest pain, cyanosis, pallor, orthopnea (how many pillows the client uses when sleeping or lying down?), Edma (does the client note any swelling in the feet or the shoes feel tight at the end of the day & how much swelling is estimated?). Nocturia (does the client wake-up at night with argent need to urinate?).
- **Presence of other disease:**
diabetes, lung disease, endocrine disorder, obesity.
- **Client's history of heart problems:**
rheumatic fever or unexplained joint pains as a child or recurrent tonsillitis or anemia, murmur , heart attack, or heart failure .
- **Family History:**
heart disease, high cholesterol level, high blood pressure , stroke , obesity, congenital heart disease, sudden death in young age.
- **Life style habits (cardiac risk factors) :**
smoking, alcohol intake, eating habits, exercise , stress levels.
- **Self care:**
last ECG, stress ECG, serum cholesterol measurement.
- **Medication :**
antihypertensive , diuretics, anticoagulants (aspirin) .

Peripheral Vascular History

- **Presence of symptoms in extremities:**
pain, cramping , numbness, tingling, burning, swelling, enlarged or crooked leg veins, changes in temperature, color or skin.
- **History of heart disorders:**
phlebitis, varicosities, arterial disease and hypertension.
- **Life style:**
exercise patterns, smoking alcohol use, activity tolerance.
- **Medication:**

B- Physical Examination of the heart:

Patient position:

1. Fowler position with head elevated (30-45).
2. Turning to the left side.
3. Sitting or dangling on the bedside.

Equipment :


1. Stethoscope.
2. Light
3. Measuring tap
4. Alcohol swabs.





General guidelines for examining the cardiovascular system:

1. Obtain baseline vital sings (pulse, respiration and blood pressure).
2. Proceed in a methodological approach so no area is omitted.
3. Assist the client to a low fowler position with head elevated (30-45 degrees), and stand at the client right side as possible. This position allows for optimal inspection and facilitates palpation
4. The pericardium & extremities are inspected and palpated simultaneously , for the presence of abnormal findings in the cardiovascular system.
5. The cardiovascular system assessment includes the survey of the vascular structures in the neck: **carotid artery & jugular veins**. These vessels reflect the efficiency of the cardiac function.
6. When examination a female client, gently displace the breast upward, or ask her to do so.
7. Note the general appearance of the client color & weight.



Techniques of examination

<i>Technique</i>	<i>Normal Findings</i>	<i>Abnormal Findings</i>
<u>Inspection</u> 1. Inspect the anterior chest for pulsation, following anatomical landmarks. * arrange tangential lightning to accentuate any flickers of movement (pulsation). 2. Look for the apical impulse in the 4 th or 5 th intercostals space or just medial to the midclavicular line.	Apical impulse may or may not be observable.	Presence of: Lifts, or heaves (forceful thrusts of the ventricles during systole , seen at sterna border or apex.

<p><u>Palpation:</u></p> <p>1. Palpate the anterior chest for pulsation beginning with the aorta and proceed downward to the apex of the heart.</p> <p>* Use finger pads, held oblique or flat on the body surface to feel the pulsation.</p> <p>* Use ball of the hand for feeling vibration.</p>	<p>No other pulsation should be present.</p> <p>No pulsation should be present except for apical impulse.</p>	<p>Presence of other pulsation.</p> <p>a) Presence of thrills: (Vibration caused by turbulence of blood moving through valves that are transmitted through skin , feels like a purring cat.</p> <p>b) presence of other pulsation. If any abnormal pulsation is present , note the timing . Use the carotid artery pulsation as a guide.</p>
		
<p><u>Auscultation:</u></p> <p>1. Eliminate all sources of room noise that lowers nurse ability to hear.</p> <p>2. Explain to client that you will listen to the heart in different places on the chest and this requires some time.</p> <p>3. place the stethoscope on the chest wall beginning with the aortic area and proceed to the apex of the heart in a Z pattern.</p>	<p>Heart sounds are regular with the rate of 60-100 beat /min.</p> <p>The two sounds are heard normally as "lub" "dub" The two sounds are separated by a short systolic interval; each pair of sounds is separated by a diastolic interval. (app.1). S1=lub, S2=dub.</p>	<p>- Presence of other sounds: Sharp-sounding ejection clicks, Murmurs (turbulent blood flow within the heart due to valve defects or abnormal openings between the compartment of the heart).</p> <p>- Increased or decreased intensity of S1&or S2.</p>

<p>Use the diaphragm end piece and follows the proceeding routine:</p> <ol style="list-style-type: none"> Note the rate & rhythm. Identify S1&S2, by listening selectively to one sound at a time. listen for extra heart sound . listen for murmur. 	<p>*In <i>the aortic</i> and <i>pulmonic</i> areas , S2 is louder than S1.</p> <p>* In <i>the tricuspid</i> area, S1 and S2 are of almost equal in intensity.</p> <p>* In <i>the mitral area</i>, S1 is louder than S2.</p>	
		
<p>*S1 coincides with the carotid artery pulse. Feel the carotid gently as you auscultate at the apex; the sound you hear s you feel the pulse is S1.</p> <p>4. Roll the client towards the left side and listen with the bell at the apex for the presence of any diastolic filling sounds(S3 or S4).</p> <p>5. Ask the client to sit up, lean forward slightly and exhale. Firmly pressed at the aortic and pulmonic area. Check for the diastolic murmur or gallop</p>	 <p><small>Fig. 6.56 Simultaneously listening to the heart sounds: feeling these against the carotid pulse</small></p> <p>No S3 or S4 is heard</p>  <p>No murmur or gallop is heard.</p> 	<p>S3 or S4 or murmur is heard.</p> <p>Murmur or gallop is heard.</p>

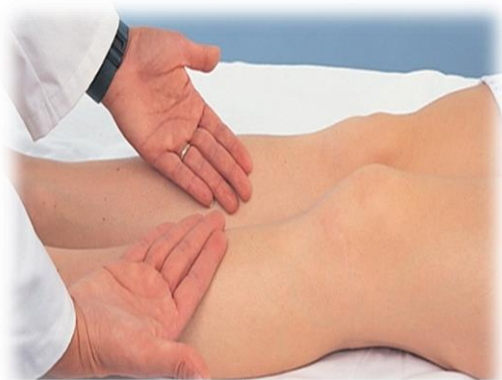Assessment of the peripheral Vascular System:

Technique	Normal Finding	Abnormal Finding
<p><u>1- Peripheral circulation:</u></p> <p><u>Extremities :</u></p> <p><u>Arms:</u></p> <p>1. Lift the client s hands by your hands the turns them over.</p> <p>* Inspect, palpate and compare symmetrically for: Skin and nail beds color, capillary refill, temperature, texture, skin turgor, the presence of any lesion swelling , clubbing, hair distribution.</p> <p>2. Palpate peripheral pulses bilaterally (radial , ulnar, brachial), comparing symmetrical the pulse rate, rhythm, elasticity of vessel wall & force from side to side. Grade the force on a (4-points scale).</p>	<p>Extremities & nail beds should be pink with capillary refill less than 3sec, bilaterally even in color, warmth/coolness & smoothness, Turgor WNL, No lesion or swelling (edema)or clubbed nails, Hair is evenly distributed.</p> <p>Normal Pulses (2+): Easily palpable , full, doesn't fade, and not easily obliterated with pressure& symmetrical. (app II).</p>	<p>Cyanosis/pallor/ erythema, delayed capillary refill, Hot or cold, rough , dry , poor turgor, swelling, clubbed nails, hair unevenly distributed.</p> <p>Absent (0), Weak(+1) increased (+3) , or Bounding (+4).</p>
		

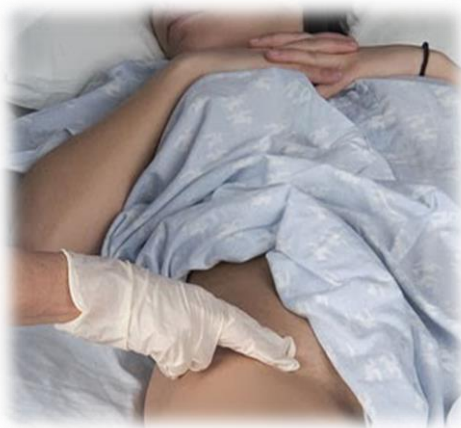Legs :

1. Inspecting & palpating both legs **while the client is still in supine** and compare symmetrically for:

Skin color and nail beds capillary refill, temperature (using the dorsal part of the hands palpate along the legs down to the feet), texture , skin turgor, the presence of any lesion, swelling, hair distribution, and venous pattern.

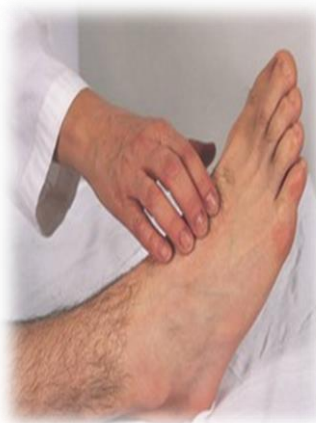

2. Palpate peripheral pulses **bilaterally** (femoral , popliteal, posterior tibial, dorsalis pedis, comparing symmetrical.



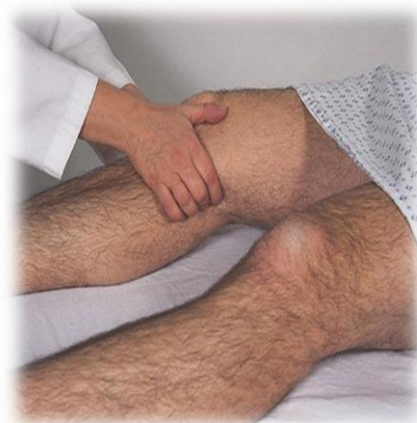Extremities & nail beds should be pink with capillary refill less than 2sec, bilaterally even in color, warmth/ coolness& smoothness, No lesion or swelling (edema) or , Hair is evenly distributed , venous pattern flat and barley visible.

Normal Pulses (2+)



Cyanosis/ pallor / erythema, delayed capillary refill, Hot or cold, rough, dry, swelling, hair loss or unevenly distributed varicosities.

Absent (0), Weak (+1)
Increased (+3) , or
Bounding (+4).



3. **inspect** both legs for size & **Palpate** for edema:

*Firmly press the skin over the tibia for 5 seconds and release.

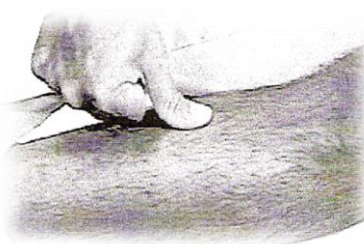*Run pads of fingers over the area pressed and note indentation.

****If indentation is noted, repeat the procedure, moving up extremity and note the point at which no more swelling is present.***

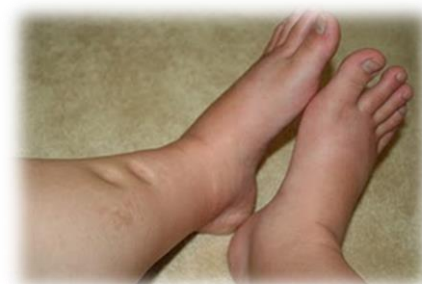* If edema is present grade it on(4-point scale) **(App.III).**

4.Size is asymmetric, measure the lower legs calf circumference with a nonstretchable tape measure. Measure at the widest point. Taking care to measure the other leg is exactly the same place (same number of centimeter down from the patella).

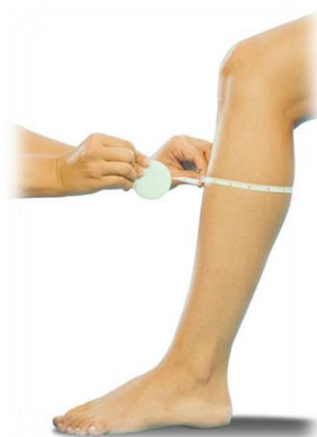Both legs are symmetric in size Absence of edema.



Swelling, atrophy. Presence of 1-4 skin indentation (0-4 edema scale) **(app.IV).**



Calf circumferences are bilaterally equal.



Calf circumferences are asymmetrical.

2-Peripheral perfusion

1. Assess the adequacy of arterial flow.
(buerger's test).

*Assist the client to a supine position.

*Have client raise one leg(or both) 30cm
above heart level.

*Ask client to wag the raised foot briskly
up and down for about 1min (this drains
off the venous blood).

*Have client sit up and dangle the leg
over the side of the table.

*Inspect& Compare the color of both
feet.

*Note the time needed for the feet to
return to original color.

*Note the time needed for the superficial
veins around the feet to fill.

***Repeat for arms & hands.**

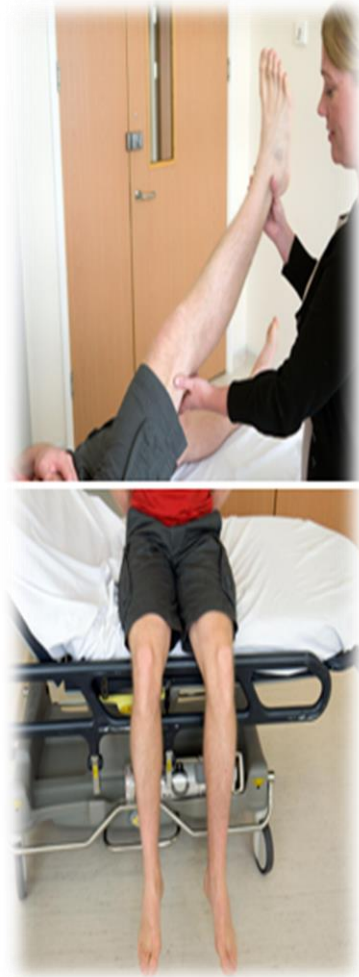2. Perform Capillary refill test.

* Squeeze client fingernail between your
fingers sufficiently to cause blanching.

* Release the pressure.

* Observe the time needed for the
normal nail color to return.

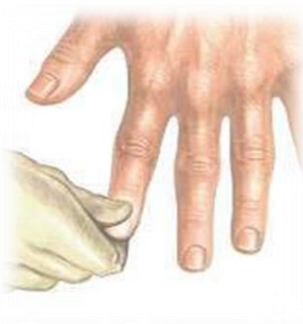***Repeat for a toenail.**



The feet color may look a
little pale but still should be
pink Original color normally
return in 10sec.

The veins fill in about 15sec.

Color returns immediately,
within 3sec. indicates a
capillary refill WNL



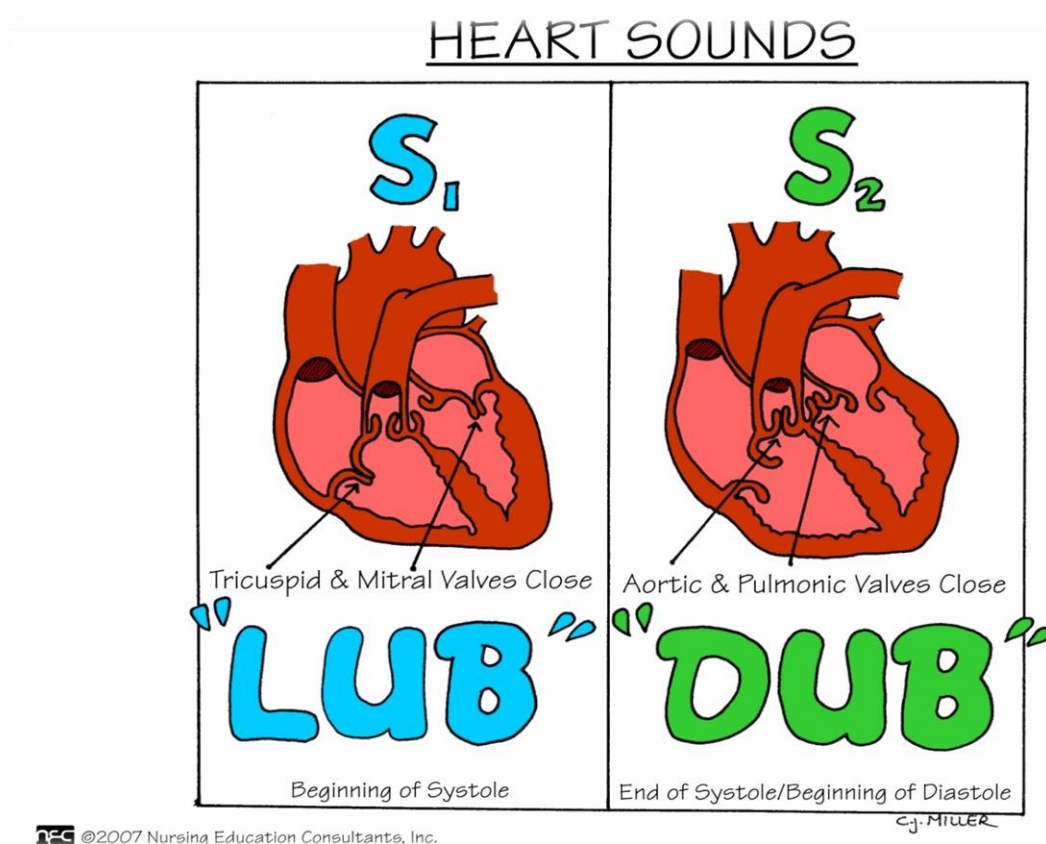
Impaired tissue perfusion or
circulation (**app.III**). Pallor, deep
blue-red color .

Pallor , deep blue-red color.

Delay in color or venous return
indicates arterial insufficiency.

Delay in color returns indicates poor
capillary refill.

Appendix I:



➤ To listen for the heart sounds [click here](http://medlink-uk.net/heart-sounds/)

<http://medlink-uk.net/heart-sounds/>

Appendix II:

grading pulse volume:

Grade	Description
0	Absent : No pulse
1	Weak : Thready, and difficult to palpate ; it may fade in & out & is easily obliterated with pressure , thus, light palpation is necessary. Once located it is stronger than scale 1 pulse.
2	Normal: Easily palpable, full, doesn't fade, and not easily obliterated with pressure.
3	Increased : Easily palpable and stronger than the normal pulse.
4	Bounding: Very strong, easily palpable, not obliterated with pressure it may indicate a disease in some cases.

Appendix: III:

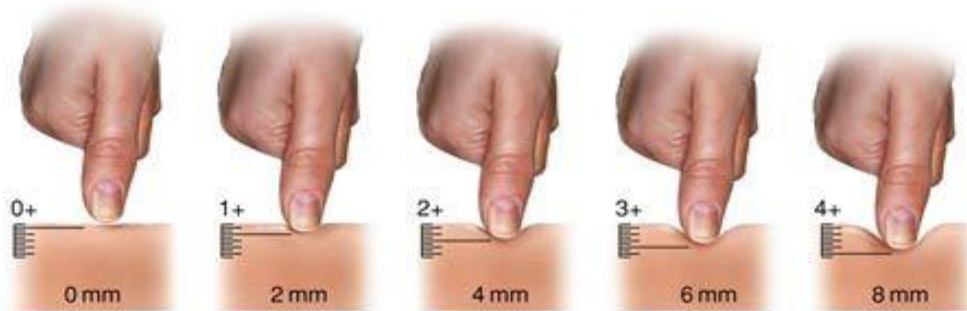Evaluating tissue perfusion:

Assessment Criterion	Normal Finding	Abnormal findings	Possible health problems
<i>Skin color</i>	Pink	Cyanotic Pallor(increase with limb elevation Dusky red when lowered). Brown pigmentation around the ankles.	Venous insufficiency Arterial insufficiency
<i>Skin temperature</i>	Not excessively warm or cold.	Cool	Arterial insufficiency
<i>Edema</i>	Absent	Marked edema mild or server	Venous insufficiency Arterial insufficiency
<i>Skin texture</i>	Resilient , moist	Thin and shiny or thick, waxy, shiny and fragile, with reduced hair and ulceration.	Venous or arterial insufficiency
<i>Arterial adequacy test</i>	Original color returns to normal in 10sec. veins fills in about 15 sec.	Delayed color return or mottled appearance , delayed venous filling , marked redness of arms or legs.	Arterial insufficiency
<i>Capillary refill test</i>	Immediate return	Delayed	Arterial insufficiency
<i>Peripheral pulse</i>	Easily palpable	No pulse , decreased or absent	Arterial insufficiency

Appendix IV:

four point scale for grading edema:

Grade	Description
+1	Mild pitting, slight indentation , no observable swelling.
+2	Less than 5mm
+3	5-10mm
+4	More than 10mm



- 0+ No pitting edema
1+ Mild pitting edema. 2 mm depression that disappears rapidly.
2+ Moderate pitting edema. 4 mm depression that disappears in 10–15 seconds.
3+ Moderately severe pitting edema. 6 mm depression that may last more than 1 minute.
4+ Severe pitting edema. 8 mm depression that can last more than 2 minutes.

➤ Click on links below to watch cardiovascular assessment:

<http://m.youtube.com/playlist?list=PLC1EB17059FA387DE>

<http://m.youtube.com/playlist?list=PLSnU06qBrmyJuWcPZ9kQg8mrM9hQLO6nY>

Terminology:

- **Heart Murmurs;** are abnormal sounds during heartbeat cycle — such as whooshing or swishing — made by turbulent blood in or near the heart. These sounds can be heard with a stethoscope.
- **Gallop** an accentuated **third heart sound** in patients with cardiac disease characterized by pathological alterations in ventricular filling in early diastole
- **WNL** its abbreviation for within normal limit

Study Questions:

Choose the correct answer:

1. You are assessing your patient for cardiovascular system, so you would position him in:

- a. trenderburg position.
- b. flat on his back.
- c. flower position , with possible rolling to the left.

2. When listening to heart sounds, you can best hear S1 at the:

- a. base of the heart.
- b. apex of the heart.
- c. 2nd intercostals space to the right of the sternum.

3. When grading arterial pulses, a 1+grade pulse indicates:

- a. absent perfusion.
- b. diminished perfusion.
- c. normal perfusion.

4. Capillary refill time is normally:

- a. less than 3 sec.
- b. between 3-5 sec.
- c. less than 1sec.

5. The point of maximum impulse is located at the:

- a. Tricuspid area.
- b. Mitral area.
- C. Pulmonic area.

Nursing health assessment documentation format
Cardiovascular system (adapted from KFSH & RC)

Instructions: Circle or fill in the blanks with actual physical assessment findings.
WNL=Within Normal Limits for age.

1-Pt. Identification data:

Name:.....Age.....Sex..... Occupation..... Marital status.....
Tel/Address.....

II-General Survey :

Physical appearance _WNL , abnormalityBody structure_WNL, abnormality.....
Mobility_WNL, abnormality.....Behavior_WNL, abnormality.....

III-Present History :

A-Chief ComplaintP.....
P.....Q.....R.....
R.....S.....T.....
T.....T.....T.....
Associated symptoms.....Medications:.....
B-Current health :
.....

IV-Past medical history:

☐Heart problem ☐Rheumatic fever ☐Murmurs ☐Arterial disease
☐Varicosities ☐Phlebitis ☐Lung disease ☐D.M.
☐Heart Attack ☐Heart failure ☐Others (specify).....

Physical Examination:

Anterior chest: ☐WNL ☐Pulsation..... ☐Vibration.....
☐Skin abnormality.....
PMI: location Size durationamplitude.....
Heart sounds: ☐S1,S2 ☐murmurs ☐diastolic refill.
Apical Pulse : ☐regular ☐irregular ☐rate.....

Fill in the blacks with actual physical assessment findings:

Peripheral examination	Hands		Feet	
	Right	Left	Right	Left
Skin color				
Nail beds color				
Capillary refill				
Temperature				
Texture				

Peripheral examination	Hands		Feet	
	Right	Left	Right	Left
Turgor				
Lesion				
Swelling				
Hair distribution				
Clubbing				
Size				
Edema grade				
Calf circumference				
Venous pattern				
Radial /Pedal pulse				
Palpable				
Rate				
Rhythm				
Vessel wall				
Volume				
Force grade				
Burger's test				
Color return				
Venous refill				

King Saud University

Application of Health Assessment

Collage of Nursing

NURS 225

Medical-Surgical Nursing

Name of student _____

Student Number _____

The student nurse should be able to:

Performance criteria	Competency Level						Comment
	Trial 1			Trial 2			
	Done correctly (2)	Done with assistance (1)	Not done (0)	Done correctly (2)	Done with assistance (1)	Not done (0)	
Collect Appropriate objective data related to general survey							
Collect appropriate subjective data related to Cardiovascular system.							
Prepare required equipment.							
Explain procedure.							
Position and drape client correctly (Assist the client to a low fowler position with head elevated (30-45 degrees), and stand at the client right side)							
Instruct client appropriately							
Cardiac Examination							
Inspection	Done correctly (2)	Done with assistance (1)	Not done (0)	Done correctly (2)	Done with assistance (1)	Not done (0)	Comment
1.Inspect the anterior chest for pulsation, following anatomical landmarks.							
2. Look for the apical impulse in the 4 th or 5 th intercostals space or just medial to the midclavicular line.							
Palpation							
1. Palpate the anterior chest <u>by using finger pads</u> for pulsation beginning with the aorta and proceed downward to the apex of the heart.							
2- Use ball of the hand for feeling vibration.							

Auscultation							
1. Eliminate all sources of room noise that lowers nurse ability to her.							
2. Explain to client that you will listen to the heart in different places on the chest and this requires some time.							
3. place the stethoscope on the chest wall beginning with the aortic area and proceed to the apex of the heart in a Z pattern.							
3- Use the diaphragm end piece and follows the proceeding routine: a. Note the rate & rhythm. b. Identify S1&S2, by listening selectively to one sound at a time. c. listen for extra heart sound . d. listen for murmur or gallop							
4. Roll the client towards the left side and listen with the bell at the apex for the presence of any diastolic filling sounds(S3 or S4).							
5. Ask the client to sit up, lean forward slightly and exhale. Firmly pressed at the aortic and pulmonic area. Check for the diastolic murmur or gallop							

Peripherals examination

Arms inspection & palpation	Done correctly (2)	Done with assistance (1)	Not done (0)	Done correctly (2)	Done with assistance (1)	Not done (0)	Comment
1. Inspect, palpate and compare symmetrically for: Skin and nail beds color, capillary refill, temperature, texture, skin turgor, the presence of any lesion swelling , clubbing, hair distribution.							
1- Palpate peripheral pulses bilaterally (radial , ulnar, brachial) a- comparing symmetrical the pulse rate, rhythm, elasticity of vessel wall & force from side to side.							

b- Grade the force on a (4-points scale).							
Legs inspection & palpation	Done correctly (2)	Done with assistance (1)	Not done (0)	Done correctly (2)	Done with assistance (1)	Not done (0)	Comment
1. Inspecting & palpating both legs while the client is still in supine and compare symmetrically for: Skin color and nail beds capillary refill, temperature (using the dorsal part of the hands palpate along the legs down to the feet), texture , skin turgor, the presence of any lesion, swelling, hair distribution, and venous pattern.							
2. Palpate peripheral pulses <i>bilaterally</i> (femoral , popliteal, posterior tibial, dorsalis pedis, comparing symmetrical.							
3. <i>inspect both legs for size & Palpate for edema:</i> *Firmly press the skin over the tibia for 5 seconds and release. *Run pads of fingers over the area pressed and note indentation. <i>*If indentation is noted, repeat the procedure, moving up extremity and note the point at which no more swelling is present.</i> * If edema is present grade it on(4-point scale)							
4. Size is asymmetric , measure the lower legs calf circumference with a tape measure. Measure at the widest point. Taking care to measure the other leg is exactly the same place (same number of centimeter down from the patella).							

<u>Peripheral perfusion</u>	Done correctly (2)	Done with assistance (1)	Not done (0)	Done correctly (2)	Done with assistance (1)	Not done (0)	Comment
1. Assess the adequacy of arterial flow. (buerger's test). *Assist the client to a supine position. *Have client raise one leg(or both) 30cm above heart level. *Ask client to wag the raised foot briskly up and down for about 1min (this drains off the venous blood). *Have client sit up and dangle the leg over the side of the table. *Inspect& Compare the color of both feet. *Note the time needed for the feet to return to original color. *Note the time needed for the superficial veins around the feet to fill.							
Repeat for arms & hands.							
Document							

Total grade _____

Evaluated by:_____

Data:_____

Signature of Faculty_____