



King Saud University

Collage of Nursing

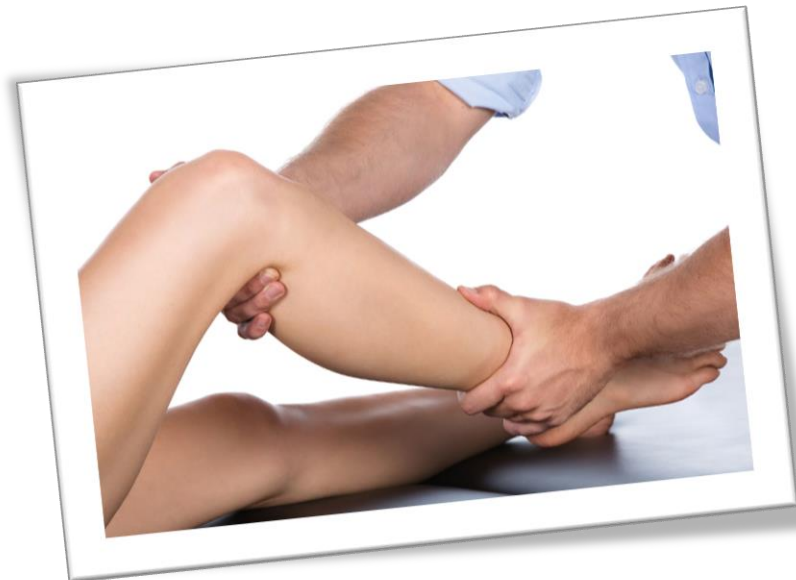Medical Surgical Nursing depart

Application of Health Assessment

NUR 225

Module Eight

Physical examination of Musculoskeletal System



Obtaining a health history

Ask about chief complain:

- ✓ History of presence of muscle pain (onset, location, Aggravating and alleviating factors character) associated phenomena (redness, swelling of joint)
- ✓ any limitation to movement or inability to perform activity of daily living ,previous sport injury any loss of function without pain

Ask About current health

- ✓ Are the patients activities of daily living affected
- ✓ Ask if he has noticed grating sounds when he move certain parts of his body
- ✓ Does he use ice, heat, or other remedies to treat the pain

Ask about past health

- ✓ The patient ever has gout ,arthritis, Tuberculosis, or cancer which may have bony metastases, osteoporosis
- ✓ If he has had a recent blunt or penetrating or trauma if so ,how did it happen
- ✓ Did he suffer knee and hip injury
- ✓ Use an assistive device such as walker , brace
- ✓ Watch him use the device to assess how he move

Ask About medication:

- ✓ Ask about what medication he regularly takes
- ✓ Many drugs can affect the musculoskeletal system such as ***corticosteroid** can cause muscle weakness (myopathy), osteoporosis, pathologic fracture and ***anticoagulant** can cause bleeding inside the joint

Examination Techniques:

- ✓ Inspect joints, muscles, and extremities for size, symmetry, and color
- ✓ Palpate joints, muscles, and extremities for tenderness, edema, heat, nodules, or crepitus.
- ✓ Test muscle strength and ROM of joints.
- ✓ Compare bilateral findings of joints and muscles.
- ✓ Perform special tests for carpal tunnel syndrome.

Equipment

- ✓ Tap measure
- ✓ Goniometer (optional)
- ✓ Skin marking pen (optional)



Physical examination

Assessment	Normal finding	Abnormal finding
<p><u>1. Muscle</u></p> <p>➤ <u>Inspection</u> Inspect the muscle for size compare the muscle on one side of the body to the same muscle on the other side, for any discrepancies, measure muscle with tape</p> <p>Inspect the muscle and tendons for contractures (Shortening)</p> <p>Inspect the muscles for <u>fasciculation</u> and tremors; inspect any tremors of the hand, and arms by having the client hold out in front of the body</p>	<p>Smoothness of movement</p> <p>Equal size on both side of the body</p> <p>No contractures</p> <p>No fasciculation or tremor</p>	<p>Muscle atrophy (decrease in size)</p> <p>Muscle hypertrophy (an increase in size)</p> <p>Malpostion of body part (foot fixed in dorsiflexion)</p> <p>Presence of fasciculation</p>
<p>➤ <u>Palpation:</u></p> <p>Palpate muscle <u>at rest</u> to determine muscle tonicity (the normal condition of tension, or tone, of muscle at rest)</p> <p>Palpate muscle while the client is <u>active</u> and <u>passive</u> movement For flaccidity, and Spasticity.</p>	<p>Normally firm</p> <p>Smooth coordinated Movement</p>	<p>(lacking Tone)</p> <p>Flaccidity (weakness or laxness) or Spasticity (Sudden involuntary muscle contraction)</p>

Test muscle strength

Muscle activity:

Sternocleidomastoid:

Client turned the head to one side against the resistance of your hand, repeat with the other side

Firm jaw pressure against your hand



Trapezius :

Stand behind your patient back place your hand on his shoulder as you apply moderate pressure

Client shrugs the shoulder against the resistance of your hand



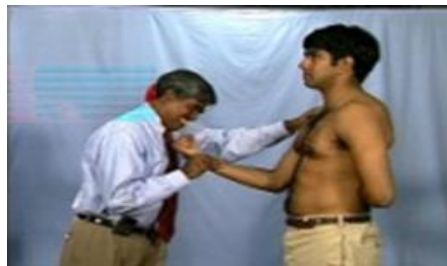Deltoid:

Client hold arm up and resists while you try to push it down



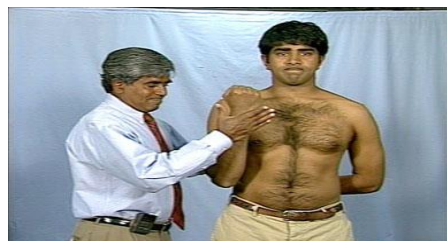
Biceps:

Client fully extends each arm and tries to flex it while you attempt to hold arm in extension



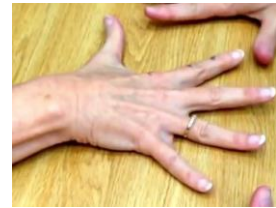Triceps:

Client flex each arm and then tries to extend it against your attempt to keep arm in flexion



Wrist and finger muscle

Client spread the fingers and resist as you attempt to push finger together



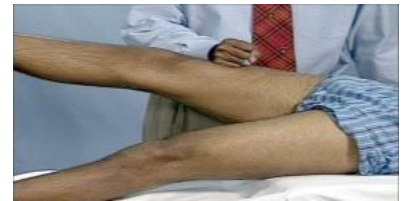Grip strength :

Client grasps your index and middle fingers while you trying to pull the



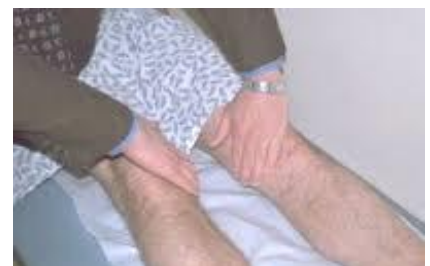Hip muscle :

Client is supine, both leg extended client raises one leg at a time while you attempt to hold it down



Hip abduction:

Client is supine, both leg extended, place your hand on the lateral surface of each knee



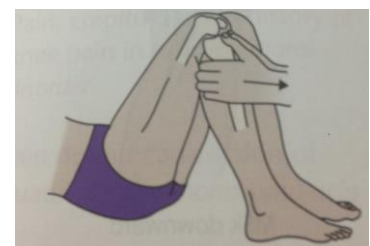Hip adduction:

Client is supine; place your hand between knees Client bring the legs together against your resistance



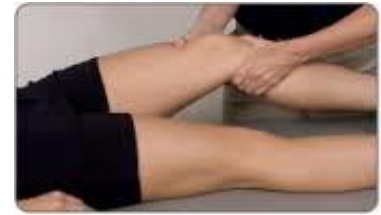Hamstrings:

Client is supine both knee bent ,client resists while you attempt to straighten the legs



Quadriceps:

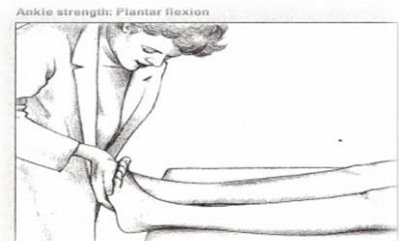
Client is supine, knee partially extended Client resists while you attempt to flex the knee



Muscles of ankle and feet

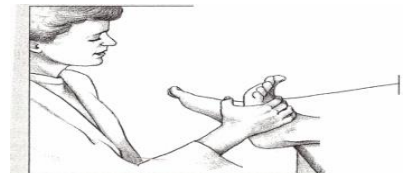
Plantar flexion:

Clients resist while you attempt to flex the foot



Dorsiflexion:

Client resist while you attempt to dorsiflex the foot

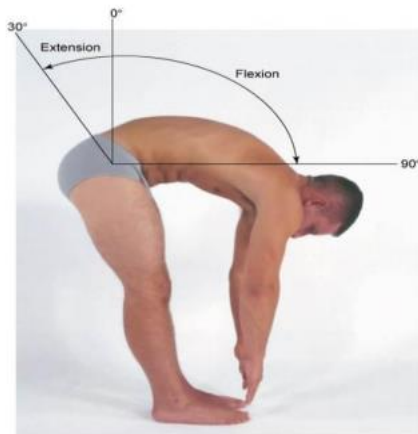

Il- Bones:

-Inspect the skeleton for normal structure and deformities

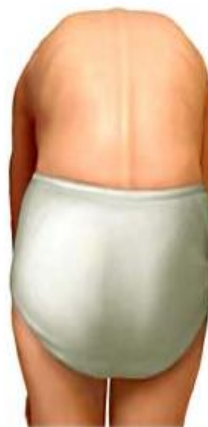Examine for scoliosis in persons over age 12 (occurs in adolescence into adulthood)

Clients stand facing away from the nurse and bend over touch the toes look for asymmetric thoracic spine

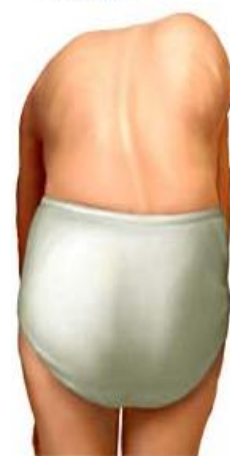

Flexion of 75–90 degrees, smooth movement, and lumbar concavity flattens out, and the spinal processes are in alignment. (No deformities)

Normal spine



Deformity from scoliosis

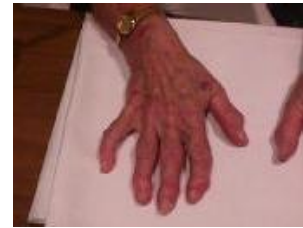

Unilateral exaggerated thoracic Convexity increases in structural scoliosis. Spinal processes are out of alignment

-Palpate the bones to locate any areas of edema or tenderness

No tenderness or swelling

Bony enlargement – degenerative joint disease (osteoarthritis)



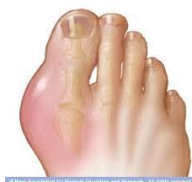Presence of tenderness or swelling indicate fracture, neoplasms or osteoporosis

III- Joints:

-Inspect joint: for redness, swelling, nodules.

No redness, swelling, nodules.

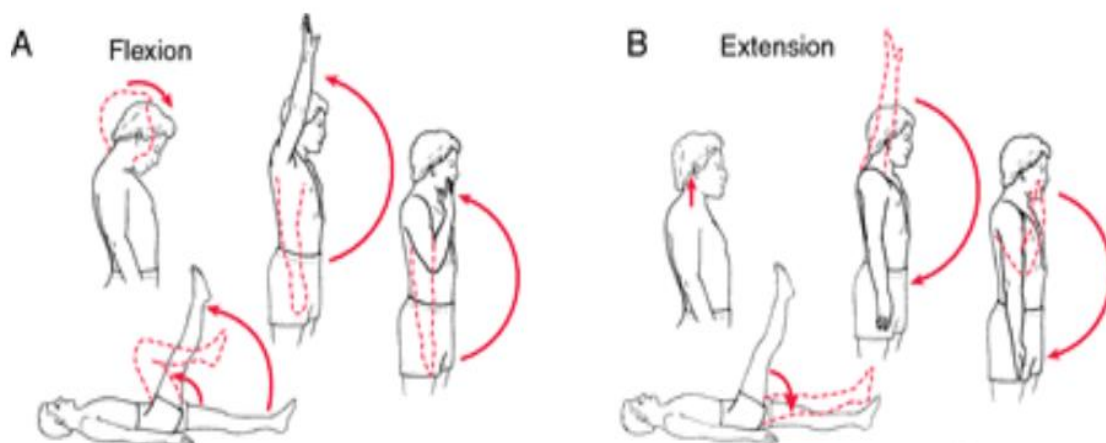
One or more swollen joint

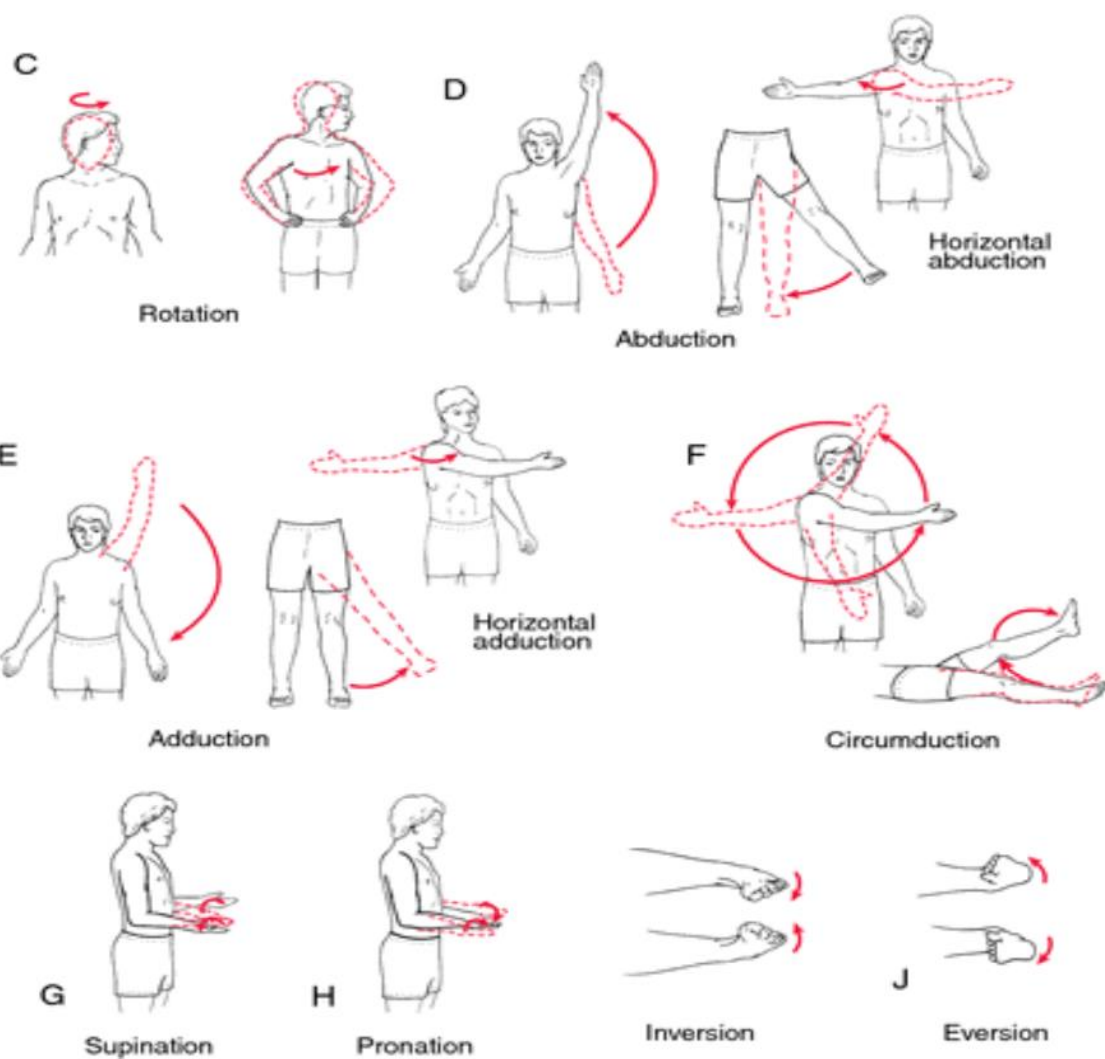


-Joint range of motion
observer Limited range of motion in one or more joint

Joint range of motion Limited range of motion in one or more joint.

Decreased range of motion suggests arthritis / inflammation of the joints

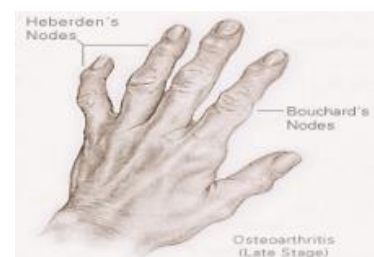



-Palpate each joint :

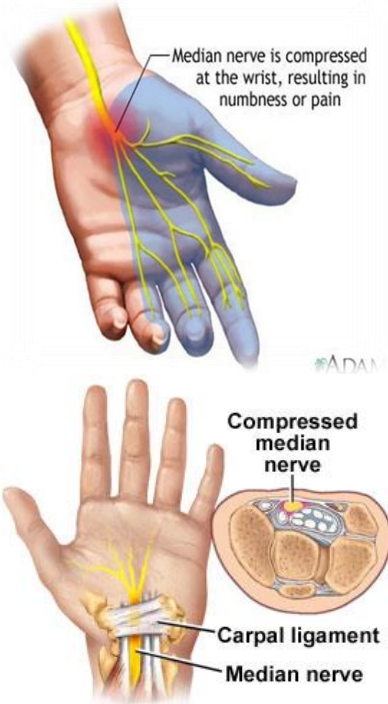
for tenderness, swelling, and smoothness of movement, crepitating, and presence of nodule

Presence of tenderness, Swelling, crepitation, or nodules indicated of rheumatoid arthritis



Testing for carpal tunnel syndrome

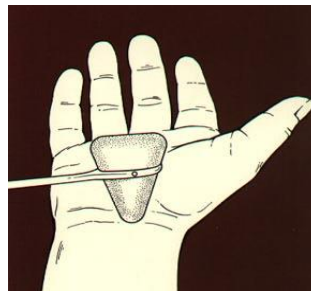
carpal tunnel syndrome



Two simple tests, tinels sign and phalens sign can confirm carpal tunnel syndrome

Tinels sign

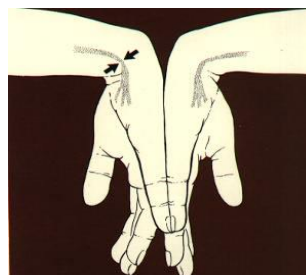Lightly percuss the transverse carpal ligament over the median nerve where the patient palm and wrist meet.



if this action produce discomfort ,such as numbness and tingling shooting in to the palm and finger ,the patient has tingle sign and probably has carpal tunnel syndrome.

Phalens sign

Instruct client to flex his wrist for about 30 second.



if flexing the patient wrist cause pain or numbness in his hand or finger ,he has phalens sign, the more sever the carpal tunnel syndrome the more rapidly the syndrome develop.

The 6 P ~s of musculoskeletal injury

☒ **pain**

Ask the patient if he is having pain. If he is assess the location, Severity and quality of the pain as well as anything that seems to relive or worsen it

☒ **Paresthesia**

Assess for loss of sensation by touching the injured area with the tip of an open safety pin or the point of a paper clip. Then assess the same area on the unaffected side and compare abnormal sensation or loss of sensation indicator neurovascular involvement.

☒ **Paralysis**

Can the patient move the affected area? If he can't, or if Movement cause severe pain and muscle spasm, he might have nerve or tendon damage.

☒ **Pallor**

Paleness, discoloration, and coolness on the injured side, may indicate neurovascular compromise from decrease blood supply to area.





☒ **Pulse**

Check all pulses distal to the injury site. If pulse is decrease or absent, blood supply to the area is reduced

☒ **Polar:** Coldness

Appendix 1

Abnormal Finding Of Musculoskeletal System

<u>Abnormal finding</u>	<u>Description</u>
Rheumatoid arthritis 	Is a chronic, systemic, inflammatory disease that attacks the joint and the surrounding tissue especially the hands ,hips, knee, and feet
Osteoarthritis 	Is the chronic degeneration of joint cartilage caused by aging or trauma.
Gout	Urate crystals are deposited in joint, causing them to be red, swollen, and acutely painful.
Tendonitis 	Is the inflammation of tendons and muscle attachment to bone
Bursitis 	Involves the burse surrounding a joint and result from trauma or inflammatory joint disease
Osteoporosis	A decrease in bone mass
Herniated disk	Most herniation occur in the lumber spine



King Saud University
College of Nursing
Medical-surgical Dept.

Application of Health Assessment
NURS 225

Performance checklist / Musculoskeletal System

Student name-----

Student # -----

Performance Criteria	Competency Level					
	Trial 1			Trial 2		Comment
	Done Correctly	Done with Assistance	Not Done	Competent	Not Competent	
Collect Appropriate objective data related to general survey						
Collect appropriate subjective data related to Musculoskeletal system.						
Explain procedure.						
I – MUSCLE						
A – Inspection						
1. Inspect the muscle for size, bilaterally, compare						
2. Inspect the muscle and tendons for contractures (Shortening, shape, malposition)						
3. Inspect the muscles for fasciculation and tremors, involuntary movement. - hold arms away of body & check for tremors						
B - Palpation:						
1. Palpate muscle at rest to determine muscle tonicity						
2. Palpate muscle while the client is active and passive for (flaccidity, Spasticity and smoothness of movement)						
3. Test muscle strength (equal strength on each side or less than 20 % of the norm al strength)						
a. Sternocleidomastoid						

b. Trapezius						
c. Deltoid:						
d. Biceps						
e. Tricep						
f. Wrist and finger muscle						
g. Grip strength						
h. Hip muscle						
i. Hip abduction						
j. Hip adduction						
k. Hamstrings						
l. Quadriceps						
m. Muscles of ankle and feet						

II. Bones

1. Inspect the skeleton structure for deformities						
2. Examine for scoliosis(posterior), Kyphosis, Lordosis (lateral)						
3. Palpate the bones to locate any areas of edema or tenderness						

III. Joint

1. Inspect joint for swelling bilaterally						
2. Palpate each joint for tenderness, swelling, and smoothness of movement, crepitation, and presence of nodule						
3. joint range of motion						
4. Assess for carpal tunnel syndrome by: <ul style="list-style-type: none"> Tinels sign Phalens sign 						

Document Findings						
-------------------	--	--	--	--	--	--

Instructor's signature