

Epithelioid Osteosarcoma of the Maxilla: A Case Report and Review of the Literature



International Journal of Surgical Pathology
2015, Vol. 23(6) 495–499
© The Author(s) 2015
Reprints and permissions:
sagepub.com/journalsPermissions.nav
DOI: 10.1177/1066896915591273
ijs.sagepub.com
SAGE

Dalal ALQahtani, BDS, MSc, MEd¹, Manal AlSheddi, BDS, MSc, DMSc, ABOMP Diplomat¹, and Ra'ed Al-Sadhan, BDS, MSc, ABOMR Diplomate¹

Abstract

Epithelioid osteosarcoma is an uncommon variant; only 4 cases have been reported in the jaw area, 2 of which were in the maxilla. A 22-year-old woman, in the eighth month of pregnancy, presented to the oral surgery clinic with a mass in the right maxilla that had rapidly expanded over the past 3 months. Computed tomography scans showed an ill-defined sclerotic destructive lesion that formed bone matrix in its soft tissue extension. Microscopic examination of the lesion revealed malignant epithelioid cells with osteoid deposits. The tumor cells were shown to have pale cytoplasm, vesicular nuclei, and prominent nucleoli and to undergo frequent mitosis. In addition, the tumor was positive for epithelial membrane antigen and vimentin and negative for AE1/AE3, Melan-A, CD30, synaptophysin, NSE, CD45, CD99, desmin, and myogenin. The final diagnosis was epithelioid osteosarcoma, which is a rare aggressive variant of osteosarcoma. Few cases of epithelioid osteosarcoma have been reported in the literature, and more studies are required to determine the clinical behavior of this tumor.

Keywords

epithelioid osteosarcoma, jaws, maxilla, immunohistochemistry, malignancy

Introduction

Osteosarcoma is a malignant neoplasm of mesenchymal origin that can produce an immature osteoid or disorganized bone.¹ Excluding hematopoietic malignancies, osteosarcoma is the most common primary malignant tumor of the bone,² and it typically affects the metaphysis of long bones during the period of greatest bone growth, which is between 10 and 20 years of age.³

In contrast, gnathic osteosarcoma, or osteosarcoma of the jaws, most frequently occurs in older patients, with a mean age of onset of 34 years,⁴ and it represents 6% to 13% of all osteosarcomas.⁵ The maxilla and mandible have nearly equal frequencies of involvement.^{4,6,7}

Depending on the relative amounts of produced matrix, osteosarcoma is divided into 3 major histological types: osteoblastic, chondroblastic, and fibroblastic¹; however, other variations have been reported.³ The rare variant of epithelioid osteosarcoma is composed of osteoblasts with epithelioid features.⁸ Only 4 cases of epithelioid osteosarcoma have been reported in the jaw area, 2 of which were in the maxilla. Here, we report a rare case of osteosarcoma arising in the maxilla in a 22-year-old woman, and to our knowledge, this is only the fifth reported case of osteosarcoma involving the jaw.

Case Report

A 22-year-old black Saudi female in the eighth month of pregnancy presented to the oral surgery clinic with a right maxillary mass that had rapidly expanded over the past 3 months. She reported dysphagia and numbness extending to the eye. Extra-oral examination revealed a hard 4 × 4 cm fixed nontender mass involving the infraorbital area to the upper lip (Figure 1A). Intraorally, the lesion extended from the upper right lateral incisor to the anterior tonsillar pillar and caused buccal and palatal bone expansions with severe gingival ulceration and bone exposure (Figure 1B). The examination also revealed grade II mobility from the upper right central incisor to the upper right first premolar. Axial, coronal, and sagittal computed tomography (CT) scans showed a sclerotic, destructive expansile lesion in the right maxilla. The

¹ College of Dentistry, King Saud University, Riyadh, Saudi Arabia

Corresponding Author:

Dalal ALQahtani, Department of Oral Medicine and Diagnostic Sciences, College of Dentistry, King Saud University, PO Box 60169, Riyadh 11545, Saudi Arabia.

Email: dalalq@ksu.edu.sa

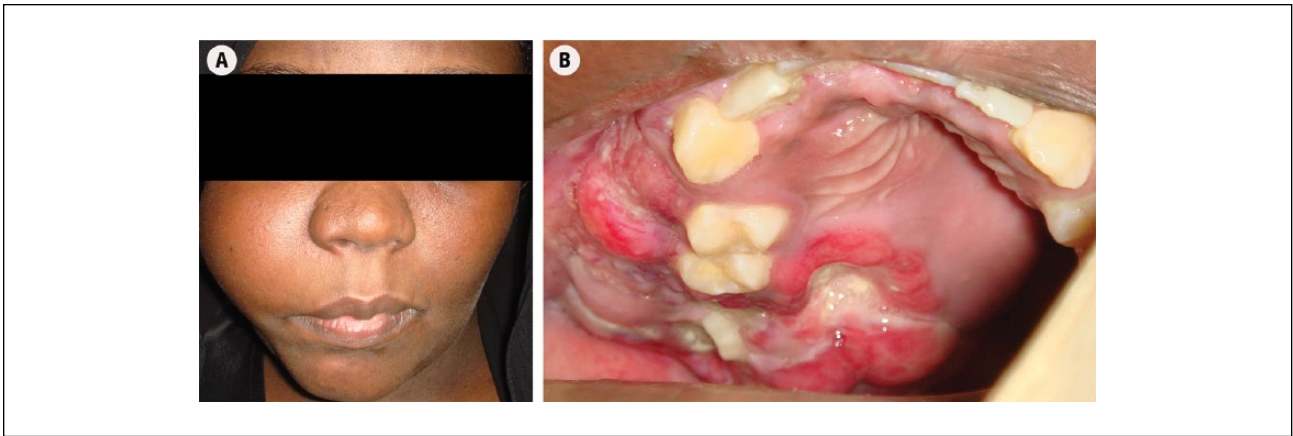


Figure 1. (A) Extra-oral picture shows the extension of the lesion on the right side of the face from the upper lip to the infra-orbital area. (B) Intra-oral picture reveals severe gingival ulceration and bone exposure produced by the tumor.

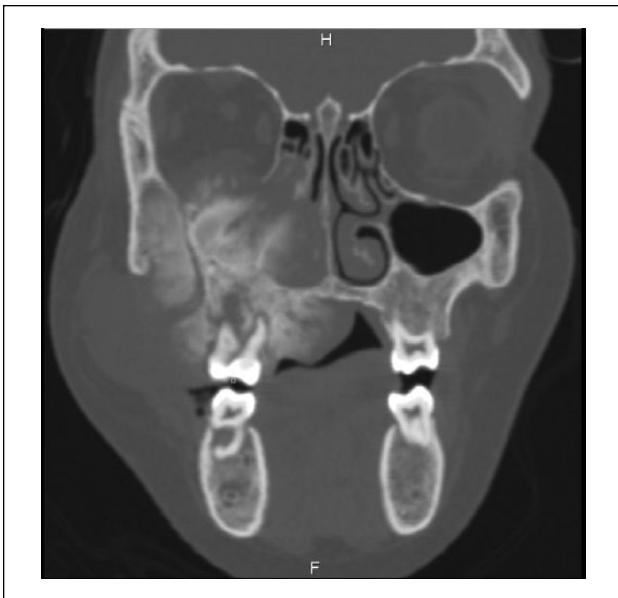

Figure 2. Coronal section CT scan shows tumor breaks through the maxilla and is producing bone matrix in its soft tissue extension.

borders of bone destruction were ill-defined. The lesion was on the right side of the face and extended into the maxillary sinus, anterior ethmoid air cells, nasal fossa, and lower portion of orbit. There was a cortical break-through, with the tumor spreading outside the maxilla and producing bone matrix that extended laterally into the soft tissue (Figure 2).

Based on the clinical and radiological findings, the patient was clinically diagnosed with osteosarcoma. Under local anesthesia, an incisional biopsy was performed, and the biopsy specimen was placed in formalin and sent for histopathological analysis. Grossly, the biopsy included

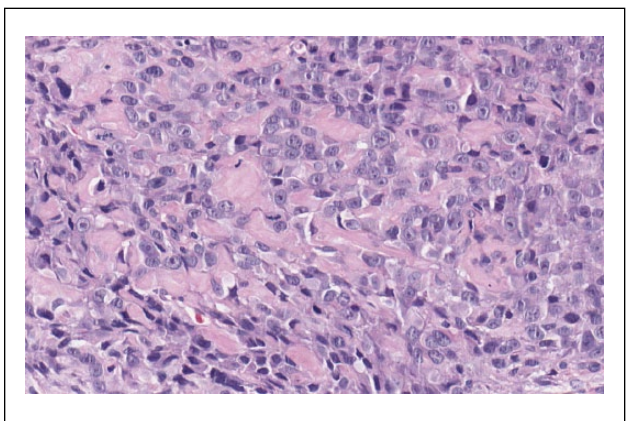


Figure 3. High-power histology demonstrates malignant epithelioid cells with intervening osteoid deposits (hematoxylin and eosin, original magnification 40×).

2 pieces of firm tissue that were brownish in color and 1.5 cm × 1.3 cm × 0.4 cm in size. The tumor was composed of infiltrating sheets of epithelioid cells and deposits of malignant osteoid. The neoplastic cells had pale cytoplasm, vesicular nuclei, and prominent nucleoli and underwent frequent mitosis (Figure 3). Some tumor cells showed plasmacytoid features (Figure 4). Focally, rosette formation was observed.

A panel of immunohistochemical stains was performed, and the tumor was only positive for epithelial membrane antigen (EMA; Figure 5A) and vimentin (Figure 5B). Stains for AE1/AE3, Melan-A, CD30, synaptophysin, NSE, CD45, CD99, desmin, and myogenin were negative. Based on the radiography, histopathology, and immunohistochemistry results, the definitive diagnosis was epithelioid osteosarcoma. The patient was informed about her condition and referred to an oncology center for specialized care and treatment.

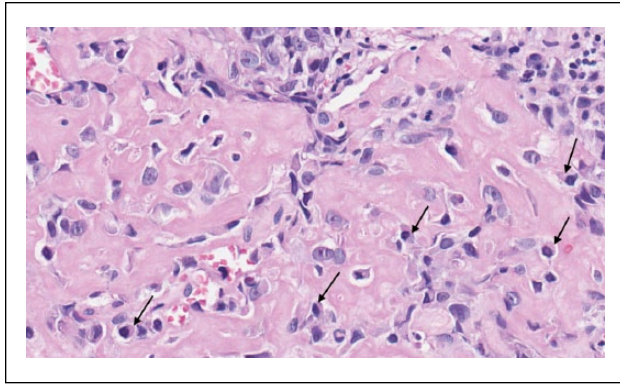


Figure 4. Prominent formation of osteoid by tumor cells in epithelioid osteosarcoma; some malignant osteoblasts show plasmacytoid features (black arrows) (hematoxylin and eosin, original magnification 40×).

Discussion

Osteosarcoma with epithelioid morphology is a rare, histological subtype of osteosarcoma that has been studied primarily in case reports⁹⁻¹² and in a few series.^{13,14} It was first reported by Scranton et al in 1975.¹⁴ The authors described this osteosarcoma as having an “endocrine” pattern that features pleomorphic epithelioid cells with malignant osteoid deposition. Similar to conventional osteosarcoma, this type of tumor affects patients from the first to seventh decades of life. It occurs predominately in long bones and affects males more often than females at ratio of 2 to 1.^{13,15} The radiological appearance of this tumor tends to be destructive, osteolytic, and ill-defined, with mineralization and periosteal reaction.¹³ Microscopically, the tumor consists of enlarged osteoblasts with epithelioid features that are organized in sheets, cords, trabeculae, glandular, or even rosette structures.⁸ The cells, which are usually round to polygonal in shape, display polymorphism, prominent mitosis, pale or eosinophilic cytoplasm, vesicular or hyperchromatic nuclei, and prominent nucleoli.^{8,13} Most osteosarcomas with epithelioid features are variants of the osteoblastic type,¹⁵ and multiple samplings of the tumor typically show malignant osteoblasts with osteoid deposition.⁸

This case report describes a 22-year-old woman with an extensive bony tumor that was ultimately diagnosed as epithelioid osteosarcoma of the maxilla. This tumor type is uncommon, and only 4 cases have been reported in the jaw area in the English-language literature (Table 1). Histologically, the present case demonstrated sheets of epithelioid cells with plasmacytoid features, and this was also reported by Carlos-Bregni et al.¹¹ This finding possibly represents a negative image of the Golgi complex.¹¹ Rosettes formation in epithelioid osteosarcoma was also described in multiple reports,^{11,13,16} but in the present case, it was seen only in a focal area. Although malignant

osteoid is a consistent finding of reports of epithelioid osteosarcoma, its amount has varied. In our case, it was prominent and contained malignant osteoblastic cells, a finding that supported the final diagnosis. Nevertheless, careful examination of the osteoid matrix should be performed to exclude other types of malignancies known to form calcifications.¹⁷ Osteoid formation by adjacent malignant osteoblasts is considered a key feature for the diagnosis of osteosarcoma.¹

Currently, immunohistochemistry has a limited role in diagnosing osteosarcoma, as this tumor type is largely identified by its morphologic features. In general, osteosarcoma has a broad immunoprofile that lacks diagnostic specificity.¹⁸ The present case showed diffuse positivity for both EMA and vimentin, which only agrees with one other reported case by Cozza et al.¹⁹ Other studies have reported negative results for epithelial markers, vimentin, or both (Table 1). Additionally, it is worth noting that the expression of epithelial markers in osteosarcomas is inconsistent and does not correlate with epithelioid morphology, as other histological variants, including chondroblastic and fibroblastic variants, also express these markers.¹⁵ This variability in marker expression might be explained by the multipotentiality of the mesenchymal cells in osteosarcomas.¹⁷

Because of the many histological variants of osteosarcoma, a wide range of tumor types needs to be considered in its differential diagnosis. Epithelioid osteosarcoma poses a diagnostic challenge, as it histologically mimics other malignant tumors with epithelioid features. Metastatic carcinomas originating from the breast, lungs, colon, and prostate may be mistaken for epithelioid osteosarcoma, especially if they stimulate osteoid formation.⁸ However, epithelioid osteosarcoma is more commonly observed in older patients (age 40 years and above) and is more often seen in the mandible than in the maxilla.¹¹ Other histologic mimickers of epithelioid osteosarcoma include metastatic melanoma of the bone, lymphoma, Ewing’s sarcoma, angiosarcoma, fibrosarcoma, leiomyosarcoma, rhabdomyosarcoma, and malignant peripheral nerve sheath tumor. In the present case, those tumor types were excluded based on an integrated study of the clinical, radiologic, histopathologic, and immunohistochemical results.

Given the low number of reported cases of epithelioid osteosarcoma, it has been difficult to determine the clinical behavior of this tumor type. Nevertheless, this tumor type has been shown to have aggressive behavior and a poor prognosis.¹³ Okada et al reported 6 cases of epithelioid osteosarcoma, 5 of whom died of the disease within 5 to 52 months of initial surgery or hospital admission.¹³ In addition, out of the 4 reported cases affecting the jaw region (Table 1), 2 patients died of the disease within 2 to 18 months of hospital admission.

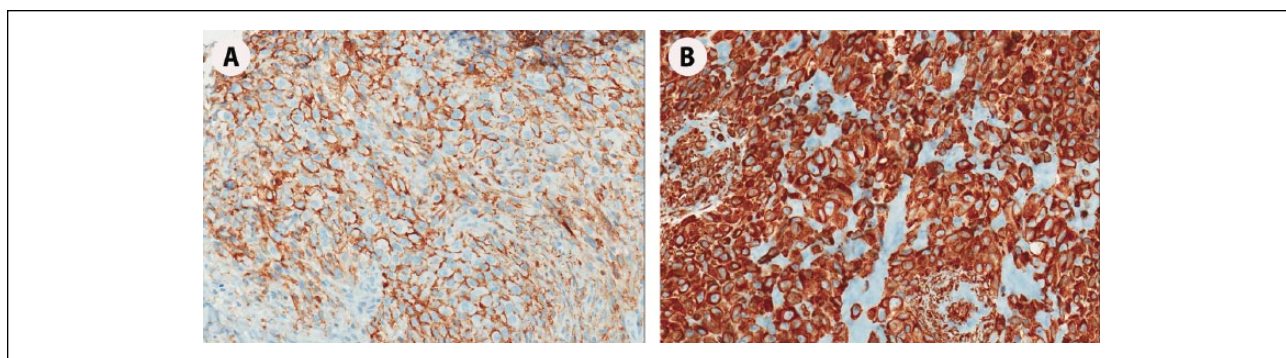


Figure 5. Tumor epithelioid cells show positivity for epithelial membrane antigen (A) and vimentin (B) (immunohistochemistry, original magnification 20×).

Table 1. Review of Reported Cases of Epithelioid Osteosarcoma in the Maxillofacial Region in English-Language Literature.

Case	Reference	Age (Years)	Gender	Site	CK	EMA	VIM	CD45	CD99
1	Rinaggio et al (2007) ¹⁰	50	Male	Maxilla	N	N	P	P	—
2	Carlos-Bregni et al (2008) ¹¹	42	Female	Mandible	N	N	N	—	N
3	Kaveri et al (2009) ¹²	4.5	Male	Maxilla	P	P	—	—	—
4	Cozza et al (2009) ¹⁹	8	Female	Mandible	N	P	P	—	N
5	Current case (2015)	22	Female	Maxilla	N	P	P	N	N

Abbreviations: P, positive; N, negative; CK, cytokeratin; EMA, epithelial membrane antigen; VIM, vimentin.

In summary, we have reported a case of epithelioid osteosarcoma in the jaw region because of its low occurrence rate and aggressive clinical behavior. The process of diagnosing this tumor was based on an integrated study of clinical, radiologic, and pathologic findings. In the majority of cases, the pathologist can rely exclusively on histopathologic examination to obtain an accurate diagnosis. However, in some cases, immunohistochemistry has to be employed to distinguish tumor entities that share morphologic characteristics.

Acknowledgments

The authors thank Dr Bishi ALGarni, oral and maxillofacial surgeon, and Dr Abdulmalik Alyahya, oral surgery senior resident, for providing the clinical information of this patient.

Declaration of Conflicting Interests

The author(s) declared no potential conflicts of interest with respect to the research, authorship, and/or publication of this article.

Funding

The author(s) received no financial support for the research, authorship, and/or publication of this article.

References

- Klein MJ, Siegal GP. Osteosarcoma: anatomic and histologic variants. *Am J Clin Pathol*. 2006;125:555-581.
- Hameed M, Dorfman H. Primary malignant bone tumors—recent developments. *Semin Diagn Pathol*. 2011;28:86-101.
- Pinieux G De, Gomez-Bouchet A, Bouvier C. *Markers for Bone Sarcomas*. 2d ed. Amsterdam, Netherlands: Elsevier; 2015:273-286.
- Clark JL, Unni KK, Dahlin DC, Devine KD. Osteosarcoma of the jaw. *Cancer*. 1983;51:2311-2316.
- Caron AS, Hajdu SI, Strong EW. Osteogenic sarcoma of the facial and cranial bones. *Am J Surg*. 1971;122:719-725.
- Delgado R, Maafs E, Alfeiran A, et al. Osteosarcoma of the jaw. *Head Neck*. 1994;16:246-252.
- Ogunlewe MO, Ajayi OF, Adeyemo WL, Ladeinde AL, James O. Osteogenic sarcoma of the jaw bones: a single institution experience over a 21-year period. *Oral Surg Oral Med Oral Pathol Oral Radiol Endod*. 2006;101:76-81.
- Deyrup AT, Montag AG. Epithelioid and epithelial neoplasms of bone. *Arch Pathol Lab Med*. 2007;131:205-216.
- Hasegawa T, Shibata T, Hirose T, Seki K, Hizawa K. Osteosarcoma with epithelioid features. An immunohistochemical study. *Arch Pathol Lab Med*. 1993;117:295-298.
- Rinaggio J, Kewitt GF, McGuff HS. Epithelioid osteosarcoma presenting as a rapidly expanding maxillary mass. *Head Neck*. 2007;29:705-709.
- Carlos-Bregni R, Contreras E, Hiraki KR, Vargas PA, León JE, de Almeida OP. Epithelioid osteosarcoma of the mandible: a rare case with unusual immunoprofile. *Oral Surg Oral Med Oral Pathol Oral Radiol Endod*. 2008;105:47-52.
- Kaveri H, Rekha K, Punnya VA. Epithelioid osteosarcoma of the maxilla: report of an unusual case. *Br J Oral Maxillofac Surg*. 2009;47:143-145.

13. Okada K, Hasegawa T, Yokoyama R. Rosette-forming epithelioid osteosarcoma: a histologic subtype with highly aggressive clinical behavior. *Hum Pathol.* 2001;32:726-733.
14. Scranton PE Jr, DeCicco FA, Totten RS, Yunis EJ. Prognostic factors in osteosarcoma. A review of 20 years' experience at the University of Pittsburgh Health Center Hospitals. *Cancer.* 1975;36:2179-2191.
15. Okada K, Hasegawa T, Yokoyama R, Beppu Y, Itoi E. Osteosarcoma with cytokeratin expression: a clinicopathological study of six cases with an emphasis on differential diagnosis from metastatic cancer. *J Clin Pathol.* 2003;56:742-746.
16. Okada K, Hasegawa T, Yokoyama R, Beppu Y, Itoi E. Prognostic relevance of rosette-like features in osteosarcoma. *J Clin Pathol.* 2003;56:831-834.
17. Mutsaers AJ, Walkley CR. Cells of origin in osteosarcoma: mesenchymal stem cells or osteoblast committed cells? *Bone.* 2014;62:56-63.
18. Hasegawa T, Hirose T, Kudo E, Hizawa K, Usui M, Ishii S. Immunophenotypic heterogeneity in osteosarcomas. *Hum Pathol.* 1991;22:583-590.
19. Cozza R, Devito R, De Ioris MA, et al. Epithelioid osteosarcoma of the jaw. *Pediatr Blood Cancer.* 2009;57:877-879.

Copyright of International Journal of Surgical Pathology is the property of Sage Publications Inc. and its content may not be copied or emailed to multiple sites or posted to a listserv without the copyright holder's express written permission. However, users may print, download, or email articles for individual use.