

Post-traumatic *Aspergillus* scleritis

Essam Osman, FRCS, Saeed Hassanyh, MD, Abdulrahman Al-Muammar, MBBS, FRCSC, Saleh Al-Obeidan, MD

Abstract

Fungal infection involving the sclera is extremely rare. We report the case of a 53-year-old man who developed post-traumatic *Aspergillus* fungal scleritis after trauma caused by branch of a tree. Diagnosis was made after tissue biopsy and successful outcome was achieved by scleral debridement, dura patch graft, and topical Amphotericine B. The patient had no signs of infection for 6 months after discontinuation of medication.

Key Words: Scleritis, fungus, *Aspergillus*, dura graft

Post traumatic fungal scleritis is uncommon and only a few cases have been reported after trauma. Brunet and Stulting¹ reported a 40-year-old man struck in his left eye by a flying chip of wood; a diagnosis of episcleritis was made and *Sporthrix schenckii*, a dimorphic fungus, was identified and treated with saturated solution of potassium iodide. Another case of traumatic scleritis caused by branch of a tree was reported by Rodriguez-Ares.² Diagnosis was established after biopsy of a scleral nodule which showed hyphal fragment, and cultures were positive for *Aspergillus fumigatus*. The patient was successfully treated with systemic antifungal drugs, cryotherapy, and dura graft.

Postoperative fungal scleritis has been reported after pterygium excision,³⁻⁷ retinal detachment surgery,⁸⁻⁹ cataract surgery,¹⁰⁻¹³ glaucoma surgery,¹⁰ and in association with systemic fungus infection.¹⁴

Aspergillus species are saprophytic molds. Most live in the environment without causing disease. *Aspergillus fumigatus* is the most common human pathogen. Other species causing infection include *A. niger* and *A. flavus* and *A. nidulans*.

Invasive aspergillosis occurs mainly in an immune-compromised patient, and is often life threatening. The hyphae of *Aspergillus* can be detected microbiologically in a KOH or calcofluor white showing typical *Aspergillus* fruiting head showing a conidiophore, swollen vesicle and phialides.

The outcome of management of fungal scleral infection depends on early detection, type of organism, and modality of intervention. In this report we present a 53-year-old man who developed post-traumatic *Aspergillus* scleritis. To the best of our knowledge there are only 2 previous cases reported as post traumatic fungal scleritis.

CASE REPORT

A 53-year-old man presented to the Emergency Room with history of trauma to his left eye caused by branch of a tree. He complained of pain and redness in his left eye. On examination he had visual acuity OS 20/60 (amblyopic eye), normal intraocular pressure, intense temporal conjunctival hyperemia, clear cornea, deep and quiet anterior chamber, round regular reactive pupil, clear lens and normal fundus examination. Examination of right eye was unremarkable.

It was difficult to evaluate temporal sclera because of intense conjunctival hyperemia. Globe exploration

From the Department of Ophthalmology, College of Medicine, King Saud University, Riyadh, Kingdom of Saudi Arabia.

Correspondence to Essam Osman, FRCS, King Abdulaziz University Hospital, PO Box 245, Riyadh 11411, Kingdom of Saudi Arabia. Telephone: 966-1-477-5731; Fax: 966-1-477-5741; Email: essamosman@hotmail.com

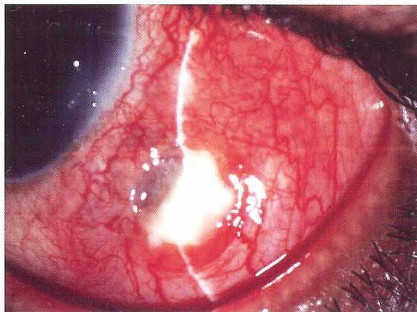


Figure 1. Slit lamp picture of the left eye showing necrotic tissue and blue sclera beneath it.

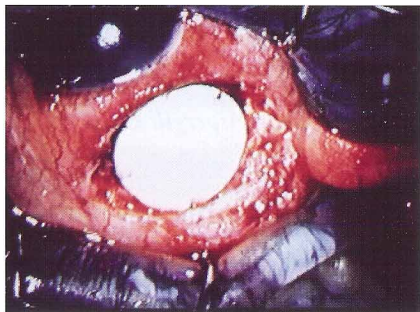


Figure 2. Picture taken during surgery while dura graft was placed over the area of scleral thinning.

showed no globe laceration or foreign body, and no organism was found from the scraping. Patient was discharged on Ofloxacin® eye drops 4 times a day in his left eye.

One week later, slit lamp examination revealed severe conjunctival injection associated with small conjunctival epithelial defect; Maxitrol® eye ointment twice a day was added. Over the next 2 weeks the patient's condition worsened as the pain persisted; conjunctival epithelial defect increased in size, with necrotic tissue and bluish discoloration of the sclera (Fig. 1). Patient underwent another globe exploration which revealed grayish membrane overlying the sclera under swollen conjunctiva. The unhealthy conjunctiva, grayish membrane and the underlying necrotic scleral tissue were excised and sent for histopathology

and microbiological examination. Artificial dura matter grafting was applied over the area of scleral thinning (Fig. 2); then the graft was covered with healthy conjunctiva.

Postoperatively, whilst waiting for histopathology results, the patient was treated with topical Ofloxacin® eye drops 4 times a day to the left eye. Interestingly the result showed 45° angle branching septate fungal hyphae consistent with *Aspergillus*, and the culture was negative (Fig. 3). Based on this result, patient was treated with topical Amphotericine B® 0.25% 4 times a day.

After 2 weeks the patient was doing very well, pain disappeared, redness subsided and visual acuity unchanged. Slit lamp examination revealed quiet eye and healed conjunctiva (Fig. 4). All medications were dis-

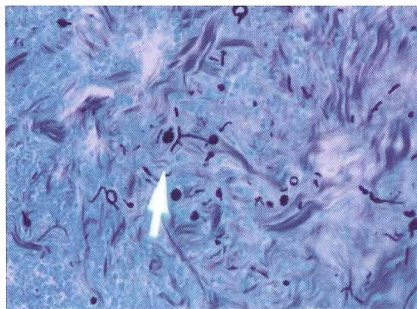


Figure 3. Grocott's methenamin silver stain showing 45° angle branching septate fungal hyphae consistent with *Aspergillus* infection.

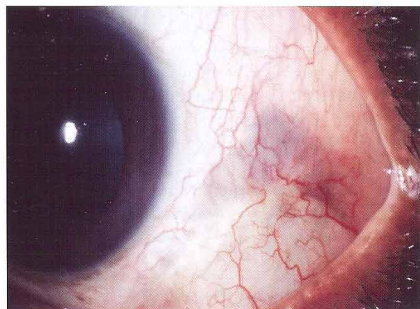


Figure 4. Slit lamp picture of the left eye which was taken 4 weeks post scleral excision and dura graft.

continued at that time. The patient was followed up for 6 months with no signs of recurrence.

DISCUSSION

Inflammatory scleral disease is commonly associated with autoimmune disorders but may rarely be caused by an infective agent. Infectious scleritis can be caused by different organisms such as *Pseudomonas*, *Aspergillus*, *Mycobacteria* and mixed organisms.⁷

Primary fungal scleral infection in a non immune-compromised patient is extremely rare but should be suspected when there is history of scleral traumatic injury, cataract surgery especially in diabetics¹² with/without topical steroid therapy,¹⁵ pterygium surgery, glaucoma surgery, retinal detachment surgery or in association with systemic fungal infection. The onset of fungal scleritis is usually delayed but it may start early after trauma.

Clinical presentation of fungus scleritis frequently consists of persistent redness, ulceration, severe postoperative anterior chamber reaction,¹¹ abscess and/or nodule formation,⁹ and typically do not respond to routine antibiotics. Therefore, scleritis especially after surgery in diabetics or in geographic areas with hot and humid climates should alert the ophthalmologist for fungal infection.¹¹

Diagnosis of fungus scleritis is often difficult as the organisms are usually deep in the sclera, few in number, and are rarely revealed by scraping. Once a physician suspects fungus scleritis, scleral biopsy is necessary to confirm the diagnosis by microbiological and histopathological examination.

In our case fungal scleritis was diagnosed based on histopathology. However, microbiological studies were negative. Wolfgang¹⁰ et al emphasized failure to detect the fungus in cultures should not exclude the infection as histopathology may reveal the organism in spite of negative cultures. Rodriguez-Ares et al² reported a similar case of traumatic *Aspergillus fungal scleritis* that followed trauma by branch of a tree. They were able to culture *Aspergillus fumigatus*, and the patient was treated with oral Fluconazole[®], topical Amphotericine B[®], and application of cryotherapy and dura graft. Brunette et al¹ reported another additional case of scleritis that followed trauma by chip of wood; microbiological workup revealed *Sporothrix schenckii*. The patient was treated successfully with saturated solution of potassium iodide.

Management of fungus scleritis remains difficult despite the new antifungal treatment available, due to

poor penetration of these medications to sclera. Oral Itraconazole[®] as a medical therapy alone had been reported by Carlson in dealing with *Aspergillus scleritis* that followed cataract surgery.¹³

Reynolds et al suggested that surgical intervention plus antifungal treatment might improve the outcome of fungus scleritis.¹⁵

In our case successful outcome was achieved by scleral debridement, dura matter patch graft, and topical Amphotericine B[®].

Wolfgang et al recommended that surgical excision with subsequent grafting has the advantage over cryotherapy in that tissue for diagnosis is provided and the treated area is more clearly defined.¹⁰

In conclusion, the diagnosis of fungal scleritis should be differential diagnosis to traumatic scleritis and should not be excluded on the basis of negative culture; deep tissue biopsy is necessary. Successful treatment of traumatic *Aspergillus scleritis* can be achieved by adequate excision of infected sclera, and by using dura graft to restore the scleral thickness with topical antifungal treatment.

REFERENCES

1. Brunette I, Stulting RD. *Sporothrix schenckii* scleritis. Am J Ophthalmol 1992; 114:370-1.
2. Rodriguez-Ares MT, De Rojas Silva, Pereiro M, et al. *Aspergillus fumigatus* scleritis. Acta Ophthalmol Scand 1995;73:467-9.
3. Huang F-C, Huang S-P, Tseng S-H. Management of infectious scleritis after pterygium excision. Cornea 2003;19:34-9.
4. Moriarty AP, Geoffrey JC, McAllister L, et al. Severe corneoscleral infection: a complication of beta irradiation scleral necrosis following pterygium excision. Arch Ophthalmol 1993;111:47-51.
5. Margo CE, Polack FM, Hood C I. *Aspergillus* panophthalmitis complicating treatment of pterygium. Cornea 1988;7:285-9.
6. Moriarty AP, Crawford GJ, Atister IL, Constable JJ. Fungal corneoscleritis complicating beta-irradiation-induced scleral necrosis following pterygium excision. Eye 1993;7:525-8.
7. Hsiao C, Chin J, Huang S, et al. Intrasceral dissemination of infectious scleritis following pterygium excision. Br J Ophthalmol 1998;82:29-34.
8. Milauskas A, Duke J. Mycotic scleral abscess: report of a case following a scleral buckling operation for retinal detachment. Am J Ophthalmol 1967;63:951-4.
9. Judy E Kim, Stephen L Perkins, Gerald J Harris, et al. Variconazole treatment of fungal scleritis and epibulbar abscess resulting from scleral buckle infection. Arch

- Ophthalmol 2003;121:735-7.
10. Wolfgang B, Bruce DA, John KG. Successful management of aspergillus scleritis by medical and surgical treatment. Eye 1998; 12:311-6.
 11. Garg P, Mahesh S, Aashish K, et al. Fungus infection of sutureless self sealing incision for cataract surgery. Ophthalmology 2003;110:2137-7.
 12. Locher D, Adesina A, Wolf T, et al. Postoperative Rhizopus scleritis in a diabetic man. J Cataract Refract Surg 1998;24:562-65.
 13. Carlson AN, Foulks GN, Perfect JR, Kim JH. Fungal scleritis after cataract surgery. Successful outcome using itraconazole. Cornea 1992;11:151-4.
 14. Stenson S, Brookner A, Rosenthal S. Bilateral endogenous necrotizing scleritis due to aspergillus oryzae. Ann Ophthalmol 1982;14:67-72.
 15. Reynolds MG, Alfonso E. Treatment of infectious scleritis and keratoscleritis. Am J Ophthalmol 1991;112:543-7.