

## Original Paper

# Protective Effect of Morocco Carob Honey Against Lead-Induced Anemia and Hepato-Renal Toxicity

Aicha Fassi Fihri<sup>a</sup> Noori S. Al-Waili<sup>b</sup> Redouan El-Haskoury<sup>a</sup> Meryem Bakour<sup>a</sup>  
Afaf Amarti<sup>c</sup> Mohammad J. Ansari<sup>d</sup> Badiia Lyoussi<sup>a</sup>

<sup>a</sup>Laboratory of Physiology, Pharmacology and Environmental Health. Faculty of Sciences Dhar Mahraz, University Sidi Mohamed Ben Abdallah, Fez, Morocco; <sup>b</sup>New York Medical Care for Nephrology, Richmond Hill, New York, USA; <sup>c</sup>Laboratory of Anatomical Pathology, CHU, Fez, Morocco; <sup>d</sup>Department of Biotechnology, Indian institute of Technology Roorkee, Roorkee, Uttarakhand, India

## Key Words

Lead • Honey • Kidney • Liver • Antioxidant • Hemoglobin

## Abstract

**Background/Aims:** Natural honey has many biological activities including protective effect against toxic materials. The aim of this study was to evaluate the protective effect of carob honey against lead-induced hepato-renal toxicity and lead-induced anemia in rabbits. **Methods:** Twenty four male rabbits were allocated into four groups six rabbits each; group 1: control group, received distilled water (0.1 ml / kg.b.wt /daily); group 2: received oral lead acetate (2 g/kg.b.wt/daily); group 3: treated with oral honey (1g /kg.b.wt/daily) and oral lead (2 g/kg.b.wt/daily), and group 4: received oral honey (1 g/kg.b.wt/daily). Honey and lead were given daily during 24 days of experimentation. Laboratory tests and histopathological evaluations of kidneys were done. **Results:** Oral administration of lead induced hepatic and kidney injury and caused anemia during three weeks of the exposure. Treatment with honey prevented hepato-renal lead toxicity and ameliorated lead-induced anemia when honey was given to animals during lead exposure. **Conclusion:** It might be concluded that honey has a protective effect against lead-induced blood, hepatic and renal toxic effects.

© 2016 The Author(s)  
Published by S. Karger AG, Basel

## Introduction

Pollutants such as lead, nickel, cadmium, vanadium and mercury can induce kidney and liver toxicity. Kidney is the main route by which lead is eliminated and then absorbed by the proximal tubular cells. Lead is the most well- studied toxic metal, and its biological effect is dependent on the level and duration of the exposure. Lead is one of the most dangerous metals because it is widely present in the soil, water, and food.

Noori Al-Waili MD, PhD, FASN

New York Medical Care for Nephrology, 87-40 134 street, Richmond hill, New York 11418, (USA)  
E-Mail Drnoori6@yahoo.com

KARGER

It was well-known that chronic lead exposure leads to nephropathy, gout and hypertension. Epidemiological studies showed that blood lead level are related to renal function and has an impact on age-related decreases in renal function in the general population [1-3]. Acute lead poisoning and consequent nephropathy are usually observed in children aged three months to six years [4]. Studies showed that environmental exposure to lead, even at low levels, is associated with chronic kidney disease (CKD) in the general population [5-8]. Furthermore, environmental lead exposure might influence progressive diabetic nephropathy [9]. It was shown that lead exposure hastens progressive CKD by accelerating microvascular and tubulointerstitial injury in rat CKD model [10].

Several plant products have antioxidant properties and have been used as prophylactics or curatives [11-13]. Recently, it was found that *G. kola*, *A. sativum*, *Z. officinale* and *L. esculentum* reduced hepatotoxic effect of lead [14-17]. We have found that honey has beneficial effects on renal function in normal volunteers [18]. In addition, our studies demonstrated that honey can protect liver and kidney during acute blood loss and after CCl<sub>4</sub> intoxication [19-21]. Honey has been mentioned in Holy books as a healer of diseases. It was mentioned in the Talmud, both the old and new testaments of the Bible, and the Holy Quran. In the Surat AL-Nahel (The Bee) it says: And thy LORD taught the bee to build its cells in hills, on tree and in men's habitations, then to eat of all the produces (fruits) of the earth and find with skill the spacious paths of its LORD, there issues from within their bodies a drink of varying colors, wherein is healing for men, verily in this is a sign for those who give thought. The objective of this study is to investigate whether using natural honey from Morocco could prevent or ameliorate lead-induced hepato-renal toxicity.

## Materials and Methods

### Lead and honey

Lead acetate trihydrate was used for the experimentation. It was purchased from Sigma-Aldrich and it was dissolved in distilled water. The dose of lead acetate was 2 g/kg.b.wt/day, the value that represents the half of lethal dose of this product (DL<sub>50</sub> Oral (e) - rat - 4.665 g/kg.b.wt).

The type of honey used was carob honey that was purchased from beekeeper in Taounate region, Morocco, and was stored at room temperature. Some physicochemical parameters of carob honey included: color: dark amber, pH: 4.79, moisture: 19.5%, electric conductivity: 1.27 mS/cm, and ash content: 0.65%. The dose of honey was 1g/kg. b.wt/day [22].

### Experimental animals

Twenty-four male white rabbits, of either sex, weight 800+/-50 g, were used for the experimentation. The animals were housed in metal cages and maintained at uniform temperature of 22 ± 2°C, and 12 h/12 h light/dark cycle. The rabbits were maintained on laboratory chow and water *ad libitum*.

The animals were allocated into four groups six rabbits each; group 1: control group, received distilled water (0.1 ml / kg.b.wt/ day); group 2: received lead at a dose of 2 g/kg. b.wt./day; group 3: treated with honey (1 g/kg.b.wt/day) and lead at a dose of 2 g/kg.b.wt/day (both interventions were given at same time after each other), and group 4: received oral honey (1 g/kg.b.wt/day). Experimentation continued for 24 days and the animals received the interventions daily for 24 days. Lead was administered by oral gavage guaranteeing an exposure of 2 g/kg.b.wt. On day 24 of the treatment, the rabbits were sacrificed and the kidneys were isolated from all animals of the four groups. The animals' weights were measured on the days 1, 11, 18, and 24.

Investigations using experimental animals were approved by the institutional committee, the University Hospital Hassan II Fez, and were conducted in accordance with the internationally accepted principles for laboratory animal use and care for animals following the French Technical Specifications for the Production, Care and Use of the Laboratory Animals.

### Blood tests

The blood samples were collected for hematological and biochemical analysis after 12 hr fasting from marginal ear veins on days 7, 14 and 24 before the administration of test sample. Blood count was

determined by an automated hematology (Sysmex KX-21 JAPAN), laboratory of the University Hassan II Complex. Biochemical parameters including serum creatinine (SCr), blood urea (BUN), and liver enzymes were determined by the controller OLYMPUS AU 640 biochemistry laboratory at the University Campus Hassan II, Morocco.

#### Histopathological study in the kidney

The study was conducted at Pathology Laboratory, University Hospital of Fez. The kidneys were removed and were immediately fixed in formalin solution at 10%, and they were subjected to observation with the naked eye to explore any gross abnormality. For qualitative analysis of kidney pathology, the tissue samples were fixed for 48 h in 10% formalin solution, dehydrated in an ascending graded series of ethanol, cleared in toluene and embedded in paraffin. Sections of the tissue (5–6 mm thickness) were prepared by using a rotary microtome and stained with hematoxylin and eosin (H & E) for microscopic observations.

#### Statistical analysis

The data were expressed as mean  $\pm$  SEM of variables. Statistical comparisons between the groups were performed with one-way (ANOVA) followed by Tukey test (Graph Pad Prism 5 software).  $P < 0.05$  was significant.

## Results

Regarding body weight, after 24 days the weight of rabbits treated with lead ( $774.66 \pm 38.32$  g) decreased significantly ( $p < 0.01$ ) as compared to rabbits in the control group ( $981.66 \pm 15.53$  g) and those in the group treated with lead and honey ( $844.16 \pm 70.45$  g) (Fig. 1). With the use of honey, changes in the body weight were not significant when compared with the control group.

Regarding biochemical parameters, there is no significant difference in the level of SGOT in the control group and in the groups treated with honey alone or honey and lead. However, on day 24, SGOT increased significantly in the group treated with lead as compared to the control, from  $45 \pm 1.38$  U/l to  $53 \pm 0.93$  U/l (Fig. 2). For SGPT, Lead causes significant elevation of SGPT during all the times as compared to other groups, while with use of honey the elevation of SGPT was not significant (Fig. 3).

Regarding the kidney function, lead caused significant elevation of SCr on day 14 ( $0.9 \pm 0.054$  mg/dl) and 24 ( $1 \pm 0.078$  mg/dl) as compared to the control group ( $0.61 \pm 0.078$ ) and group treated with use of honey alone ( $0.61 \pm 0.059$ ). When

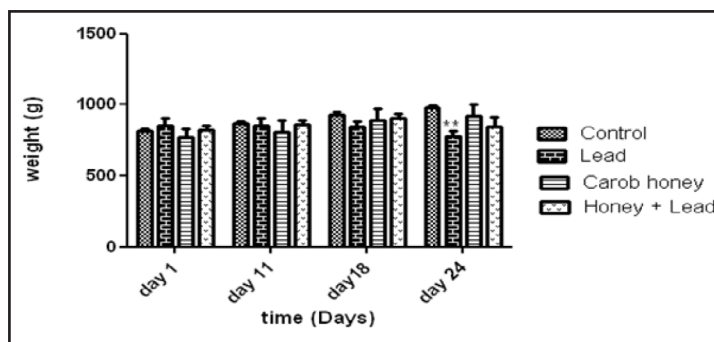


Fig. 1. Effects of lead and honey on the body weight. \*\*  $p < 0.01$ .

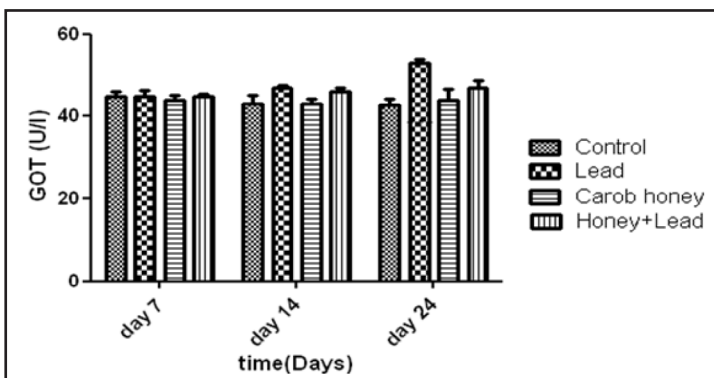


Fig. 2. Effects of lead and honey on SGOT (\* $P < 0.05$ ; \*\* $P < 0.01$ ; \*\*\* $P < 0.001$ ).

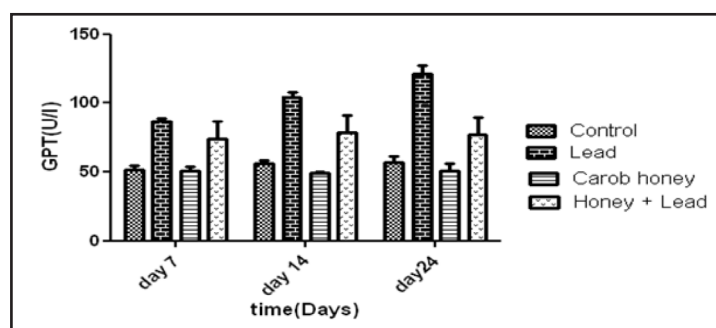
the animals fed honey in addition to lead, there was an insignificant elevation of SCr as compared to the control (Fig. 4). Similar results were obtained regarding BUN (Fig. 5).

Lead caused significant reduction of hemoglobin on days 7 ( $10.73 \pm 0.45$  g/dl), 14 ( $8.76 \pm 0.84$  g/dl) and 24 ( $7.73 \pm 0.65$  g/dl). Animals fed honey alone showed no changes in hemoglobin level and animals fed honey in addition to lead showed mild reduction in hemoglobin as compared to the control group (Fig. 6). Lead increased the number of lymphocytes significantly which was pronounced on day 24, from  $4433.33 \pm 329.7$  / mm<sup>3</sup> to  $6294.5 \pm 211.31$  / mm<sup>3</sup> (Fig. 7). Also lead increased neutrophils counts but the differences were insignificant as compared to the other groups (Fig. 8).

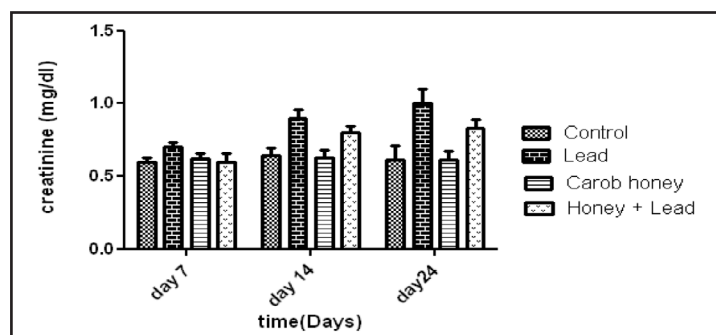
In the control group (Fig. 9A), histopathological studies showed that renal tubes were regular and there was no fibrosis. However, in the second group treated by lead there were a sign of necrosis in the kidney, interstitial fibrosis, and mesangial hyperplasia (Fig. 9B1 and B2). No sign of kidney damage was observed in the animals treated with honey and lead (Fig. 9C).

## Discussion

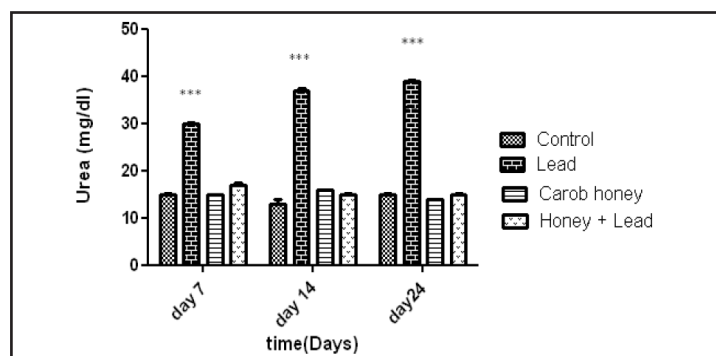
The results of this study showed that honey has a protective effect against lead hepato-renal toxicity. This effect was evident



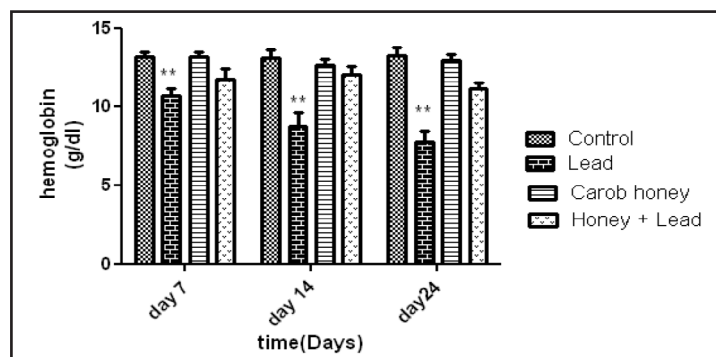
**Fig. 3.** Effects of lead and honey on SGPT (\*P < 0.05; \*\*P < 0.01; \*\*\*P < 0.001).



**Fig. 4.** Effects of lead and honey on serum creatinine (\*P < 0.05; \*\*P < 0.01; \*\*\*P < 0.001).



**Fig. 5.** Effects of lead and honey on the blood urea (\*P < 0.05; \*\*P < 0.01; \*\*\*P < 0.001).

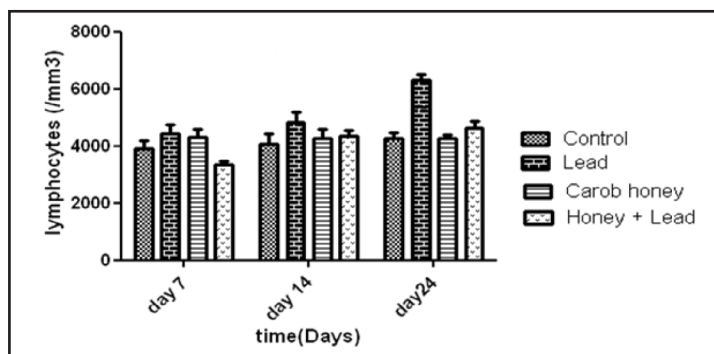


**Fig. 6.** Effects of lead and honey on hemoglobin (\*P < 0.05; \*\*P < 0.01; \*\*\*P < 0.001).

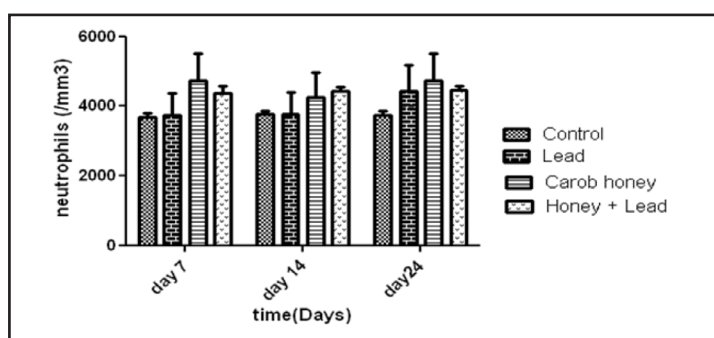


with normalization of liver enzymes and kidney function tests, and amelioration of histopathological changes caused by lead. The mechanism of action might be related to various beneficial properties of honey such as anti-inflammatory and antioxidants action.

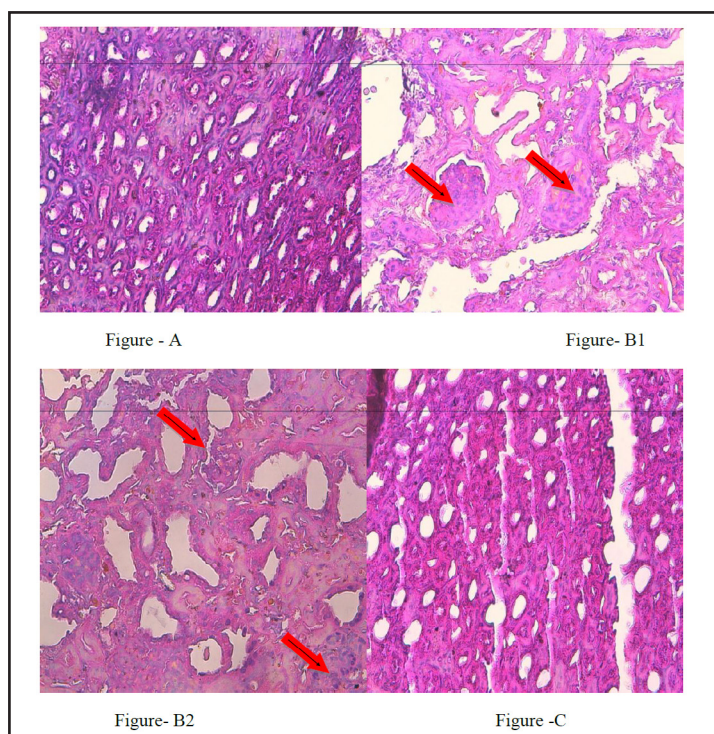
Lead exposure causes kidney toxicity. It was found that lead acetate administered by oral route to adult rats at the rate of 0.3% and 0.6% increased SCr on the 30th day of the experiment [23]. Lead can cause increase in intracellular calcium and reactive oxygen species, and it can trigger apoptosis through the cytochrome C release and a fall in the mitochondrial potential [24, 25]. It was found that renal excretion of 6-keto-prostaglandin factor 1- $\alpha$ , prostaglandin E<sub>2</sub>, and thromboxane B<sub>2</sub> excretion was increased in children exposed to lead [26]. Other studies showed that chronic exposure to low-dose lead causes generation of reactive oxygen species, reduces nitric oxide availability, increases blood pressure and promotes secondary upregulation of endothelial nitric oxide synthase [27-29]. Furthermore, lead stimulates hydroxyl radical generation and lipid peroxidation, and enhances vascular reactivity to sympathetic stimulation [30]. Consequently, it was found that lead chelating agents or antioxidants treatment can alleviate lead-induced oxidative stress and reduced nitric oxide availability in rats [31, 32].



**Fig. 7.** Effects of lead and honey on the lymphocytes count (\* $P < 0.05$ ; \*\* $P < 0.01$ ; \*\*\* $P < 0.001$ ).



**Fig. 8.** Effects of lead and honey on the neutrophils count (\* $P < 0.05$ ; \*\* $P < 0.01$ ; \*\*\* $P < 0.001$ ).



**Fig. 9.** Histopathological changes caused by lead alone or lead with honey. (A) Normal control, (B1) after lead ingestion, (B2) after lead ingestion, (C) After lead and honey ingestion.

Others and we have found that honey has anti-inflammatory, antimicrobial, and antioxidant activities [33-36]. In our previous study, it was found that honey decreased urinary prostaglandins concentration including thromboxane B and increased total urinary nitrite content [18]. Honey increased insignificantly free water clearance, filtered sodium and creatinine clearance. It decreased insignificantly urinary osmolality, urinary calcium, and urinary sodium [18]. We have found that honey increases nitric oxide end products in various biological fluids including blood, saliva and urine [18, 22, 37]. Furthermore, honey lowers plasma concentrations of thromboxane B2, PGE2, and PGF2a [38]. In healthy subjects, honey increased antioxidant agents, serum iron, blood indices, trace elements, and decreased immunoglobulin E and liver and muscle enzymes [39]. Therefore, honey might encounter stimulatory effect of lead on thromboxane excretion as well as inhibitory effect of lead on nitric oxide generation. Also it was found that honey can ameliorate anemia seen in rabbits exposed to lead. This might be due to ability of honey to increase iron and to stimulate bone marrow.

In addition, we found that a significant reduction in BUN, AST, ALT, and alkaline phosphatase, and a significant elevation of hemoglobin were obtained after acute blood loss in rats' model exposed to total food restriction and 50% honey feeding as compared with the animals subject to bleeding. It was concluded that honey feeding during total food restriction has protective effects on both liver and kidney after acute blood loss [19]. In another experiment, we found that oral honey feeding significantly ameliorates biochemical and hematological changes obtained after CCl4 injection; showing hepato-renal protection [20]. Another study from our center demonstrated that intravenous honey had a hepatoprotective effect against CCl4-induced liver injury. It reduced SGOT, SGPT, and BUN, and it elevated serum protein, serum albumin, hemoglobin, and white blood cell [21].

In chronic lead nephropathy, the pathological changes usually are nonspecific. Contracted Kidney with a granular surface could be encountered. Microscopical sections usually show varying degrees of relatively a cellular interstitial nephritis with periglomerular fibrosis. Immunofluorescence shows a variety of immunoglobulin deposits in glomerular capillaries and tubular basement membranes. The inclusion bodies in glomerular cells are seen in chronic exposure and absent in acute exposure. In the present study, kidney pathology examination in control group showed regular normal tubes without interstitial fibrosis. However in the group treated by lead there was a sign of necrosis in the kidneys, interstitial fibrosis and mesangial hyperplasia. Interestingly, no sign of kidney damage was observed in the animals treated with honey and lead. These results showed that honey can protect structural damage caused by lead exposure. The mechanism again might be due to various biological activities of honey, in particular, antioxidant. In addition, honey and lead were given at same time every day. Therefore, there is a possibility that honey might decrease lead absorption. This hypothesis required measuring of lead level in the blood when both interventions are given together. Further studies are in progress in our laboratories.

## Conclusion

It could be concluded that honey has a marked protective effect against lead-induced blood, hepatic and renal toxicity. The mechanism of action might be due to modulation of prostaglandins, nitric oxide production, lead absorption, and antioxidant and anti-inflammatory effects of honey. Further studies are required to explore the mechanism of action and whether our results have a future clinical application.

## Disclosure Statement

The authors declare that there is no conflict of interest regarding publication of this manuscript.

## References

- 1 Staessen J, Lauwerys R, Buchet J: Impairment of renal function with increasing blood lead concentrations in the general population. *N Engl J Med* 1992;327:151–156.
- 2 Payton M, Hu H, Sparrow D, Weiss S: Low-level lead exposure and renal function in the normative aging study. *Amer J Epidemiol* 1994;140:821–829.
- 3 Kim R, Rotnitzky A, Sparrow D, Weiss T, Wager C, Hu H: A longitudinal study of low-level lead exposure and impairment of renal function: the normative aging study. *JAMA* 1996;275:1177–1181.
- 4 Mitra AK, Haque A, Islam M, Bashar SA: Lead poisoning: an alarming public health problem in Bangladesh. *Int J Environ Res Public Health* 2009;6:84–95.
- 5 Muntner P, He J, Vupputuri S, Coresh J, Batuman V: Blood lead and chronic kidney disease in the general United States population: results from NHANES III. *Kidney Inter* 2003;63:1044–1050.
- 6 Navas-Acien A, Tellez-Plaza M, Guallar E: Blood cadmium and lead and chronic kidney disease in US adults: a joint analysis. *Amer J Epidemiol* 2009;170:1156–1164.
- 7 Huang W, Lin J, Lin-Tan D, Hsu C, Chen K, Yen T: Environmental Lead Exposure Accelerates Progressive Diabetic Nephropathy in Type II Diabetic Patients. *BioMed Res Intern* 2013;2013:742545.
- 8 Muntner P, Menke A, DeSalvo KB: Continued decline in blood lead levels among adults in the United States: the National Health and Nutrition Examination Surveys. *Arch Intern Med* 2005;165:2155–2161.
- 9 Lin J, Lin-Tan D, Yu C, Li Y, Huang Y, Li K: Environmental exposure to lead and progressive diabetic nephropathy in patients with type II diabetes. *Kidney Inter* 2006;69:2049–2056.
- 10 Roncal C, Mu W, Reungjui S: Lead, at low levels, accelerates arteriolopathy and tubulointerstitial injury in chronic kidney disease. *Amer J Physiol* 2007;293:F1391–F1396.
- 11 Nwokocha CR, Owu DU, Ufearo CS, Iwuala MO: Comparative study on the efficacy of *Garcinia kola* in reducing some heavy metal accumulation in liver of Wistar rats. *J Ethnopharmacol* 2011;135:488–491.
- 12 Shi J, Le Maguer M: Lycopene in tomatoes: Chemical and physical properties affected by food processing. *Crit Rev Food Sci Nutr* 2000;40:1–42.
- 13 Nwokocha CR, Ozolua RI, Owu DU, Nwokocha MI, Ugwu AC: Antihypertensive properties of *Allium sativum* (garlic) on normotensive and two kidney one clip hypertensive rats. *Niger J Physiol Sci* 2011;26:213–218.
- 14 Nwokocha CR, Owu DU, Ufearo CS, Iwuala MO: Comparative study on the efficacy of *Garcinia kola* in reducing some heavy metal accumulation in liver of Wistar rats. *J Ethnopharmacol* 2011;135:488–491.
- 15 Nwokocha CR, Owu DU, Nwokocha MI, Ufearo CS, Iwuala MO: Comparative study on the efficacy of *Allium sativum* (garlic) in reducing some heavy metal accumulation in liver of wistar rats. *Food Chem Toxicol* 2012;50:222–226.
- 16 Nwokocha CR, Owu DU, Nwokocha MI, Ufearo CS, Iwuala MO: Comparative study on the hepatoprotection to heavy metals of *Zingiber officinale*. *Pharmacognosy Res* 2012;4:208–213.
- 17 Nwokocha CR, Nwokocha MI, Aneto I, Obi J, Udekweleze DC, Olatunde B: Comparative analysis on the effect of *Lycopersicon esculentum* (tomato) in reducing cadmium, mercury and lead accumulation in liver. *Food Chem Toxicol* 2012;50:2070–2073.
- 18 Al-Waili NS: Effects of honey on the urinary total nitrite and prostaglandins concentration. *Int Urol Nephrol* 2005;37:107–111.
- 19 Al-Waili NS, Saloom KY, Akmal M, Al-Waili F, Al-Waili TN, Al-Waili AN, Ali A: Honey ameliorates influence of hemorrhage and food restriction on renal and hepatic functions, and hematological and biochemical variables. *Int J Food Sci Nutr* 2006;57:353–362.
- 20 Al-Waili NS, Saloom KY, Al-Waili TN, Al-Waili AN, Akmal M, Al-Waili FS, Al-Waili HN: Influence of various diet regimens on deterioration of hepatic function and hematological parameters following carbon tetrachloride: a potential protective role of natural honey. *Nat Prod Res* 2006;20:1258–1264.
- 21 Al-Waili NS: Intravenous and intrapulmonary administration of honey solution to healthy sheep: effects on blood sugar, renal and liver function tests, bone marrow function, lipid profile, and carbon tetrachloride-induced liver injury. *J Med Food* 2003;6:231–247.
- 22 Al-Waili NS, Boni NS: Honey increased saliva, plasma, and urine content of total nitrite concentrations in normal individuals. *J Med Food* 2004;7:377–380.
- 23 Ghorbe F, Boujelbene M, Makni-Ayadi F, Guermazi F, Kammoun A, Murat J, Croute F, Soleilhavoup A: Effect of Chronic Lead Exposure on Kidney Function in Male and Female Rats: Determination of a Lead Exposure Biomarker. *Arch Physiol Biochem* 2001;109:457–463.

- 24 Flora SJ, Saxena G, Mehta A: Reversal of lead-induced neuronal apoptosis by chelation treatment in rats: role of reactive oxygen species and intracellular Ca (2+). *J Pharmacol Exp Ther* 2007; 322:108-116.
- 25 Xu J, Ji LD, Xu LH: Lead-induced apoptosis in PC 12 cells: involvement of p53, Bcl-2 family and caspase-3. *Toxicol Lett* 2006;166:160-167.
- 26 Fels LM, Wünsch M, Baranowski J, Norska-Borówka I, Price RG, Taylor SA, Patel S, De Broe M, Elsevier MM, Lauwerys R, Roels H, Bernard A, Mutti A, Gelpi E, Roselló J, Stolte H: Adverse effects of chronic low level lead exposure on kidney function--a risk group study in children. *Nephrol Dial Transplant* 1998;13:2248-2256.
- 27 Prozialeck WC, Edwards JR, Nebert DW: The vascular system as a target of metal toxicity. *Toxicol Sci* 2008;102:207-218.
- 28 Vaziri ND, Khan M: Interplay of reactive oxygen species and nitric oxide in the pathogenesis of experimental lead-induced hypertension. *Clin Exp Pharmacol Physiol* 2007;34:920-925.
- 29 Vaziri N: Mechanisms of lead-induced hypertension and cardiovascular disease. *Amer J Physiol* 2008;295:H454-H465.
- 30 Ding Y, Gonick H, Vaziri N: Lead promotes hydroxyl radical generation and lipid peroxidation in cultured aortic endothelial cells. *Amer J Hyperten* 2000;13:552-555.
- 31 Nwokocha CR, Ufearo CS, Owu DU, Idemudo NC, Ojukwu LC: *In vivo* distribution of lead in male and female rats after intraperitoneal and oral administration. *Toxicol Ind Health* 2012;28:131-135.
- 32 Flora SJ, Saxena G, Mehta A: Reversal of lead-induced neuronal apoptosis by chelation treatment in rats: role of reactive oxygen species and intracellular Ca (2+). *J Pharmacol Exp Ther* 2007;322:108-116.
- 33 Al-Waili NS, Salom K, Butler G, Al Ghamdi AA: Honey and microbial infections: a review supporting the use of honey for microbial control. *J Med Food* 2011;14:1079-1096.
- 34 Al-Waili N, Salom K, Al-Ghamdi AA: Honey for wound healing, ulcers, and burns; data supporting its use in clinical practice. *ScientificWorldJournal* 2011;11:766-787.
- 35 Erejuva O, Sulaiman A, Wahab MS: Honey: a novel antioxidant. *Molecules* 2012;17:4400-4423.
- 36 Kassim M, Achoui M, Mustapha MR, Mohd MA, Yussof KM: Ellagic acid, phenolic acids and flavonoids in Malaysian honey extracts demonstrate *in vitro* anti-inflammatory activity. *Nutr Res* 2010;30:650-659.
- 37 Al-Waili NS: Identification of nitric oxide metabolites in various honeys: effects of intravenous honey on plasma and urinary nitric oxide metabolites concentrations. *J Med Food* 2003;6:359-364.
- 38 Al-Waili NS, Boni NS: Natural honey lowers plasma prostaglandin concentrations in normal individuals. *J Med Food* 2003;6:129-133.
- 39 Al-Waili NS: Effects of daily consumption of honey solution on hematological indices and blood levels of minerals and enzymes in normal individuals. *J Med Food* 2003;6:135-140.