

# The ideal aesthetic nasal dorsum in the Saudi population

Sami E. Albharethy, SB.

## ABSTRACT

**الأهداف:** معرفة مستوى ارتفاع الأنف جانبياً الذي يرى السعوديون والسعوديات بأنه الأكثر جمالاً.

**الطريقة:** أجريت دراسة ملاحظة خلال الفترة من يناير حتى ديسمبر 2012م في قسم أمراض الأنف والأذن والحنجرة، جراحة الرأس والعنق، مستشفى الملك عبدالعزيز، جامعة الملك سعود، الرياض، المملكة العربية السعودية. تم تعديل صور شخصين (ذكر وأنثى) باستخدام برنامج الفوتوشوب للحصول على 5 مستويات من الارتفاع لمنظر الأنف الجانبي. ثم عرضت الصور على 127 شخصاً منهم 56 ذكراً و 71 امرأة للقيام باختيار أي صورة يرى الشخص بأنها الأجمل لدى الرجل والمرأة.

**النتائج:** فضل أغلبية المصوتون من الرجال (57.1%) صورة الرجل بمستوى ارتفاع للأنف متراجع قليلاً، بينما فضلوا (58.9%) صورة السيدة بمنظر جانبي مستقيم تماماً. أما بالنسبة للمصوتات من النساء فالأكثرية (71.8%) كانت مع أنف متراجع قليلاً لدى الرجال بنسبة متساوية بين متراجع قليلاً أو مستقيماً عند نظيراتهم من الإناث (47.9%).

**خاتمة:** يفضل الرجال أنف متراجع قليلاً لدى الرجال ومستقيم تماماً لدى النساء بينما تفضل النساء أنف متراجع قليلاً لدى الذكور ومتراجع قليلاً أو مستقيم لدى الإناث.

**Objectives:** To investigate and define the ideal aesthetic nasal dorsum measurement in the Saudi population.

**Methods:** This observational study was conducted from January to December 2012 at the Department of Otolaryngology, Head and Neck Surgery, King Abdulaziz University Hospital, King Saud University, Riyadh, Kingdom of Saudi Arabia. A total of 127 raters, 56 males and 71 females were asked to choose the most ideal profile view from one male and one female photograph, whose nasolabial angle were fixed at 90 degrees for the male, and 95 degrees for the female, and whose level of dorsum was modified with a Photoshop program into 5 variables in relation to a line drawn from the radix to the tip-

defining points (anterior of more than 2 mm anterior within 2 mm, at the level of the line, posterior within 2 mm, and posterior of more than 2 mm).

**Results:** Male raters preferred the dorsal level slightly posterior within 2 mm (57.1%) for the male photograph, and a straight dorsum (58.9%) for the female photograph. For female raters, the slightly concave profile of less than 2 mm was the most preferred (71.8%) in males, while for females they gave an equal score for either straight dorsum or posteriorly within 2 mm (47.9%).

**Conclusion:** The findings in this study conclude that males preferred a male of a slight deep dorsum, and a female of a straight profile line. Females preferred the male of slight deep dorsum and a female of a straight profile, or slight concavity.

*Saudi Med J 2013; Vol. 34 (9): 920-922*

*From the Department of Otolaryngology, Head and Neck Surgery, King Abdulaziz University Hospital, King Saud University, Riyadh, Kingdom of Saudi Arabia.*

*Received 29th May 2013. Accepted 29th July 2013.*

*Address correspondence and reprint request to: Asst. Prof. Sami E. Albharethy, Department of Otolaryngology, Head and Neck Surgery, King Abdulaziz University Hospital, Riyadh, Kingdom of Saudi Arabia. Tel. +966 (11) 4786100. Fax. +966 (11) 4775791. E-mail: Samiharthi@gmail.com*

The nasal dorsum is one of the key measures for evaluation and aesthetic management of the nose. It is analyzed by drawing a line from the radix to the tip-defining points. Almost all facial plastic aesthetic standards are for Anglo-American population. However, these beauty measures may vary across cultures. In reviewing the literature, for women, the ideal aesthetic nasal dorsum should lie approximately 2 mm behind and parallel to this line, and in men, it should approach this line.<sup>1,2</sup> The nasal bones, dorsal septum, and upper lateral cartilages provide the framework for this region.

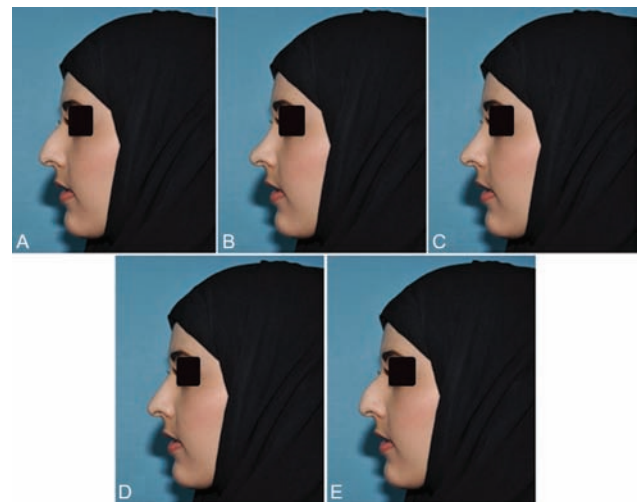
When this area is altered with rhinoplasty, the resulting dorsum may affect the overall harmony of the nose. A large percentage of patients seeking rhinoplasty in the Middle East have wide high dorsum with thick skin envelope requiring surgery at this region, and special attention is given to the degree of reduction, or less commonly augmentation, being sometimes one of the major patient concerns. The purpose of this study was to define the ideal aesthetic nasal dorsum in a Saudi population, and how both genders observe it most beautiful for each, to help surgeons operating on the nose to better understand the beautiful face desired, and improve the surgical outcomes in the Saudi population.

**Methods.** This study was conducted from January to December 2012 at the Department of Otolaryngology, Head and Neck Surgery, King Abdulaziz University Hospital, King Saud University, Riyadh, Kingdom of Saudi Arabia. A left-sided profile face photograph of one male and one female were chosen. A written consent was obtained for using the images from both persons. An Institutional Review Board (IRB) approval was obtained for this study. Nasolabial angle (which is the angle between a line drawn intersecting sub-nasale and perpendicular to the Frankfurt horizontal line and another line drawn through the midpoint of the nostril aperture) were fixed at 90 degrees for the male, and 95 degrees for the female, the level of nasal dorsum was modified with Photoshop program into 5 variables in relation to a line drawn from the radix to the tip-defining points (anterior of more than 2 millimeter (mm) anterior within 2 mm, at the level of the line, posterior within 2 mm and posterior of more than 2 mm (Figure 1 & Figure 2). A total of 127 raters (56 males, and 71 females) with a mean age of  $21.84 \pm 1.2$  years (males:  $22.3 \pm 0.6$ ; females:  $21.5 \pm 1.4$ ) were shown the slides, and were asked the following question: "Knowing that these images have the difference at the nasal dorsal height only, which level do you think is most beautiful?" Data analysis was carried out using the distribution of means.

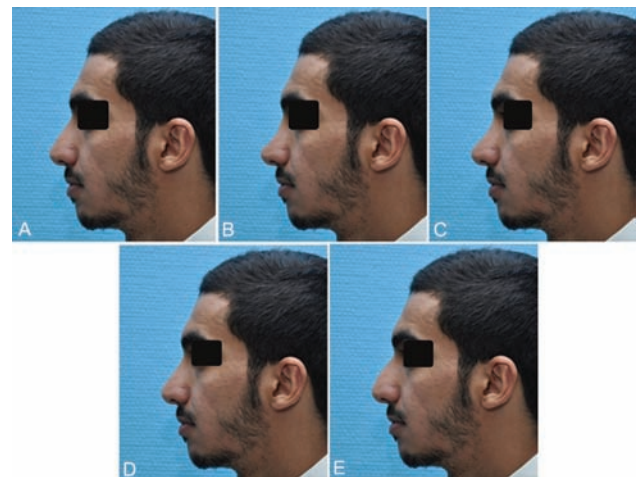**Results.** Male raters preferred the dorsal level slightly posterior within 2 mm (32 raters [57.1%] for the male photograph, and a straight dorsum (33 raters

[58.9%] for the female photograph (Table 1 & Table 2). For female raters the slightly concave profile of less than 2 mm was the most preferred in males (51 female raters [71.8%]), while for females they gave an equal score, between either straight dorsum or posteriorly within 2 mm (34 raters for each dorsal heights [47.9%]).

**Discussion.** There is no universally ideal nose and the degree of nasal dorsal height has a significant effect on facial harmony, balance and beauty. The described nasal dorsal height in the literature is mainly based on studies carried out on population away from the Middle



**Figure 1** - A profile photograph of a female with 5 different nasal dorsal levels: A) convex within 2 mm; B) concave >2 mm; C) concave within 2 mm; D) straight; E) convex >2 mm.



**Figure 2** - A profile photograph of a male with 5 different nasal dorsal levels: A) convex within 2 mm; B) concave >2 mm; C) concave within 2 mm; D) straight; E) convex >2 mm.

**Disclosure.** Author have no conflict of interests, and the work was not supported or funded by any drug company.

**Table 1 -** Female profile photo rating in a study conducted at the Department of Otolaryngology, Head and Neck Surgery, King Abdulaziz University Hospital, Riyadh, Kingdom of Saudi Arabia.

Picture	Male raters	Female raters n (%)	Total
A	2 (3.5)	1 (1.4)	3 (2.3)
B	1 (1.8)	0 (0.0)	1 (0.8)
C	14 (25.0)	34 (47.9)	48 (37.8)
D	33 (58.9)	34 (47.9)	67 (52.8)
E	6 (10.7)	2 (2.8)	10 (7.8)
<b>Total</b>	<b>56</b>	<b>71</b>	<b>127</b>

A - convex within 2 mm, B - concave >2 mm, C - concave within 2 mm,  
D - straight, E - convex >2 mm

**Table 2 -** Male profile photo rating in a study conducted at the Department of Otolaryngology, Head and Neck Surgery, King Abdulaziz University Hospital, Riyadh, Kingdom of Saudi Arabia.

Picture	Male raters	Female raters n (%)	Total
A	2 (3.6)	5 (7.0)	7 (5.5)
B	15 (26.8)	9 (12.7)	24 (18.9)
C	32 (57.1)	51 (71.8)	83 (65.4)
D	6 (10.7)	6 (8.5)	12 (9.4)
E	1 (1.8)	0 (0.0)	1 (0.8)
<b>Total</b>	<b>56</b>	<b>71</b>	<b>127</b>

A - convex within 2 mm, B - concave >2 mm, C - concave within 2 mm,  
D - straight, E - convex >2 mm

East region. The level of the nasal dorsum is described in relation to a line drawn from the radix to the tip-defining points.<sup>1-3</sup> The measurements of the "ideal" nose found in the literature and textbooks, are not necessarily accepted in all cultures, and patients satisfaction is not guaranteed by following these measures. Broer et al<sup>3</sup> showed that there exists major differences in aesthetic perception among plastic surgeons and the general public depending on their gender, age, country of origin, and ethnic background.

Although plastic surgeons approach the aesthetic evaluation of the nose with the help of a universal, seemingly objective measurements, the overall impression depends largely on the individual's judgment.<sup>4-6</sup> The presence of this convexity in male noses was repeatedly reported as a masculine feature.<sup>3-5</sup> Common features of a Saudi nose include thick skin high dorsum with cartilaginous and bony humps, bulbous nasal tip, nostril asymmetry, decreased nasal tip rotation, and with a droopy nasal tip. The surgical techniques which are often required to address these

deformities include hump reduction, osteotomies, soft tissue defatting, and tip work involving suturing and grafting. Common postoperative complications are related to asymmetric soft-tissue scarring, dorsal irregularities, and polybeak deformity.<sup>7-9</sup> The challenging goal on performing rhinoplasty on Middle Eastern patients is to achieve a balanced smooth nasal dorsum, and a harmony of the nose in relation to the rest of the face, preserving the ethnic trait. Rhinoplasty goals and techniques of a Middle Eastern nose can be different from those for other cultures.<sup>8</sup> In this article, the young population view in Saudi Arabia on the aesthetic nasal dorsal height is overall similar to what was described in the literature, except that the nasal convexity (presence of nasal hump) was not preferred for both males and females and by both males and female raters.

Although this research had achieve its aims, there are limitations and shortcomings. First, these results reflect the young generation view to the ideal dorsal height. Second, the study sample include an average Saudi male and female photographs. However, including more persons photographs may add to the results of the study.

In conclusion, one of the most presenting features in Middle East rhinoplasty patients is the wide high nasal dorsum. Males preferred a male of a slight deep dorsum, and a female of a straight profile line. Females preferred the male of slight deep dorsum and a female of a straight profile or slight concavity.

## References

1. Aufricht G. Rhinoplasty and the face. *Plast Reconstr Surg* 1969; 43: 219-230.
2. Powell N, Humphreys B. Proportions of the aesthetic face. New York: Thieme-Stratton; 1984.
3. Broer PN, Buonocore S, Morillas A, Liu J, Tanna N, Walker M, et al. Nasal aesthetics: A cross-cultural analysis. *Plast Reconstr Surg* 2012; 130: 843-850.
4. Farkas LG, Kolar JC, Munro IR. Geography of the nose: A morphometric study. *Aesthetic Plast Surg* 1986; 10: 191-223.
5. Springer IN, Zernial O, Warnke PH, Wiltfang J, Russo PA, Wolfart S. Nasal shape and gender of the observer: implications for rhinoplasty. *J Craniomaxillofac Surg* 2009; 37: 3-7.
6. Leong SC, White PS. A comparison of aesthetic proportions between the healthy Caucasian nose and the aesthetic ideal. *J Plast Reconstr Aesthet Surg* 2006; 59: 248-252.
7. Rohrich RJ, Ghavami A. Rhinoplasty for Middle Eastern noses. *Plast Reconstr Surg* 2009; 123: 1343-1354.
8. Azizzadeh B, Mashkevich G. Middle Eastern rhinoplasty. *Facial Plast Surg Clin North Am* 2010; 18: 201-206.
9. Romo T 3rd, Abraham MT. The ethnic nose. *Facial Plast Surg* 2003; 19: 269-278.