Check for updates

Received: 8 November 2020 | Revised: 20 January 2021 | Accepted: 23 January 2021

DOI: 10.1111/cge.13932

SHORT REPORT

CLINICAL GENETICS WILEY

Hematological findings associated with tubulin-folding cofactors D-related encephalopathy: Expanding the phenotype

Albandary Al-Bakheet[1] | Mohamed Tohary[2] | Sameena Khan[3] | Aziza Chedrawi[3] | Alaa Edrees[2] | Ehab Tous[3] | Hamoud Al-Mousa[4] | Lefian Al-Otaibi[5] | Saif AlShahrani[2] | Maysoon Alsagob[1] | Laila Al-Quait[1] | Rawan Almass[1] | Haya Al-Joudi[3] | Dorota Monies[1] | Abdulaziz Al-Semari[3] | Mazhor Aldosary[1] | Maha Daghestani[6] | Dilek Colak[7] | Namik Kaya[1,8] | Mohammed Al-Owain[2,9]

[1]Department of Genetics, King Faisal Specialist Hospital and Research Center, Riyadh, Saudi Arabia

[2]Department of Medical Genetics, King Faisal Specialist Hospital and Research Center, Riyadh, Saudi Arabia

[3]Department of Neurosciences, King Faisal Specialist Hospital and Research Center, Riyadh, Saudi Arabia

[4]Department of Pediatrics, King Faisal Specialist Hospital and Research Center, Riyadh, Saudi Arabia

[5]Department of Radiology, King Faisal Specialist Hospital and Research Center, Riyadh, Saudi Arabia

[6]Division of Genetics, Zoology Department, College of Science, King Saud University, Riyadh, Saudi Arabia

[7]Department of Biostatistics, Epidemiology and Scientific Computing, King Faisal Specialist Hospital and Research Center, Riyadh, Saudi Arabia

[8]Department of Translational Genomics, Center for Genomic Medicine, King Faisal Specialist Hospital and Research Center, Riyadh, Saudi Arabia

[9]College of Medicine, Alfaisal University, Riyadh, Saudi Arabia

Correspondence
Mohammed Al-Owain, MBC:75, Department of Medical Genetics, King Faisal Specialist Hospital and Research Center, Riyadh, Saudi Arabia.
Email: alowain@kfshrc.edu.sa

Abstract

The dysfunction of microtubules (α/β-tubulin polymers) underlies a wide range of nervous system genetic abnormalities. Defects in TBCD, a tubulin-folding cofactor, cause diseases highlighted with early-onset encephalopathy with or without neurodegeneration, intellectual disability, seizures, microcephaly and tetraparaperesis. Utilizing various molecular methods, we describe nine patients from four unrelated families with two novel exon 18 variants in *TBCD* exhibiting the typical neurological phenotype of the disease. Interestingly, all the investigated patients had previously unreported hematological findings in the form of neutropenia and mild degree of anemia and thrombocytopenia. In addition to delineating the neurological phenotype in several patients with *TBCD* variants, our study stresses on the new association of neutropenia, in particular, with the disease.

KEYWORDS

corpus callosum, hematological findings, neurodegenerative disease, neutropenia, *TBCD*

Abbreviation: ANC, absolute neutrophil count; CBC, complete blood count; CBCD, complete blood count with automated differential; cm, centimeter; CNS, central nervous system; EEG, electroencephalogram; Kg, kilogram; IQ, intelligence quotient; MRI, magnetic resonance imaging; OFC, occipitofrontal circumference; PEBAT, brain atrophy and thin corpus callosum; SD, standard deviation; SNP, single nucleotide polymorphism; TBCD, tubulin-folding cofactors D; WBC, white blood cell; WES, whole exome sequencing.

 © 2021 John Wiley & Sons A/S. Published by John Wiley & Sons Ltd

Namik Kaya, Department of Genetics, KFSHRC, Riyadh, Saudi Arabia.
Email: nkaya@kfshrc.edu.sa

Funding information
King Abdulaziz City for Science and Technology, Grant/Award Number: 11-BIO2221-20

1 | INTRODUCTION

The cytoskeleton, an interconnected network of filamentous polymers and regulatory proteins, consists of three main elements: the microtubules (polymers of α/β-tubulin), actin filaments, and intermediate filaments. The microtubules heavily participate in wide variety of important cellular functions including neuronal development, signal transduction, cell morphology and polarity.[1] Among the five tubulin-folding cofactors (TBCA, B, C, D, and E), mutations in *TBCD* and *TBCE* have been linked to human disorders (OMIM: 604649 and OMIM: 604934, respectively).[2] In addition, mutations in the genes encoding various tubulin isoforms (TUBA1A, TUBA8, TUBB2A, TUBB2B, TUBB, TUBB3, and TUBG1), commonly referred as tubulinopathies, have been implicated in abnormal neuronal proliferation, migration, and postmigrational development.[3] Defects in *TBCD* has been shown to lead to early onset "progressive encephalopathy with brain atrophy and thin corpus callosum" (PEBAT), dystonia, seizures, nystagmus, microcephaly and spasticity.[4-11] Evidently, from previous reports, TBCD dysfunction causes primarily a neurological phenotype. With tremendous progress in the genetic basis of rare neurogenetic disorders, involvement of other body functions has become apparent as more patients are described. Here, we describe nine patients from four unrelated families with *TBCD*-related encephalopathy caused by novel missense mutations. The patients presented with the typical neurological phenotype, in addition to hematological involvement with prominent neutropenia, mild anemia and thrombocytopenia, as seen in many of the affected individuals. Such features have not been previously described in patients with *TBCD* mutations.

2 | MATERIALS AND METHODS

Four unrelated Saudi families were recruited to the study (KFSHRC, RAC# 2120022). Except for the Family-B, all families were consanguineous (Figure 1(A)). The families belong to different regions in the Kingdom and have no known tribal connections. To perform whole-exome sequencing (WES), library preparation was achieved using AmpliSeq™ Exome RDY (Life Technologies, Carlsbad, CA, USA). The sequencing was performed on the Ion Proton™ System (Life Technologies), using Ion PI™ Sequencing 200 Kit v3 with the Ion PI™ Chip Kit v2 (Life Technologies). WES data was filtered and the candidate variants were confirmed by Sanger Sequencing.[12,13] Variants were tested for potential pathogenicity using various prediction algorithms tools.[14]

3 | RESULTS

3.1 | Family A, patient 1

This boy was born to a consanguineous couple after a full term normal pregnancy via vaginal delivery. The family has no history of a similar condition. The parents noted that he was not acquiring milestones on time. He developed seizures at 9 months of age, with a semiology of "staring and uprolling of the eyes". He was started on sodium valproate and switched to levetiracetam later with good control. Few months later, he was found to have leukopenia and thrombocytopenia. He was referred to our institution at age of 16 months to rule out leukemia. On examination, he appeared pale with good eye contact and nondysmorphic, weight was 9 kilogram (kg) (− 2.2 Standard Deviation [SD]), height was 75 cm (− 1.5 SD), occipitofrontal circumference (OFC) was 44 cm (centimeter) (− 3 SD). Chest, cardiovascular and abdominal examination was normal and no lymphadenopathy was noted. Central nervous system (CNS) examination revealed normal cranial nerves. He had spasticity in both upper and lower limbs with normal power. Deep tendon reflexes were increased in all extremities (3/4). Hematological findings are provided in the "Results" section. Immunological evaluation showed normal immunoglobulin levels, surface markers, and blastogenesis. Diepoxybutane-based chromosomal analysis did not result in increased chromosome breakage, particularly radial formations, as compared to the control. Single nucleotide polymorphism (SNP) array was normal. Electroencephalogram (EEG) showed bilateral occasional frontal independent epileptiform discharges and bilateral frontal slow activity. Auditory Brainstem Response were normal bilaterally. Ophthalmological examination was normal. At the age of 46 months, formal neuropsychological assessment revealed mild to moderate delay in cognitive function. Fine motor skills were borderline, which was an area of strength, but the gross motor function was severely delayed. Social function remained immature for his age. Overall, his neurodevelopmental function was around 18-month level.

3.2 | Family B, patient 2

This girl was born after a full-term, uncomplicated pregnancy, via normal spontaneous delivery to a nonconsanguineous couple. Seizures developed at 7 months of age and she was diagnosed with progressive myoclonic epilepsy, controlled by sodium valproate. Her EEG showed generalized spikes/polyspikes. She had significant

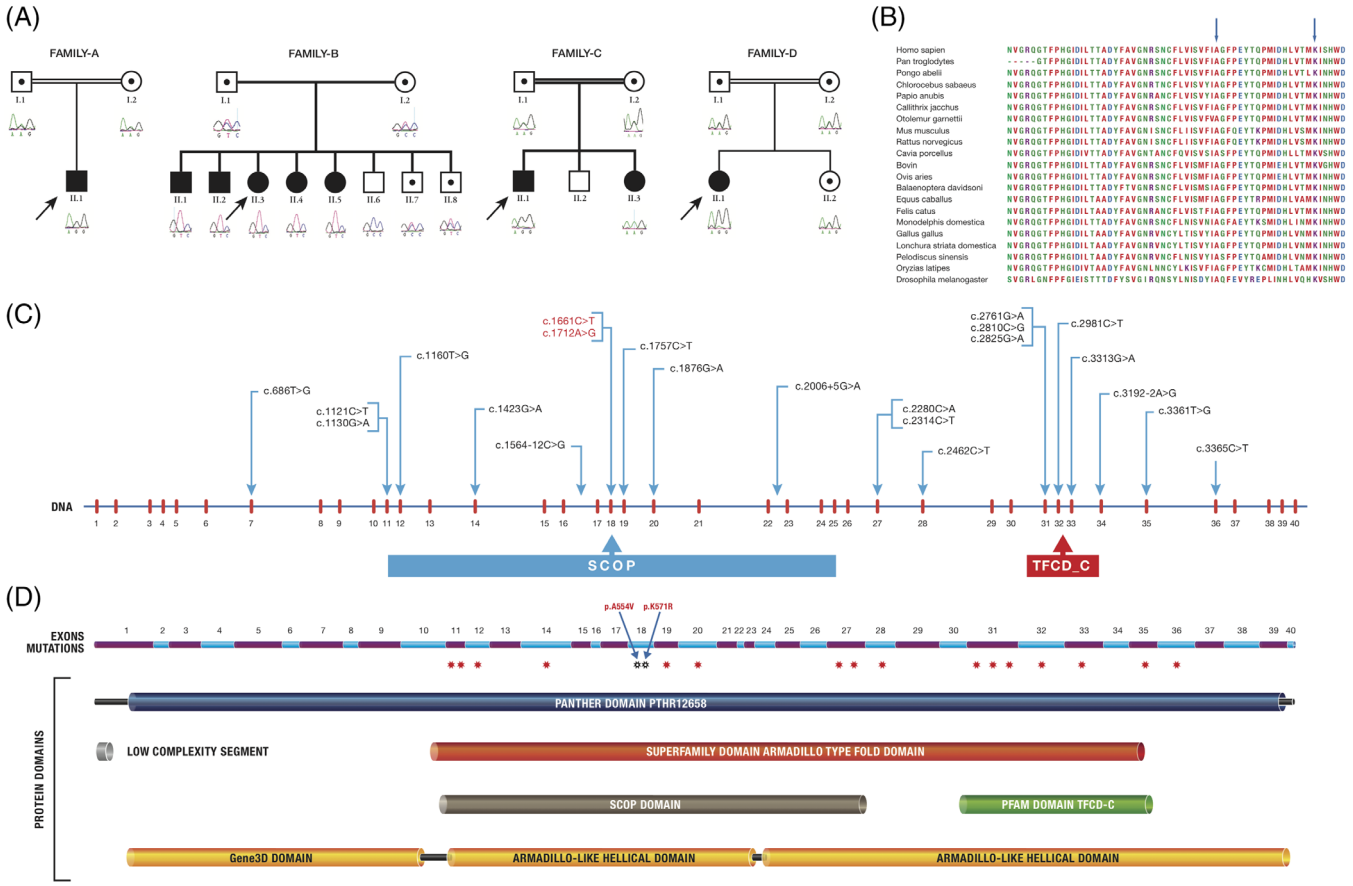

FIGURE 1 Genetic Analyses of the Families. (A) Pedigree shows four families and brief chromatograms of *TBCD* for the tested individuals. (The black arrow indicates the probands. The affected individuals are represented by filled symbols while the carriers are in dotted forms). (B) The figure shows aligned amino acids from different species for both mutation sites (pointed by blue arrow). (C) The schematic drawing of the *TBCD*. The drawing contains two panels (top and bottom). The top panel presents harbored mutations on exons indicated by blue arrows. The two novel mutations are located on exon 18 and written in red fonts. SCOP and TFCD domains are in the bottom. (D) This figure displays exons in different colors in upper panel. Red stars are displaying known mutations whereas gray stars points novel Saudi mutations identified in this study. The lower panel presents all domains adopted from Ensembl [Colour figure can be viewed at wileyonlinelibrary.com]

delays in virtually all neurodevelopmental domains. She sat around 7 months and walked at 16 months. Speech and language skills were significantly delayed, as well as her fine motor skills. Formal neuropsychological assessment at the age of 12 years revealed that she was able to speak only few intelligible words with the gross motor function and activities of daily living were her most developed abilities, as she was fully independent in ambulating, transferring, feeding, and, to a great extent, toileting. Her Intelligence Quotient (IQ) was not obtained formally due to difficulty understanding concepts, but it was estimated to be 39–50, which places her in the moderate to severe mental delay; she mainly functions at the 3 year-level. On examination at 12 years of age, she had normal weight and height growth parameters. The OFC was small 50.5 cm (−2 SD). She was noncommunicating and appeared nondysmorphic. She had normal lung, cardiac, abdominal examination, skin, and CNS examination. Patients,[3-6] sibs of patient 2, have similar phenotype and their clinical findings are summarized in Table 1.

3.3 | Family C, patient 7

This boy was a product of full term uneventful pregnancy and delivery. He was the first child of this consanguineous couple. Family history revealed that the father had pubertal onset epilepsy and was on treatment (lamotrigine and sodium valproate). Patient was noted to have delayed motor milestones. He was able to pronounce "baba" and "mama" at the age of 2 years. He never attained independent sitting or walking and by age of 3–4 years, he was wheelchair-bound and developed quadreparesis. He developed generalized tonic clonic seizures at age of 1 year. Subsequently, his seizures semiology was facial twitching, eye deviation to the left, right upper and lower limb myoclonic movements, associated sometimes with generalized tonic clonic seizures. He had good response to sodium valproate. EEG showed mild degree of encephalopathy with left hemispheric epileptic activity with tendency for secondary generalization. No history of recurrent infections was noted. On examination at 7 years of age, weight was 15.5 kg (−4.3 SD), length was 112 cm (−2.6 SD), and OFC was 49 cm (− 2 SD). He had normal chest,

TABLE 1 Clinical and molecular findings of all the patients in this study

	Family A	Family B					Family C		Family D
	Patient 1	Patient 2	Patient 3	Patient 4	Patient 5	Patient 6	Patient 7	Patient 8	Patient 9
Age (Years)	5	12	7	20	29	25	8	1.8	7
Onset of Seizures (Months)	9	7	18	10	15	48	12	None	16
Onset of Regression (Months)	9	13	15	10	15	18	18	NA	9
Speech Delay	Yes	Yes	Yes	Yes	Yes	Yes	Yes	Yes	Yes
Intellectual Disability	Yes	Yes	Yes	Yes	Yes	Yes	Yes	NA	Yes
Ocular findings	Normal	Normal	NA	NA	NA	NA	Mild hyperopic astigmatism with bilateral temporal pallor of the optic discs.	NA	Pale optic discs
Microcephaly	Yes	Yes	Yes	NA	NA	NA	Yes	NA	Yes
Dysmorphic feature	None	None	None	NA	NA	NA	None	NA	None
Skin manifestation	Normal	Normal	Normal	NA	NA	NA	Normal	NA	Normal
WBC $\times 10^9$/L (3.90–11)	1.9–3.3	3.1–5.27	5.42–6.5	5.77	NA	NA	6.50–9	10.89	2–8
Hemoglobin (135–18 g/L)	95–100	95–141	120	123	NA	NA	110–135	12.8	107–149
MCV (68–95 fl)	74–79	67–85	82–88	83	NA	NA	70–77	78	79–87
MCH (24–31 pg)	25.7–27.4	29.6–34	27.8–29.5	28.7	NA	NA	23.8–24.9	25	27.6–29.2
Platelet (155–435 $\times 10^9$/L)	56–123	69–250	185–220	238	NA	NA	105–200	321	41–171
Neutrophil (30–70%)	13–23	6–23	16–18	25	NA	NA	3–22	6	5–8
ANC (1500–7500)	390–670 (6)[a]	210–1040[6a]	960 (1)[a]	1470 [1a]	NA	NA	400-1430[3a]	650 (1)[a]	400-666 (2)
EEG	Abnormal	Abnormal	Abnormal	Abnormal	NA	Abnormal	Abnormal	NA	Abnormal
MRI Brain	Abnormal	Abnormal	Abnormal	Normal	NA	Abnormal	Abnormal	NA	Abnormal
Mutation	c.1712A > G p.K571R	c.1661C > T p.A554V					c.1712A > G p.K571R	c.1712A > G p.K571R	c.1712A > G p.K571R

Abbreviations: ANC, absolute neutrophil count; NA, not available; WBC, white blood cell count.
Note: Reference range is included in the parenthesis for the laboratory findings.
[a]Represents how many times the test repeated.

cardiovascular, abdominal, and skin examination. CNS examination showed normal cranial nerves. The power was reduced in all extremities, more pronounced in lower limbs consistent with spastic diplegia. There was generalized hypertonia and hypereflexia in all limbs associated with clonus, with a positive Babinski. Ophthalmological examination showed mild hyperopic astigmatism, with bilateral temporal pallor of the optic discs. The immunoglobulins and lymphocyte markers were normal. SNP array was normal. The boy has an affected 21-month-old sister (patient 8) whose diagnosis was confirmed molecularly, but, she was not available for the full clinical evaluation. She was a product of full term pregnancy and noted by the family to have motor delay (now only able to sit but cannot stand/walk) and speech delay. There is no history of seizures.

3.4 | Family D, Patient 9

This girl was a product of full term uneventful pregnancy and delivery to consanguineous couple with negative family history. Parents noted developmental delay, with motor milestones by the end of the first year of life. She had Lower limb spasticity that resulted in bilateral hip subluxations. Patient developed myoclonic seizures at 16 months of age, associated with generalized tonic clonic seizures. EEG showed epileptiform discharges with tendency for secondary generalization. She had a good response to phenobarbital, and then switched to levetiracetam. Patient had global developmental delay. On examination at age of 7 years, she was nondysmorphic. Weight was 14 kg (− 4.3 SD), length was 106 cm (− 3.1 SD) and OFC was 45.5 cm (− 4 SD). CNS examination showed reduced power with generalized increased tone and deep tendon reflexes, more pronounced in lower extremities consistent with spastic diplegia. Ophthalmological examination showed pale optic discs. In addition to the immunoglobulins, and lymphocyte markers, SNP array was also normal.

3.5 | Hematological findings

Initial CBC of patient 1 showed leukopenia, normocytic normochromic anemia, and thrombocytopenia (Table 1). He had moderate to severe neutropenia on multiple occasions. The reticulocyte count was 1.21–1.66%. Erythrocyte sedimentation rate was 5–8 (0–15 mm/hr). Direct coombs and antinuclear antibody titer were negative. Despite multiple attempts, anti-neutrophil antibodies could not be performed since the neutrophil percentage did not reach >20% of the WBC. Flow cytometry done on the bone marrow aspirate detected around 14% in blast gate that were most likely hematogon and no evidence of myeloid leukemia was seen. Bone marrow biopsy revealed normocellular marrow (90% to 95%) with active trilineage hematopoiesis and no immunomorphological evidence of leukemia. The apparently healthy mother had slightly reduced WBC of 3.8 (normal range $3.9–11 \times 10^9$) and normal absolute neutrophil count (ANC) of 1520, normal hemoglobin of 13.9 g/dl, and platelet count of 235.

Hematological parameters are available for three members of the family B (patients 2, 3 and 4). Patient 2's WBC and platelets counts, and hemoglobin were ranging from normal to mildly reduced on several readings. Patients 3 and 4 had mild normocytic normochromic anemia but with normal WBC and platelet counts. Neutropenia of variable severity was observed in all these three patients. We attempted to obtain CBC parental studies, but only maternal studies were available and were completely normal.

Both patients 7 and 8 (family C) had normocytic normochromic anemia and neutropenia, but with normal WBC. The platelet count was variably reduced in patient 7 but normal in patient 8. Parental complete blood count and differential were obtained and were completely normal.

WBC and platelets counts, and hemoglobin of patient 9 ranged from normal to mildly decreased. Moderate to severe neutropenia was seen on two occasions. Parental CBC studies were not available.

All the available hematological findings for the patients and the parents are shown in Table 1 and Table S3, respectively.

3.6 | Neuroradiological evaluation

Brain magnetic resonance imaging (MRI, Figure 2) showed confluent periventricular hyperintensity in patient 1 with significant delayed myelination of the white matter and moderately thin corpus callosum. The MRI of patient 2 revealed mild diffuse, symmetric hyperintensity predominantly periventricular within the white matter, in the occipital and frontal regions, representing delay in myelination. There was also thinning of the corpus callosum. The patient 3's MRI showed mild callosal thinning and cortical atrophy, along with mild white matter periventricular hyperintesities. Patient 4 had unremarkable brain MRI, and the study was not available for patient 5. Supratentorially, the MRI on patient 6 showed mild atrophy, and the corpus callosum was rather prominently atrophic, it was however fully myelinated. Within the cerebral hemispheres there was diffuse mild volume loss of the white matter, in conjunction with very faint and ill-defined hyperintensities on the T2 weighted images in the frontal and the parietal regions (not shown in Figure 2). Brain MRI of patient 7 revealed significantly delayed myelination with hypoplastic corpus callosum and cerebellar vermis. No MRI was available for patient 8. The study showed significantly delayed myelination in patient 9 (Not shown in Figure 2).

3.7 | In silico analysis

We performed filtering steps on the WES as described previously.[12,13,15-17] The analysis yielded a single most plausible candidate, a homozygous missense variant in *TBCD* (NM_005993.5: c.1712A > G, p.K571R) in family A. Sanger sequencing confirmed complete segregation of the variant within the family (Figure 1(A)). Interestingly, this variant had previously been annotated in ExAC at heterozygous state (1/249268); but was completely absent in 2379

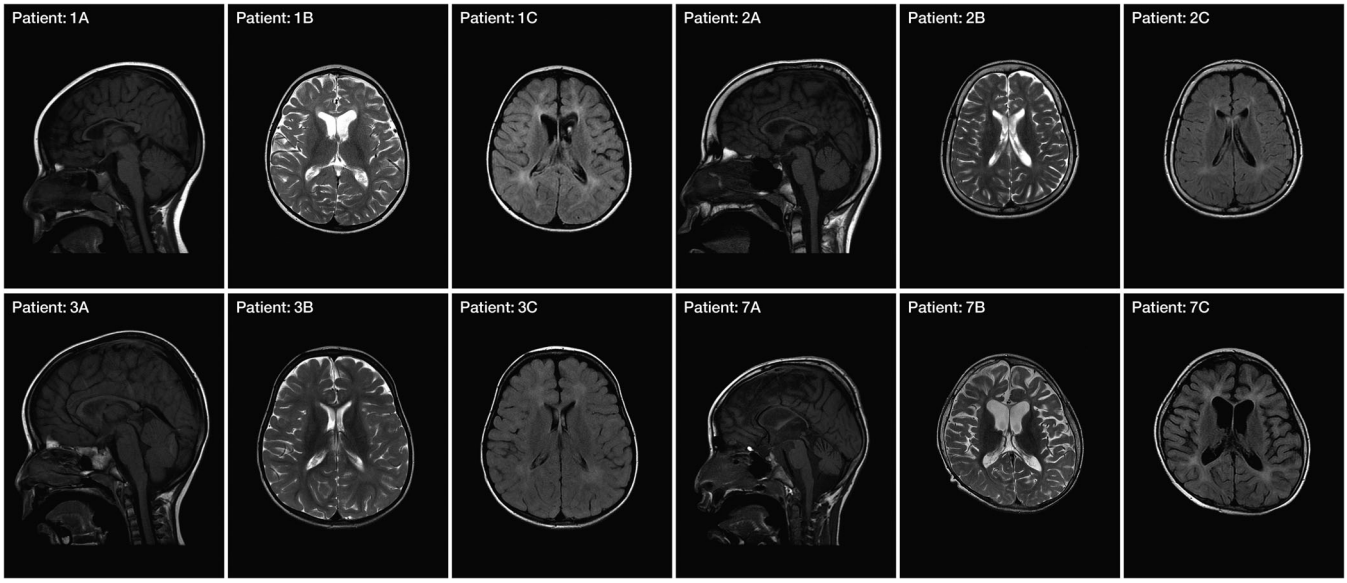

FIGURE 2 MRI images of selected patients. Brain MRIs of patients with *TBCD* mutations. Patient 1: Sagittal T1 MR image (1A), showing moderate thinning/hypoplasia of the corpus callosum body. Axial T2 MR image (1B), showing mild prominence of the lateral ventricles and cerebral sulci compatible with central volume loss and cortical atrophy. Axial FLAIR image (1C), showing confluent periventricular FLAIR white matter hyper intensities and hypo myelination. Patient 2: Sagittal T1 MR image (2A), showing mild thinning/hypoplasia of the corpus callosum body. Axial T2 Image (2B), showing mild widening of the cerebral sulci compatible with mild cortical atrophy. Axial FLAIR image (2C), showing mild peritrigonal periventricular FLAIR hyper intensities and hypo myelination. Patient 3: Sagittal T1 MR image (3A) showing minimal thinning of the corpus callosum body. Axial T2 image (3B), showing mild prominence of the cerebral sulci /cortical atrophy. Axial FLAIR image (3C), showing minimal anterior and posterior periventricular FLAIR hyper intensities and hypo myelination. Patient 7: Sagittal T1 image (7A), showing markedly thin /hypoplastic corpus callosum, moderately hypolastic cerebellar vermis. Axial T2 image (7B), showing moderate prominence of the lateral ventricles and cerebral sulci compatible with moderate central volume loss and cortical atrophy. Axial FLAIR image (7C), showing confluent moderate periventricular white matter FLAIR hyper intensities and hypo myelination

in-house Saudi exomes and 1000 Genomes. Moreover, the variant was predicted to be pathogenic by different classifiers such as by MutationTaster (Score: 26), PolyPhen2 (0.997, probably damaging), SIFT (0, deleterious), and CADD (PHRED: 24.4).

After utilizing the same genetic approach, WES of the index cases from family C and family D revealed the same variant found in the family A. Interestingly, we identified another novel homozygous missense variant in the index patient in family-B in the same gene (*TBCD*: NM_005993.5: c.1661C > T, p.A554V). Confirmatory Sanger sequencing revealed full segregation of the variant within the family (Figure 1(A)). Similar analysis indicated that p.A554V existed at heterozygous state (4/2379) in our Saudi exome cohort, and was absent in ExAC Browser, Exome Server, and 1000 Genomes. The variant was also predicted to be pathogenic by the same classifiers, Mutation tester (Score: 64), PolyPhen2 (0.997, probably damaging), SIFT (0, deleterious), and CADD (PHRED: 24.4). Furthermore, we performed amino acid alignment for both variants that indicated high conservation of the mutation sites among different species (Figure 1(B)).

4 | DISCUSSION

Biallelic mutations in *TBCD* cause early-onset PEBAT. In this paper, we describe nine patients from four unrelated Saudi families exhibiting the classical *TBCD*-related neurological phenotype. The onset of the neurodevelopmental delay was mostly in the first year of life. All patients had similar neurological findings. Variable degree of brain atrophy and thinning of the corpus callosum was seen in the six patients on whom brain imaging was available. Cerebellar vermian hypoplasia was observed in patient 7. More interestingly, the patients,[1-4,7-9] and had variable degree of hematological involvement with prominent neutropenia, and mild anemia and thrombocytopenia that even led to suspicion of leukemia (patient 1). Bone marrow aspirate and biopsy were only feasible in patient 1 and showed normal trilineage morphology.

Neutropenia is defined as the ANC lower than normal level for age and race. ANC less than 1500, 1000, and 500/μl are termed mild, moderate, and severe neutropenia, respectively. Severe neutropenia predisposes to major pyogenic infections and life-threatening infections. Of note, cytopenia including neutropenia can be drug-induced (e.g., antiepileptic medications with sodium valproate in particular), nutritional deficiencies (e.g., cobalamin and folate), or secondary to infection, autoimmunity, or malignancy.[18] Although neutropenia appears to be a consistent finding in our cohort with the *TBCD* defect, it is not clear whether the use of the antiepileptic medications is pharmacogenomically contributing to the development of neutropenia in our patients. In all patients in this report, the B12 and folate levels were normal. Involvement of other body functions in genetic disorders is not surprising; as broad range of hematological findings has

been observed in many of them. For example, neutropenia is seen in Shwachman-Diamond syndrome, Chediak-Higashi syndrome, Barth syndrome, Wiskott-Aldrich syndrome, glycogen storage disease type Ib, Pearson syndrome, among others.[19]

Beside the severity of neutropenia, other determinants that generally correlate with the risk of life-threatening infections include the duration of neutropenia and the status of the storage pool of the neutrophils in the bone marrow (central versus peripheral neutropenia).[20] In our cohort, the neutropenia was never associated with severe bacterial infections, as the severe neutropenia (ANC < 500) was not persistent, and in the only patient in whom bone marrow biopsy was available, there was normally active granulopoiesis indicating the neutropenia is likely of the peripheral type. In communication with previous authors, the serial readings of hematological tests of one patient of the 5 reported by Pode-Shakked et al (2017) was shared.[10] He had mild anemia (11.4–12.1 g/dl, intermittent borderline ANC (1500) and intermittent thrombocytopenia (30 000, 108 000). Evardson S. et al (2016), who reported four patients, did not observe abnormal hematological findings in his cohort, although no data was shared.[4]

To date, 24 different pathogenic *TBCD* variants and 28 patients have been reported in the literature (Supplementary Table 1 and 2). The onset of the disease ranges from birth up to 3 years of age. Interestingly, among the patients reported, neutropenia and thrombocytopenia have not been observed. The p.A554V was identified only in the family B whereas the other variant (p.K571R) was detected in the remaining families. Three families that harbor the same missense variant have completely different tribal affiliations. The in silico pathogenicity analysis revealed that both variants are pathogenic. Strikingly, the first variant (p.A554V) has led to less severe neurological phenotype unlike the other affected individuals with p.K571R from other families in which all patients had severe phenotype. Interestingly, both variants are located on exon 18 of the gene containing a large SCOP domain (Figure 1(C)). Reviewing the reported mutations revealed that 10 variants are found on this domain (Figure 1(C)).

As our patients harbored the exon 18 mutations, the hematological findings may represent a form of genotype–phenotype correlation. Although, some insightful research has emerged on the role of microtubules in neutrophil polarity and migration in vertebrates,[21] it remains intriguing how the *TBCD* genetic defect in our patients cause the decreased blood counts. This may reflect the high demand of *TBCD* during hematopoiesis. In a functionally related cytoskeletal gene, *WASP*, the gene regulates actin cytoskeleton-dependent cellular processes. Its defect causes Wiskott-Aldrich syndrome, which is characterized by immune deficiency, microthrombocytopenia, eczema and lymphoid malignancies. Remarkably, constitutively activating mutation in *WASP* have been described to give rise to X-linked neutropenia.[22] Moreover, many chemotherapeutic agents have been developed that primarily target the microtubule. Vinca alkaloids are thought to act by binding to β-tubulin and inhibiting polymerization into microtubules. Myelosuppression is one of their main side effects. Newer microtubule targeting agents, for example, eribulin mesylate, inhibits microtubule growth and thus causes sequestration of tubulin. Neutropenia is considered the dose-limiting toxicity.

In conclusion, our study expands phenotypic spectrum of *TBCD* mutations mainly in the form of hematological findings (neutropenia and mild degree of anemia and thrombocytopenia), and for the first time links such findings to the TBCD-associated PEBAT. Moreover, we report two novel mutations that are located on a likely hotspot over SCOP domain.

ACKNOWLEDGEMENTS

We are grateful to the families and to Saudi Genome Project team members, Genetics Core Laboratories, Research Advisory Council Committees, and KFSHRC Purchasing Departments (especially to Mr. Faisal AlOtaibi) for facilitating and expediting our requests. We appreciate continuous support and help that we received from KACST Biotech Team Members at KFSHRC.

CONFLICT OF INTEREST

We have no conflict of interest to disclose.

DATA AVAILABILITY STATEMENT

The data that support the findings of this study are available from the corresponding author upon reasonable request.

ETHICS STATEMENT

Obtained by Institutional Review Board at KFSHRC, Riyadh, Saudi Arabia.

ORCID

Dilek Colak https://orcid.org/0000-0001-6485-8768
Namik Kaya https://orcid.org/0000-0001-8912-7507

REFERENCES

1. Martin L, Fanarraga ML, Aloria K, Zabala JC. Tubulin folding cofactor D is a microtubule destabilizing protein. *FEBS Lett*. 2000;470(1):93-95.
2. Sferra A, Baillat G, Rizza T, et al. TBCE mutations cause early-onset progressive encephalopathy with distal spinal muscular atrophy. *Am J Hum Genet*. 2016;99(4):974-983.
3. Yokoi S, Ishihara N, Miya F, et al. TUBA1A mutation can cause a hydranencephaly-like severe form of cortical dysgenesis. *Sci Rep*. 2015;5:15165.
4. Edvardson S, Tian G, Cullen H, et al. Infantile neurodegenerative disorder associated with mutations in TBCD, an essential gene in the tubulin heterodimer assembly pathway. *Hum Mol Genet*. 2016;25(21):4635-4648.
5. Flex E, Niceta M, Cecchetti S, et al. Biallelic mutations in TBCD, encoding the tubulin folding cofactor D, perturb microtubule dynamics and cause early-onset encephalopathy. *Am J Hum Genet*. 2016;99(4):962-973.
6. Ikeda T, Nakahara A, Nagano R, et al. TBCD may be a causal gene in progressive neurodegenerative encephalopathy with atypical infantile spinal muscular atrophy. *J Hum Genet*. 2017;62(4):473-480.
7. Meng L, Pammi M, Saronwala A, et al. Use of exome sequencing for infants in intensive care units: ascertainment of severe single-gene disorders and effect on medical management. *JAMA Pediatr*. 2017;171(12):e173438.

8. Miyake N, Fukai R, Ohba C, et al. Biallelic TBCD mutations cause early-onset neurodegenerative encephalopathy. *Am J Hum Genet*. 2016;99(4):950-961.
9. Poulton CJ, Schot R, Seufert K, et al. Severe presentation of WDR62 mutation: is there a role for modifying genetic factors? *Am J Med Genet A*. 2014;164A(9):2161-2171.
10. Pode-Shakked B, Barash H, Ziv L, et al. Microcephaly, intractable seizures and developmental delay caused by biallelic variants in TBCD: further delineation of a new chaperone-mediated tubulinopathy. *Clin Genet*. 2017;91(5):725-738.
11. Ghanbari M, Franco OH, de Looper HW, Hofman A, Erkeland SJ, Dehghan A. Genetic variations in MicroRNA-binding sites affect MicroRNA-mediated regulation of several genes associated with cardio-metabolic phenotypes. *Circ Cardiovasc Genet*. 2015;8(3):473-486.
12. AlMuhaizea M, AlMass R, AlHargan A, et al. Truncating mutations in YIF1B cause a progressive encephalopathy with various degrees of mixed movement disorder, microcephaly, and epilepsy. *Acta Neuropathol*. 2020;139(4):791-794.
13. Seidahmed MZ, Hamad MH, AlBakheet A, et al. Ancient founder mutation in RUBCN: a second unrelated family confirms Salih ataxia (SCAR15). *BMC Neurol*. 2020;20(1):207.
14. Al-Hassnan ZN, Al-Dosary M, Alfadhel M, et al. ISCA2 mutation causes infantile neurodegenerative mitochondrial disorder. *J Med Genet*. 2015;52(3):186-194.
15. Chelban V, Alsagob M, Kloth K, et al. Genetic and phenotypic characterization of NKX6-2-related spastic ataxia and hypomyelination. *Eur J Neurol*. 2020;27(2):334-342.
16. Al-Muhaizea MA, AlQuait L, AlRasheed A, et al. Pyrostigmine therapy in a patient with VAMP1-related congenital myasthenic syndrome. *Neuromuscul Disord*. 2020;30(7):611-615.
17. Perenthaler E, Nikoncuk A, Yousefi S, et al. Loss of UGP2 in brain leads to a severe epileptic encephalopathy, emphasizing that bi-allelic isoform-specific start-loss mutations of essential genes can cause genetic diseases. *Acta Neuropathol*. 2020;139(3):415-442.
18. Acharya S, Bussel JB. Hematologic toxicity of sodium valproate. *J Pediatr Hematol Oncol*. 2000;22(1):62-65.
19. Klein C. Genetic defects in severe congenital neutropenia: emerging insights into life and death of human neutrophil granulocytes. *Annu Rev Immunol*. 2011;29:399-413.
20. Donadieu J, Fenneteau O, Beaupain B, Mahlaoui N, Chantelot CB. Congenital neutropenia: diagnosis, molecular bases and patient management. *Orphanet J Rare Dis*. 2011;6:26.
21. Yoo SK, Lam PY, Eichelberg MR, Zasadil L, Bement WM, Huttenlocher A. The role of microtubules in neutrophil polarity and migration in live zebrafish. *J Cell Sci*. 2012;125(Pt 23):5702-5710.
22. Devriendt K, Kim AS, Mathijs G, et al. Constitutively activating mutation in WASP causes X-linked severe congenital neutropenia. *Nat Genet*. 2001;27(3):313-317.

SUPPORTING INFORMATION

Additional supporting information may be found online in the Supporting Information section at the end of this article.

How to cite this article: Al-Bakheet A, Tohary M, Khan S, et al. Hematological findings associated with tubulin-folding cofactors D-related encephalopathy: Expanding the phenotype. *Clinical Genetics*. 2021;1–8. https://doi.org/10.1111/cge.13932