

Nasal packing in cosmetic and functional nasal surgery

Ahmad Al-Arfaj, FKSU, FRCS, Jamil N. Al-Swiabb, MD, SSC-ORL, Sami Al-Harthi, MD, FKSU, Mohammed Al-Essa, MD, FRCS.

ABSTRACT

الأهداف: تقييم الاستخدام الروتيني لحشوات الأنف بعد عمليات الأنف التجميلية.

الطريقة: تم تجميع عينة للدراسة المستقبلية في الفترة ما بين 2005م وحتى 2006م، في مستشفى الملك عبد العزيز الجامعي - الرياض - المملكة العربية السعودية. كان عدد المرضى أربعة وخمسين مريض أجريت لهم عمليات تجميل الحاجز الأنفي، وشكل الأنف الخارجي، وبعض المرضى أجريت لهم عملية كي أو تجميل قرنيات الأنف السفلية. تمت متابعة جدوى ومضاعفات حشوات الأنف بأحجام مختلفة ولفترات زمنية مختلفة.

النتائج: أجريت عملية تجميل الحاجز الأنفي 54 مريض، وعملية تجميل شكل الأنف الخارجي لـ 21 مريضاً، وعملية كي قرنيات الأنف لـ 21 مريضاً، وعملية الكسر الخارجي لقرنيات الأنف السفلية لـ 24 مريضاً. تم عمل حشوة ميروسيل من النوع الرقيق بطول 8cm في سبعة وستين فتحة من فتحات الأنف بعد العملية، وحشوة ميروسيل العادية بطول 8cm في أربعة وعشرين فتحة، وحشوة ميروسيل العادية بطول 10cm في ستة فتحات من فتحات الأنف. وضعت حشوات الأنف لمدة ستة ساعات ثم أزيلت لسبعة وثلاثين مريضاً، كما تم وضع الحشوات لمدة أربعة وعشرين ساعة لسبعة عشر مريضاً. إحدى وأربعين مريض لم يشتكوا من أي إزعاج من حشوات الأنف، بينما ثلاثة عشر مريض كانوا يعانون من عدم ارتياح بسيط إلى متوسط.

خاتمة: يمكن السيطرة على عمليات تجميل الأنف وعمليات تجميل قرنيات الأنف السفلية في أغلب الحالات دون الحاجة إلى استخدام حشوات الأنف أو أي إجراء آخر مرقى للدم.

Objective: To evaluate the routine use of nasal packing after cosmetic and functional nasal surgery.

Methods: Prospective collection from 2005 to 2006 at King Abdulaziz University Hospital in Riyadh for 54 patients post-septorhinoplasty with and without submucous diathermy or lateralization of inferior turbinate were evaluated for efficacy and complications of nasal packing which kept for different duration.

Results: All 54 patients had septoplasty, 21 with rhinoplasty, 12 with SMD, and 24 patients had inferior turbinate lateralization. Eight cm slim Merocel packed in 67 nasal cavity sides, 8 cm regular Merocel packed in 24 sides and 10 cm regular Merocel packed in 6 sides. Thirty-seven patients had the pack for 6 hours then removed and 17 patients had it for 24 hours. Forty-one patients with no significant discomfort, 13 patients with mild to moderate discomfort.

Conclusion: Septorhinoplasty and SMD or lateralization of inferior turbinate can be managed without packing or any other hemostatic measures.

Saudi Med J 2008; Vol. 29 (7): 994-997

From the Department of Otorhinolaryngology, Head & Neck Surgery, King Abdulaziz University Hospital, Riyadh, Kingdom of Saudi Arabia.

Received 25th February 2008. Accepted 18th June 2008.

Address correspondence and reprint request to: Dr. Jamil N. Al-Swiabb, Department of Otorhinolaryngology, King Abdulaziz University Hospital, PO Box 245, Riyadh 11411, Kingdom of Saudi Arabia. Tel. +966 (1) 2355769. Fax. +966 (1) 2350220. E-mail: ziad8026@hotmail.com/fawaz8026@yahoo.com

Nasal packing is known as the primary treatment for moderately severe epistaxis since it was first documented by Hippocrates in the fifth century BC.¹ Packing devices act by maintaining pressure on the damaged blood vessel within the nasal mucosa, allowing thrombus to form and become organized. Packing of the nasal cavity following surgery reduces the incidence of post-operative hemorrhage, decrease edema, provide internal support to bony parts, and increase septal flap apposition. But it may expose the patient to complications such as sinusitis or toxic shock syndrome which indicate prescribing patients prophylactic systemic antibiotics that may result in allergic reactions and emergence of highly resistant bacteria. The aim of the present study was to evaluate the necessity of nasal packing after meticulous nasal surgery, effective duration of hemostasis if needed, and its complications.

Methods. This is a prospective study approved by the local internal review board and performed on 54 patients undergoing elective septoplasty, septorhinoplasty and non-destructive turbinate reduction procedure by same group of surgeon in Otorhinolaryngology Department at King Abdulaziz University Hospital, between 2005 and 2006. All patients signed an informed consent form and were scheduled to undergo the procedure under general anesthesia according to the standard preoperative assessment used in our department. Only patients with hemoglobin levels higher than 10 mg/dL, normal prothrombin, and normal partial thromboplastin times were eligible for surgery. Exclusion criteria were a history of renal and hepatic insufficiency, pregnancy, allergy, asthma, peptic ulcer, bleeding disorders and intolerance to nonsteroidal anti-inflammatory drug (NSAID). All patients undergoing surgery under general anesthesia were maintained according to the anesthesiologist's preference. A hypotensive technique was used. In all cases, 2 mL of 2% lidocaine with 1:100,000 epinephrine were applied topically by gauze pledgets for 10 minutes at the beginning of surgery. The medial nasal wall (septum) was injected with 2% lidocaine with 1:100,000 epinephrine bilaterally including the site of incision, rasping and osteotomy sites. Bipolar electrocautery was used only when a pulsatile bleeding artery was encountered. At the end of surgery the silastic sheets applied and fixed. Merocel packing was used in all patients after completion of surgery. Patients was analyzed with regard to demographic characteristics, medical history, previous surgeries, current surgical procedure, type of anesthesia, amount of intraoperative bleeding, incidence of nasal bleeding after removal of nasal pack after 6-hours in some patients and 24 hours in others and nasal pack complication and discomfort was also analyzed.

Statistical analysis was performed using SPSS 12.0 for Windows (SPSS, Inc., Chicago, IL). A probability value of <0.05 was considered significant. All patients remained hospitalized for one nights after surgery. They were instructed to sleep with their head elevated, to refrain from hot food and from blowing their nose, and to rinse their nose with normal saline and Otrivin nasal spray. Antibiotics were given for the duration of 10 days. Manual clearing of the nose in addition, silastic sheet and stitch removal at the first clinic visit (6 days after surgery).

Results. Fifty-four patients underwent septoplasty, septorhinoplasty and turbinate reduction surgery between January 2005 and December 2006. Age ranged from 8 to 42 years (mean age 20 years). Fifty-four patients (45 males and 9 females) fulfilled our criteria and enrolled into the study. The same surgeon and the same anesthetist performed all operations. Thirty-seven patients (68.5%) packed for 6 hours then removed, so minimal nasal bleeding (<5 ml) occur in 29 (78.1%) and moderate nasal bleeding (<25 ml) in 8 patients (21.9%). Seventeen patients packed for 24 hours, 14 (82.4%) had minimal bleeding and 6 (17.6%) had moderate bleeding with p -value of 0.87 (Figure 1). Thirty-five (64.9%) patients packed with size 8 slim Merocel, 30 (85.7%) with minimal bleeding and 5 (14.3%) had moderate bleeding. Fourteen (25.8%) packed with size 8 regular Merocel, 10 (71.4%) had minimal bleeding and 4 (28.6%) had moderate bleeding. And 5 (9.2%) packed with size 10 regular Merocel 1 (20%) had minimal bleeding and 4 (80%) had moderate bleeding (Figure 2). Thirty-six (66.7%) patients had in addition to main procedure inferior turbinate procedure (submucous diathermy SMD

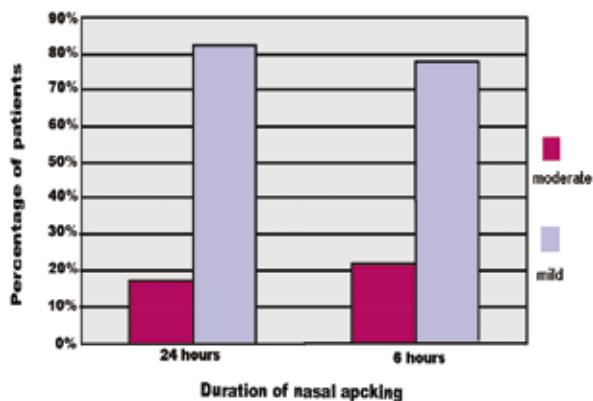


Figure 1 - Relationship between severity of bleeding and duration of nasal pack.

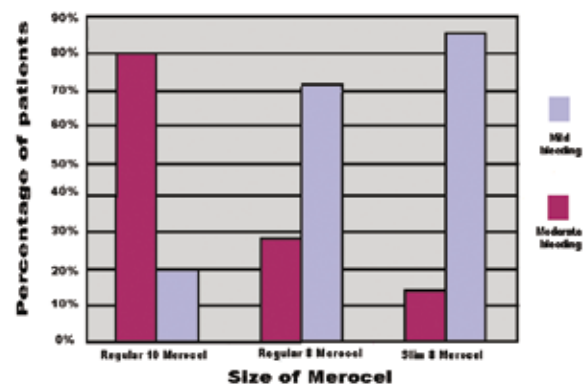


Figure 2 - Relationship between severity of bleeding and size of merocel.

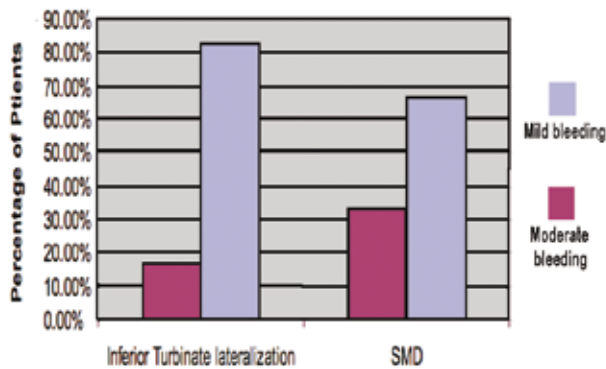


Figure 3 - Relationship between severity of bleeding and type of turbinate surgery.

Table 1 - Complications of nasal packing.

Complication	Aetiology
Hemorrhagic shock	Failure to stop bleeding
Septic shock	Infection
Toxic Shock Syndrome	Infection
Nasal septum perforation	Pressure necrosis
Epiphora	Blockage of Nasolacrimal duct
Sinusitis	Blockage of sinus drainage
Hypoxia	Blockage of nasal airway
Obstructive sleep apnea	Blockage of nasal airway
Neurogenic Syncope	Nasovagal reflex
Acute airway obstruction	Displacement of the nasal pack

and inferior turbinate lateralization), 12 (33.3%) had SMD, 8 (66.7%) had minimal bleeding and 4 (33.3%) had moderate bleeding. Twenty-four (66.7) patients underwent inferior turbinate lateralization, 20 (83.3%) had minimal bleeding and 4 (16.7) had moderate bleeding (**Figure 3**). Forty-one (79.6%) patients with no significant nasal pack discomfort (pain or sleep disturbance) and 13 (20.4%) with mild discomfort (p-value 0.22).

Discussion. Nasal packing is routinely performed by many surgeons following nasal surgery such as septoplasty, rhinoplasty, septorhinoplasty, turbinate surgery, intranasal biopsy, endoscopic sinus surgery and submucosal resections. This has led to the development of various packing materials, includes silastic-coated foam packs (Rhinotamps), self-expanding polyvinylacetate packs (Merocel), hydrogel-coated packs (Rhino-Force), oint-impregnated gauze strips (Tampogress), and Telfa gauze.¹ Nasal packing can provide hemostasis, prevent hematoma formation, support septal flap apposition, close dead spaces between cartilage and mucoperichondrial flaps, and prevent displacement of the cartilage or bony grafts.² Furthermore, nasal packing may also be life saving in cases of epistaxis, when there

is no hint of the need for a spot cauterization or when cauterization fails to control bleeding. It also prevents potential systemic toxicity and adverse reactions onto the nasal mucosa when silver nitrate is used for chemical cauterization.² However, application of a nasal pack may result in severe complications. These complications are diverse and range from a relatively simple postoperative hemorrhage to life-threatening toxic shock syndrome (**Table 1**). To avoid some of the complications alternative methods suggested in many articles such as suturing the mucoperichondrial flaps to the septal cartilage, the use of silicon mesh,² hemostatic dissolvable nasal packs,³ and nasal stents but still not without complications.² Moumoulidis et al⁴ concluded that Merocel and Rapid Rhino nasal packs are effective, relatively easy to use and associated with minimal complications.^{4,5} We used Merocel pack in all of our patients to reduce the risk of postoperative oozing of blood, sometimes with significant blood loss, and the possibility of aspiration leading to pneumonitis. Coughing of blood in the recovery room puts nursing care workers at risk of being exposed to bloodborne infections thus, we used slim Merocel to reduce the nasal pack discomfort and compare it with regular size and we found better comfort and no significant difference in post-nasal pack removal bleeding. Decision to pack the nose during surgery for hemostasis is left to the operating surgeon and is usually not contested.⁵ Nasal packing was well described in the literature and there was no universal protocol regarding the ideal packing material and duration of its effective application.³ Several factor facilitates preventing postoperative bleeding, thus negating the need for packing include strict local anesthesia technique, application of local vasoconstrictors and minimal tissue damage.⁶ In our study, intraoperative bleeding is not sever with haemostatic measures (hypertensive anesthesia, nasal decongestant, epinephrine/zylocain injection and minimal mucosal manipulation) thus patients with unusual bleeding were excluded and the different kind of pack were used randomly for different duration and we found that the differences in postoperative bleeding in all group were not significant (**Figure 1-3**). Tierney et al⁷ evaluated tolerability of nasal packing after endonasal surgery and claimed that a short-term application of nasal packing increased tolerability to the packing. In contrast, Toffel⁸ reported that a long-term use of nasal packing had a positive effect on wound healing. Furthermore, early removal of nasal pack after insertion may cause recurrent bleeding, thus, many physicians leave nasal pack in place for 3-5 days.⁹ In this study, we demonstrated the safety and feasibility of early removal of both nasal tampons, even as early as 6 hours after insertion. Even though recurrent bleeding was uncommon, the benefits of early tampon

removal are numerous, including increased patient comfort, a reduction in the risk of infections (such as sinusitis and toxic shock syndrome), and a reduction in the risk of drug allergies and the development of resistant bacteria. A study on patient discomfort caused by nasal packs of various materials (Telfa, paraffin gaze, Merocel, BIPP) revealed no difference in discomfort between the materials.⁸ However, nose packs are uncomfortable; their removal is painful and can cause other complications such as bleeding, adhesions, septal perforations and rarely infections,⁵ in this review 20.4% had discomfort (pain and sleep disturbance) with no further complication.

In conclusion, we suggested that the routine use of nasal packs after nasal surgery is not justified; and this study has demonstrated that nasal pack for at least 6 hours in patients undergoing nasal surgery significantly reduces post-operative bleeding, which reducing patient discomfort and postoperative complications.

References

1. Kim MG, Baek RM, Minn KW, Heo CY, Kwon SS, Park CY. Nasal packs with X-ray indicators. *Ann Plast Surg* 2006; 56: 342-343.
2. Genç E, Ergin NT, Bilezikçi B. Comparison of suture and nasal packing in rabbit noses. *Laryngoscope* 2004; 114: 639-645.
3. Karkos PD, Thinakarajan T, Goodyear P, Srinivasan VR. Day-case endoscopic sinus surgery using dissolvable haemostatic nasal packs: a pilot study. *Eur Arch Otorhinolaryngol* 2007; 264: 1171-1174. Epub 2007 Jun 12
4. Moumoulidis I, Draper MR, Patel H, Jani P, Price T. A prospective randomised controlled trial comparing Merocel and Rapid Rhino nasal tampons in the treatment of epistaxis. *Eur Arch Otorhinolaryngol* 2006; 263: 719-722. Epub 2006 May 10.
5. von Schoenberg M, Robinson P, Ryan R. Nasal packing after routine nasal surgery--is it justified? *J Laryngol Otol* 1993; 107: 902-905.
6. Eliashar R, Gross M, Wohlgeleitner J, Sichel J. Packing in Endoscopic Sinus Surgery: Is It Really Required? *Otolaryngology-Head and Neck Surgery* 2006; 134: 276-279.
7. Tierney PA, Samuel D, Patel KS, Thomas DM. Audit of patient acceptance of nasal surgery as a day case procedure. *Br J Clin Pract* 1996; 50: 357-359.
8. Toffel PH, Aroesty DJ, Weinmann RH 4th. Secure endoscopic sinus surgery as an adjunct to functional nasal surgery. *Arch Otolaryngol Head Neck Surg* 1989; 115: 822-825.
9. Yilmazer C, Sener M, Yilmaz I, Erkan AN, Cagici CA, Donmez A, et al. Pre-emptive analgesia for removal of nasal packing: A double-blind placebo controlled study. *Auris Nasus Larynx* 2007; 34: 471-475.

Supplements

- * Supplements will be considered for work including proceedings of conferences or subject matter covering an important topic
- * Material can be in the form of original work or abstracts.
- * Material in supplements will be for the purpose of teaching rather than research.
- * The Guest Editor will ensure that the financial cost of production of the supplement is covered.
- * Supplements will be distributed with the regular issue of the journal but further copies can be ordered upon request.
- * Material will be made available on Saudi Medical Journal website