

## Determination of nephrotoxicity and genotoxic potential of silver nanoparticles in Swiss albino mice

Saud Alarifi, Daoud Ali, Mohammed A Al Gurabi & Saad Alkahtani

To cite this article: Saud Alarifi, Daoud Ali, Mohammed A Al Gurabi & Saad Alkahtani (2017) Determination of nephrotoxicity and genotoxic potential of silver nanoparticles in Swiss albino mice, Toxicological & Environmental Chemistry, 99:2, 294-301, DOI: [10.1080/02772248.2016.1175153](https://doi.org/10.1080/02772248.2016.1175153)

To link to this article: <https://doi.org/10.1080/02772248.2016.1175153>



Published online: 09 May 2016.



Submit your article to this journal [↗](#)



Article views: 142



View related articles [↗](#)



View Crossmark data [↗](#)



Citing articles: 1 View citing articles [↗](#)

## Determination of nephrotoxicity and genotoxic potential of silver nanoparticles in Swiss albino mice

Saud Alarifi, Daoud Ali, Mohammed A Al Gurabi and Saad Alkahtani

Department of Zoology, College of Science, King Saud University, Riyadh, Saudi Arabia

### ABSTRACT

Silver nanoparticles (AgNPs) possess properties that are important for industrial and medical applications. This study is aimed to investigate intra-peritoneal toxicity of AgNPs at 26, 52 or 78 mg/kg/day for 5 days in mice Swiss albino mice. The effects on oxidative stress markers activities of serum superoxide dismutase (SOD) and catalase (CAT), levels of serum glutathione (GSH), apoptosis (TUNEL assay), DNA strand breaks (comet assay) in lymphocytes, as well as histopathological of kidney tissue were determined. AgNPs significantly increased SOD and CAT activities reduced GSH levels. In kidney apoptosis (TUNEL assay) while DNA strand breaks (comet assay) in lymphocytes revealed that AgNPs at concentration 78 mg/kg produced significant apoptosis and DNA damage. AgNPs also produced associated histological renal tissue damage. Evidence suggests that AgNPs-mediated alterations may be attributed to oxidative stress.

### ARTICLE HISTORY

Received 15 February 2016  
Accepted 1 April 2016

### KEYWORDS

Silver nanoparticles; kidney tissue; histology; apoptosis; DNA damage

## Introduction

Nanomaterials are widely used in environmental remediation; consumer products, electronics, and health care (Gerber and Lang 2006; Zhao and Castranova 2011). Silver nanoparticles (AgNPs) have drawn more consideration currently due to their antibacterial and antimycotic actions. Fung and Bowen (1996) reported that Ag (colloidal form) was used as an oral drug to control and treat diseases. However, there are associated adverse risks (Johnston et al. 2010). Characterization of the risk-benefits needs to be estimated in order to continue to utilize these compounds. Asharani et al. (2009) noted that AgNPs-induced cytotoxic and genotoxic effects in *in vitro*. Gagne et al. (2013a, 2013b) demonstrated that AgNPs produced cytotoxic, immunotoxic, oxidative stress, and DNA damage in freshwater mussels. Oxidative stress as evidenced by free radical production was suggested to be involved in cytotoxicity and genotoxicity (Ostrovsky et al. 2009). Tang (2008) noted that AgNPs produce more severe toxicity compared to other metallic nanoparticles (NPs) such as iron, manganese, nickel, and aluminum. Li and Chen (2011) reported that NPs translocated to other organs attributed to small size. The aim of this study is to

determine the biological risks and benefits of AgNPs using various tissues serum, blood lymphocytes, and kidney from Swiss albino mice.

## Materials and methods

### Chemicals and animals

AgNPs (APS < 50 nm) were synthesized at Chemistry Department, King Saud University while other chemicals were purchased locally. A total of 40 Swiss albino mice six weeks old weighing 25–30 gm were acquired from animal house of Faculty of Pharmacy, King Saud University, Saudi Arabia.

### Characterization of AgNPs

AgNPs were placed in double distilled water at 5 mg/5 ml. The solution was mixed by sonication for 15 min at 40 W. Size of AgNPs was measured by transmission electron microscope (TEM) (JEOL model 2100 F) at 200 kV.

### Experimental design

Mice were kept on standard lab mice diet and placed in temperature and moisture controlled cages on 12 h light/dark cycle. Five animals from each group were sacrificed at day 1 and 5 after treatment with AgNPs. Investigations were carried out in according guidelines approved by King Saud University local animal care and use committee.

On the basis of LC<sub>50</sub> 96 h value, different concentrations 26, 52 or 78 µg/kg AgNPs of silver nanoparticles were selected. Mice were divided into four groups (20 mice/set) and exposed as following: (Figure 1)

- Group 1-Untreated animals (normal water)
- Group 2-AgNPs (26 mg/kg b.w. for 1 or 5 days) i. p.
- Group 3-AgNPs (52 mg/kg b.w. for 1 or 5 days) i. p.
- Group 4-AgNPs (78 mg/kg b.w. for 1 or 5 days) i. p.

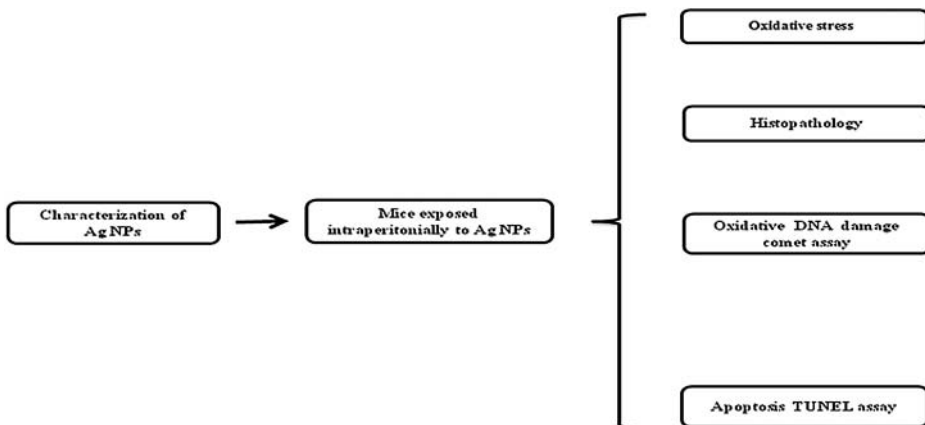


Figure 1. Schematic diagram of study design.

### **Collection of blood and serum**

Serum was harvested from mice blood after centrifugation at 4500 g and stored at  $-80^{\circ}\text{C}$  until evaluation of superoxide dismutase (SOD), catalase (CAT) enzymes, and glutathione (GSH) by using Cayman Chemical kits.

### **Alkaline single-cell gel electrophoresis (SCGE)**

The SCGE test was done according to the method of Ali et al. (2008). Blood lymphocyte cells were isolated from total blood using histopaque and watered down 20-fold for SCGE test. Viability of lymphocytes cells was assessed by trypan blue exclusion assay (Anderson et al. 1994).

### **Staining for apoptosis in kidney tissue**

According the manufacture's specified protocol, paraffin embedded sections of kidney tissue of control and AgNPs treated mice for either 1 or 5 days were stained for apoptotic nuclei using terminal deoxynucleotidyl transferase mediated dUTP nick end labeling (TUNEL) assay (Gen Script The Biology CRO, Piscataway, NJ, USA). Two slides from each group manually quantitated for the total number of cells and apoptotic cells within renal tissue and snaps taken by using optical microscope (Olympus).

### **Histopathology**

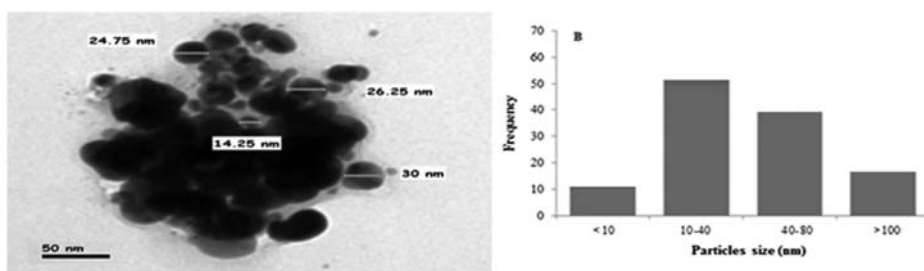
After exposure, animals were killed by decapitation. Fresh kidney tissues from each animal were cut quickly, fixed in 10% formalin, and dehydrated, with grades of ethanol (70%, 80%, 90%, 95%, and 100%). After dehydration samples were evaporated with xylene twice. Kidney tissues were saturated with two changes of paraffin wax, then fixed and blocked out. Sections ( $4\ \mu\text{m}$ ) were stained with eosin and hematoxylin according to Alarifi et al. (2013). Stained sections of control and exposed mice were observed and photos were taken using microscope (Olympus Microscope BX51 with Digital Camera, Tokyo, Japan), for changes in the nephritic architecture, glomeruli, and for the presence of apoptosis, necrosis, degeneration, and glomerulosclerosis.

### **Statistical analysis**

At least three independent experiments were carried out for each evaluation. Data were expressed as mean ( $\pm\text{SE}$ ) and statistically analyzed by one-way analysis of variance. The  $p$ -value  $< 0.05$  was considered statistically significant.

### **Results and discussion**

The size and shape of AgNPs were characterized by TEM and found to be in nano-range, but AgNPs formed small agglomerates in aqueous suspension. The average size measured by TEM was  $31.6 \pm 5.2\ \text{nm}$  (Figure 2(B)). The physiochemical effects of NPs were derived



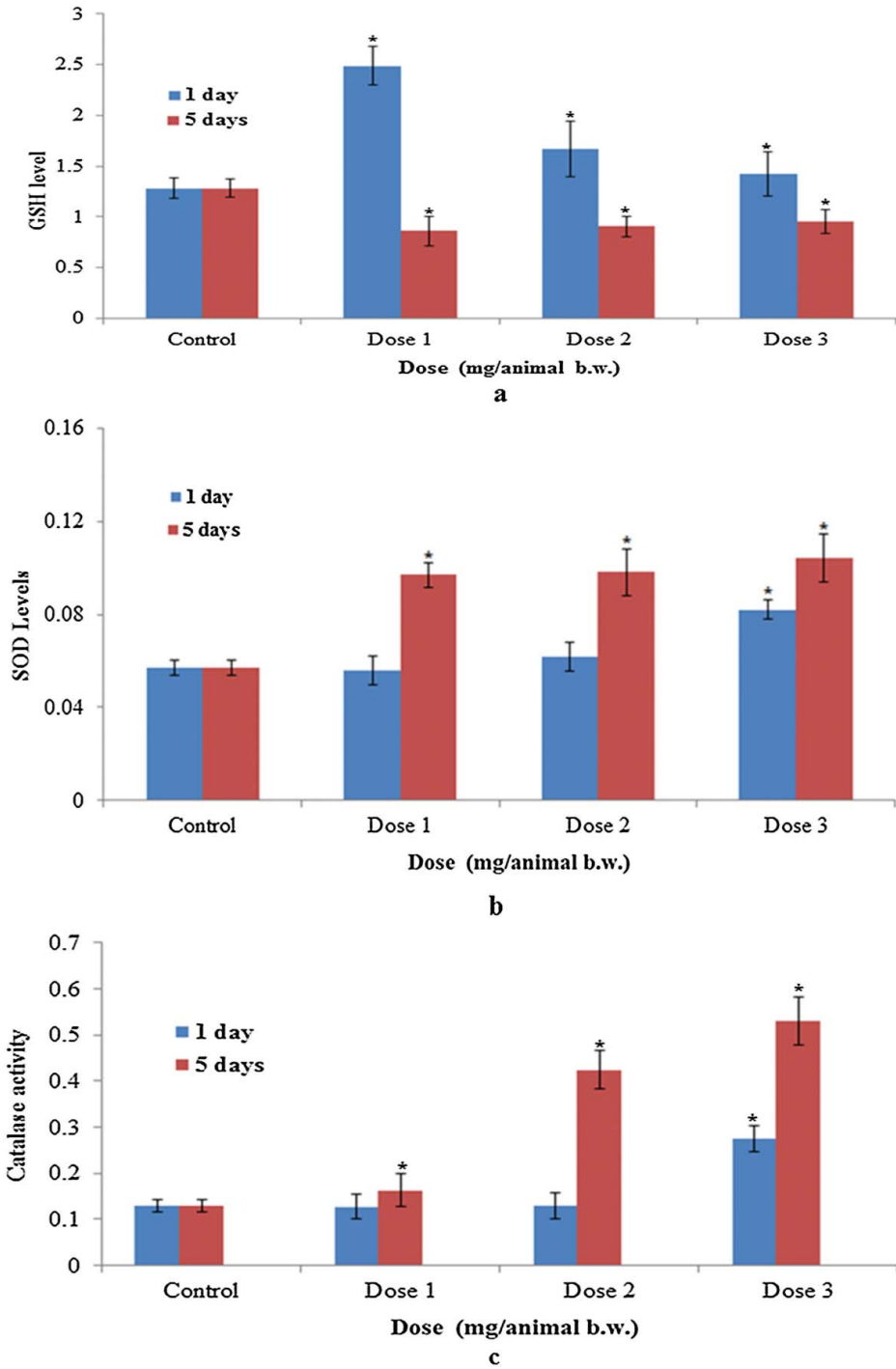
**Figure 2.** Characterization AgNPs (A) TEM image (B) the size distribution histogram generated by using TEM image.

from its high surface to volume ratio. NPs have higher fraction of atoms on its surface compared with microparticles, which makes it more reactive.

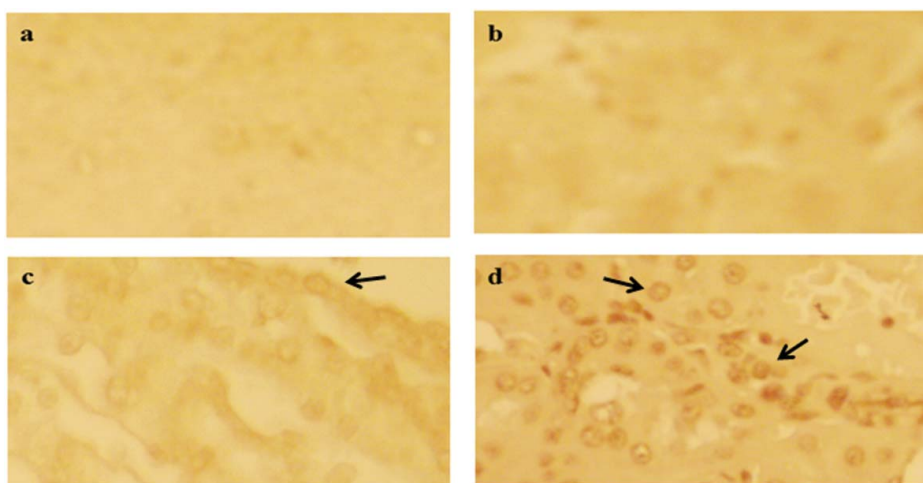
The main outcome of this study is significant increase in activities of SOD and CAT but fall in GSH levels at 26, 52 or 78 mg/kg AgNPs compared to control (Figure 3). Among the most sensitive and widely used oxidative stress markers are GSH levels and activities of SOD and CAT. The rate of AgNPs uptake in the kidney is believed to be depended upon the injected dose and time. Apoptosis and DNA damage were seen in kidney cells and lymphocytes of mice treated with AgNPs, respectively (Figures 4 and 5). Compared with control group, histological variations were noted in kidney tissue of Swiss albino mice treated with AgNPs (Figure 6). Histopathological observation showed AgNPs produced severe damage in kidney. In this study, nephrotic cells may be more efficient to uptake of AgNPs. The rate of metabolism in these cells is believed to be depended upon the concentration of AgNPs taken by cell types (Wisse, Doucet, and Van Bossuyt 1991).

The presence of inflammatory cells in kidney tissue indicates that AgNPs interact with proteins and enzymes in the interstitial tissue of the kidney, preventing with the antioxidants protection mechanism and leading to production of reactive oxygen species, which in turn may initiate an inflammatory response. Immunotoxicity attributed to AgNPs was previously reported by Gagne et al. (2013b) in freshwater mussels. Bi-nucleation is a concern of cell injury and a type of chromosomal hyperplasia typically observed in redeveloping cell (Gerlyng et al. 2008). Cell puffiness may be accompanied by escape of lysosomal hydrolytic enzymes, leading to deterioration of the cytoplasm and macromolecule (Del Monte 2005). Hydropic disintegration is a result of ion and fluid homeostasis and leads to an increase in intracellular water (Schrand, Rahman, and Hussain 2010). The vacuolated swelling seen in the cytoplasm of kidney cells from mice exposed to AgNPs indicates acute kidney injury.

DNA damage and apoptosis in kidney cells treated to AgNPs increased in a dose and time-dependent manner (Figures 4 and 5). Well-defined necrosis was also noted in some kidney cells in mice treated with AgNPs, which may be due to oxidative stress. AgNPs-induced apoptosis and genotoxicity was reported in plants (*Allium cepa* and *Nicotiana tabacum*), animals (Swiss albino mice) (Ghosha et al. 2012), and freshwater mussels (Gagne et al. 2013a). In this study, after intra-peritoneal (ip) administration of AgNPs (78 mg/kg b.w.), the difficulty encountered in clearance of these NPs may have resulted in deposition of particles in kidney and leading to renal injury. The kidney is excretory organ

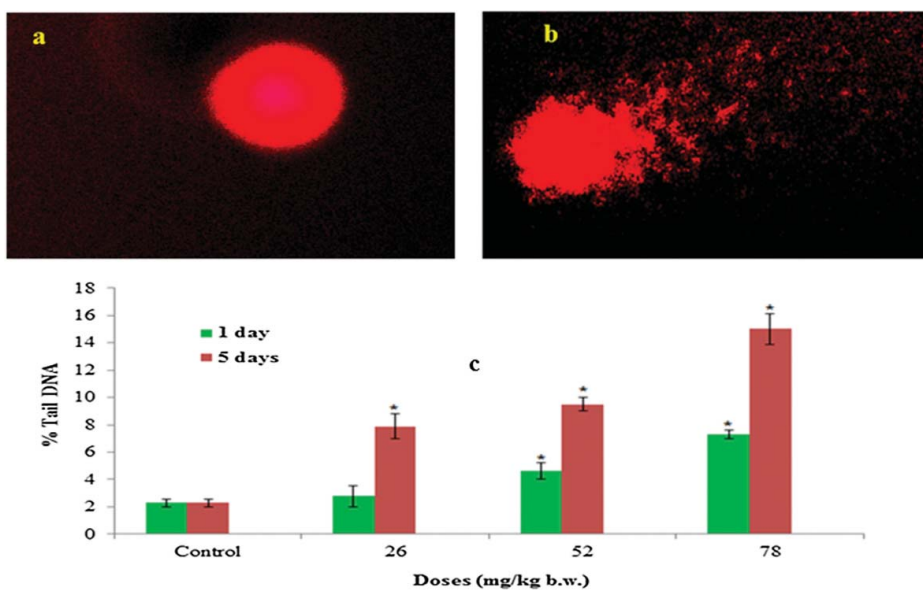


**Figure 3.** (A) GSH (B) SOD (C) catalase activity after exposure to AgNPs for 1 and 5 days. Each value represents the mean  $\pm$  SE of three experiments. \* $p < 0.05$  vs. control.



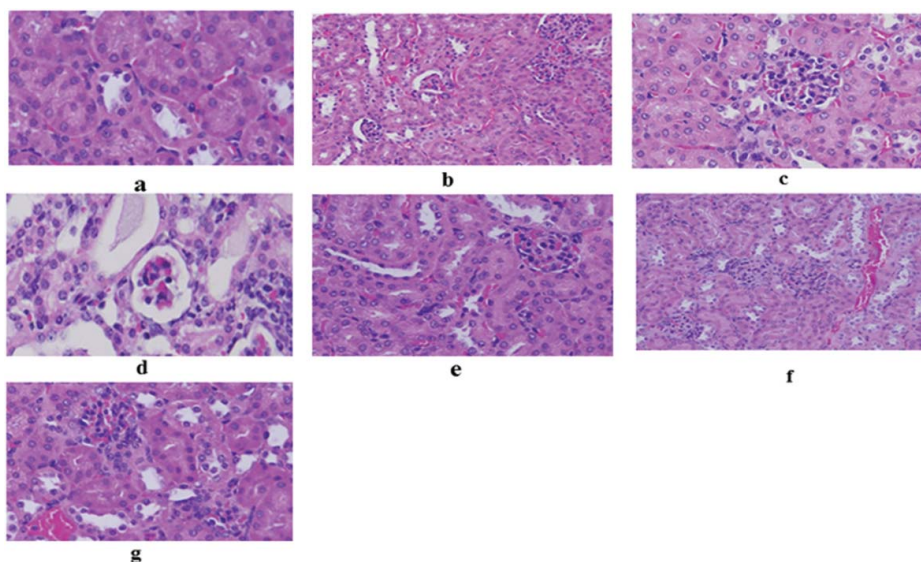
**Figure 4.** Apoptosis cells in kidney tissue of Swiss albino mice after exposure of AgNPs. (A) Control (B) 26 mg/kg b.w. (C) 52 mg/kg b.w. (D) 78 mg/kg b.w.

in the body and removes waste products and eliminates adverse effects induced by the ingested mass of AgNPs. Due to the small size and difficult clearance, AgNPs accumulated in animal and renal damage occurred after high concentration ip treatment. In conclusion, our results indicate that AgNPs induce histological changes in kidney tissue, via oxidative stress to induce genotoxicity and apoptosis.



**Figure 5.** DNA damage in kidney cells of Swiss albino mice after exposure of silver nanoparticles. (A) Control (B) 78 mg/kg b.w. for 5 days (C) % Tail DNA. Data is presented mean  $\pm$  SEM of three experiments.

\* $p < 0.05$  vs. control.



**Figure 6.** (A–G). Microphotographs of kidney tissue. (A) Mice injected with Mill Q water over 5 days demonstrating normal histological architecture. H&E, 100 $\times$ . (B) Mice injected to AgNPs (26 mg/kg b.w.) over 1 day demonstrating lymphocytes infiltration. H&E, 100 $\times$ . (C) Mice injected to AgNPs (52 mg/kg b.w.) over 1 day demonstrating marked necrosis and scattered hemorrhages. H&E, 100 $\times$ . (D) Mice injected to AgNPs (78 mg/kg b.w.) over 1 day administration demonstrating vacuolization of renal cells. H&E, 100 $\times$ . (E) Mice injected to AgNPs (26 mg/kg b.w.) over 5-day edema around the blood vessel. H&E, 100 $\times$ . (F) Mice injected to AgNPs (52 mg/kg b.w.) over 5 days demonstrating lymphocytic infiltration. H&E, 100 $\times$ . (G) Mice injected to AgNPs (78 mg/kg b.w.) for 5 days demonstrating swelling and hydropic degeneration of kidney cells. H&E, 100 $\times$ .

## Acknowledgments

The authors would like to extend their sincere appreciation to the Deanship of Scientific Research at King Saud University for its funding, this Research Group Project No RGP-180.

## Disclosure statement

The authors declare no conflicting interests.

## Funding

Deanship of Scientific Research at King Saud University for its funding this Research Group Project No RGP-180.

## References

- Alarifi, S., D. Ali, A.A. Al-Doaiss, B.A. Ali, M. Ahmed, and A.A. Al-Khedhairi. 2013. "Histologic and Apoptotic Changes Induced by Titanium Dioxide Nanoparticles in the Livers of Rats." *International Journal of Nano Medicine* 8: 3937–3943.
- Ali, D., N.S. Nagpure, S. Kumar, R. Kumar, and B. Kushwaha. 2008. "Genotoxicity Assessment of Acute Exposure of Chlorpyrifos to Freshwater Fish *Channa Punctatus* (Bloch) using Micronucleus Assay and Alkaline Single-cell Gel Electrophoresis." *Chemosphere* 71 (10): 1823–1831.



- Anderson, D., T.W. Yu, B.J. Phillips, and P. Schmerzer. 1994. "The Effect of Various Antioxidants and Other Modifying Agents on Oxygen-Radical-Generated DNA Damage in Human Lymphocytes in the COMET Assay." *Mutation Research* 307: 261–271.
- Asharani, P.V., K.M.G. Low, M.P. Hande, and S. Valiyaveetil. 2009. "Cytotoxicity and Genotoxicity of Silver Nanoparticles in Human Cells." *ACS Nano* 3: 279–290.
- Del Monte, U. 2005. "Swelling of Hepatocytes Injured by Oxidative Stress Suggests Pathological Changes Related to Macromolecular Crowding." *Medical Hypotheses* 64: 818–825.
- Fung, M.C., and D.L. Bowen. 1996. "Silver Products for Medical Indications: Risk-Benefit Assessment." *Clinical Toxicology* 34: 119–126.
- Gagne, F., J. Auclair, P. Turcotte, and C. Gagnon. 2013a. "Sublethal Effects of Silver Nanoparticles and Dissolved Silver in Freshwater Mussels." *Journal of Toxicology and Environmental Health, Part A* 76: 479–490.
- Gagne, F., J. Auclair, M. Fortier, A. Bruneau, M. Fournier, P. Turcotte, M. Pilote, and C. Gagnon. 2013b. "Bioavailability and Immunotoxicity of Silver Nanoparticles to the Freshwater Mussel *Elliptio complanta*." *Journal of Toxicology and Environmental Health, Part A* 76: 767–777.
- Gerber, C., and H.P. Lang. 2006. "How the Doors to the Nano-World Were Opened." *Nature Nanotechnology* 1: 3–5.
- Gerlyng, P., A. Åbyholm, T. Groton, B. Erikstein, H.S. Huitfeldt, T. Stokke, and P.O. Seglen. 2008. "Binucleation and Polyploidization Patterns in Developmental and Regenerative Rat Liver Growth." *Cell Proliferation* 26: 557–565.
- Ghosha, M., J. Manivannan, S. Sinha, A. Chakraborty, S.K. Mallick, M. Bandyopadhyay, and A. Mukherjee. 2012. "In vitro and in vivo Genotoxicity of Silver Nanoparticles." *Mutation Research* 749: 60–69.
- Johnston, H.J., G. Hutchison, F.M. Christensen, S. Peters, S. Hankin, and V. Stone. 2010. "A Review of the in vivo and in vitro Toxicity of Silver and Gold Particulates: Particle Attributes and Biological Mechanisms Responsible for the Observed Toxicity." *Critical Reviews in Toxicology* 40: 328–346.
- Kermanizadeh, A., I. Gosens, L. MacCalman, H. Johnston, P.H. Danielsen, N.R. Jacobsen, A.-G. Lenz, et al. 2016. "A Multilaboratory Toxicological Assessment of a Panel of 10 Engineered Nanomaterials to Human Health – ENPRA Project – The Highlights, Limitations and Current and Future Challenges." *Journal of Toxicology and Environmental Health B* 19: 1–28.
- Li, Y.F., and C. Chen. 2011. "Fate and Toxicity of Metallic and Metal-Containing Nanoparticles for Biomedical Applications." *Small* 7: 2965–2980.
- Ostrovsky, S., G. Kazimirsky, A. Gedanken, and C. Brodie. 2009. "Selective Cytotoxic Effect of ZnO Nanoparticles on Glioma Cells." *Nano Research* 2: 882–890.
- Project of the Emerging Nanotechnologies. 2009. Project of the Emerging Nanotechnologies (PEN). <http://www.nanotechproject.org>
- Schrand, A.M., M.F. Rahman, and S.M. Hussain. 2010. "Metal-based Nanoparticles and Their Toxicity Assessment." *Wiley Interdisciplinary Reviews: Nanomedicine and Nanobiotechnology* 2: 544–568.
- Tang, J. 2008. "Status of Biological Evaluation on Silver Nanoparticles." *Journal of Biomedical Engineering* 25: 958–961.
- Wisse, E., D. Doucet, and H. Van Bossuyt. 1991. "A Transmission Electron Microscopic Study on the Uptake of AMI-25 by Sinusoidal Liver Cells." In *Cells of the Hepatic Sinusoid*, edited by E. Wisse, 534–539. The Netherlands: Kupffer Cell Foundation.
- Zhao, J., and V. Castranova. 2011. "Toxicology of Nanomaterials Used in Medicine." *Journal of Toxicology and Environmental Health B* 14: 593–632.